Effect of Farming Condition on Postnatal Growth and Development of Lymphoid Organs and Tissues in Deshi Chicken (*Gallus domesticus*) of Bangladesh

Md. Shahriar Hasan Sohel[1], Abdullah Al Faruq[1],
Mohammad Shahjalal[2], Mohammad Lutfur Rahman[1]

10.18805/ag.D-162

ABSTRACT

Total 40 non-descriptive deshi chickens were reared in scavenging and intensive farming system (20 for each) from day 1 to 180. Gross examinations of different lymphoid organs and tissues were performed at D_1, D_{30}, D_{90} and D_{180} for both types of chickens. Tissue samples were stained with H and E stain and AmScope image measurement software was used for histomorphometry. Gross and histomorphometrical parameters of thymus, spleen and cecal tonsils gradually increased significantly ($P \leq 0.05$) with the advancement of ages from D_1 to D_{180} in both scavenging Deshi chickens (SDC) and captive Deshi chickens (CDC). Gross and histomorphometrical parameters of bursa increased up to D_{90} and thereafter decreased indicating the involution of bursa by D_{180}. The gross and histomorphometrical parameters of bursa, thymus, spleen and cecal tonsils were significantly ($P \leq 0.05$) higher in all age groups of CDC (except D_1 chicks) as compared with SDC, owing to the different patterns of rearing system.

Key words: Bursa, Cecal tonsil, Deshi chicken, Postnatal, Spleen, Thymus.

INTRODUCTION

Deshi or native chicken is a major local chicken breed in Bangladesh. This breed is being reared in Bangladesh for a long period of time and it has contributed about 19.75 and 25.06 per cent of total meat and egg production, respectively (Dutta *et al.,* 2013). Most of the farmers, particularly village women reared these chickens. For this reason, these chickens are usually regarded as a “Walking Bank or Bank Coin” for the rural poor families. These chickens are frequently reared in free range farming system where they scavenge for feeds during the day time and are confined at night. They usually take kitchen waste, seeds, grains, garden leftover, insects, green grasses and all other human refusal that would otherwise go to waste. Attaining approximately 1.0 kg at 6 months of age in free range farming system (Rahman *et al.,* 2003; Islam *et al.,* 2012), their body weight also increases if being reared in intensive farming system (Ershad, 2005). The lymphoid organs of chicken, *viz.* bursa and thymus and tissues, *viz.* spleen and cecal tonsils, plays significant roles in the prevention of disease occurrence (Khalil *et al.,* 2002; Tizard, 2013). Studies on the lymphoid organs of chicken have revealed that the growth and development of lymphoid organs and morphology and functions of tissues are related with the growth of chickens (Ciriaco *et al.,* 2003). In turn, the growth rates of chickens are related with their rearing systems (Ershad, 2005).

Many scientists have studied the postnatal growth and development of lymphoid organs in different high yielding birds like Broiler chicken (Nagy and Olah, 2010; Khenenou *et al.*, 2012; Khan *et al.*, 2014), White Leghorn chicken (Betti *et al.*, 1991; Del Moral *et al.,* 1998; Kozuka *et al.*, 2010), Aseel chicken (Haseeb *et al.*, 2014), CARI Shyama and Vanaraja chickens (Jain *et al.*, 2010), Guinea fowl (Onyeanusi *et al.*, 1994) and Geese (Gulmez and Aslan, 1999). A few number of research were conducted on gross and histomorphology of the postnatal lymphoid organs of deshi chickens in Bangladesh (Khalil *et al.*, 2002), with the results being compared to broiler chickens as well as other high yielding chickens. The reports on postnatal growth and development of lymphoid organs of deshi chickens reared in intensive farming system are scanty. Some authors have also reported that due to scavenging nature, the postnatal lymphoid organs of deshi chickens contain more immunocompetent cells than that of high yielding chickens (Khan *et al.*, 2007; Islam *et al.*, 2012). Therefore, from economic, nutritional and immunological point of view, this

[1]Department of Anatomy and Histology, Chittagong Veterinary and Animal Sciences University, Zakir Hossain Road, Khulshi, Chittagong-4225, Bangladesh.
[2]Department of Microbiology and Veterinary Public Health, Chittagong Veterinary and Animal Sciences University, Zakir Hossain Road, Khulshi, Chittagong-4225, Bangladesh.

Corresponding Author: Md. Shahriar Hasan Sohel, Department of Anatomy and Histology, Chittagong Veterinary and Animal Sciences University, Zakir Hossain Road, Khulshi, Chittagong-4225, Bangladesh. Email: s.h.sohel08@gmail.com

How to cite this article: Sohel, M.S.H., Faruq, A.A., Jalal, M.S. and Rahman, M.L. (2020). Effect of Farming Condition on Postnatal Growth and Development of Lymphoid Organs and Tissues in Deshi Chicken (*Gallus domesticus*) of Bangladesh. Agricultural Science Digest. 40(1): 69-76.

Submitted: 16-05-2019 **Accepted:** 02-08-2019 **Published:** 06-03-2020

study was conducted to explore the effect of farming conditions on the postnatal growth and development of lymphoid organs and tissues in deshi chickens of Bangladesh.

MATERIALS AND METHODS

Rearing of chicken

A total of 40 day-old non-descriptive deshi chicks were collected and categorized into two groups of 20 each. Subsequently, the chicks were reared in both scavenging (traditional or free range system) and intensive farming system up to 180 days in Chittagong district (sub-division) of Bangladesh according to Banerjee (1978).

Collection of lymphoid organs and tissues

The chickens were routinely collected at D_1 (day-1), D_{30}, D_{90} and D_{180} and then sacrificed by 'halal' method. After separation of lymphoid organs and tissues (bursa of Fabricius, thymus, spleen and cecal tonsil), samples were washed with normal saline solution.

Morphometry

Color and shape of lymphoid organs and tissues were recorded after collection. Weights of individual lymphoid organs and tissues were measured in grams (g) by using a sensitive electronic balance (Mettler Toledo B154, ± 0.001 g, China). The height of bursa of Fabricius; length of thymus, spleen and cecal tonsils and the width of bursa of Fabricius, spleen and cecal tonsils were measured in centimeter (cm) using slide calipers (0-150 digital caliper, Shinko Denshi Co. Ltd, Japan) and calibrated scales.

Tissue processing

For histological study, sections of the tissue samples were fixed in 10% neutral buffered formalin for a period of 72 hours followed by processing and staining with H and E stain according to Gridley (1957).

Histomorphometry

For obtaining histomorphometric data, fivephotomicrographs were taken from each age group of lymphoid organs and tissues of both SDC and CDC by using a photomicroscope (AmScope Trinocular Compound Microscope, Model T490 B-MT). AmScope image measuring software (x86, 3.7.3036 version) was used for measuring the actual length, height and width of respected lymphoid organs and tissues and was expressed in micrometer (µm).

Data analysis

The recorded data in excel sheet (Microsoft Excel-2007) were transferred to statistical software, STATA-13 (STATA Corp., Texas, USA) and unpaired sample t-test was done to compare means of different variables between two chicken groups (SDC and CDC). A p-value of equal to or less than 0.05 ($P \leq 0.05$) was considered as significant for this test and results were expressed as Mean ± SD.

RESULTS AND DISCUSSION

Morphometry

Bursa of Fabricius

In the present study, the mean weight, height and width of bursa in both SDC and CDC gradually increased from D_1 to D_{90} and the highest mean values of those parameters (2.04 ± 0.11 g, 1.48 ± 0.08 cm and 1.04 ± 0.11 cm, respectively) were found at 90 days old CDC (Fig 1). The respective values for highest weight, height and width of bursa were 3.0 g, 3.0 cm and 2.0 cm, in 120-150 days-old Hybrid chicken (Getty, 1975), 1.95 g, 0.6 cm and 0.31cm, in 70-80 days-old Broiler chicken (Khenenou *et al.,* 2012) and 3.8 g, 5.0 cm and 0.7 cm, in 180 days-old Duck (Sultana *et al.,* 2012). It was also found that the mean weight, height and width of this organ were significantly($P \leq 0.05$) higher in all ages of CDC except day-old (D_1) chicks as compared with SDC (Fig 1). This higher weight, height and width of bursa in CDC may be due to their higher growth rate in the intensive farming system as compared with SDC in the free range scavenging system. Jain *et al.* (2010) pointed out that the size and shape of bursa depend on the species, breed and even farming

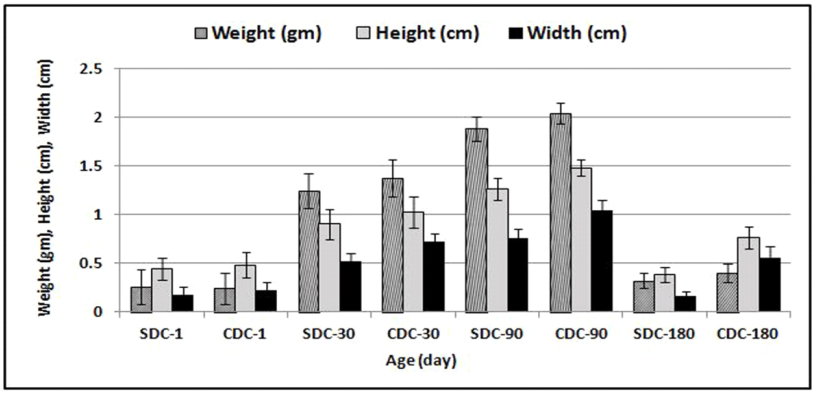

Fig 1: The present graph is showing the weight, height and width of bursa of Fabricius in different ages of scavenging deshi chicken (SDC) and captive deshi chicken (CDC). The growth of the bursa is found higher at D_{90} in both SDC and CDC; N=40 (n=5) and each bar represent Mean ± SD.

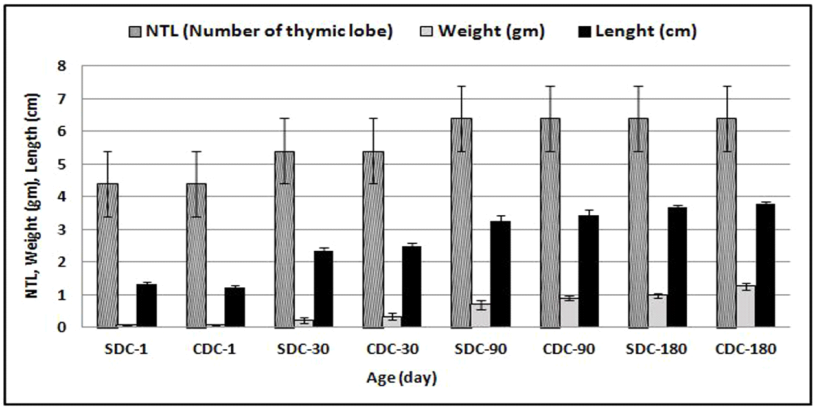

Fig 2: The present graph is showing the number of thymic lobe, weight and length of thymus in different ages of scavenging deshi chicken (SDC) and captive deshi chicken (CDC). The growth of the thymus is found higher at D_{180} in both SDC and CDC; N=40 (n=5) and each bar represent Mean ± SD.

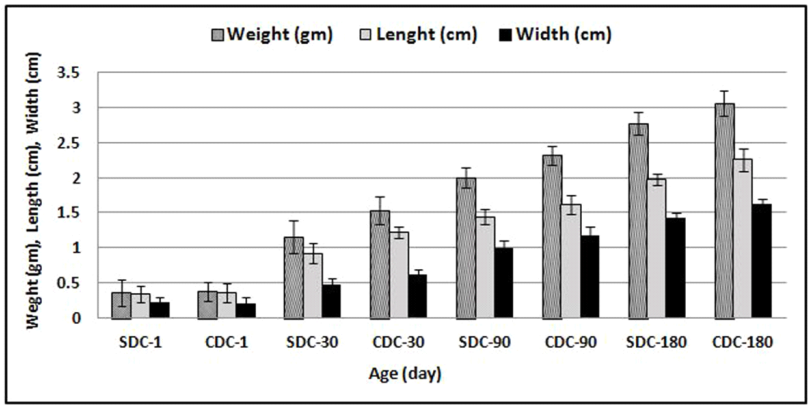

Fig 3: The present graph is showing the weight, length and width of spleen in different ages of SDC) and CDC. The growth of the spleen is found higher at D_{180} in both SDC and CDC; N=40 (n=5) and each bar represent Mean ± SD.

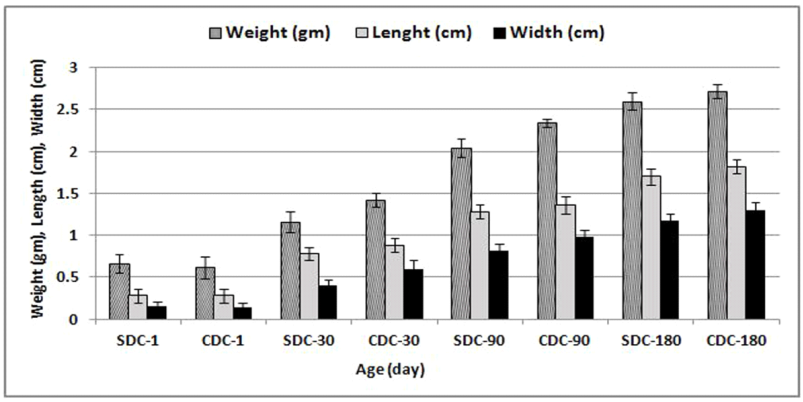

Fig 4: This graph is showing the weight, length and width of cecal tonsil in different ages of SDC and CDC. The growth of the cecal tonsil is found higher at D_{180} in both SDC and CDC; N=40 (n=5) and each bar represent Mean ± SD.

conditions of the birds. In D_1 chicks, the parameters of bursa of both CDC and SDC were analogous owing to their relatively equal body weights in both the farming conditions. The mean weight, height and width of bursa decreased at D_{180} in both SDC and CDC, indicating the involution of this organ by that age. Involution of bursa started by D_{140} in Broiler chicken (Khenenou *et al.,* 2012), >150 days in White Leghorn chicken and >180 days in Duck (Getty, 1975). Hence, in the present study, the size and involution of bursa in both SDC and CDC varied according to the species and breed.

Thymus

Data in Fig 2 showed that the morphometric parameters of thymus *viz.* number of lobes, weight and length increased significantly ($P \leq 0.05$) with advancement of age from D_1 to D_{180} in both SDC and CDC. These results partially differed

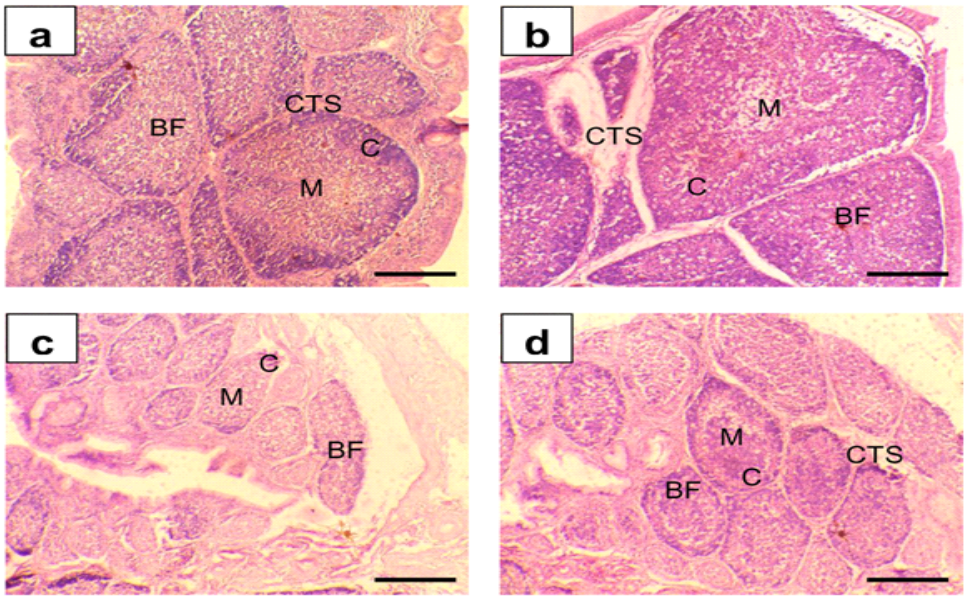

Fig 5: Histological structure of 90 days (a, b) and 180 days (c, d) old bursa of Fabricius in both SDC (left column) and CDC (right column) in H and E staining showing cortex (C), medulla (M), mucosal fold (MF), bursal follicle (BF), epithelium (E) and connective tissue septum (CTS); Scale Bar 180 µm.

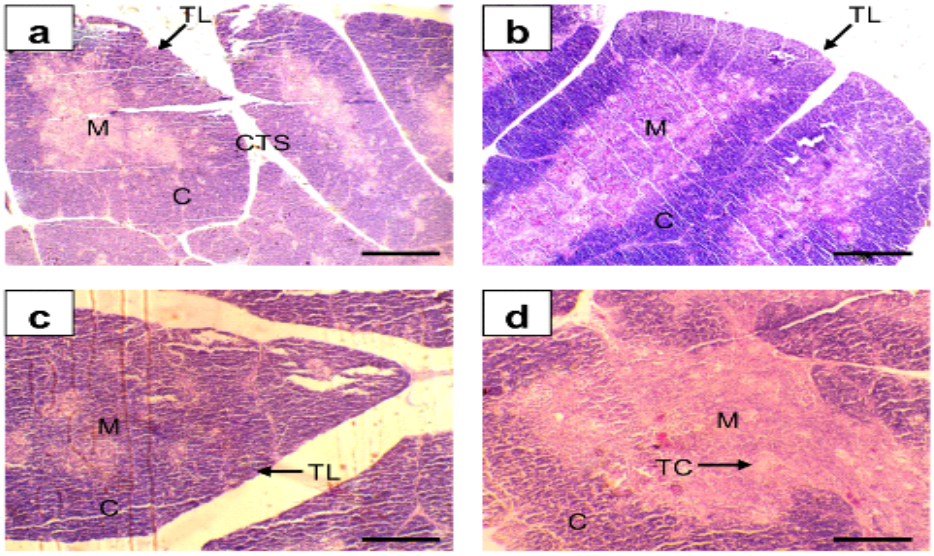

Fig 6: Histological structure of 90 days (a, b) and 180 days (c, d) old thymus in both SDC (left column) and CDC (right column) in H and E staining showing cortex (C), medulla (M), thymic lobule (TL), thymic corpuscle (TC), connective tissue septum (CTS); Scale Bar 180 µm.

from the reports of Getty (1975) who observed that the number of lobes, weight and length of thymus in White Leghorn chickens increased up to D_{120}. This dissimilarity may be due to the breed difference. In both SDC and CDC, the number of lobes in thymus varied according to age, with no difference in the same age. Average mean number of thymic lobes on each side of neck was 4.40 to 6.40 in both SDC and CDC, which partially agreed with previous reports of 3-8 on each side of neck in Domestic fowl (Hodges, 1974; King and McLelland, 1984), 6-7 in Guinea fowl (Onyeanusi *et al.,* 1994) and 5-9 in Geese (Gulmez and Aslan, 1999). This partial discrepancy may be due to the variation in species. Contrarily, the mean weight and length of thymus were significantly ($P \leq 0.05$) higher in all age groups except day-old chicks of CDC as compared with SDC. This inconsistency with the advancement of age may be attributed to their rearing environment. Comparatively similar weight and length of thymus was found at D_1 chicks in both SDC and CDC as their body weights were relatively equal in both scavenging and intensive farming conditions.

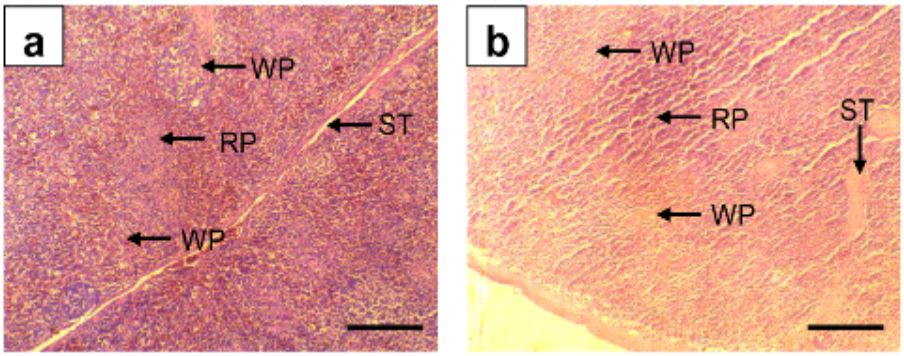

Fig 7: Histological structure of 180 days old spleen in both SDC (a) and CDC (b) in H and E staining showing white pulp (WP), red pulp (RP), splenic capsule (SC), splenic trabeculae (ST); Scale Bar 180 µm.

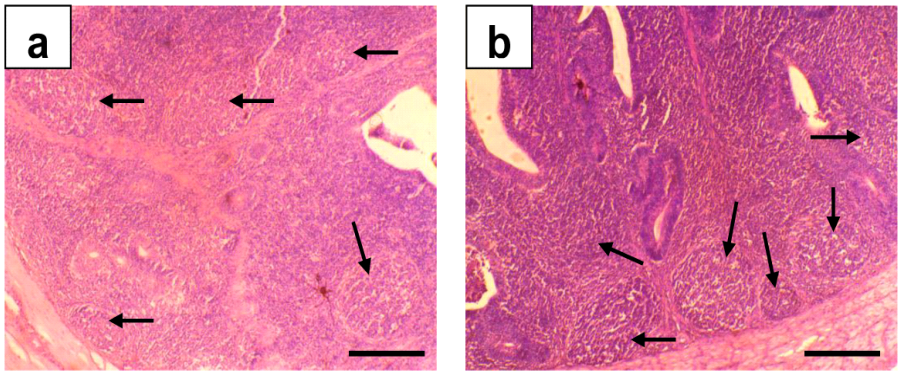

Fig 8: Histological structure of 180 days old cecal tonsil in both SDC (a) and CDC (b) in H and E staining where arrow headed area indicates lymphatic nodule; Scale Bar 180 µm.

Spleen and Cecal Tonsil

The mean weight, length and width of spleen (Fig 3) and cecal tonsil (Fig 4) in both SDC and CDC also increased from D_1 to D_{180} in accordance with the reports of Getty (1975), who described that the weight, length and width of spleen and cecal tonsil in White Leghorn chicken also increased with the advancement of age. In the present study, the mean weight, length and width of spleen and cecal tonsil were significantly ($P \leq 0.05$) higher in all age groups (except D_1 chicks) in CDC as compared with SDC. The CDC was reared in intensive farming condition where ad-libitum feed and water were supplied thus, their growth rates were higher than SDC. For this reason the mean weight, length and width of spleen and cecal tonsil were higher in CDC than that of SDC. Ciriaco *et al.* (2003) reported that the mean weight, length and width of lymphoid organs of Hybrid chickens depend on the farming condition as well as their weight gain. In day-old (D_1) chicks of both SDC and CDC, the mean weight, length and width of spleen and cecal tonsils were relatively similar as their relatively equal body weights in both scavenging and intensive farming conditions. On the other hand, maximum mean values of weight, length and width of spleen (3.06 ± 0.18 g, 2.26 ± 0.16 cm and 1.62 ± 0.08 cm, respectively) were found at 180 days-old CDC. Previously reported respective highest mean weight, length and width were 3.0-4.5 g, 2.0-3.0 cm and 1.0-2.0 cm, in 120-150 days-old Hybrid chicken (Getty, 1975), 1.974 ± 0.04 g, 18.93 ± 0.39 mm and 13.45 ± 0.34 mm, in 28 days-old Broiler chicken in Bangladesh (Khan *et al.,* 2014) and 0.18 g, 0.94 cm and 0.68 cm, in 90-120 days-old indigenous Duckling in Bangladesh (Sultana *et al.,* 2012). This dissimilarity may be due to the difference in species, breed and age as reported by Jain *et al.* (2010) who noticed that the color, weight, length and width of lymphoid organs of Hybrid chicken depended on the breed, age, sex and rearing environment.

Histomorphometry

Bursa of Fabricius

The comparative histomorphometrical data of bursa of Fabricius are shown in Table 1. The number of mucosal folds in the present study varied from 6-12 (Fig 5), whereas the number of mucosal folds was 12 in Domestic fowl (King and McLelland, 1984), 12-14 in Helmeted Guinea fowl (Onyeanusi *et al.,* 1993), 11-13 in Geese (Gulmez and Aslan, 1999), 8-16 in both CARI Shyama and Vanaraja breeds of poultry (Jain *et al.,* 2010) and 11-13 in Hybrid chicken (Betti *et al.,* 1991). The mucosal folds of the bursa was covered by pseudostratified columnar epithelium except at the apex where it was covered by simple columnar epithelium (Fig 5). Some authors have reported that the surfaces of mucosal folds were covered by pseudostratified columnar epithelium

Table 1: Histomorphometrical observations of bursa of fabricius.

Age group (Day)	Parameter (µm)	Chickens group (Mean ± SD) SDC	CDC	P-value
D_1	HE	29.00 ± 5.47	30.00 ± 3.54	0.74
	NMF	7.00 ± 0.71	6.80 ± 0.84	0.69
	NFPMF	14.00 ± 3.16	14.20 ± 2.86	0.91
	HMF	468.00 ± 105.21	471.60 ± 103.49	0.95
D_{30}	HE	43.40 ± 5.94	51.50 ± 3.71	0.03*
	NMF	7.80 ± 1.30	8.80 ± 1.30	0.02*
	NFPMF	26.80 ± 7.01	30.20 ± 6.14	0.03*
	HMF	481.00 ± 144.59	879.80 ± 152.04	0.01*
D_{90}	HE	57.4 ± 5.59	68.60 ± 4.93	0.01*
	NMF	10.80 ± 1.30	12.00 ± 1.58	0.002*
	NFPMF	59.80 ± 7.56	63.40 ± 7.70	0.05*
	HMF	1017.00 ± 134.82	1076.40 ± 154.74	0.03*
D_{180}	HE	40.80 ± 3.19	47.00 ± 5.43	0.05*
	NMF	7.20 ± 1.30	8.20 ± 1.30	0.009*
	NFPMF	24.00 ± 3.16	26.80 ± 3.19	0.04*
	HMF	560.80 ± 102.53	608.40 ± 103.97	0.02*

Here, N= 40 (n= 5 for each age group); HE= Height of epithelium; NMF= Number of mucosal fold; NFPMF= Number of follicles per mucosal fold; HMF= Height of mucosal fold; *Significant when $P \leq 0.05$.

Table 2: Histomorphometrical observations of thymus, spleen and cecal tonsil.

Lymphoid organ	Parameter	Age group (Day)	Chickens group (Mean ± SD) SDC	CDC	P-value
Thymus	LTL (µm)	D_1	265.40 ± 45.75	269.00 ± 39.93	0.89
		D_{30}	547.60 ± 90.56	583.20 ± 102.31	0.05*
		D_{90}	881.00 ± 153.22	913.40 ± 144.00	0.04*
		D_{180}	985.80 ± 28.19	1001.20 ± 28.96	0.01*
	WTL (µm)	D_1	152.00 ± 22.89	152.80 ± 22.19	0.95
		D_{30}	285.60 ± 63.05	328.80 ± 58.78	0.02*
		D_{90}	510.80 ± 174.78	539.20 ± 188.69	0.05*
		D_{180}	566.60 ± 86.39	608.80 ± 85.40	0.015*
Spleen	LWP (µm)	D_1	69.20 ± 6.26	69.60 ± 7.40	0.92
		D_{30}	209.00 ± 39.99	229.40 ± 47.04	0.04*
		D_{90}	279.80 ± 69.02	310.60 ± 82.42	0.05*
		D_{180}	362.20 ± 19.43	399.80 ± 17.17	0.007*
	WWP (µm)	D_1	32.40 ± 5.22	32.60 ± 5.89	0.95
		D_{30}	81.00 ± 10.75	88.20 ± 11.61	0.02*
		D_{90}	140.60 ± 28.51	151.20 ± 31.36	0.05*
		D_{180}	167.20 ± 19.09	190.40 ± 10.53	0.05*
Cecal tonsil	LLN (µm)	D_1	26.60 ± 4.04	27.20 ± 3.89	0.81
		D_{30}	53.40 ± 7.57	61.80 ± 8.26	0.01*
		D_{90}	129.40 ± 22.09	142.80 ± 24.65	0.03*
		D_{180}	164.20 ± 16.02	180.20 ± 13.44	0.01*
	WLN (µm)	D_1	19.40 ± 5.18	19.40 ± 5.03	1.00
		D_{30}	38.60 ± 6.58	49.40 ± 8.14	0.05*
		D_{90}	92.40 ± 16.46	103.80 ± 19.58	0.03*
		D_{180}	107.20 ± 15.55	120.40 ± 18.51	0.05*

Here, N= 40 (n= 5 for each age group); LTL= Length of thymic lobe; WTL= Width of thymic lobe; LWP= Length of white pulp; WWP= Width of white pulp; LLN= Length of lymph nodule; WLN= Width of lymph nodule; *Significant when $P \leq 0.05$.

(Hodges, 1974; Onyeanusi *et al.,* 1994) but the others have reported, they were covered by both simple columnar and pseudostratified columnar epithelium (Jain *et al.,* 2010). Jain *et al.* (2010) found that the respective highest mean value for height of epithelium in CARI Shyama and Vanaraja breeds of poultry were 54.24 ± 1.76 µm, 42.56 ± 2.40 µm; with the height of mucosal folds being 2200± 40.60 µm, 2280 ± 45.00 µm and the number of follicles per fold being 25.14 ± 0.05, 18.98 ± 2.34. These observations indicated that the number of mucosal folds, number of follicles per fold, height of mucosal folds and covering epithelium of bursa varied within breed and species. In this study, the height of epithelium, number of mucosal folds, number of follicles per mucosal folds and height of mucosal folds increased with advancement of age from D_1 to D_{90} in both SDC and CDC but decreased by D_{180} in both SDC and CDC (Fig 5). These histomorphometrical results indicated involution of bursa by D_{180} in both SDC and CDC. In contrast, all those histomorphometrical parameters of bursa were higher in all age groups in CDC as compared with SDC. The possible causes of these higher results in CDC may be due to their higher growth rate in intensive farming system as compared with SDC in free range scavenging system with expected involvement of other factors also. Kannan *et al.* (2012) found that the histological structure of lymphoid organs in Hybrid chicken depended on the breed, age, sex and their rearing environment. In day-old (D_1) chicks of both SDC and CDC groups, the mean values of all histomorphometrical parameters of bursa were relatively similar owing to their relatively equal body weights in both scavenging and intensive farming conditions.

Thymus, Spleen and Cecal tonsil

Data in Table 2 showed that the mean length and width of thymic lobules (Fig 6), white pulps of spleen (Fig 7) and lymphatic nodules of cecal tonsil (Fig 8) in both SDC and CDC increased with the advancement of age from D_1 to D_{180}. Similar findings were also noticed in Broiler chicken by Akter *et al.* (2006) and Khan *et al.* (2014) and in Aseel chicken by Haseeb *et al.* (2014). On the other hand, the mean length and width of lobules of thymus, white pulps of spleen and lymphatic nodules of cecal tonsils were higher in all age groups in CDC as compared with SDC. The body weights of CDC were higher being reared in intensive farming conditions with *ad-libitum* feed and water. In contrast, the SDC being reared in free range scavenging system and feeding on kitchen waste, seeds and grains, insects, green grasses had a comparatively slower body weight gain than CDC. So, the parameters of these lymphoid organs, *viz.* length and width of lobules of thymus, white pulps of spleen and lymphatic nodules of cecal tonsils exhibited corresponding higher values in all age groups in CDC. As per the earlier reports, histological structure of lymphoid organs and tissues in Hybrid chicken varied according to the breed, age, sex and rearing environment (Jain *et al.,* 2010; Kannan *et al.,* 2012).

CONCLUSION

The higher gross and histomorphometrical parameters of lymphoid organs and tissues in CDC over that of SDC in the present study may be attributed to their different pattern of rearing system. It indicated that the level of immunity might be better in CDC over that of SDC associated with an advancement of age. Moreover, as indicated by the improved growth rate of deshi chickens in the present study, captive or intensive system is recommended over the scavenging system of rearing.

ACKNOWLEDGEMENT

The authors are grateful to National Science Technology (NST) and Committee for Advanced Studies and Research (CASR), CVASU, Bangladesh for sanctioning research grants to complete this work.

REFERENCES

Akter, S., Khan, M., Jahan, M., Karim, M., Islam, M. (2006). Histomorphological study of the lymphoid tissues of broiler chickens. Bangl. J. Vet. Med. 4(2): 87-92.

Banerjee, G.C. (1978). A textbook of animal husbandry. New Delhi, India: Oxford and IBH Publishing.

Betti, F., Worsmann, T., De Faria, F., Sesso, A. (1991). Development of the cloacal bursa in the domestic fowl. II. A quantitative and fine structural analysis of the follicular cortex and medulla. J. Submicrosc. Cytol. Pathol. 23(4): 613-628.

Ciriaco, E., Pinera, P.P., Diaz Esnal, B., Laura, R. (2003). Age related changes in the avian primary lymphoid organs (thymus and bursa of Fabricius). Microsc. Res. Tech. 62 (6): 482-487.

Del Moral, M.G., Fonfria, J., Varas, A., Jimenez, E., Moreno, J., Zapata, A. (1998). Appearance and development of lymphoid cells in the chicken (*Gallus gallus domesticus*) caecal tonsil. Anat. Rec. 250(2): 182-189.

Dutta, R.K., Islam, M.S., Kabir, M.A. (2013). Production performance of indigenous chicken (*Gallus domesticus* L.) in some selected areas of Rajshahi, Bangladesh. American J. Experi. Agric. 3(2): 308-323.

Ershad, S. (2005). Performance of hybrid layers and native hens under farmers' management in a selected area of Bangladesh. Int. J. Poult. Sci. 4(4): 228-232.

Getty, R. (1975). Sisson and Grossman's The anatomy of the domestic animals. Vol. 2, 5th ed. W.B. Saunders Company, London.

Gridley, M.F. (1957). Manual of histologic and special staining technics. McGraw Hill Book Company, Inc., New York.

Gulmez, N., Aslan, S. (1999). Histological and histometrical investigations on bursa of Fabricius and Thymus of Native Geese. Turk. J. Vet. Anim. Sci. 23(2): 163-172.

Haseeb, A., Shah, M.G., Gandahi, J.A., Lochi, G.M., Khan, M., Faisal, M. (2014). Histo-morphological Study on Thymus of Aseel chicken. J. Agric. Food. Tech. 4(2): 1-5.

Hodges, R.D. (1974). The histology of the fowl. Academic Press, New York.

Islam, M.N., Khan, M.Z.I., Jahan, M., Fujinaga, R., Yanai, A., Kokubu, K., Shinoda, K. (2012). Histomorphological study

on prenatal development of the lymphoid organs of native chickens of Bangladesh. Pak. Vet. J. 32(32): 175-178.

Jain, P., Ingole, S., Dang, U. (2010). Gross and histological studies on bursa of Fabricius of CARI Shyama and Vanaraja breeds of poultry. Haryana Vet. 49(1): 51-53.

Kannan, T., Geetha, R., Ushakumary, S., Raj, G., Vairamuthu, S. (2012). Light microscopic studies on spleen of chicken (*Gallus domesticus*). Haryana Vet. 51(1): 114-115.

Khalil, M., Islam, Z., Khalil, M., Islam, R. (2002). Effects of age in the structure of the bursa of Fabricius of deshi chicken of Bangladesh. Mymensingh Med. J. 11(2): 91.

Khan, M.Z.I., Masum, M., Khan, M.Z.I., Aziz, A.R., Nasrin, M.,Siddique, M.N.H. (2014). Histomorphology of the lymphoid tissues of broiler chickens in Kelantan, Malaysia (Histomorfologi Tisu Limfa Ayam Pedaging di Kelantan, Malaysia). Sains Malays. 43(8): 1175-1179.

Khenenou, T., Melizi, M., Benzaoui, H. (2012). Morpho-histological study of the Bursa of Fabricius of broiler chickens during post-hashing age. In, Proceedings of World Academy of Science, Engineering and Technology.

King, A.S., McLelland. J. (1984). Birds, their structure and function. 2nd ed. Bailliere Tindall, 1 St. Annes Road, UK.

Kozuka, Y., Nasu, T., Murakami, T., Yasuda, M. (2010). Comparative studies on the secondary lymphoid tissue areas in the chicken bursa of Fabricius and calf ileal Peyer's patch. Vet. Immunol. Immunopathol. 133 (2): 190-197.

Nagy, N.. Olah, I. (2010). Experimental evidence for the ectodermal origin of the epithelial anlage of the chicken bursa of Fabricius. Development. 137(18): 3019-3023.

Onyeanusi, B., Onyeanusi, J., Emma, A., Ezeokoli, C. (1994). The thymus of the guinea fowl from the eighteenth day of incubation until maturity. Anat. Histol. Embryol. 23 (4): 320-329.

Rahman, M., Islam, M., Asaduzzaman, M., Khan, M. (2003). Lymphoid tissues in the digestive tract of Deshi Chicken (*Gallus domesticus*) in Bangladesh. Pak. J. Biol. Sci. 6 (13): 1145-1150.

Sultana, N., Khan, M., Wares, M., Masum, M. (2012). Histomorphological study of the major lymphoid tissues in indigenous ducklings of Bangladesh. Bangl. J. Vet. Med. 9(1): 53-58.

Tizard, I. R. (2013). Veterinary Immunology. E-Book. 9th ed. Elsevier Health Sciences.