RESEARCH ARTICLE Agricultural Scinece Digest, Volume 39 Issue 4: 353-356 (October-December 2019)

Case of Vaccine-Associated Fibrosarcoma (VAS), Related to Aluminium, in a Cat

Fulya Altinok-Yipel[1], Nuri Altug[1] and Sevda Inan[2]

10.18805/ag.D-174

Abstract

An 11-year-old, male, crossbreed cat was presented for a subcutaneous mass affecting the prescapular region extending to the thoracic vertebrae. The diagnosis of fibrosarcoma was made according to the histopathological examination of the biopsy. Scanning electron microscopy (SEM-EDX) was used to determine the presence of aluminium in the tumor tissue. The owner did not accept further treatment, so the cat died 1 month after diagnosis. This is the first case report from Turkey which diagnoses verified by SEM and has shown that aluminium-containing vaccines may be associated with fibrosarcoma formation. Awareness of the side effects of adjuvants is still not enough level. Determining the frequency of VAS in fibrosarcoma cases will contribute to the increase of life span/ survival by protective measures. The aim of this case report is to draw attention to the adjuvant contents of the vaccines and to scrutinize the relationship between vaccine applications and tumor development.

Key words: Adjuvant, Aluminium, Cat, Fibrosarcoma, SEM, Vaccine.

Introduction

Feline vaccine-associated sarcomas (VAS) has been describe in cats in 1991 (Martano *et al*., 2011). VAS occurs after the administration of vaccines within 4 months to 3 years (Hendrick *et al*., 1994; Hartmann *et al*., 2015). Fibrosarcomas are common sarcomas seen dermis and subcutis of the trunk and extremities of adult and senior cats and there is no breed predisposition or sex prevalence (Moulton, 1990, Hartmann *et al*., 2015).

The fundamental mechanism of these sarcomas is still not clear, but a response to chronic, inflammatory reactions after the administration of vaccines is considered to lead to uncontrolled proliferation of fibroblasts and myofibroblasts (Seguin, 2002; Hartmann *et al*., 2015). This inflammation represents a response to adjuvant material in the vaccines. Factors related to the adjuvant contents of the vaccines and subcutaneous administration contribute to the development of sarcomas in cats (Hendrick, 1999; Kass *et al*., 2003; Hendricks *et al*., 2014). Adjuvants are used to enhance the immune response of a vaccination (Hogenesch, 2012). Aluminium compounds containing adjuvants are especially widely used in cat vaccines (Hendrick, *et al*., 1992).

This case report aims to draw attention to the adjuvant contents of the vaccines and to clarify the relationship between VAS developments.

Materials and Mathods

An 11-year-old, neutered male, crossbreed cat was presented, presenting an approximately 8 cm diameter hard lobe mass in the interscapular region (Fig 1A). The owner reported that a triple combined and a rabies vaccines had been administered about 5 months prior to this appointment as regularly once a year for 11 years. A small diameter mass development was observed in the vaccination site about 3 months. Treatment was not immediately attempted, and the mass continued to grow rapidly. The vital findings were within normal ranges in the clinical examination of the patient. The results of biochemical and hematological tests were unremarkable.

[1]Department of Internal Medicine, Faculty of Veterinary Medicine, Tekirdağ Namık Kemal Univ., 59030, Tekirdağ, Turkey.
[2]Department of Pathology, Faculty of Veterinary Medicine, Tekirdağ Namık Kemal Univ., 59030, Tekirdağ, Turkey.

Corresponding Author: Fulya Altinok-Yipel, Department of Internal Medicine, Faculty of Veterinary Medicine, Tekirdağ Namık Kemal Univ., 59030, Tekirdağ, Turkey. e-mail: fulyip@hotmail.com

How to cite this article: F.A. Yipel, N. Altug and S. INAN (2019). Case of Vaccine-Associated Fibrosarcoma (VAS), Related to Aluminium, in a Cat. Agricultural Science Digest, 39(4): 353-356.

Source of support: Nil

Conflict of interest: Authors declare no conflict of interest.

Submitted: 03-07-2019 **Accepted:** 27-08-2019 **Published:** 09-12-2019

For histopathological examination, biopsy samples were surgically excised (Fig 1B). Biopsy materials and necrotic haemorrhagic transudate from the tumoral tissue were sent to the Tekirdağ Namık Kemal University, Faculty of Veterinary Medicine, Pathology Department. The cytological slides from the neoplastic tissues and transudate were stained with Diff Quick stain. Then, tissues were fixed in a 10% buffered formaldehyde solution for the routine histopathological process. The fixed tumoral tissues were trimmed, embedded in paraffin and cut at a thickness of approximately 5µm. The slides were stained with haematoxylin and eosin (H&E) and were examined at a magnification of × 40, under the light microscope.

Thoracic radiography and abdominal ultrasonography were performed. On radiographic images, it was seen that the mass extended to the thoracic vertebrae (Fig 2A) and revealed no metastasis (Fig 2B).

Scanning electron microscope (SEM) images and EDXs were created to determine the presence of aluminium. Aluminium analysis was performed with X-Ray Analyser Energy Dispersive Automatic Scanning Electron Microscopes. The presence of aluminium was determined by x-ray energies at 1.5 keV. (Figs 3A, 3B, 3C and 3D).

Macroscopically, the biopsy materials were variable in size, ranging from 0.3-0.5 cm; showed irregular shapes; and were non-encapsulated, with firm consistency. The transudates from the tumoral tissue were necrotic and haemorrhagic. The cut surface of the tumoral tissues was ulcerated, lobulated, and homogeneous; the tissues were reddish-white colored and had haemorrhagic mucinous transudate. Impression smears revealed atypical, large, multinucleated cells, tumoral giant cells, and atypical fusiform-ovoid cells, and mitotic Figs were seen around the dense erythrocytes (Figs 4A, and 4B). Histopathological examination of the haematoxylin-eosin (H&E) stained slides displayed pleomorphic (mainly fusiform) cells with indistinct cell borders, showing diffuse growth patterns. The tumor cells had elongated hyperchromatic nuclei, oval nuclei, and dispersed chromatin. The mitotic Fig per 10 high power fields was seen moderately. Haemorrhagic areas were observed between pleomorphic cells. The tumoral cells were invaded subepidermal muscle tissue (Fig 4C). All the histopathological evidence pointed to a fibrosarcoma.

According to recommended treatment for VAS, the tumor needed to be removed with radical surgery. The resection would need to be at least 5 cm, and the surgery would be followed by radiotherapy and/or immunotherapy. However, the recurrence rate might still be up to 50-70% (Hartmann *et al*., 2015).

In this case, surgical removal of the mass and chemotherapy was suggested, but the treatment was refused by the owner.

The case was defined as *VAS* according to the anamnesis of the mass formation after vaccination, the presence of aluminium, the clinical findings, and the pathologic evaluation. The tumor grew rapidly, as observed at appointments 10 and 20 days after the initial screening (Figs5A and 5B). The cat died 1 month after diagnosis.

Results and Discussion

Feline vaccine-associated *sarcomas* occur commonly in adult and aged cats (mean 12 years) (Moulton, 1990).In one study, VAS was reported to develop in younger cats (mean 8 years) at a higher rate than non-vaccine-associated sarcomas (Doddy *et al*., 1996). However, in a study conducted in the following years, which revealed no decrease in feline postvaccinal sarcoma prevalence from 1992 to 2010, despite changes in feline vaccination protocols, there was no decrease in the average age of affected cats (Wilcock *et al.,* 2012). In this case, the cat was 11 years old, and the case was, in its details, also similar to the previous reports (Moulton, 1990; Wilcock *et al*., 2012).

Aluminium is thought to be responsible for the development of VAS, according to some studies (Hendrick *et al*., 1992; Madewell *et al*., 2001; Day *et al*., 2007). Hendrik *et al*. (1992) has been proved the presence of aluminium in some sarcomas. However, complicating this hypothesis, subsequent studies reported that aluminium-containing vaccine administration did not increase the risk of cats developing tumors, relative to aluminium-free vaccines

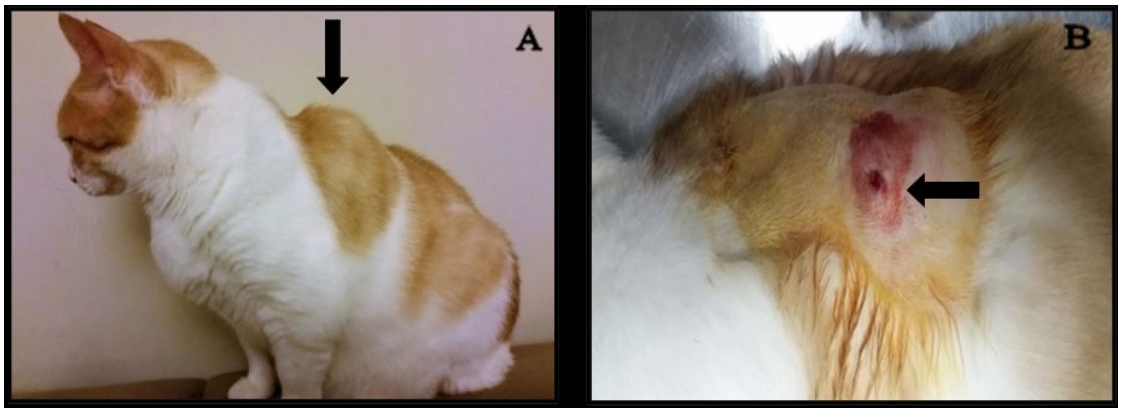

Fig 1(A): Hard lobe mass in the interscapular region, (B) Biopsy area view.

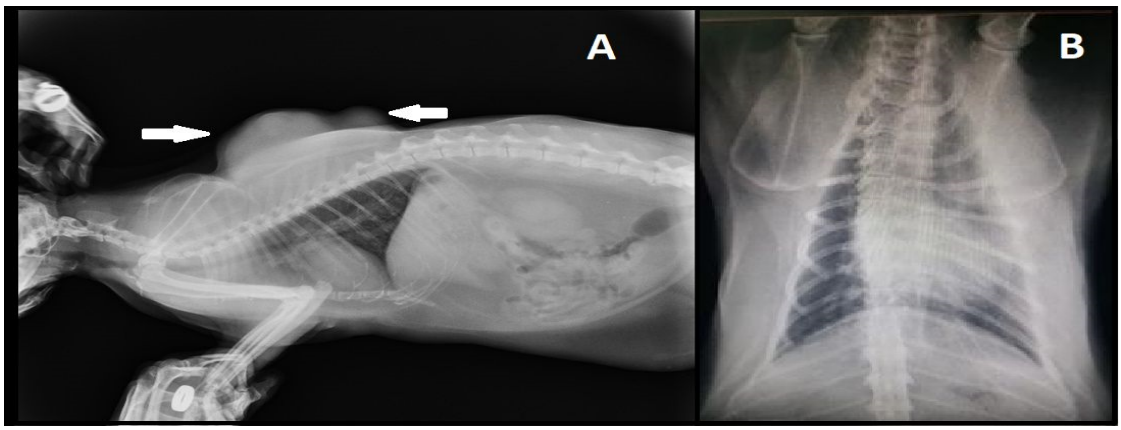

Fig 2(A): Radiographic image of the tumor, **(B)** Ventro- dorsal thoracic radiography views of cat.

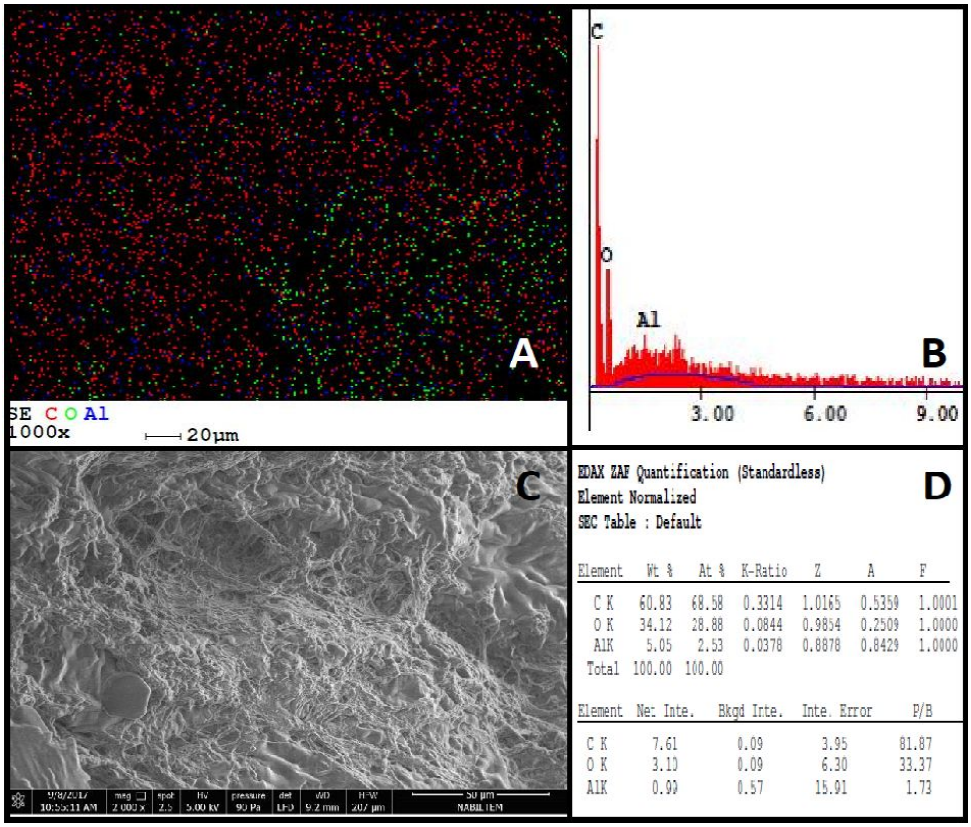

Fig 3(A) and **(B):** The distribution maps was shown that prensence and intensity of Aluminium on fibrosarcoma tissue according the energy level of the X-rays over the scanned area, **(C)** Scanning electron microscope (SEM) image of fibrosarcoma tissue, **(D)** Energy Dispersive X-Ray Analysis EDX analysis result (%) of Aluminium.

(Hendrick *et al*., 1994). Nonetheless, in the following years, Day *et al*. (2007) revealed that non-adjuvanted vaccines cause less tissue inflammation than adjuvanted (aluminium-based) vaccines. In this case report, aluminium presence was detected in the fibrosarcoma tissue. This evidence confirms the association of fibrosarcoma with aluminium-containing vaccinations, contributing to this ongoing discussion. Further study will elucidate this development mechanism.

Overall, some studies have shown the significance of the existence of aluminium in tumor tissue (Hendrick *et al*., 1992; Madewell *et al*. 2001).The results of the case study here, according to the SEM-EDX analysis, support the association between aluminium and feline vaccine-associated sarcomas. These results reflect the first relevant case that has been put forward by this analysis method in Turkey according to literature.

When a vaccination is administered in the interscapular region, the vaccinated cat's risk of VAS increases by 50% compared with non-vaccinated cats. More than one vaccination to the same site increases this risk, from 127%, during a second administration, to 175%, at a fourth vaccination administration (Saba, 2017).In the present study case, the adjuvant vaccination was applied to the interscapular area; the mixed and rabies vaccines were applied to the same area.

Tumor development duration ranges from 2 months to 15 years after vaccine administration (Wilcock *et al*., 2012;

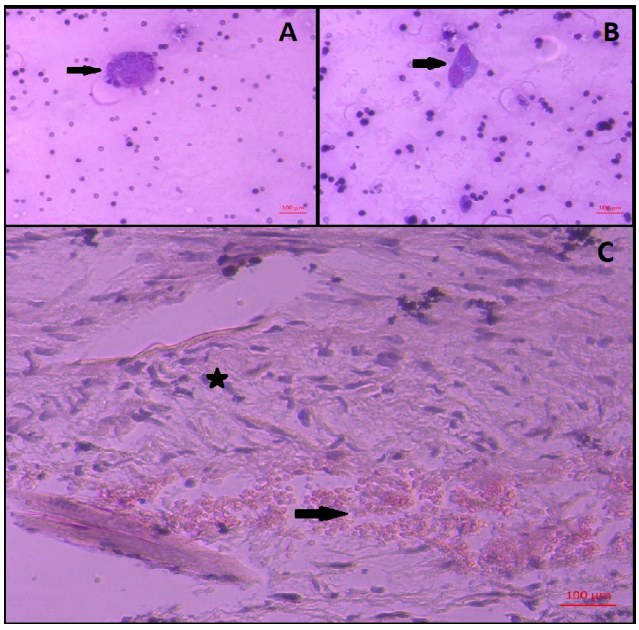

Fig 4: (A) and **(B)** Giant cell (arrow), multi- nucleated cell (thick arrow) were seen from microscopic images of cytological slides of subcutaneous tumoral tissue and transudate. Diff-Quick staining, respectively, Bar: 100 µm, **(C)** Histopathological appearance of the fibrosarcoma indicated that anaplastic tumoral cells (star) and hemorragic areas (arrow) were seen. H &E; Bar: 100 µm.

Saba, 2017). The cat in this case developed a fibrosarcoma about 3 months after the vaccination. VAS often metastasizes to the lungs and regional lymph nodes, as seen in 10-25% of affected cats. Commonly used diagnosis methods for metastasis are based on the findings of radiography or tomography. (Cronin *et al*., 1998; Hershey *et al*., 2000; Saba, 2017). In this cat, radiography revealed no evidence of metastasis.

Conclusion

There are still debates about vaccine application areas, due to the side effects caused by adjuvants (especially containing aluminium compounds). One recommended solution is to apply adjuvant-containing vaccines to different regions which may cause harmful side effects. However, awareness of the side effects of adjuvants is still not at a sufficient level.

The application of aluminium-containing vaccines may trigger the formation of fibrosarcoma. Therefore, unnecessary repetition of or, when possible, use of adjuvant-containing vaccines should be avoided. If an alternative product is not available, amputatable sites should be preferred for vaccine application. consequently, this case report supports the knowledge that adjuvant vaccines should be avoided. Also supported histopathology diagnosis of fibrosarcomas by SEM technique can better understanding of aetiology of VAS.

References

Cronin, K., Page, R.L., Spodnick, G., Dodge, R., Hardie, E.N., Price, G.S., Ruslander, D.,Thrall, D.E.(1998).Radiation therapy and surgery for fibrosarcoma in 33 cats. Journal Veterinary Radiology and Ultrasound., 39: 51–56.

Day, M.J., Schoon, H.A., Magnol, J.P., Saik, J., Devauchelle, P.,Truyen, U., Gruffdd-Jones, T.J., Cozette, V., Jas, D., Poulet, M., Pollmeier, M., Thibault, J.C. (2007). A kinetic study of histopathological changes in the subcutis of cats injected with non-adjuvanted and adjuvanted multi-component vaccines. Vaccine., 25: 4073-4084.

Doddy, F.D., Glickman, L.T., Glickman, N.W., Janovitz, E.B. (1996). Feline fibrosarcomas at vaccination sites and non-vaccination sites. Journal of Comparative Pathology, 114: 165–174.

Hartmann, K., Day, M.J., Thiry, E., Lloret, A., Frymus, T., Addie, D., Boucraut-Baralon, C., Egberink, H., Gruffydd-Jones, T., Horzinek, M.C., Hosie, M.J., Lutz, H., Marsilio, F., Pennisi, M.G., Radford, A.D., Truyen, U., Mostl, K. (2015). Feline injection-site sarcoma: ABCD guidelines on prevention and management. Journal of Feline Medicine and Surgery,17: 606-613.

Hendrick, M.J. (1999). Feline vaccineassociated sarcomas. Cancer Investigation, 17: 273-277.

Hendrick, M.J., Shofer, F.S., Goldschmidt, M.H., Haviland, J.C., Schelling, S.H., Engler, S.J., Gliatto, J.M. (1994). Comparison of fibrosarcomas that developed at vaccination sites and at nonvaccination sites in cats: 239 cases (1991–1992). Journal of the American Veterinary Medical Association, 205: 1425–1429.

Hendrick, M.J.,Goldschmidt, M.H., Shofer, F., Wang, Y.Y., Somlyo, A.P. (1992).Postvaccinal sarcomas in the cat: epidemiology and electron probe microanalytical identification of aluminium. Cancer Research, 52: 5391–5394.

Hendricks, C.G., Levy, J.K., Tucker, S.J., Olmstead, S.M., Crawford, P.C., Dubovi, E.J., Hanlon, C.A. (2014). Tail vaccination in cats: a pilot study. Journal of Feline Medicine and Surgery, 16: 275-280.

Hershey, A.E., Sorenmo, K.U., Hendrick, M.J., Shofer, F.S., Vail, D.M. (2000). Prognosis for presumed feline vaccine-associated sarcoma after excision: 61 cases (1986–1996). Journal of the American Veterinary Medical Association, 216: 58–61.

Hogenesch, H. (2012). Mechanism of immunopotentiation and safety of aluminium adjuvants. Frontiers in Immunology, 3: 406.

Kass, P.H., Spangler, W.L., Hendrick, M.J., Mcgill, L.D., Esplin, D.G., Lester, S., Slater, M., Meyer, E.K., Boucher, F., Peters, E.M., Gobar, G.G., Htoo, T., Decile, K. (2003). Multicenter case-control study of risk factors associated with development of vaccine-associated sarcomas in cats. Journal of the American Veterinary Medical Association, 223: 1283–1292.

Madewell, B.R., Griffey, S.M., Mcentee, M.C., Leppert, V.J., Munn, R.J. (2001). Feline vaccineassociated fibrosarcoma: an ultrastructural study of 20 tumors (1996–1999). Veterinary Pathology, 38: 196–202.

Martano, M., Morello, E., Buracco, P. (2011). Feline injection site sarcoma: past, present and future perspectives. Veterinary Journal, 188: 136-141.

Moulton, J.E. (1990). Tumors in Domestic Animals. 3th ed., University of California Press.

Saba, C.F. (2017). Vaccine-associated feline sarcoma: current perspectives. Veterinary Medicine: Research and Reports, 8: 13–20.

Seguin, B. (2002). Feline injection site sarcomas. Veterinary Clinics of North America: Small Animal Practice, 32: 983- 995.

Open Access This article is licensed under a Creative Commons Attribution 4.0 International License, which permits use, sharing, adaptation, distribution and reproduction in any medium or format, as long as you give appropriate credit to the original author(s) and the source, provide a link to the Creative Commons license, and indicate if changes were made. The images or other third party material in this article are included in the article's Creative Commons license, unless indicated otherwise in a credit line to the material. If material is not included in the article's Creative Commons license and your intended use is not permitted by statutory regulation or exceeds the permitted use, you will need to obtain permission directly from the copyright holder. To view a copy of this license, visit http://creativecommons.org/ licenses/by/4.0/.© The Author(s) 2019

ISSN: 0976-0547 (Online), 0253-150X (Print), Naas Rating: 4.21