CASE REPORT Agricultural Science Digest, Volume 40 Issue 3: 330-331 (September 202

Pathomorphological Studies on Congenital Porcine Polycystic Kidneys: Case Report

B. Baruah[1], S.M. Tamuli[1], G. Bezbaruah[2]

10.18805/ag.D-5016

ABSTRACT

A total of three cases of congenital porcine polycystic kidneys were observed incidentally in Hampshire and Desi crossbred piglets during necropsy examination in the Department of Pathology, College of Veterinary Science, Assam Agricultural University (AAU), Khanapara, Guwahati. Grossly, the kidneys were swollen with thinning of the cortex. There were presence of multiple cysts containing serous fluid. Microscopically, the cystic cavities were emptied and surrounded by a serous membrane and fibrous connective tissues. Renal tubules and glomeruli around the cysts were atrophied. The end stage renal failure appears to be the cause of death in piglets. The cases were diagnosed as congenital polycystic kidneys.

Key words: Congenital, Cyst, Kidney, Piglet, Porcine.

Polycystic kidney disease (PKD) is an inherited disorder in which clusters of cysts develop primarily within kidneys causing kidneys to enlarge and loss its function over time. Cysts are noncancerous round sacs containing fluid. These cysts can vary in their size. Polycystic kidney disease also can cause cysts to develop in liver or elsewhere in the body. In swine, polycystic kidney disease (PKD) is a rare form of congenital renal malformation in contrast to other species. The anomaly is characterized by the presence of numerous cysts located in the renal parenchyma. Most of the affected animals died during neonatal age due to severe renal failure.

A total of three cases of congenital porcine polycystic kidneys were observed incidentally in Hampshire and Desi crossbred piglets during necropsy examination in the Department of Pathology, College of Veterinary Science, Assam Agricultural University (AAU), Khanapara, Guwahati. The pigs did not revealed any symptoms of renal failure rather the disease was recorded incidentally during routine necropsy examination. Postmortem examination revealed grossly swollen kidneys with thinning of the cortex. On incision, there were presence of multiple cysts containing serous fluid (Fig 1).

Kidneys were mishapend, showed elevated area over the cortex. The ureter was enlarged and tortuous and the urinary bladder was almost rounded (Fig 2).

Histopathological examination of formalin fixed and H & E stained tissue sections from morbid specimens revealed cystic cavity which was emptied & surrounded by a serous membrane and fibrous connective tissues (Fig 3). Cystic dilatation of the renal tubules and atrophy of glomeruli due to pressure from the cyst was the prominent feature noticed. (Fig 4).

PKD is a rare disorder in swine, which results when offspring inherits a mutant copy of PKD genes (Adarsh *et al*., 2010). In humans and in cats PKD is of great of importance, which often leads to chronic renal failure. There are some reports on congenital porcine polycystic kidneys by various workers (Biller *et al*., 1996; He *et al*., 2001; Kumar *et al*., 2016; Wells *et al*., 1980; Wijeratne, 1980). Polycystic kidney disease in Persian cat was reported by previous worker (Biller *et al*., 1996). The development of cystic lesions in PKD is governed by polycystine-1, a cell membrane associated protein and a product of PKD gene. It is involved in normal cell proliferation and apoptotic pathways (McGavin and Zachary, 2012). Mutational changes in PKD-1 gene results in alteration of differentiation pathways interferes with the formation of tubular structure due to increased susceptibility to apoptotic activity during developmental stages. Blocked tubular structures results in obliteration of excretory passage and subsequently accumulation of fluid leading to the development of cystic lesions (Drolet, 2013; Kumar *et al*. 2007; McGavin and Zachary, 2012).

Present case report is a record of genetic susceptibility of Hampshire and Desi crossbred pigs for the development of PKD. Detection of carrier animals and subsequent culling can eliminate the incidence of PKD from the herd.

[1]Department of Veterinary Pathology, College of Veterinary Science, Assam Agricultural University, Guwahati-781 022, Assam India.
[2]Department of Zoology, Chandraprabha Saikiani Academy of Science, Pathsala-781 325, Assam, India.

Corresponding Author: B. Baruah, Department of Veterinary Pathology, College of Veterinary Science, Assam Agricultural University, Guwahati-781 022, Assam India.
Email: binitabaruah17@gmail.com

How to cite this article: Baruah, B., Tamuli, S.M. and Bezbaruah, G. (2020). Pathomorphological Studies on Congenital Porcine Polycystic Kidneys: Case Reports. Agricultural Science Digest. 40(3): 330-331.

Submitted: 10-08-2019 **Accepted:** 13-04-2020 **Published:** 22-08-2020

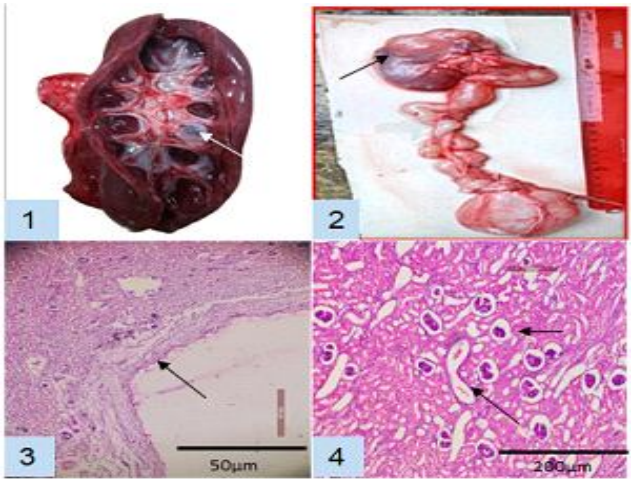

Fig 1: Porcine kidney showing multiple cysts containing serous fluid along with the thinning of the cortex. **Fig 2:** Misshapen porcine kidney showing elevated areas on the cortex along with enlarged and tortuous ureter. **Fig 3:** Section of the porcine kidney showing cystic boundary surrounded by a serous membrane and fibrous connective tissues H&E-50. **Fig 4:** Section of the porcine kidney showing cystic dilatation of the renal tubules and atrophy of glomeruli H&E-20x.

REFERENCES

Adarsh, V., Vijay, A. and Pankaj, P. (2010). Autosomal Dominant Polycystic Kidney Disease: A Comprehensive Review. International Journal of Nephrolurology (Supplement 2): 172-192.

Biller, D.S., DiBartola, S.P., Eaton, K.A., Flueger, P.S., Wellman, M.L. and Radin, M.J. (1996). Inheritance of polycystic kidney disease in Persian cats. Journal of Hereditary. 87: 1-5.

Drolet, R. and Dee, A.S. (2013). Diseases of Swine. (9th Edn.). Blackwell Publishing, Oxford, U.K.

He, J., Wang. Q., Ye, J., Hu, X. and Li, N. (2001). Identification of porcine polycystic kidney disease 1 (PKD1) gene: mo lecular cloning, expression profile and implication in dis ease model. Gene. 490(1-2): 37-46

Kumar, K., Gupta, M.K., Singh, K.K. and Kumar, S. (2016). Pathomorphology of porcine polycystic kidney: A case report. Indian Journal of Veterinary Pathology. 40(2): 181-182.

Kumar, V., Abbas, A.K., Fausto, N. and Mitchell, R.N. (2007). *Robbins Basic Pathology* (8th Edn.) Elsevier Inc., Philadelphia. pp. 569-570.

McGavin, M.D. and Zachary, J.F. (2012). *Pathologic basis of Veterinary Diseases* (5th Edn.), Elseiver, London, U.K.: pp.619-620.

Paslawski, R., Janiszewski, A., Noszczyk -Nowak, A., Nowacki, D. and Paslawska, U. (2013). Electronic Journal of Polish Agricultural Universities. 16: 4. (Available from: http://www. Ejpau. media.pl/volume16/issue2/art04.html).

Wells, G.A., Hebert, C.N. and Robins, B.C. (1980). Renal cysts in pigs: Prevalence and pathology in slaughtered pigs from a single herd. Veterinary Record. 106: 532-535.

Wijeratne, W.V. and Wells, G.A. (1980). Inherited renal cysts in pigs: results of breeding experiments. Veterinary Record.107: 484-488.