RESEARCH ARTICLE Agricultural Science Digest, Volume 41 Special Issue: 237-241 (April 2021)

A Case Study of Multiple Parasitisms in a Calf Buffalo (*Bubalus bubalis*)

Roshan Babu Adhikari, Tirth Raj Ghimire

10.18805/ag.D-5172

ABSTRACT

Background: Gastrointestinal (GI) parasitism by protozoan and helminth parasites exists as one of the major limiting factors in the buffalo industry, especially in the wellbeing of the calves around the developing countries like Nepal. During a field survey on buffaloes, we encountered a two- and half month ill male calf suffering from various illnesses for 14 days.

Methods: We collected its stool sample for three days and processed through a direct wet mount, sedimentation, floatation and acid-fast staining techniques and observed via a compound microscope.

Result: We detected the multiple patterns of infections of GI parasites and even counted the oocysts of coccidia and eggs of nematodes released per gram of the feces and discussed that co-infection was associated with the pathologic consequences. Coprological surveys with appropriate egg/oocyst counting techniques are useful in the treatment and preventive options of GI infections in calves.

Key words: Calf, *Cryptosporidium*, *Eimeria bovis*, Gastrointestinal parasites, *Strongyloides*, *Toxocara.*

Abbreviations: RPM: Revolution per minute, GI: Gastrointestinal parasite.

INTRODUCTION

Buffalo (*Bubalus bubalis*) is one of the most popular domestic ruminants, reared especially for the production of milk and meat around the world. In Nepal, male baby calves of two to three years are usually preferred by many religious and cultural groups for the consumption of meat. Very few smallholder farmers rear them for the natural breeding purposes. However, the babies are usually neglected, particularly after their birth and are deprived of sucking sufficient milk, consuming other nutritious supplements and applications of deworming practices. These factors may result in the sub-clinical and clinical illnesses like weak growth, susceptibility to parasites and parasitic diseases like diarrhea, anemia and many secondary infections in these naive calves (Regional Dairy Development and Training Team for Asia and Pacific Chiangmai 1993, Das *et al.* 2018). Few coccidian parasites like *Eimeria* spp. and *Cryptosporidium* and helminths like *Toxocara* and Strongyle have been shown to be fatal in the calves (Abdel-Rahman and El-Ashmawy 2013, Gaddam 2005, Olias *et al.* 2018, Rast *et al.* 2013, Regional Dairy Development and Training Team for Asia and Pacific Chiangmai 1993). Interestingly, during a survey on gastrointestinal (GI) parasites on buffaloes, we found one of the calves suffering from extreme illnesses. Thus, we aimed to detect various GI parasites in its stool and explained their causal association with its pathology. Exceptionally, we found 15 mixed parasitic species, many of which are pathogenic in young animals and are also implicated in fatal consequences.

MATERIALS AND METHODS

When we were conducting a coprological survey on buffaloes in Ratnanagar, Chitwan (Location: 27.64009 N, 084.49810 E, 151 meter above sea level) in the central part of Nepal, we found a two and half month calf (black male) suffering from extreme illnesses on September 14, 2019. The calf was weak, could not stand up well and seemed to be dying. The conjunctival mucous membrane was congested. It was lethargic and could not suck up milk. Its nose was running with mucus. Its skin was rough and there were lice and ticks infestations in the neck region. There were red patches or spots around the anal opening. It was not urinating for two days, although it frequently defecated (5 times a day) and was suffering from frequent belching and flatulence. The feces were semisolid, ash-colored, froth-smelling and contained mucus without blood. The environment nearby the calf was dirty and untidy, which was not cleaned for weeks. The calf-owner said that there was no previous and ongoing medication. We collected the stool samples of the calf and its mother for three consecutive days, preserved

Animal Research Laboratory, Faculty of Science, Nepal Academy of Science and Technology (NAST), Khumaltar, Lalitpur-44700, Nepal.

Corresponding Author: Tirth Raj Ghimire, Animal Research Laboratory, Faculty of Science, Nepal Academy of Science and Technology (NAST), Khumaltar, Lalitpur-44700, Nepal.
Email: tirth.ghimire@nast.gov.np

How to cite this article: Adhikari, R.B. and Ghimire, T.R. (2021). A Case Study of Multiple Parasitisms in a Calf Buffalo (*Bubalus bubalis*). Agricultural Science Digest. 41 (Special Issue): 237-241. DOI: 10.18805/ag.D-5172.

Submitted: 25-03-2020 **Accepted:** 23-12-2020 **Online:** 11-02-2021

the samples at 2.5% potassium dichromate immediately and transported them to the research laboratory (Animal Research Laboratory, Faculty of Science, Nepal Academy of Science and Technology, Lalitpur, Nepal). The samples were processed and examined by direct wet mount at potassium dichromate solution with or without staining by Gram's Iodine. Other techniques like sedimentation (1200 revolutions per minute, rpm, for 5 minutes at 0.9% w/v NaCl), flotation (1200 rpm, for 5 minutes at 45% w/v NaCl) and acid-fast staining methods were used and samples were observed under X100, X400 and X1000 total magnifications of the compound microscope (Ghimire and Bhattarai 2019). Finally, the 2 CELL McMASTER COUNTING SLIDE (HAWKSLEY, UK) was used to count the number of eggs and oocysts of few pathologically significant parasites released per gram in the fecal sample following the company protocol.

RESULTS AND DISCUSSION

The current study detected the multiple infections of various protozoan and helminth parasites. For example, we recorded the oocysts of *Eimeria bovis, E. bukidnonensis*, *E. cylindrica*, *E. subspherica*, *E. ellipsoidalis*, *E. zuernii, Cryptosporidium* sp., cysts of *Entamoeba* spp. and trophozoite of *Balantidium coli*. Similarly, we found the eggs of *Toxocara vitulorum*, *Strongyloides* sp., three morphotypes of Strongyle and *Trichostrongylus* sp. (Fig 1a-m). In a study, calves were found to excrete *Cryptosporidium* oocysts up to 3 months of age although oocyst shedding gradually became maximum from 16 to 30 days of age (Swain *et al.* 2019). Previous studies in India reported a 20-day-old calf with similar symptomatic nature was heavily infested with *Toxocara vitulorum* (36, 000 epg) (Raut, Sahu and Mahalik 2016) and a one-month calf with intermittent diarrhea, poor growth, dullness and anorexia was concomitantly infested with *Toxocara vitulorum* and *Strongyloides papillosus* (Samal, Patra and Maharana 2011). Moreover, mixed infection with *Neoascaris vitulorum, Strongyloides papillosus* and five Strongyle morphotypes was also diagnosed in one-month-old calves in India (Patnaik and Pande 1963). In the same geography, *Toxocara vitulorum* and *Eimeria* spp. were diagnosed in the intestinal lumen of the dead calf (Singh, Mishra and Pruthi 2008). Similarly, cent percent sampled calves, ranging from one- to six-month-old, were positive for eimeriosis with about 63% mixed (triplet) eimerian species in Iran (Bahrami and Alborzi 2013). Further, about 34% *Eimeria* positive 2-4-month-old calves in Hungary showed multiple infections with two or more species of this coccidian (Farkas, Szeidemann and Majoros 2007). These reports, coupled to our case study, suggest that the concomitant infection is extremely pathogenic in young calves, although we did not diagnose diarrheal stool in our calf. Diseases caused by *Eimeria* and *Cryptosporidium* and Balantidiosis caused by *B. coli* may lead to fatal consequences with or without diarrhea among calves around the world (Bahrami and Alborzi 2013, Olias *et al*. 2018, Gaddam 2005, Hassan *et al.* 2017, Sharma and Joshi 2020).



Fig 1a: An oocyst of *E. bovis* (30 x 22 µm, at X 400 after floatation).



Fig 1b: An oocyst of *E. bukidnonensis* (38 × 25 µm, at X 400 after floatation).



Fig 1c: An oocyst of *E. cylindrica* (24 × 14 µm, at X 400 after floatation).

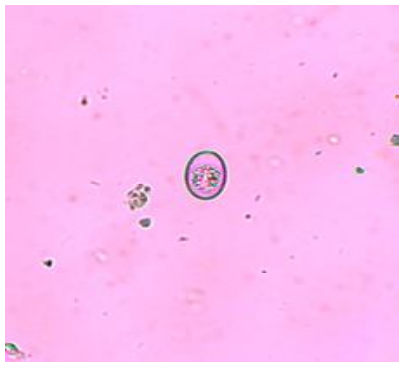

Fig 1d: An oocyst of *E. ellipsoidalis* (19 × 13 µm, at X 400 after floatation).

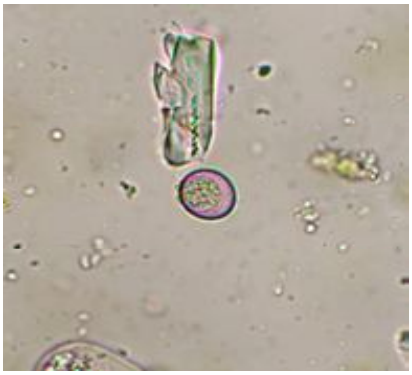

Fig 1e: An oocyst of *E. subspherica* (18 × 17 µm, at X 400 after floatation).



Fig 1f: An oocyst of *E. zuernii* (21 × 20 µm, at X 400 after floatation)

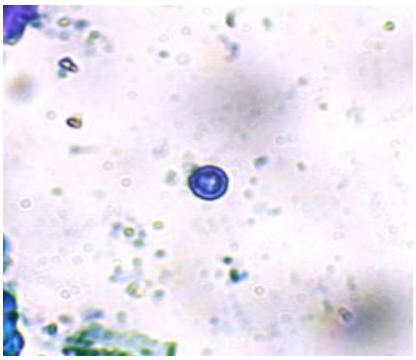

Fig 1g: An oocyst of *Cryptosporidium* sp. (5 × 5 µm, at X 1000 after acid-fast staining).

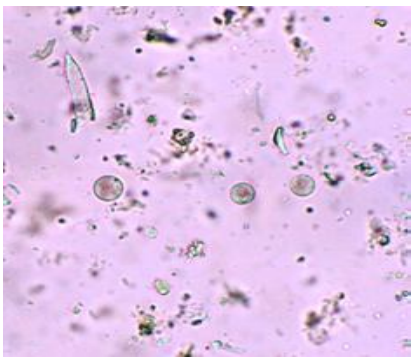

Fig 1h: Cysts of *Entamoeba* spp. (8-11 × 8-10 µm, at X 400 after Gram's Iodine staining).



Fig 1i: Trophozoite of *Balantidium coli* (99 × 65 µm, at X 400 after Gram's Iodine staining).

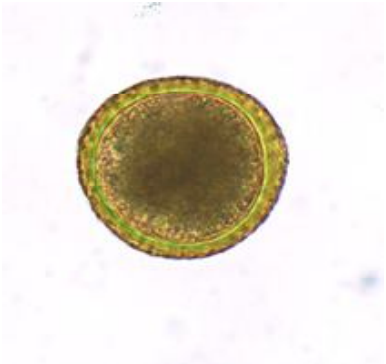

Fig 1j: Egg of *Toxocara vitulorum* (71 × 65 µm, at X 40 after floatation).



Fig 1k: Egg of *Strongyloides* sp. (63 × 33 µm, at X 400 after sedimentation).



Fig 1l: Egg of *Trichostrongylus* sp. (80 × 39 µm, at X 400 after sedimentation).

Table 1: The epg/opg count from stool sample of calf in three consecutive days.

	Parasitic species				
	Eimeria bovis	*E. zuernii*	*Toxocara vitulorum*	Strongyle	*Strongyloides* sp.
Range (Average epg or opg/g)	6,000-9,700 (8,300)	400-1,300 (700)	7,400-18,500 (12,800)	300-2,200 (1,000)	300-900 (500)



Fig 1m: Eggs of Strongyle spp. (52-58 × 31-35 µm, at X 400 after floatation).

Similarly, helminthiasis caused by Strongyle, *Toxocara, Strongyloides* and *Trichostrongylus* can severely affect the body condition of the young calves in between 1 and 3 months of age (Singh and Juyal 2014, Abdel-Rahman and El-Ashmawy 2013, Rast *et al*. 2013, Ezenwa *et al.* 2010). Although most of these species can be transmitted via fecal-oral routes, in the newly-born calves, other modes like consumption of milk or colostrum and contamination with fecal matters may cause transmission of the *Toxocara* and *Strongyloides* spp. suggesting how concomitant infections might occur in these young animals.

Further, we evaluated the average number of oocysts of *Eimeria bovis* (8,300/g) and *E. zuernii* (700/g) and eggs of *Toxocara* (12,800/g), Strongyle (1,000/g) and *Strongyloides* spp. (500/g) in the feces, for three consecutive days (Table 1) because these parasites are considered to be pathogenic in calves (Abdel-Rahman and El-Ashmawy 2013, Gaddam 2005, Olias *et al*. 2018, Rast *et al*. 2013, Regional Dairy Development and Training Team for Asia and Pacific Chiangmai 1993, Singh *et al*., 2008). These data suggest that the intensity of both these coccidia as well as nematodes in our calf was severe (Bahrami and Alborzi 2013, Soulsby 2012) and require immediate treatment.

This type of substantial mixed pattern reflects that young hosts are immunologically naive that show much stronger disease symptoms and are not capable of inhibiting the establishment and reproduction of other parasitic fauna (Mabbott 2018, Gasbarre, Leighton and Sonstegard 2001, Regional Dairy Development and Training Team for Asia and Pacific Chiangmai 1993). It is widely recognized that interactions among mixed species within hosts are critical for understanding mechanisms of pathology. Thus, mixed infections may be linked to the robust pathology of the newly-born calf and should be considered during treatment and preventive strategies of the parasites.

CONCLUSION

In conclusion, the multiple parasitisms here in our case might be associated with the traditional husbandry practices, the negligence of the farmers in the proper feeding practices and the lack of deworming adults as well as calves. Although further studies should be conducted, the mixed patterns of parasites might be due to naïve immune system of the calves. Thus, an awareness program accompanied by the antiparasitic treatment to the buffalo calves should be conducted to get rid of mixed infections. Further elaboration of infectious disease susceptibility and pathogenesis during mixed infections will help the rational design of treatment and preventive options.

Declarations

Ethics approval and consent to participate

The authors declare that the study was conducted on naturally-infected calf. No experimental infection was established during this research work. The required permission for the collection of the fecal samples was issued by the Ratnanagar Municipality and Veterinary Services, Ratnanagar, Chitwan, Nepal (Permission number: 952/2076/2077). This research was a part of the research proposal of Animal Research Program published in Red Book (2076/077) by Planning Division of Nepal Academy of Science and Technology (NAST).

Consent to publish

Written informed consent was obtained from the calf's owner.

Availability of data and materials

All data generated or analyzed during this study are included in this article.

Competing interests

The authors declare that they have no conflict of interest.

Funding

The laboratory cost was supported by the Faculty of Science, Nepal Academy of Science and Technology, (NAST).

Authors' contributions

RBA and TRG planned, worked in the laboratory and analyzed the data. Both authors worked in the field and wrote the first draft of the manuscript and finalized it.

ACKNOWLEDGEMENT

The authors would like to acknowledge Ratnanagar Municipality and Veterinary Services Chitwan, Nepal (Permission number: 952/2076/2077), for the permission to carry out the field survey and NAST for providing laboratory facilities.

REFERENCES

Abdel-Rahman, M. and El-Ashmawy, W. (2013). *Toxocara vitulorum* in faeces, serum and milk of buffaloes in Giza Governorate. International Journal of Livestock Research. 3: 89.

Bahrami, S. and Alborzi, A.R. (2013). Prevalence of subclinical coccidiosis in river buffalo calves of southwest of Iran. Acta Parasitologica. 58: 527.

Das, M., Deka, D., Sarmah, A., Sarmah, P. and Islam, S. (2018). Gastrointestinal parasitic infections in cattle and swamp buffalo of Guwahati, Assam, India. Indian Journal of Animal Research. 52: 1732.

Ezenwa, V.O., Etienne, R.S., Luikart, G., Beja-Pereira, A. and Jolles, A.E. (2010). Hidden consequences of living in a wormy world: nematode-induced immune suppression facilitates tuberculosis invasion in African buffalo. The American Naturalist. 176: 613.

Farkas, R., Szeidemann, Z. and Majoros, G. (2007). Studies on coccidiosis of calves in Hungarian dairy farms. Parasitology Research. 101: 113.

Gaddam, M.J. (2005). Epidemiology of coccidiosis in calves and control of coccidiosis using toltazuril at the time of weaning. Master of Philosophy in Veterinary Parasitology. Massey University, New Zealand.

Gasbarre, L.C., Leighton, E.A. and Sonstegard, T. (2001). Role of the bovine immune system and genome in resistance to gastrointestinal nematodes. Veterinary Parasitology. 98: 51.

Ghimire, T.R. and Bhattarai, N. (2019). A survey of gastrointestinal parasites of goats in a goat market in Kathmandu, Nepal. Journal of Parasitic Diseases. 43: 686.

Hassan, N., Randhawa, C.S., Singh, S. and Narang, D. (2017). Chronic diarrhea and therapeutic trial with metronidazole in *Balantidium coli* infected cattle and buffaloes. International Journal of Livestock Research. 7: 74.

Mabbott, N.A. (2018). The influence of parasite infections on host immunity to co-infection with other pathogens. Frontiers in Immunology. 9: 2579.

Olias, P., Dettwiler, I., Hemphill, A., Deplazes, P., Steiner, A. and Meylan, M. (2018) The significance of cryptosporidiosis for the health of calves in Switzerland. Schweizer Archiv fur Tierheilkunde. 160: 363.

Patnaik, M. and Pande, B. (1963). Notes on the helminthic infestations encountered in one month old buffalo calves. Indian Veterinary Journal. 40: 128.

Rast, L., Lee, S., Nampanya, S., Toribio, J.-A. L., Khounsy, S. and Windsor, P.A. (2013). Prevalence and clinical impact of *Toxocara vitulorum* in cattle and buffalo calves in northern Lao PDR. Tropical Animal Health and Production. 45: 539.

Raut, S., Sahu, R.K. and Mahalik, A. (2016). *Toxocara* infestation in a suckling buffalo calf: A case report. Scholars Journal of Agriculture and Veterinary Sciences. 3: 123.

Regional Dairy Development and Training Team for Asia and Pacific Chiangmai, T., (1993) Parasites in dairy cattle and buffalo. In: Small-scale Dairy Farming Manual 143. Food and Agriculture Organization, Rome.

Samal, A., Patra, P. and Maharana, B.R. (2011). Simultaneous infestation of a buffalo calf with *Ascaris* and *Strongyloides*: a case study. Veterinary World. 4: 322.

Sharma, S.K. and Joshi, M. (2020). Etio-Epidemiological Studies on Diarrhoea in Cattle and Buffalo Calves. Indian Journal of Animal Research. 54: 1391.

Singh, K., Mishra, S. and Pruthi, A. (2008). Pathology of parasitic infestations in gastrointestinal tract in buffalo calves. Journal of Veterinary Parasitology. 22: 17.

Singh, N. and Juyal, P. (2014). Prevalence of gastro-intestinal parasites in buffalo calves from different agro-climatic zones of Punjab. Journal of Parasitic Diseases. 38: 367.

Soulsby, E.J.L. (2012). Helminths, Arthropods and Protozoa of Domesticated Animals Seventh Edition. New Delhi: Affiliated East-West Press Private Limited.

Swain, K., Routray, A., Sahoo, S. and Ganguly, S. (2019). *Crypto--sporidium* oocyst shedding in buffalo calves in Haryana: A case study. Indian Journal of Animal Research. 53: 275.