RESEARCH ARTICLE Agricultural Science Digest, Volume 41 Issue 2: 352-357 (June 2021)

Investigations into Foot and Mouth Disease Outbreak among Small Ruminants in Karnataka State of India

Raveendra Hegde, B.P. Shivashankar, N. Gautham, G.R. Praveenkumar, B. Rajasekar, H.K. Muniyellappa, S.M. Byregowda, Madhusudan Hosamani[1], R.P. Tamil Selvan[1], Aniket Sanyal[1] 10.18805/ag.D-5228

ABSTRACT

Background: Foot-and-Mouth Disease (FMD) remains a serious threat to the Indian livestock sector due to significant economic loss associated with it. Systematic vaccination of large ruminants over the years has lead to a gradual reduction in the number of disease outbreaks in India. However exposure to FMDV infection in small ruminants has been recorded during the past few years (Rout *et al.* 2013). Sheep and goat population have not been vaccinated so far against FMD under the FMD-Control program (FMD-CP). The present study highlighted the outbreak of FMD in small ruminants in Karnataka, India.

Methods: During the period 2018-19, seven suspected FMD outbreaks among sheep population in Bellary and Tumakuru districts of Karnataka state were investigated. Tongue epithelium (oral swabs) and foot lesions (n=23) from clinically affected sheep and tissues such as heart, lung, liver, spleen, lymph nodes and kidneys from lambs during post mortem (n=67) were collected. All the samples were processed in the laboratory for the detection of FMD virus antigen by employing Serotype differentiating antigen detection ELISA and by multiplex PCR. Heart tissue samples were also collected in buffered formalin for histopathology study and processed by routine paraffin embedding technique and stained with Hematoxylin and Eosin (H and E). Serum samples from the recovered animals were collected and screened by NSP-ELISA and LPB-ELISA to check the antibody status in the affected herd.

Result: A total of seven suspected outbreaks of FMD involving 688 small ruminants was investigated. The outbreak of FMD due to FMDV serotype O was confirmed by ELISA and multiplex PCR assays. Clinically, the affected adult sheep showed typical signs of FMD, while mortality in young lambs was observed without apparent signs of disease. Histologically, heart tissues from FMD affected lambs showed myocardial necrosis with marked aggregations of lymphocytes and neutrophils in the myocardium and perivascular spaces. History of FMD outbreaks in cattle and common grazing land for the livestock, as well as sheep within the reach of these villages, may be the major contributing factors for the outbreaks in sheep populations.

Key words: ELISA, FMD, Outbreak, Small ruminants.

INTRODUCTION

The livestock sector constitutes an important component of agriculture providing livelihood security to rural poor who keep livestock as a source of food, income, manure, draught power, social status, a buffer against risk and a form of savings (FAO, 2008). The increased livestock productivity contributes substantially to the income of rural people in the developing world. (Forman *et al*. 2009). However, FMD remains a major constraint to the increasing livestock productivity with severe economic and social effects (James and Rushton, 2002). Endemic presence of FMD is a serious threat to the livestock population of India. Three (O, A and Asia-1) of the seven serotypes of FMD virus (FMDV) are prevalent in India, while serotype C has not been detected in the country since 1995 (Pattnaik *et al*. 2012). FMD outbreaks are regularly recorded in the state of Karnataka and serotype O has been the most prevalent one (ICAR-DFMD Annual Report 18-19). The disease severity varies between host species, with cattle developing most severe clinical signs, while small ruminants suffer from mild/sub clinical disease. Since September 2011, cattle and buffalo population of the Karnataka state are regularly vaccinated with a trivalent vaccine containing representative strains of FMDV serotypes O, A and Asia-1 viruses circulating in the country.

Institute of Animal Health and Veterinary Biologicals, Karnataka Veterinary, Animal and Fisheries Sciences University, Bengaluru-560 024, Karnataka, India.

[1]ICAR-Indian Veterinary Research Institute, Bengaluru-560 024, Karnataka, India.

Corresponding Author: Raveendra Hegde, Institute of Animal Health and Veterinary Biologicals, Karnataka Veterinary, Animal and Fisheries Sciences University, Bengaluru-560 024, Karnataka, India. Email: ravihegde63@gmail.com

How to cite this article: Hegde, R., Shivashankar, B.P., Gautham, N., Parveenkumar, G.R., Rajasekar, B., Muniyellappa, H.K., Byregowda, S.M., Hosamani, M., Selvan, R.P.T. and Sanyal, A. (2021). Investigations into Foot and Mouth Disease Outbreak among Small Ruminants in Karnataka State of India. Agricultural Science Digest. 41(2): 352-357. DOI: 10.18805/ag.D-5228.

Submitted: 02-06-2020 **Accepted:** 02-11-2020 **Online:** 26-01-2021

Cattle and buffalo are vaccinated at 6 monthly intervals under the government-funded National FMD control program (FMDCP) (Pattnaik *et al*. 2012). Sheep and goat population are not vaccinated against FMD under the FMD-CP till now. Although the number and severity of FMD outbreaks have been reduced due to systematic vaccinations in livestock,

an increase in FMD incidences due to serotype O is continued to be recorded in small ruminants. FMD in small ruminants is usually subclinical compared to cattle or pigs. The infected sheep and goats have been incriminated due to transboundary spread of the disease on several occasions in the past (Kitching, 1998). The role of small ruminants in the spread and distribution of FMD in Asian and African countries is well documented, where the small ruminants contaminate river water, ponds, pastures, the shrubs and other environments. The source of infection to the other livestock occurs because the movement of ruminants in these countries is unrestricted and is of free-range nature (Uppal, 2009). In India, sheep and goats are cohoused and share common pastures with cattle and buffaloes in the mixed farming set up. They often migrate long distances because of transhumance in search of grazing lands or for sale through meat markets, thereby posing a serious risk of disseminating the virus (Madhanmohan *et al*. 2009). Timely investigation of field outbreaks aids in the rapid implementation of appropriate vaccination and zoo sanitary measures for effective control of the disease and for restricting the dissemination of the virus. In the present study, outbreak of FMD in small ruminants was investigated in Tumakuru and Bellary districts, Karnataka, India.

MATERIALS AND METHODS

Outbreak description

A total of seven suspected outbreaks of FMD involving 688 number of small ruminants at Tumakuru and Bellary district of Karnataka during 2018-19 were investigated. The outbreaks started with the appearance of clinical signs in adult sheep and goats, with mortality in young lambs within a week. The villages, where outbreaks are seen had a common grazing land for all livestock species. In Bellary district, the disease was seen in a migratory flock, where mortality was seen in lambs of less than 30 days old. Initially, dullness with lameness was noticed. At the time of the investigation, high fever with salivation, ulcerative lesions on the tongue, the dental pad was observed. The interdigital space was swollen with lesions. In some lamb, the mortality was sudden without showing clinical signs. The details of the outbreak area are given in Table 1.

Clinico pathological examination (Post mortem examination)

Post mortem examination of lambs died of suspected FMD was carried out and recorded the pathological lesions on heart and other vital organs. At post-mortem, the characteristic pathologic finding observed was myocardial necrosis (Fig 4.) with small greyish necrotic foci on heart ('tiger heart' lesion) (Fig 5) in 1 to 3 months old lambs. The other body tissues were not having any pathological findings except for enteritis in few lambs.

Sample collection and laboratory confirmation

Tongue epithelium (oral swabs) and foot lesions (n=23) from clinically affected sheep and body tissues such as heart (n=26), lung (n=10), liver(n=05), spleen(n=10), lymph nodes (n=11) and kidneys (n=05) from lambs during post mortem (n=67) were collected in 50% phosphate-buffered saline-glycerine medium (pH 7.2-7.4). All the samples were processed in the laboratory for the detection of FMD virus antigen by employing serotype differentiating antigen detection ELISA and further by reverse transcriptase polymerase chain reaction (RT-PCR). Heart tissue samples were also collected in 10% neutral buffered formaline for

Table 1: Details of FMD outbreaks in Tumakuru and Bellary districts, Karnataka, India.

Village	Population	Affected flock size	Number affected	Mortality	Incidence rate (%)	History of FMD in cattle	GPS coordinates
Kodigenahalli, MadhugiriTq	Sheep-1750, Goat-550.	Sheep-150 Goat-28	Adult Sheep: 40 Lambs: 13	Lambs: 13	30.00	Yes	13.7203304 77.3859542
Hoysalakatte C.N.HalliTq	Sheep-1200, Goat-300.	Sheep-85 Goat-11	adult Sheep:24 Lambs: 6, Kids: 2	Lambs: 6 Kids: 2	33.00	No	13.6181454 76.6437931
Manganahalli,	Sheep-635, Goat-215	Sheep-110 Goat-20	15 adults sheep	3 lambs	13.00	Yes	14.7472143 76.212904
Kaggaladu	Sheep-850, Goat-300	Sheep-150 Goat-25	30 adults sheep	15 lambs	26.00	Yes	13.8137322 76.8578921
Gollarahati	Sheep-1100, Goat-450	Sheep-90 Goat-10	18 adults sheep	03 lambs	21.00	No	13.8494086 77.1676469
Kusukunte village	Sheep-750, Goat-210	Sheep-95 Goat-15	20 adults sheep	10 lambs	27.00	Yes	13.7528659 76.9366188
Vaddarahalli, Hospetetq, Ballary dist	Migratory flock	Sheep:1200	Sheep: 300 Lambs: 200	180	36.00	No	15.2368154 76.467946

histopathological examination and processed by routine paraffin embedding technique and stained with Hematoxylin and Eosin (H&E) as per Luna (1968). Blood samples from recovered animals (n=70) were collected for screening of FMD NSP and SP antibodies.

Serotype differentiating antigen detection ELISA

Supernatants of the homogenized clinical tissue materials (10% PBS suspension) were used in a serotype differentiating antigen detection ELISA as per Bhattacharya *et al*. (1996) for confirmation of serotype of the virus involved in the outbreaks. Briefly, the 96-well ELISA plate (Nunc, Maxisorp) was coated with FMDV anti-146S serum raised in rabbit at 1 in 1000 dilution in carbonate-bicarbonate buffer (pH 9.6). The plate was incubated at 37°C for 1 h and washed 3 times with PBST (Phosphate buffered saline containing 0.05% Tween-20). Samples were added in duplicates, along with positive and negative controls. The plate was incubated and washed. Anti-146S guinea pig tracing antibody diluted 1:4000 in blocking buffer (PBST + 5% skimmed milk powder) was then added to each well. The plate was washed after incubation at 37°C for 1 hr and anti-guinea pig IgG conjugated to HRPO (Dako, Denmark) at 1:3000 dilution in blocking buffer was added and incubated. After washing, freshly prepared orthophenylene diamine/hydrogen peroxide substrate was added and incubated at 37°C for 15 min for colour to develop. Then the reaction was stopped using 1M H_2SO_4. The absorbance in the plates was read at 492 nm using ELISA plate reader (Tecan Infinite 50).

Serotype differentiating multiplex polymerase chain reaction (mPCR)

Total RNA from tissue samples was extracted using Trizol-LS reagent. Reverse transcription was performed using M-MLV reverse transcriptase and reverse primer NK61 (Knowles and Samuel, 1995). Serotype differentiating multiplex PCR (mPCR) was performed as per the method described by Giridharan *et al*. (2005) with slight modifications. The mPCR products were visualized on ethidium bromide-stained 2% agarose gel. The PCR product corresponding to 249, 376, 537 bp product indicated FMD virus serotype O, A and Asia1, respectively.

Liquid phase blocking ELISA

Liquid Phase Blocking (LPB) ELISA was carried out to quantify the antibody against Indian FMD vaccine virus antigens' structural proteins in the serum samples collected from sheep (Hamblin *et al*., 1986; OIE, 2018). Two-fold dilutions of serum samples were tested for serotype- O specific SP-Ab titer and the results were expressed as percentage reactivity for each serum dilution as follows:

$$\text{Percentage reactivity} = (OD_{\text{mean of each test serum dilution}} / OD_{\text{mean of antigen control}}) \times 100$$

The antibody titers were expressed as the log values of reciprocal of serum dilutions giving 50% of the absorbance recorded in the antigen control wells. The samples showing a log10 titer of at least ≥ 1.8 were considered as having protective antibody.

NSP antibody detection ELISA

The test was performed to confirm the infection status of animals using a commercial kit (Prionics FMD NS kit, Netherlands) as per the instructions provided by manufacturer. After color development and stopping the reaction, the plate was read in an ELISA reader at 450 nm wavelength (Tecan Infinite 50) and the absorbance values obtained were used to determine the percent-inhibition (PI) values. Serum samples having ≥ 50% PI values were considered as positive for NSP antibodies.

RESULTS AND DISCUSSION

The present outbreaks of FMD in small ruminants in two districts of Karnataka (Tumakuru and Bellary) were associated with FMDV serotype O as confirmed by antigen detection ELISA and further by m-PCR. The antigen detection ELISA could detect FMDV from tongue epithelium (27% samples) and heart tissue (19% samples) and m-PCR detected FMDV from lung, spleen (10% samples) and lymph nodes (17% samples). FMDV could not be detected from liver, kidney and foot lesion samples. FMD outbreaks in livestock are being regularly reported in the state and majority of the FMD outbreaks in Karnataka in recent years were due to serotype O (ICAR-DFMD Annual report 18-19). Though, the severity and the duration of FMD outbreaks in livestock has relatively reduced due to systematic vaccinations in large ruminants over the years, exposure to FMDV infection in small ruminants has been recorded during the past few years (Rout *et al.,* 2014, Rout *et al*., 2014a). Sheep and goat population were not vaccinated so far against FMD under the FMD-Control program (FMD-CP). Clinically, the affected ailing adult sheep showed high fever with salivation (Fig 1a), ulcerative lesions on the tongue (Fig 1b) and dental pad. The inter-digital was swollen with lesions leading to limping in some animals as observed during the time of investigation (Fig 2). FMD is generally subclinical in small ruminants but severe overt clinical signs were observed in sheep in the present outbreak. History of FMD outbreaks in cattle and common grazing land for the livestock, as well as sheep within the reach of these villages might be the major risk factors identified for the disease in small ruminants in these districts. However, it was reported earlier that some



Fig 1: Clinical signs in small ruminants. An infected sheep showed profuse salivation (a, arrow) ulceration on tongue (b, arrow) and tongue erosion.

strains of FMDV serotype O is well adapted to small ruminants and 90 per cent of the positive samples from small ruminants submitted to WRL are due to serotype O (Kitching and Hughs, 2002). Within the flock, the disease might have spread due to close contact or by mechanical carriage by humans. In the present outbreak, it was observed that the virus has not disseminated to all the animals in the flock, but the clinical disease in young lambs and kids was characterized by death without clinical signs due to heart failure (Fig 3). Outbreaks of FMD in sheep flocks have been reported to cause death in lambs with reported clinical signs including fever, collapse, tachycardia and marked abdominal respirations (Pay, 1988). Mortality is a feature of the disease in young lambs (Barnett *et al*. 1999). In the present outbreaks also severe mortality in lambs and kids was observed. The death in lambs was noticed after two to three days of the appearance of clinical symptoms in adult ewes.

At post-mortem, the characteristic pathologic finding observed was myocardial necrosis (Fig 4) with small greyish necrotic foci on heart ('tiger heart' lesion) (Fig 5) in 1 to 3 months old lambs. Histologically, heart tissues from FMD affected sheep and goats showed severe myocarditis with marked aggregations of lymphocytes and neutrophils in the myocardium and perivascular spaces. Interstitial edema, multifocal myocardial degeneration and necrosis with the fragmentation of cardiomyocyte are also noted (Fig 6, 7, 8).



Fig 2: Swollen interdigital space with lesions leading to limping in sheep.

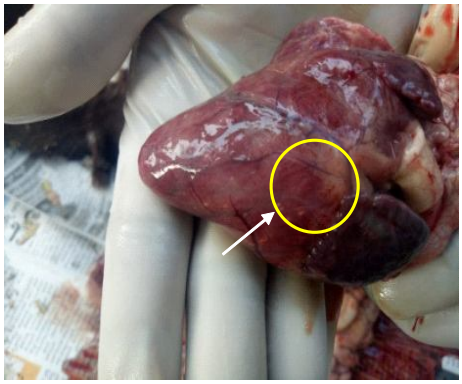

Fig 3: Focal necrotic lesions on myocardium in lambs (arrow).



Fig 4: Tigroid lesions on myocardium in lambs (arrow).

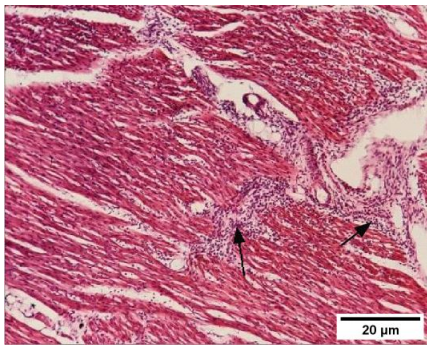

Fig 5: Severe myocarditis with marked aggregations of lymphocytes and neutrophils in myocardium and perivascular spaces (arrow). Haematoxylin and Eosin stain (100x).

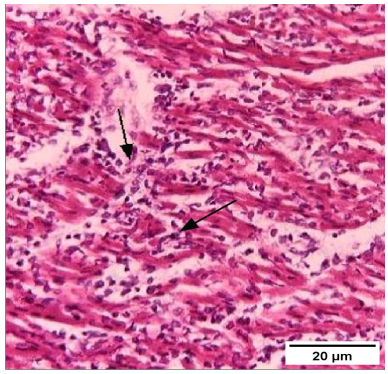

Fig 6: Dispersed and disrupted myocardiocytes due to interstitial edema and aggregations of lymphocytes and neutrophils within the myocardium (arrow). Haematoxylin and Eosin stain (400x).

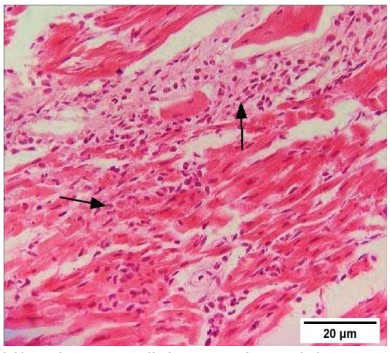

Fig 7: Multifocal myocardial necrosis and fragmentation of myocardiocytes (arrow). Haematoxylin and Eosin stain (400x).

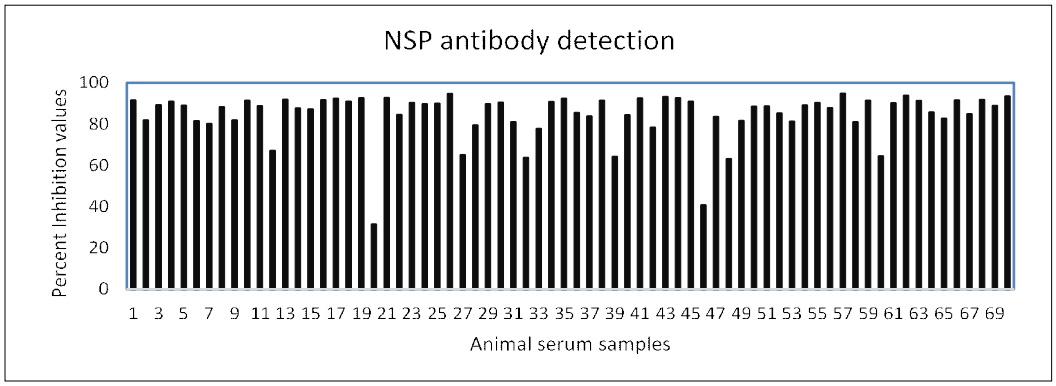

Fig 8: NSP antibody detection in serum from recovered sheep.

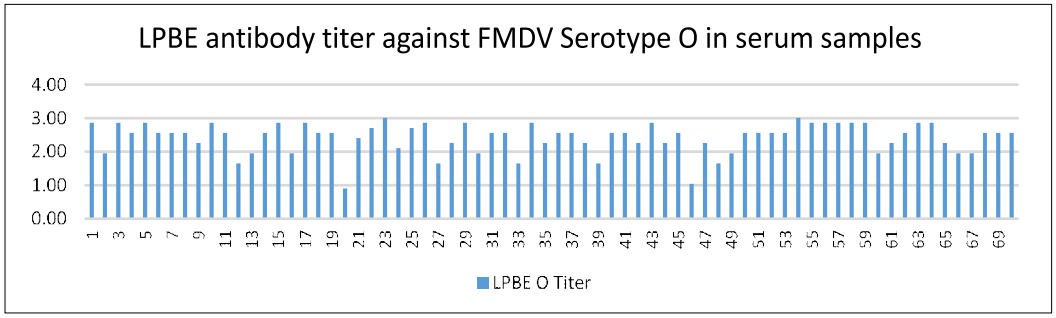

Fig 9: FMDV antibodies to serotype O in serum samples from recovered small ruminants.

Similar findings were also reported elsewhere (Beskawy *et al*. 2016; Ryan *et al*. 2008). The histopathological lesions in the heart indicate that viral myocarditis may have been a factor in the lamb mortality. Detection of antibody against the 3ABC (Non-structural protein) of FMDV is a useful indicator of FMD virus infection and the presence of high titers of non-structural antibodies (per cent inhibition of 45 to 95 per cent in 69 of the 70 samples) in the serum collected from the recovered animals also indicated widespread infection in the flock (Fig 8). The sheep were not vaccinated and the spike in the serotype O specific anti-structural protein antibodies (log10 titer of ≥1.8) also clearly indicated the animals got infected with FMDV serotype O (Fig 9). The antibodies were detected by LPB-ELISA was due to natural infection because there was no history of vaccination in sheep and goats in the study areas.

FMD is endemic and known for its wider distribution in Karnataka state, India. The retrospective study on the epidemiology of FMD in Karnataka had revealed the dominance of serotype O over the other serotypes in causing the outbreaks in the livestock (Hegde *et al*. 2014). The role of small ruminants in maintaining of FMD virus remains uncertain making the strategy of disease control more challenging (Balinda *et al*. 2009). The present outbreaks reaffirm FMD virus activity in small ruminants and the recovered infected herds and nomadic farmers can spread the disease to other herds or areas (Phyoe *et al*. 2017). The animal husbandry practice in the state reflects cattle, sheep and goats being reared nearby and at many places even co-housed. Communal grazing is practiced in many areas, where both small and large ruminants are allowed to use the same pasture land and water sources. These unrecognized, subclinically infected small ruminants may act as a source of infection through their secretions and excretions and could pose a potential risk of virus dissemination to cattle and other animals.

Since September 2011, cattle and buffalo (bovines) population of Karnataka state are regularly vaccinated with a trivalent vaccine containing all the three FMDV serotypes O, A and Asia-1 circulating in the country, at 6 monthly intervals under the government-funded National FMD control program (FMDCP). The small ruminants are not included under FMD-CP. The recent outbreaks in small ruminants emphasize the importance of these species in the epidemiology of FMD.

ACKNOWLEDGEMENT

The authors are thankful to Director, ICAR-DFMD Mukteswar, Director, KVAFSU-IAH and VB, Director ICAR-IVRI, Bengaluru and the Director AH and VS, Karnataka for facilitating this study.

REFERENCES

Balinda, S.N., Tjornehoj, K., Muwanika V.B., Sangula, A.K., Mwiine, F.N., Ayebazibwe, C., Massembe, C., Siegismund, H.R. and Alexandersen S. (2009). Prevalence estimates of antibodies towards foot and mouth disease virus in small ruminants in Uganda. Transboundary Emerging Disease. 56: 362-371.

Barnett, P.V. and Cox, S.J. (1999). The role of small ruminants in the epidemiology and transmission of foot-and-mouth disease. The Veterinary Journal. 158: 6-13.

Beskawy, M.A. EL., Farag, V.M. and Saad, M.A. (2016). Epidemiological and clinic pathological studies of sheep naturally infected with Foot and Mouth Disease Virus (SAT2) in Egypt. Alexandria Journal of Veterinary Sciences. 49: 129-137. DOI:10.5455/ajvs.223318.

Bhattacharya, S., Pattnaik, B. and Venkataramanan, R. (1996). Development and application of sandwich enzyme-linked immunosorbent assay (ELISA) for the type identification of foot and mouth disease (FMD) virus indirect field materials. Indian Journal of Animal Sciences. 66: 1-9.

FAO (2008). Livestock Policy and Poverty Reduction. Livestock Policy Brief 04. Animal Production and Health Division. FAO. Rome.

Forman, S., Le Gall, F., Belton, D., Evans, B., Francois, J.L., Murray, G., Sheesley, D., Vandersmissen, A. and Yoshimura, S. (2009). Moving towards the global control of foot and mouth disease: an opportunity for donors. Scientific and Technical Review. Office International des Epizooties. 28: 883-896.

Giridharan, P., Hemadri, D., Tosh, C., Sanyal, A. and Bandyopadyay, S.K. (2005). Development and evaluation of a multiplex PCR for differentiation of foot-and-mouth disease virus strains native to India. Journal of Virological Methods. 126:1-11.doi: 10.1016/j.jviromet. 2005.01.015.

Hamblin, C., Barnett, I.T. and Hedger R.S. (1986). A new enzyme-linked immunosorbent assay (ELISA) for the detection of antibodies against foot-and-mouth disease virus. I. Development and method of ELISA. Journal of Immunological Methods. 93: 115-121.

Hegde, R., Gomes, A.R., Giridhar, P., Kowalli, S., Shivashankar, B.P., Sudharshana, K.J., Nagaraj, K., Shesharao., Mallinath, K.C., Shankar, B.P., Nagaraj, D., Seema, C.M., Khan, T.A., Nagaraj, G.V., Srikala, K., Dharanesh, N.K., Venkatesha, M.D. and Renukaprasad, C. (2014). Epidemiology of foot and mouth disease in Karnataka state, India: A retrospective study. Virus Disease. 25: 504-509.

ICAR-DFMD Annual Report 2018-19, ICAR-Directorate of Foot and Mouth Disease, Mukteswar, Nainital-263 138.

James, A.D. and Rushton, J. (2002). The economics of foot and mouth disease. Scientific and Technical Review. Office International des Epizooties. 21: 637-644.

Kitching, R.P. (1998). A recent history of Foot-and-Mouth Disease. Journal of Comparative Pathology. 118: 89-108.

Kitching, R.P. and Hughes, G.J. (2002) Clinical variation in foot and mouth disease: sheep and goats. Scientific and Technical Review. Office International des Epizooties. 21: 505-512.

Knowles, N.J. and Samuel, A.R. (1995). Polymerase chain reaction amplification and cycle sequencing of the 1D (VP1) gene of foot-and-mouth disease viruses. Report of the Session of the Standing Technical Committee of the European Commission for the Control of Foot-and-Mouth disease held at Vienna, Austria, September 19-22, 1994. FAO, Rome, pp. 45-53.

Luna, L.G. (1968). Manual of histologic staining methods of the Armed Forces Institute of Pathology. McGraw Hill Book Company, New York.

Madhanmohan, M., Tresamol, P.V. and Saseendranath, M.R. (2009). Immune response in goats to two commercial foot-and-mouth disease vaccines and the assessment of maternal immunity in their kids. Transboundary and Emerging. Disease. 56: 49-53.

OIE (2018). Foot and Mouth Disease, chapter 2.1.8 in: Manual of Diagnostic Tests and Vaccines for Terrestrial Animals 2018 available at www.oie.int/standard/terrestrial-manual/ access online, accessed on 17-12-2018.

Pattnaik, B., Subramaniam, S., Sanyal, A., Mohapatra, J.K., Dash, B.B., Ranjan, R. and Rout, M. (2012). Foot-and-mouth disease: global status and future road map for control and prevention in India. Agric Res. 1: 132-147.

Pay, T.W.F. (1988). Foot and mouth disease in sheep and goats: A review. Foot and Mouth Disease Bulletin. 26: 2-13.

Phyoe, H.M.M., Khaing, A.T., Abba, Y., Aung, Y.H., Htun, L.L., Htin, N.N., Abdullah, J.F.F. and Lila, M.A.M. (2017). Seroprevalence of Foot and Mouth Disease Virus (FMDV) and associated risk factors in unvaccinated sheep and goats in Pyawbwe and Meikhtila townships of Myanmar. Journal of Advanced Veterinary and Animal Research. 4: 161-167.

Rout, M., Biswal, J.K., Dash, B.B., Hegde, R., Subramanium, S. and Mohapatra, J.K. (2014). Investigation of foot and mouth disease outbreaks in Chikkaballapur districts of Karnataka. Indian Journal of Animal Sciences. 84: 231-235.

Rout, M., Senapati, M.R., Mohapatra, J.K., Dash, B.B., Sanya, l. A. and Pattnaik, B. (2014a). Serosurveillance of foot and mouth disease in sheep and goat population of India. Preventive Veterinary Medicine. 113: 273-277.

Ryan, E., Horsington, J., Durand, S., Brooks, H., Alexandersen, S., Brownlie, J. and Zhang, Z. (2008). Foot-and-mouth disease virus infection in young lambs: pathogenesis and tissue tropism. Veterinary Microbiology. 127: 258-274.

Uppal, P.K. (2009). Foot-and-Mouth Disease in Small Ruminants-An Issue of Concern. Appen, 29. www.fao.org/ag/aga/ infocommissionsdocs/greece04/Ap p29.pdf.