RESEARCH ARTICLE Agricultural Science Digest, Volume 44 Issue 4: 745-750 (August 2024)

Evaluation of Wound Healing Activity of *Teucrium polium* on Excisional Wounds in Wistar Rats

Kalbaza Ahmed Yassine[1], Hemida Houari[2], Rezgui Houssam[1], Hamouta Younes[1], Benchohra Mokhtar[2], Amara Karim[2]

10.18805/ag.DF-520

ABSTRACT

Background: *Teucrium polium* a member of *Lamiaceae* family is a widely used plant in Algerian traditional medicine; however, there are few reports on its use as a healing agent. The aim of this study is to investigate the wound healing property of aerial part of this plant on excisional wounds.

Methods: Twenty adult male Wistar rats with an average weight of 180 g were used in this study. Post wound development, 10 rats received daily treatment with the plant ointment and the remaining rats served as control. Measurement of wound areas and calculation of closure percentages were made in order to evaluate wound healing macroscopically and a sample of the scar tissue formed was submitted at day 24 post treatment for a histological study.

Result: Better and faster healing was observed in the *Teucrium polium* group compared to control. This improvement in wound healing was confirmed by the histological study which revealed that the effect of the plant lies in its stimulation of proliferative phase and its regulation of the inflammatory phase of wound healing. Based on these results, we could deduce that *Teucrium polium* enhance healing of excisional wounds.

Key words: Excision, Phytotherapy, Rat, *Teucrium polium*, Wound healing.

INTRODUCTION

A wound is defined as a tissue injury, in which the skin or other body tissue is torn, cut, scraped, scratched or punctured (Singer and Clark, 1999). After an injury, a complex process takes place in order to repair the tissue damage. Wound healing consists of an initial inflammatory phase followed by a repair phase, maturation and finally remodeling (Gangwar *et al.,* 2015). Wounds are still a major problem in developing countries, often leading to serious complications (Strecker-McGraw, 2007) because their care is complex, time consuming, sometimes confusing and almost always expensive (Robson *et al.,* 2009).

The research of new wound healing agents is one of the developing fields in modern biomedical sciences and many studies have been carried out using different wound healing models (Elzayat *et al.,* 2018). Among these agents, natural products such as medicinal plants continue to be a focus of interest due to their cost-effectiveness, wide availability, non-toxicity, ease of use and reduction of side effects (Bhaskar Rao *et al.,* 2015).

In Algeria, *Teucrium polium* commonly called “El khayata”, is one of the widely used plants in traditional medicine. This plant belongs to the genus *Teucrium* of *Lamiaceae* family, which includes more than 300 aromatic species growing spontaneously in various regions of the world (Jeanmonod and Gamisans, 2007). It grows in the south of the Sahara, mainly in the stony beds of wadis and rocks (Ozenda, 2004). It is a perennial herbaceous shrub that has been widely used for over 2000 years as a treatment for inflammation, rheumatism, ulcers and the other injuries (Esmaeili *et al.,* 2004; Mirzaei and Jaberi Hafshajani, 2010).

[1]Institute of Veterinary and Agronomic Sciences, Batna-1 University, Batna, Algeria.
[2]Institute of Veterinary Sciences, University of Tiaret, Tiaret, Algeria.

Corresponding Author: Kalbaza Ahmed Yassine, Institute of Veterinary and Agronomic Sciences, Batna-1 University, Batna, Algeria. Email: yassine.kalbaza@univ-batna.dz

How to cite this article: Yassine, K.A., Houari, H., Houssam, R., Younes, H., Mokhtar, B. and Karim, A. (2024). Evaluation of Wound Healing Activity of *Teucrium polium* on Excisional Wounds in Wistar Rats. Agricultural Science Digest. 44(4): 745-750. doi: 10.18805/ag.DF-520.

Submitted: 12-11-2022 **Accepted:** 05-04-2023 **Online:** 23-05-2023

Recently, numerous pharmacological studies have reported the antipyretic, analgesic, anticancer, antioxidant, wound-healing, antifungal and antibacterial activities of *Teucrium polium* (Tatar *et al.,* 2012; Aouadhi *et al.,* 2013; Movahedi *et al.,* 2014; Meguellati *et al.,* 2019). The main objective of our study is therefore to test the healing activity of *Teucrium polium* in the form of an ointment prepared by mixing commercial petroleum jelly with the aerial part of the plant in its crushed form on excisional wounds in Wistar rats.

MATERIALS AND METHODS

Study site

This study has been conducted from April to September 2021, at the Institute of Veterinary and Agronomic Sciences, Batna - 1 University and the Institute of Veterinary Sciences, University of Tiaret of Algeria.

Plant and ointment preparation

The flowering aerial parts of *Teucrium polium* have been gathered in April 2021 from the region of Tiaret in Western Algeria, at 35°22′15″N latitude and 1°19′01″E longitude. The plant was first authenticated by the forest conservation services of Tiaret and then it was rinsed and left to shady dry at room temperature. Thereafter, the aerial parts of the plant were crushed using an electric grinder.

Fifty gram of the obtained powder was added to 300 ml of 70% methanol and incubated in a shaking incubator (200 rpm) at 25°C for 72 h. After filtration of the extract, the flow-through was concentrated using rotary evaporator (Heidolph Laborota 4002-Germany) and a freeze dryer (Alpha 1-4 LSCbasic-Martin Christ-Germany). Finally, a 25% ointment was prepared by mixing 25 g of the plant concentrate to 100 g of ointment base composed of 5 g of hard paraffin, cetostearyl alcohol, wool fat and 85 g of white soft paraffin, as mentioned in British Pharmacopoeia (1988). The prepared ointment was stored in dark containers at 4°C.

Animals

For our experiment, we have used 20 healthy adult male *albino* Wistar rats with an average weight of 180 g. The animals were purchased from the Pasteur Institute of Algeria. Prior to any procedure, the rats were adapted for 10 days in a clean, well ventilated and temperature-controlled room (25°C). The animals were kept in individual clear rodent cages with a stainless-steel cover where they received a standard rat pellet feed (UAB, El Kseur, Bejaia, Algeria) and *ad libitum* water in rodent bottles. Sawdust was used as bedding and cleaning of cages and water bottles was carried out one in every 2 days.

Experimental design

Animals were randomly divided into two groups of 10 each: Control group (C) treated with the ointment base, and *Teucrium polium* (TP) group treated with the plant ointment. Macroscopic evaluation of wound healing was based on measurement of wound surface and calculation of wound closure percentage for every three days once. Twenty-four days post treatment, a histological evaluation of the tissues formed at wound site was carried out. Finally, a statistical analysis of data obtained was performed to determine which group had the better healing.

Wound creation

Aseptic conditions were fully complied in all surgical procedures. Before surgery, rats were tranquilized in order to prepare the operative region. The back was therefore largely clipped and carefully shaved, taking care to avoid skin damage. No antiseptic was used on the shaved part. Animals were anesthetized with an intramuscular injection of Ketamine® at the rate of 80 mg/kg (Ketamine, Virbac, France) with Xylazine pro 2% @ 10 mg/kg (Xylazine, VETOPHARM Pro, Algeria) and then they were placed in sternal recumbency, and the skin to be excised was outlined. Using a scalpel blade, an incision through the entire depth of the skin was made along the markings. The skin was then gently excised using dissecting forceps and a pair of scissors. Minor bleeding was stopped with a sterile gauze buffered with normal saline. At the end of this procedure, an excisional wound of approximatively 600 mm^2 was obtained. Wounds were left uncovered throughout the experimental period. Twenty-four hour post incised wound, treatment has been started as described in the experimental design section.

Measurement of wound surface and determination of wound closure percentage

After a deep tranquillization using 10 mg/kg of Xylazine, animals have been maintained in a sternal recumbency and the excisional wounds were photographed with an HD camera every three days. Wounds pictures were processed with Image-J software(https://imagej.nih.gov/ij/download.html) to measure the wound surfaces. The obtained results were finally used to calculate the percentage of wound closure according to the following formula:

$$\% \text{ of closure} = \frac{\text{Wound surface at J0-Wound surface at Jn}}{\text{Wound surface at J0}} \times 100$$

Where

n= 3rd, 6th, 9th, 12th, 15th, 18th, 21st, 24th day of experiment.

Histological evaluation of wound healing

Animals were euthanized with an intracardiac injection of Propofol (Provive, El Kendi, Algeria). Samples of the scar tissue were then taken from the wound areas of each rat and were stored separately in 10% formalin solution (Formaldehyde, Sigma Aldrich, Germany) for 72h. After the usual histological treatment of the samples and their staining with hematoxylin and eosin, the prepared histological sections were subjected to microscopic observation in order to assess the degree of epithelialization, differentiation, amount of granulation tissue, inflammation, orientation of collagen fibers, and neovascularization. These observations were transformed into scores according to the modified scoring system based on previous models adapted by Sultana *et al.* (1970) and Abramov *et al.* (2007) (Table 1). Scores of histological parameters have been summed to calculate total histological score and determine which group had better healing.

Statistical analysis

Obtained results were statistically analyzed using Minitab 19 software on Windows. Means and standard deviations were calculated and then subjected to one-way analysis of variance (ANOVA) to determine the significant difference between the control group and the treatment group (*Teucrium polium*). The Dunnett's t-test was used to compare the scores recorded in both groups and a $p<0.05$ was considered as statistically significant.

RESULTS AND DISCUSSION

Wound surface and closure percentage

Results of wound area measurements and percentages of wound closure in both groups are represented in Fig 1. The macroscopic evolution of wound healing is shown in Fig 2. Treatment of wounds with *Teucrium polium* had resulted in an enhancement of wound healing and at the end of the experiment, a very small scar was noted in the TP group while in the control group an open wound was still evident as shown in Fig 2.

Indeed, in the period from the first day to the 9th day of treatment, mean wound surface of TP group has ranged

Table 1: Modified scoring system based on Sultana *et al.* (1970) and Abramov *et al.* (2007).

Histological parameters	Scores		
	1	2	3
Epithelialization	Absent	Moderate	Marked
Differentiation	Absent	Present	/
Amount of granulation tissue	Profound	Moderate	Absent
Inflammation	Severe	Moderate	Weak
Collagen fiber orientation	Vertical	Mixed	Horizontal
Neovascularization	<5/HPF	6-10/HPF	>10/HPF

HPF: High power field.

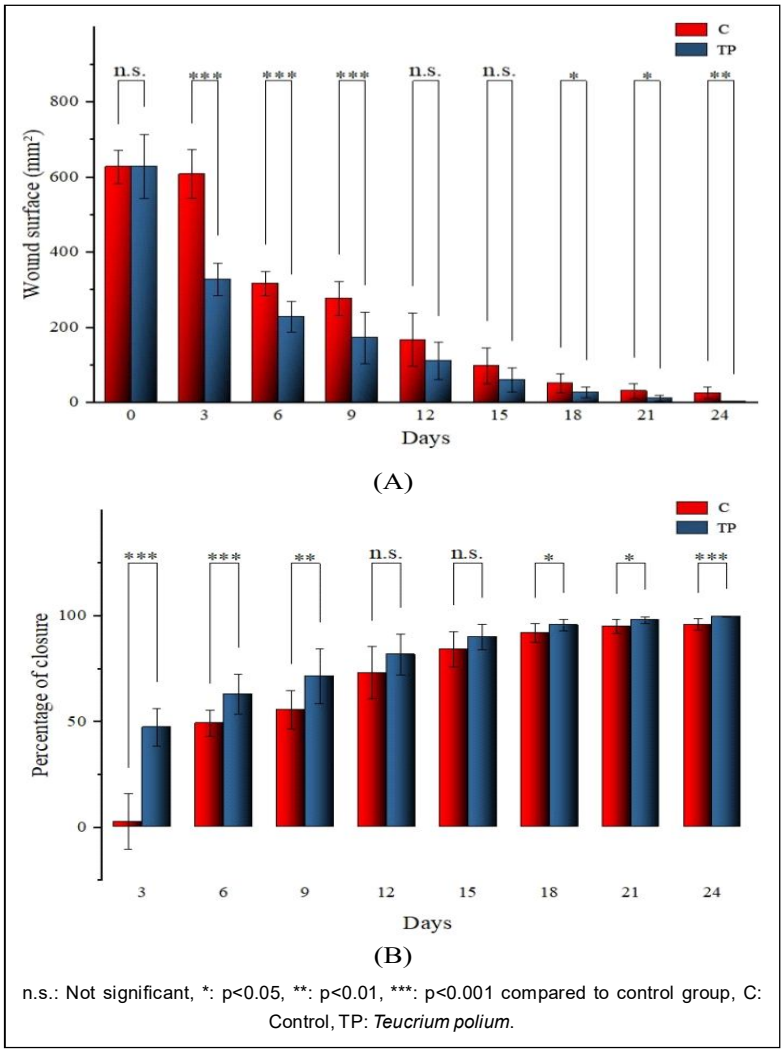

n.s.: Not significant, *: p<0.05, **: p<0.01, ***: p<0.001 compared to control group, C: Control, TP: *Teucrium polium*.

Fig 1: (A) Effect of TP application on wound surface measurement (mm^2), (B) Effect of TP application on percentage of wound closure.

from 628.82 to 172.12 mm² which represent a closure percentage of 71.49% compared to a wound surface ranging from 626.78 to 276.36 in control and which is considered as 60.17% of closure. Comparison between the values recorded during this period revealed a highly significant difference between both groups (p<0.01). These results can be explained by the support provided by the plant to the inflammatory phase of healing probably with an antimicrobial effect. Similar results have been reported by Ruiters *et al.* (2016) who proved the antibacterial activity of African species of *Teucrium*, by Fertout-Mouri *et al.* (2017) who reported that *Teucrium polium* essential oil has very excellent antimicrobial activity *in vitro* and Fallah Huseini *et al.* (2020) who stated that this herb accelerates wound healing through an effect on pro-inflammatory cytokines and by potential antioxidant activity.

In the period from the 12th to 15th day of the experiment, and even if the results of wound surface and closure percentage recorded in TP group were better than those of control, we have not noticed any significant difference between the two groups of the study (p>0.05).

From the 18th to the last day of the experiment, the difference between the two groups was found to be highly significant (p<0.01) and the mean wound surface of TP group ranged from 26.57 to 1.81 mm² which is considered as a wound closure of 99.70% compared to 95.93% in control group (50.31 to 25.21 mm²). These results can be explained by the impact of the plant on the granulation and epithelialization of wounds as mentioned by Meguellati *et al.* (2019) and Chabane *et al.* (2021). Also, Fallah Huseini *et al.* (2020) indicated that the wound healing effect of *Teucrium polium* is attributed to an increase in collagen

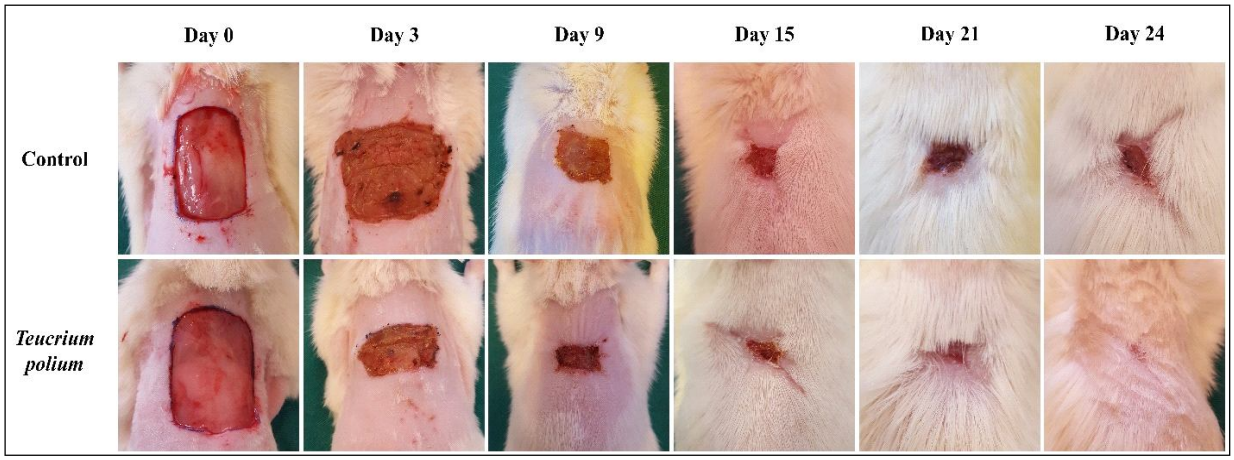

Fig 2: Images of excisional wounds from control and treated group taken on day 0, 3, 9, 15, 21 and 24 post wounding with an HD camera.

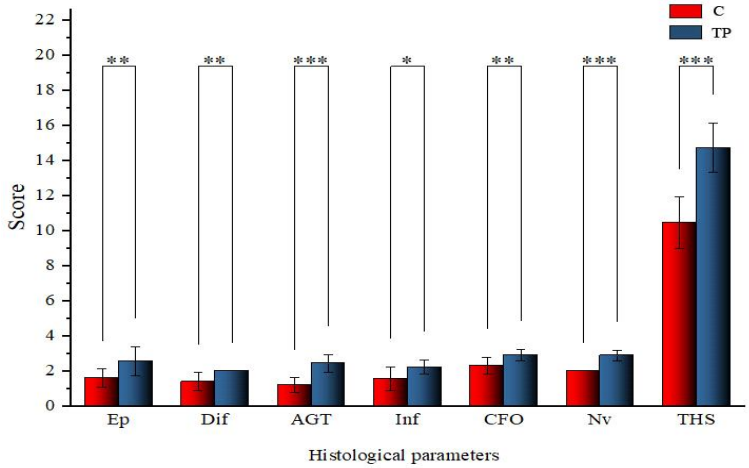

*: p<0.05, **: p<0.01, ***: p<0.001 compared to control group, C: Control, TP: *Teucrium polium*, Ep: Epithelialization, Dif: Differentiation, AGT: Amount of granulation tissue, CFO: Collagen fiber orientation, Nv: Neovascularization, THS: Total histological score.

Fig 3: Effect of TP application on histological parameters in both groups.

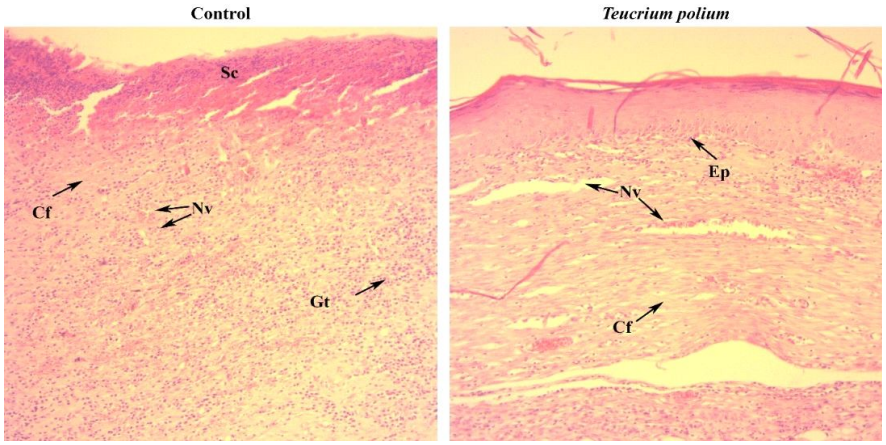

Sc: Scab; Cf: Collagen fibers; Nv: Neovascularization; Gt: Granulation tissue; Ep: Epithelialization.

Fig 4: Histological sections of wound tissue by hematoxylin (H) and eosin (E) staining after 24 days; Magnification 100X.

synthesis and angiogenesis and Gharaboghaz *et al.* (2020) stated that this plant accelerates cell proliferation by increasing the expression of glucose transporter-1 (GLUT-1), insulin-like growth factor 1 (IGF-1), basic growth factor fibroblasts (FGF-2) and vascular endothelial growth factor (VEGF).

Histological score of wound healing

As shown in Fig 3 and 4, our histological results compliment those of the macroscopic study. In fact, animals treated with *Teucriumpolium* have shown better total histological score than control group and comparison between them has revealed a highly significant difference (p<0.001). This impact of the plant on wound healing is related to the stimulation of epithelialization, differentiation, fibroblastic proliferation and neovascularization, and the regulation of inflammatory phase of wound healing. Our results are in agreement with those of Alizadeh *et al.* (2011), Fallah Huseini *et al.* (2020), Gharaboghaz *et al.* (2020) and Chabane *et al.* (2021) who all reported that *Teucrium polium* improves wound healing.

Finally, although our study demonstrates the beneficial effect of *Teucriumpolium* on wound healing, we cannot precisely attribute this effect to a well-defined component. However, research carried out on the plant has demonstrated its richness in flavonoid and phenolic components (Bakari *et al.,* 2015; Chabane *et al.,* 2021) playing an important role in wound healing (Lodhi and Singhai, 2013) and other components such as terpenes, tannins, saponins, sterols and leucoanthocyanin known for their antioxidant, antimicrobial and antiinflammatory effects (Marume *et al.,* 2017).

CONCLUSION

This study proves that *Teucriumpolium* has excellent healing activity which is mainly linked to its richness in phenolic and flavonoid compounds. However, the whole mechanism by which *Teucriumpolium* improves wound healing remains ambiguous and further studies are needed to determine the interactions between the various active ingredients of this plant. Finally, our study fully agrees with the recognized efficacy of this plant in traditional medicine.

ACKNOWLEDGEMENT

The authors are thankful to the Institute of Veterinary and Agronomic sciences, Batna 1 University and the Institute of Veterinary Sciences, University of Tiaret of Algeria.

Disclosure

The authors declare that they have no competing interests. This research did not receive any specific grant from funding agencies in the public, commercial, or not-for-profit sectors.

Conflict of interest

All authors declared that there is no conflict of interest.

REFERENCES

Abramov, Y., Golden, B., Sullivan, M., Botros, S.M., Miller, J.-J.R., Alshahrour, A., Goldberg, R.P., Sand, P.K. (2007). Histologic characterization of vaginal vs. abdominal surgical wound healing in a rabbit model. Wound Repair and Regeneration. 15: 80-86.

Alizadeh, A.M., Sohanaki, H., Khaniki, M., Mohaghgheghi, M.A., Ghmami, G., Mosavi, M. (2011). The effect of *Teucrium polium* honey on the wound healing and tensile strength in rat. Iranian Journal of Basic Medical Sciences. 14: 499-505.

Aouadhi, C., Ghazghazi, H., Brahim, H., Maaroufi, A. (2013). Secondary metabolite, antioxidant and antibacterial activities of *Teucrium polium* L methanolic extract. International Journal of Agronomy and Plant Production. 4: 1790-1797.

Bahramsoltani, R., Farzaei, M.H., Rahimi, R. (2014). Medicinal plants and their natural components as future drugs for the treatment of burn wounds: An integrative review. Archives of Dermatological Research. 306: 601-617.

Bakari, S., Ncir, M., Felhi, S., Hajlaoui, H., Saoudi, M., Gharsallah, N., Kadri, A. (2015). Chemical composition and *in vitro* evaluation of total phenolic, flavonoid and antioxidant properties of essential oil and solvent extract from the aerial parts of Teucrium polium grown in Tunisia. Food Science and Biotechnology. 24: 1943-1949.

Bhaskar Rao, A., Ernala, P., Deepthi Seelam, S., Vennapusa, H., Sistla, R., Kuncha, M., Surekha Mullapudi, V., Rao Yerramilli, S. (2015). Wound healing: A new perspective on glucosylated tetrahydrocurcumin. Drug Design, Development and Therapy. 3579.

Chabane, S., Boudjelal, A., Keller, M., Doubakh, S., Potterat, O. (2021). *Teucrium polium*-Wound healing potential, toxicity and polyphenolic profile. South African Journal of Botany. 137: 228-235.

Elzayat, E.M., Auda, S.H., Alanazi, F.K., Al-Agamy, M.H. (2018). Evaluation of wound healing activity of henna, pomegranate and myrrh herbal ointment blend. Saudi Pharmaceutical Journal. 26: 733-738.

Esmaeili, M.A. and Yazdanparast, R. (2004). Hypoglycaemic effect of Teucrium polium: studies with rat pancreatic islets. Journal of Ethnopharmacology. 95: 27-30.

Fallah Huseini, H., Abdolghaffari, A.H., Ahwazi, M., Jasemi, E., Yaghoobi, M., Ziaee, M. (2020). Topical application of *Teucrium polium* can improve wound healing in diabetic rats. The International Journal of Lower Extremity Wounds. 19: 132-138.

Fertout-Mouri, N., Latrèche, A., Mehdadi, Z., Toumi-Bénali, F., Khaled, M.B. (2017). Composition chimique et activité antibactérienne de l'huile essentielle de *Teucrium polium* L. du mont de Tessala (*Algérie occidentale*). Phytothérapie. 15: 346-353.

Gangwar, M., Gautam, M.K., Ghildiyal, S., Nath, G., Goel, R.K. (2015). Mallotus philippinensis Muell. Arg fruit glandular hairs extract promotes wound healing on different wound model in rats. BMC Complementary and Alternative Medicine. 15: 123.

Gharaboghaz, M.N.Z., Farahpour, M.R., Saghaie, S. (2020). Topical co-administration of *Teucrium polium* hydroethanolic extract and Aloe vera gel triggered wound healing by accelerating cell proliferation in diabetic mouse model. Biomedicine and Pharmacotherapy. 127: 110-189.

Jeanmonod, D. and Gamisans, J. (2007). Flora Corsica. Aix-en-Provence: Édisud.

Lodhi, S. and Singhai, A.K. (2013). Wound healing effect of flavonoid rich fraction and luteolin isolated from *Martynia annua* Linn. on streptozotocin induced diabetic rats. Asian Pacific Journal of Tropical Medicine. 6: 253-259.

Marume, A., Matope, G., Katsande, S., Khoza, S., Mutingwende, I., Mduluza, T., Munodawafa-Taderera, T., Ndhlala, A.R. (2017). Wound healing properties of selected plants used in ethnoveterinary medicine. Frontiers in Pharmacology. 8: 544.

Meguellati, H., Ouafi, S., Saad, S., Djemouai, N. (2019). Evaluation of acute, subacute oral toxicity and wound healing activity of mother plant and callus of *Teucrium polium* L. subsp. geyrii Maire from Algeria. South African Journal of Botany. 127: 25-34.

Mirzaei, A., Jaberi Hafshajani, H. (2010). Effects of hydroalcoholic extract of *Teucrium polium* on biochemical and hematological parameters of hepatotoxic rats. Yums-Armaghan. 15: 67-75.

Movahedi, A., Basir, R., Rahmat, A., Charaffedine, M., Othman, F. (2014). Remarkable anticancer activity of *Teucrium polium* on hepatocellular carcinogenic rats. Evidence-Based Complementary and Alternative. pp 1-9.

Ozenda, P. (2004). Flore et Végétation du Sahara. 3. ed. (mise à jour et augm.) de la Flore du Sahara. Paris: Ed. du Centre National de la Recherche Scientifique.

Robson, V., Dodd, S., Thomas, S. (2009). Standardized antibacterial honey (Medihoney™) with standard therapy in wound care: randomized clinical trial. Journal of Advanced Nursing. 65: 565-575.

Ruiters, A.K., Tilney, P.M., Van Vuuren, S.F., Viljoen, A.M., Kamatou, G.P.P., Van Wyk, B.-E. (2016). The anatomy, ethnobotany, antimicrobial activity and essential oil composition of southern African species of *Teucrium* (Lamiaceae). South African Journal of Botany. 102: 175-185.

Singer, A.J. and Clark, R.A.F. (1999). Cutaneous wound healing. New England Journal of Medicine. 341: 738-746.

Strecker-McGraw, M.K., Jones, T.R., Baer, D.G. (2007). Soft Tissue Wounds and Principles of Healing. Emergency Medicine Clinics of North America. 25: 1-22.

Sultana, J., Molla, M.R., Kamal, M., Shahidullah, M., Begum, F., Bashar, M.A. (1970). Histological differences in wound healing in Maxillofacial region in patients with or without risk factors. Bangladesh Journal of Pathology. 24: 3-8.

Tatar, M., Qujeq, D., Feizi, F., Parsian, H., Sohan Faraji, A., Halalkhor, S., Abassi, R., Abedian, Z., Pourbagher, R., Aghajanpour Mir, S.M., Mir, H., Seyfizadeh, N. (2012). Effects of *Teucrium polium* aerial parts extract on oral glucose tolerance tests and pancreas histopathology in Streptozocin-induced diabetic rats. International Journal of Molecular and Cellular Medicine. 1: 44-49.