RESEARCH ARTICLE Agricultural Science Digest, Volume 43 Issue 4: 562-567 (August 2023)

Virological and Pathological Diagnosis of Canine Oral *Papillomavirus* in Dogs and Evaluation of Treatment Applications

Sevinc Kant[1], Y. Sinan Orta[1], Mehmet Kale[1], Yakup Yildirim[1], Ozlem Ozmen[2], Kamil Atli[1], H. Sait Saltik[1]

10.18805/ag.DF-526

ABSTRACT

Background: The canine oral papillomavirus (CoPV) is the cause of oral papillomatosis in all dogs. The purpose of this study is to compare two treatment methods after virological and pathological diagnosis of oral papillomas.

Methods: Blood samples were collected from 50 owned and stray dogs of various breeds. The presence of CoPV antigen (Ag) in the blood samples investigated. Tissue samples from the papilloma mass were collected for auto vaccination and histopathological examination. CoPV (Ag) was found in the blood of dogs with papilloma lesions who were randomly divided and treated into two groups. While group 1 receives autologous vaccines and immune-supportive Zylexis™, Group 2 receives PAPILEND™® cream, immune-boosting Zylexis™ and premix powder (vitamin E, zinc, selenium, copper).

Result: The dogs have an average age of 31.9+7.4 months. CoPV (Ag) was detected in half of all dogs with papilloma lesions. The histopathological examination typically revealed an increased epidermal layer. In the treatment of group 1, the mean remission period was 21-30 days. This period was determined to be 15-30 days in 15 animals from the second treatment group. Lesions were successfully treated in all dogs with CoPV (Ag) in both groups. The combination of PAPILEND™® cream, immune-supportive Zylexis™ and premix powder was found to shorten the disease remission period caused by CoPV oral lesions.

Key words: Canine oral papillomavirus, Dog, PAPILEND™®, Treatment.

INTRODUCTION

The *Papillomaviridae* family of viruses includes the small, non-enveloped, icosahedral papillomavirus (PV). The virus has a paracrystalline line in the cell nucleus and is tissue and species-specific (Campo, 2006; Modis *et al*., 2002; Nicholls and Stanley, 2000).

In dogs, PVs are the cause of oral papilloma, cutaneous papilloma and canine viral pigmented plaques. Species-specific CoPV has three genera as Lambda, Tau and Chi. Oral papillomas in dogs are caused by CPV-1 as well as CPV-13. In addition to benign papillomas, it has also been reported as a causative agent for squamous cell carcinoma (SCC). It is known that HPV is the causative agent of cervix carcinomas in humans. CPV-16 has also been reported in association with SCC in dogs; however, there are few studies about this subject (Chang *et al*., 2020; Sancak *et al*., 2015). PVs are becoming more significant for both human and animal health as a result of their developmental roles into malignancy.

Oral papillomas, frequently seen in young dogs, are in the exophytic vegetative form. The contagious virus is transmitted by contact with an infected dog or by contaminated equipment and fomites. The majority of cases are sporadic; however, outbreaks can also occur. Typically, there are no systemic symptoms, but in excessive distributions, it can prevent breathing and feeding (Chang *et al*., 2020; Kale *et al*., 2018; Lane *et al*., 2017; Munday *et al*., 2017).

Histopathological, immunohistochemical, in situ hybridization, electron microscopy and PCR methods are used for virus detection in oral papillomas although it can be diagnosed according to their clinical appearance. Antibody detection by ELISA in blood and serum samples indicates previous infection, while antigen detection determines infection (Kale *et al*., 2018; Lane *et al*., 2017; Lange *et al*., 2009).

Benign papillomas show spontaneous remission. The period of remission varies from one month to one year. The high antibody level (87.5%) in oral papillomas in which the virus is detected and it reveals the importance of immunity in remission (Sancak *et al*., 2015). Although papillomas that often develop in the mouth area in dogs show spontaneous remission, their treatment varies according to their distribution and size. Usually, it is surgically excised and

[1]Department of Virology, Faculty of Veterinary Medicine, Burdur Mehmet Akif Ersoy University, Burdur, Turkey.
[2]Department of Pathology, Faculty of Veterinary Medicine, Burdur Mehmet Akif Ersoy University, Burdur, Turkey.

Corresponding Author: Mehmet Kale, Department of Virology, Faculty of Veterinary Medicine, Burdur Mehmet Akif Ersoy University, Burdur, Turkey. Email: drmkalex@yahoo.com

How to cite this article: Kant, S., Orta, Y.S., Kale, M., Yildirim, Y., Ozmen, O., Atli, K. and Saltik, H.S. (2023). Virological and Pathological Diagnosis of Canine Oral *Papillomavirus* in Dogs and Evaluation of Treatment Applications. Agricultural Science Digest. 43(4): 562-567. doi: 10.18805/ag.DF-526.

Submitted: 14-12-2022 **Accepted:** 16-05-2023 **Online:** 06-06-2023

cryosurgery may be applied. Various treatment methods are being tried in order to shorten the recovery period. Autogenous vaccine, homeopathy, immunotherapy, various antibiotic and antiviral drug trials have been reported. These are in the choice of combined treatments (Moore *et al*., 2003; Raj *et al*., 2020; Yagci *et al*., 2008). Topical cream applications are in successful treatment methods and their effects have also been reported as an alternative to invasive procedures (Kale *et al*., 2018; Williams *et al*., 2021). The fact that the remission period of oral papillomas is variable and long and their recurrence shows also reveals the importance of the epidemic potential of treatment. Studies on this subject will also guide the epidemiology of CoPVs and the treatment of benign and malignant diseases they cause.

In this study, treatment methods after virological and pathological diagnosis of papillomas in dogs were compared. The effectiveness of the developed treatment method will shed light on the developments for the treatment of malignant lesions caused by CoPVs in humans and animals.

MATERIALS AND METHODS

This study was done by Department of Virology at Veterinary Faculty, The Burdur Mehmet Akif Ersoy University. Experiment period had done for this study on March-May 2021.

Samples

Blood samples from 50 owned and stray dogs of various breeds were taken from the ramus dorsalis of *vena saphena parva*. The serum from the blood samples that were sent to the lab was prepared and kept at -80°C.

Virologic diagnosis

The presence of CoPV (Ag) in the collected blood samples was examined with the CPV ELISA kit (My Bio Source Inc., Cat. No: MBS2603159, San Diego, USA). The test was carried out according to the manufacturer instructions.

Histopathology method

Tissue samples taken from the papillomas were fixed in 10% neutral formalin solution. Then, routinely processed by a fully automatic tissue processing device (Leica ASP300S; Leica Microsystem, Nussloch, Germany) and embedded the paraffin wax. Serial sections of 5 µm thickness were taken from the paraffin blocks by a Leica 2155 rotary microtome. Sections were stained with hematoxylin-eosin (HE) and examined under a light microscope.

Treatment protocol

Dogs with papilloma were randomly divided into two groups by drawing lots and two treatment methods were applied. 1) As treatment 1, autologous vaccines prepared with the Hunt (1984) protocol and immune supportive Zylexis™ were applied. 2) PAPILEND™® cream, immune-supportive Zylexis™ and premix powder (vitamin E, zinc, selenium, copper) were used as treatment 2. Ten dogs were treated with the treatment 1 protocol and 15 dogs with the treatment 2 protocol. The remission period of the papillomas was followed.

RESULTS AND DISCUSSION

The mean age of the dogs participating in the study was 31.9+7.4 months and 66% were male. Totally, 69% of the dogs of the different breeds involved in the study were owned. CoPV Ag was detected in 50% of the serum of dogs with papillomatous lesions (Table 1). On 25 animals whose CoPV Ag was found, treatment regimens were used. In the treatment 1 protocol, the remission period was determined as 21-30 days in 10 animals whose CoPV Ag presence was determined. In the treatment 2 protocol, this period was 15-30 days in 15 animals whose CoPV Ag presence was diagnosed. Lesions were successfully treated in all dogs with the presence of CoPV Ag in both groups (Table 2), (Fig 1-5).

The histological analysis revealed a substantial increase in the epidermal layer and marked epithelial proliferation.

Table 1: Distribution of the dog breed according to age, sex and positivity of CoPV Antigen.

Breeds	Age (mean)	Sex		CoPV positivity (%)
		♂	♀	
German shepherd dog	4-6 month	2	3	-
Drahthaar hybrid	36 months	1	-	-
Anatolian sheep dog	10-24 month	6	-	6 (24%)
Cocker spaniel	6-12 month	2	2	-
Rottweiler	10-48 month	5	-	5 (20%)
Bichon yorkie	10-24 month	4	3	-
Border collie	48 months	1		-
Chow chow	12-24 month	3	2	3 (12%)
Golden retriever	12 months	1		-
Pointer	4-24 month	3		3 (12%)
Stray dog	6-48 month	6	2	6 (24%)
Terrier	36-180 month	3	2	2 (8%)
Total		36	14	25 (100%)

CoPV: Canine oral papillomavirus, ♂: Male, ♀: Female.



(A: Before treatment; B: After treatment)

Fig 1: CoPV infected dog, treatment 1 results.

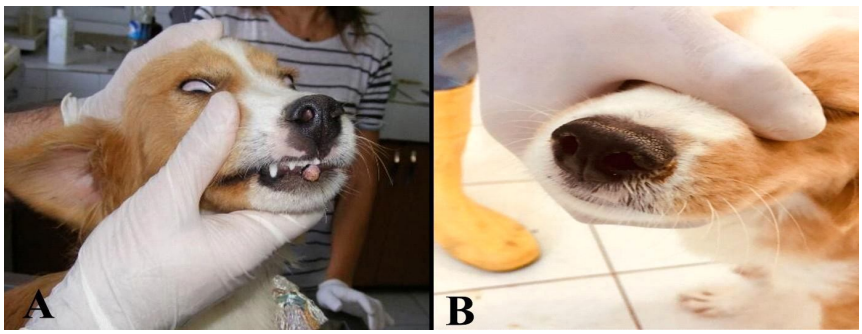

(A: Before treatment; B: After treatment)

Fig 2: CoPV infected dog, treatment 2 results.

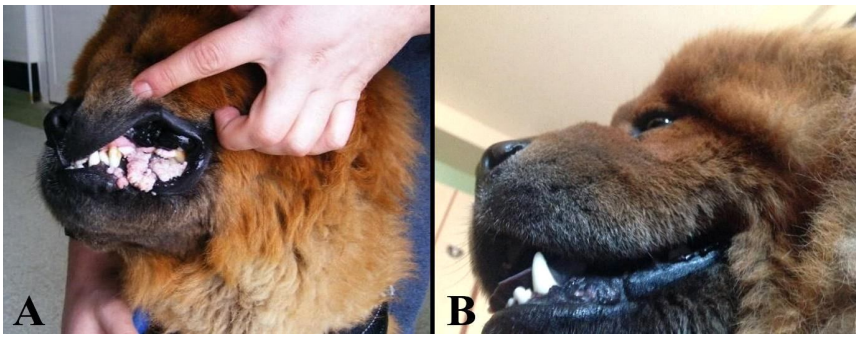

(A: Before treatment; B: After treatment)

Fig 3: CoPV infected dog, treatment 2 results.



(A: Before treatment; B: After treatment)

Fig 4: CoPV infected dog, treatment 2 results.

The thickness of epidermis was a characteristic finding. The proliferated epithelial cells included many keratohyalin granules. The keratinocytes of stratum granulosum or spinosum had big nuclei and some of the cells that were losing their nuclei displayed eosinophilic intranuclear inclusion bodies (Fig 6).

In both people and animals, papillomas that lead to recurring infections can result in benign and malignant tumors. Papillomas are more commonly localized in the head and neck areas of dogs. Whereas cutaneous papillomas are verrucous and hyperkeratotic; mucosal papillomas (eyes, mouth and other mucosal areas) are cauliflower-like lesions. The infection, which has no definitive treatment, heals spontaneously in 3-12 months if not intervened (Williams *et al*., 2021; Chang *et al*., 2020; Yagci *et al*., 2008). Although papillomas are self-limiting, because of the prevention of feeding, CoPV-related anorexia and halitosis in dog hospices have been reported (Lane *et al*., 2017; Yhee *et al*., 2010). CoPV1 was detected in a 3-year-old Labrador retriever dog and oral squamous cell carcinoma with oral papilloma malignant transformation originated at the level of the left mandibular first molar was reported (Regalado Ibarra *et al*., 2018). It has been stated that more animals are affected in the outbreaks and the risk of malignancy increases in immunocompetent dogs. Therefore, it is important to develop an effective treatment to reduce secondary papilloma-related conditions. Studies have shown that environmental factors along with CoPV genotypes are important in malignant transformation (Chang *et al*., 2020; Thaiwong *et al*., 2018). This situation reveals the necessity of effective treatment of lesions in a short time.

CoPV-induced papillomas in dogs are generally seen in the younger age group, regardless of breed or gender (Head *et al*., 2002). Oral papillomas have been reported in dogs of all age groups (Agut *et al*., 1996; Chang *et al*., 2020; Kalita *et al*., 2022; Nemec *et al*., 2014; Yhee *et al*., 2010). Contrary to this situation, Thaiwong *et al*. (2018) examined 349 papilloma cases during the 10 years and determined the mean age as 8.5 in 9 malignant cases in which CoPV was detected. Nemec *et al*. (2014) reported that ¾ of dogs with SCC were older than 6 years of age. This situation reveals that papillomas are more common and the risk of malignancy increases due to the decrease in immune response as age progresses. In our study, the average age

Table 2: Treatment results of COPV ELISA Ag (+) dogs.

Treatment results	Treatment 1¥	Treatment 2£
Successful	10	15
Unsuccessful	-	-
Total	10	15

¥Treatment 1: Autologous vaccination + immune supportive (zylexis); £Treatment 2: Papilend™,® ointment + immune supportive (Zylexis™) + premix powder (vitamin E, zinc, selenium, cupper).

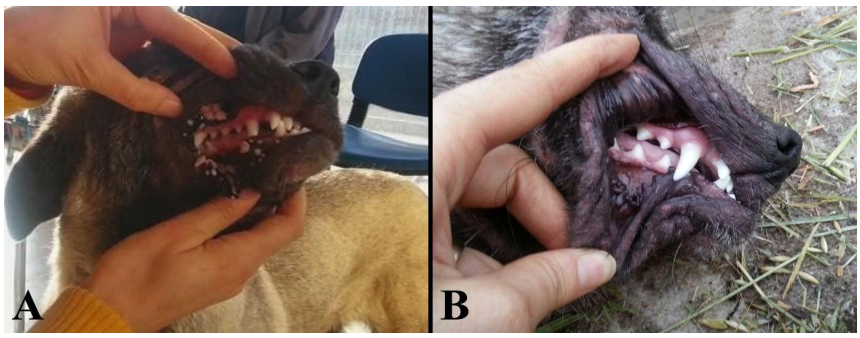

(A: Before treatment; B: After treatment)

Fig 5: CoPV infected dog, treatment 2 results.

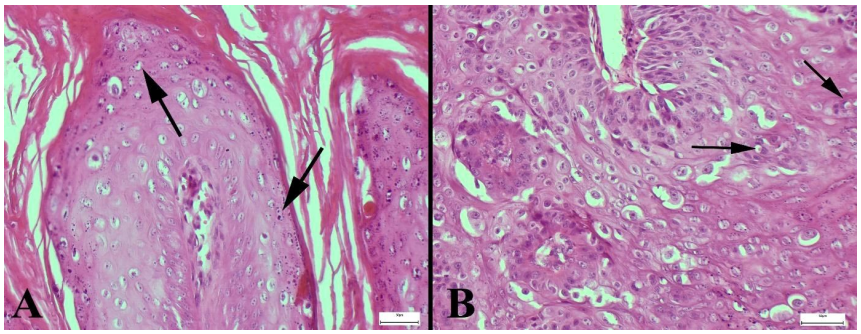

(A) Proliferated epithelial cells and keratohyalin granules (arrows), (B) Intracytoplasmic inclusion bodies (arrows) in the epithelial cells, HE, Scale bars=50 µm.

Fig 6: Histopathological appearance of the canine oral papilloma.

of the dogs was determined as 31.9+7.4 months and there was no clustering in a certain age group.

Studies have revealed that no particular breed predisposes for CoPV infection. Cases have been reported in many dog breeds such as Labrador Retriever, Rottweiler, Cavalier King Charles Spaniel, Parson Russell Terrier and Newfoundland (Regalado Ibarra *et al*., 2018). Papillomas were seen in many breeds such as Rottweiler, Cavalier King Charles Spaniel, Parson Russell Terrier, Newfoundland (Bredal *et al*., 1996; Brandes *et al*., 2009). Although PVs are species specific, they do not differ in dog breeds. In this study, CoPV was detected in half of the dogs with papillomas belong the different breeds. Although the virus is species specific, it infects all dog breeds.

Although papillomas are self-limiting lesions, it is important to treat them because of their more frequent localization in the oral cavity, their prevalence and malignant transformation. Numerous researches have been done and are being done on various treatment methods. Surgical treatment can be chosen according to the size, distribution and localization of oral papillomas of dogs. However, studies on treatment protocols that provide ease of application come to the fore. For this purpose, immunomodulatory agents (imiquimod) are recommended (Lange and Favrot, 2011). After the fifth dose, regression of papillomas was observed after intravenous administration of taurolidine (45 mg/kg) every 3 days to a 1-year-old coiled dog with clinical, histopathological and immunohistochemical CoPV detected (Biricik *et al*., 2008). In medical treatments, it should contain antiviral effects and formulations to prevent recurrence. Such treatments will also shed light on the treatment of human papillomas.

Vaccination is the most effective and inexpensive way to prevent viral diseases. Vaccines are also used for therapeutic aim. Therefore, autogenous vaccines are more commonly used. Inactivation of autogenous vaccine obtained from infected tissue is done by various methods. Agut *et al.* (1996) performed autogenous vaccine inactivation by temperature increase instead of formalin and reported that they achieved 100% success with vaccination in nine dogs aged between 3-7 years. At the same time, they reported that the development of chemical contamination could be prevented as a result of inactivation with heat (Agut *et al*., 1996). The codon E2 vaccine obtained from CoPV E protein was found to be effective as a therapeutic vaccine (Moore *et al*., 2003). Although studies have shown that vaccines are effective against papillomas, they are not commercially available in the market (Lange and Favrot, 2011). In treatment 1, which is one of the treatment protocols compared in the study, 100% success was achieved in 10 animals that received autologous vaccine and immune-supportive Zylexis™. We speculate that humoral immunity developed in animals as a result of the application of this treatment protocol.

In young dogs, benign epithelial papillomas are more like cauliflower. As these lesions are widespread and break easily, many complications can be seen. It is important for the owners/caregivers of the animals that the treatment applications can be made easily in terms of the rapid regression and recovery of the disease. After the application of homeopathic agent (*Thuja occidentalis*), injectable lithium antimony thiomalate, autohomeopathy and topical 15% zinc oxide protocol in CoPV infected dogs for four weeks, full recovery was observed and it was recommended as a treatment protocol (Kalita *et al*., 2022). In another study, it was reported that the lesions regressed in a short time with azithromycin application and there was no recurrence in the 8-month follow-up period (Yagci *et al*., 2008). Marins (2011) reported that combined therapy (autogenous vaccine, *Thuja occidentalis* homeopathy and immunotherapy) was successful in CoPV-infected dogs and no recurrence was observed in the two-year follow-up period. In a study investigating the experimental effects of topical antiviral agents, 2% cidofovir ointment was found to be effective in the treatment of cottontail rabbit papillomavirus (Christensen *et al*., 2014). Divya *et al.* (2015) reported that combined treatment including Thuja (homeopathy), autoimmune therapy (serum) and topical application of podowart, apple cider vinegar was ineffective in Rottweiler dog with massive papilloma lesion on the face. After this treatment, a rapid recovery and regression of papillomas have been reported after five doses of lithium antimony thiomolate at a dose of 0.5 ml intramuscularly (Divya *et al*., 2015).

CONCLUSION

Immunity and contaminated fomites may be effective in the frequent development of CoPV-induced oral warts in dogs. In these animals, it was determined that both autologous vaccine and immune-supporting Zylexis™ application and the combined use of topical cream and immune-supporting premix powders gave successful results in the treatment.

ACKNOWLEDGEMENT

†A part of this study is the XV. Presented orally at the National Veterinary Microbiology Congress held on 26-28 October 2022, in Şanlıurfa, Turkey.

Conflict of interest: None.

REFERENCES

Agut, M., Bayo, M., Larrondo, J., Calvo, M.A. (1996). Autovaccination as a treatment in canine papillomavirus dermatological disease: A study of nine cases. Biomedical Letters. 54: 23-26.

Biricik, H.S., Cabalar, M., Gulbahar, M.Y. (2008). Oral papillomatosis in a dog and its therapy with taurolidine. Acta Veterinaria Brno. 77: 373-375. DOI: 10.2754/avb200877030373.

Brandes, K., Fritsche, J., Mueller, N., Koerschge, B., Dierig, B., Strebelow, G., Teifke, J.P. (2009). Detection of canine oral papillomavirus DNA in conjunctival epithelial hyperplastic lesions of three dogs. Veterinary Pathology. 46: 34-38. DOI: 10.1354/vp.46-1-34.

Bredal, W.P., Thoresen, S.I., Rimstad, E., Aleksandersent, M., Nafstadt, P.H.J. (1996). Diagnosis and clinical course of canine oral *papillomavirus* infection. Journal of Small Animal Practice. 37: 138-142.

Campo, M.S. (2006). Bovine Papillomavirus: Old System, New Lessons? In: Papillomavirus Research: From Natural History to Vaccine and Beyond. [Campo, M.S. (Eds)], Chapter 23, England: Caister Academic Press. pp: 459-472.

Chang, C.Y., Chen, W.T., Haga, T., Yamashita, N., Lee, C.F., Tsuzuki, M., Chang, H.W. (2020). The detection and association of canine papillomavirus with benign and malignant skin lesions in dogs. Viruses. 12: 170. DOI: 10.3390/v12020170.

Christensen, N.D., Cladel, N.M., Hu, J., Balogh, K.K. (2014). Formulation of cidofovir improves the anti-papillomaviral activity of topical treatments in the CRPV/rabbit model. Antiviral Research. 108: 148-155. DOI:10.1016/j.antiviral.2014.06.001.

Divya, A., Manoj, K., Tarun, K., Parmod, K., Ankit, K., Neelesh, S. (2015). Successful therapeutic management of a case of canine papillomatosis. Haryana Veterinarian. 54: 79-80.

Head, K.W., Else, R.W., Dubielzig, R.R. (2002). Tumors of the Alimentary Tract. In: Tumors in Domestic Animals. [Meuten, D.J. (ed.)]. (4th Edn.) Iowa State University Press, Ames. pp. 422- 423.

Hunt, E. (1984). Fibropapillomatosis and papillomatosis. Veterinary Clinics of North America: Large Animal Practice. 6: 163-167.

Kale, M., Mamak, N., Saltık, H.S., Çınar, H., Yavru, S., Bütüner, O., Çalış, A., Çankar, A., Katırcı, H. (2018). The diagnosis and treatment of canine oral papillomavirus derived wart case in a stray dog. Göller Bölgesi Aylık Hakemli Ekonomi ve Kültür Dergisi Ayrıntı. 5: 39-43.

Kalita, J.C., Verma, P., Jakhar, J., Patidar, S. (2022). Case report on therapeutic management of canine oral papillomatosis. International Journal of Pharmaceutical Research and Applications. 7: 385-389.

Lane, H.E., Weese, J.S., Stull, J.W. (2017). Canine oral papillomavirus outbreak at a dog daycare facility. The Canadian Veterinary Journal. 58: 747-749.

Lange, C.E. and Favrot, C. (2011). Canine papillomaviruses. Veterinary Clinics: Small Animal Practice. 41: 1183-1195. DOI: 10.1016/j.cvsm.2011.08.003.

Lange, C.E., Tobler, K., Favrot, C., Muller, M., Nothling, J.O., Ackermann, M. (2009). Detection of antibodies against epidermodysplasia verruciformis-associated canine papillomavirus 3 in sera of dogs from Europe and Africa by enzyme-linked immunosorbent assay. Clinical and Vaccine Immunology. 16: 66-72. DOI: 10.1128/CVI.00346-08.

Marins, R. (2011). Inactivated autogenous vaccine associated with hemotherapy and application of Thuya occidentalis in the homeopathic treatment of canine oral papillomatosis a case report. International Research Journal of Pharmacy and Pharmacology. 1: 7-11.

Modis, Y., Benes, L., Stephen, C. (2002). Atomic model of the papillomavirus capsid. The Embo Journal. 21: 4754-4762. DOI: 10.1093/emboj/cdf494.

Moore, R.A., Walcott, S., White, K.L. Anderson, D.M., Jain, S., Lloyd, A., Topley, P., Thomsen, L., Gough, G.W., Stanley, M.A. (2003). Therapeutic immunisation with COPV early genes by epithelial DNA delivery. Virology. 314: 630-635. DOI: 10.1016/S0042-6822(03)00465-3.

Munday, J.S., Thomson, N.A., Luff, J.A. (2017). Papillomaviruses in dogs and cats. The Veterinary Journal. 225: 23-31. DOI: 10.1016/j.tvjl.2017.04.018.

Nemec, A., Murphy, B.G., Jordan, R.C., Kass, P.H., Verstraete, F.J.M. (2014). Oral papillary squamous cell carcinoma in twelve dogs. Journal of Comparative Pathology. 150: 155-161. DOI:10.1016/j.jcpa.2013.07.007.

Nicholls, P.K. and Stanley, M.A. (2000). The immunology of animal papillomaviruses. Veterinary Immunology and Immunopathology. 73: 101-127. DOI: 10.1016/s0165-2427(99)00165-8.

Raj, P.A.A., Pavulraj, S., Kumar, M.A., Sangeetha, S., Shamugapriya, R., Sabithabanu, S. (2020). Therapeutic evaluation of homeopathic treatment for canine oral papillomatosis. Veterinary World. 13: 206-213. DOI: 10.14202/vetworld.2020.206-213.

Regalado Ibarra, A.M., Legendre, L., Munday, J.S. (2018). Malignant transformation of a canine papillomavirus type 1-induced persistent oral papilloma in a 3-year-old dog. Journal of Veterinary Dentistry. 35: 79-95. DOI: 10.1177/0898756418774575.

Sancak, A., Favrot, C., Geisseler, M.D., Müller, M., Lange, C.E. (2015). Antibody titres against canine papillomavirus 1 peak around clinical regression in naturally occurring oral papillomatosis. Veterinary Dermatology. 26: 57-59. DOI: 10.1111/vde.12189.

Thaiwong, T., Sledge, D.G., Wise, A.G., Olstad, K., Maes, R.K., Kiupel, M. (2018). Malignant transformation of canine oral papillomavirus (CPV1)-associated papillomas in dogs: An emerging concern? Papillomavirus Research. 6: 83-89. DOI: 10.1016/j.pvr.2018.10.007.

Williams, A., Scally, G., Langland, J. (2021). A topical botanical therapy for the treatment of canine papilloma virus associated oral warts: A case series. Advances in Integrative Medicine. 8: 151-154. DOI: 10.1016/j.aimed.2020.12.003.

Yagci, B.B., Ural, K., Ocal, N., Haydardedeoglu, A.E. (2008). Azithromycin therapy of papillomatosis in dogs: A prospective, randomized, double-blinded, placebo-controlled clinical trial. Veterinary Dermatology. 19: 194-198. DOI:10.1111/j.1365-3164.2008.00674.x.

Yhee, J.Y., Kwon, B.J., Kim, J.H., Yu, C.H., Im, K.S., Lee, S.S., Lyoo, S.S., Chang, B.J., Sur, J.H. (2010). Characterization of canine oral papillomavirus by histopathology and genetic analysis in Korea. Journal of Veterinary Science. 11: 21-25. DOI: 10.4142/jvs.2010.11.1.21.