RESEARCH ARTICLE Asian Journal of Dairy and Food Research, Volume 40 Issue 2: 177-180 (June 2021)

Cow Brain Consumption Causes Hypercholesterolemia: An in Vivo Study

Swarup Kumar Kundu[1,2], Md. Abu Hadi Noor Ali Khan[3], Shonkor Kumar Das[2]

10.18805/ajdfr.DR-216

ABSTRACT

Background: Organ meats are rich in cholesterol and saturated fats. The experiment was conducted to investigate the effects of cow brain consumption on blood cholesterol level and possible histomorphological changes of liver, heart and kidney in Swiss albino mice.

Methods: Total twenty (20) Swiss albino mice (aged 3 weeks; average weight 20-25gm) were taken and randomly divided into group A and group B. Each group consisted of ten (10) mice. The group A was fed with normal mice pellet and water. On the other hand, cow brain (2gm/kg body weight orally once daily for 28 days) was supplied to group B. After the experimental tenure, the mice of both groups were sacrificed ethically and the samples (Blood, liver, heart and kidney) were collected for investigation.

Result: Total cholesterol (TC), triglyceride level (TG) and low density lipoprotein level (LDL) significantly (*$p<0.01$*) increased as well as high density lipoprotein level (HDL) significantly (*$p<0.01$*) decreased in group B. In the gross observation, pale with hemorrhagic liver, fat accumulation at the base of the heart and peri renal fat deposition were found in group B of mice. Congestion and dilation in both central and portal vein, marked lymphocytic infiltration and fatty infiltration in liver, wide separation of cardiac muscle fiber in ventricular myocardium, glomerular and tubular fatty infiltration of kidney were also found in histomorphological study. Therefore, the present findings presage that cow brain consumption might have baleful effects on health.

Key words: Cow brain, Health risk, Hypercholesterolemia, Pathological changes, Swiss albino mice.

INTRODUCTION

Dietary fats provide essential fatty acids which are not made by the body, commonly obtained from food such as beef fat, red meat, poultry products (Lichtenstein *et al.,* 2006). Beef fat contains larger amount of saturated fatty acids (SFAs), trans fatty acids and very small amount of polyunsaturated fatty acids (PUFAs). This type of fat may increase the risk of heart disease by increasing low density lipoprotein (LDL) cholesterol (Lichtenstein *et al.,* 1998). Cow brain is a full package of essential nutrients like iron and protein but low in carbohydrates. There are many ways to prepare cow brain as a food items such as burger, cow brain curry, cow brain bhuna, cow brain soup *etc.* Cow brain also contains docosahexaenoic acid or DHA. It is especially rich in selenium and copper. Cattle brain also contains beneficial vitamins especially vitamin B-5, B-12 and about 29% fats. This cow brain is also a highly source of cholesterol (Ailhaud *et al.,* 2006). Consumption of high fat diet induces excessive weight gain that can lead to metabolic complications as well as increased risk of fatty liver diseases and cardio vascular disease (Cho *et al.,* 2012).Trans fatty acid raise plasma low-density lipoprotein (LDL) cholesterol, triglyceride (TG) levels and reduce high density lipoprotein (HDL) cholesterol level (Katan *et al.,* 1995). This hypercholesterolemia causes tubular damage and inhibits filtration rate that creates protein loss and renal tubular luminal leak with fat droplets accumulation at tubular cells (Salim *et al.,* 2018). Excess cardiac interstitial fibrosis as well as low contractile activity of myocardium lead to cardiac dysfunction and heart failure (Han *et al.,* 2018). Hence, this study was undertaken to highlight the harmful effects of cow brain consumption on health.

Department of Anatomy and Histology, Faculty of Veterinary Science, Bangladesh Agricultural University, Mymensingh-2202, Bangladesh.
[1]Department of Anatomy and Histology, Faculty of Veterinary, Animal and Biomedical Sciences, Khulna Agricultural University, Khulna, Bangladesh.
[2]Department of Anatomy and Histology, Faculty of Veterinary Science, Bangladesh Agricultural University, Mymensingh-2202, Bangladesh.
[3]Department of Pathology, Faculty of Veterinary Science, Bangladesh Agricultural University, Mymensingh-2202, Bangladesh.

Corresponding Author: Swarup Kumar Kundu, Department of Anatomy and Histology, Faculty of Veterinary, Animal and Biomedical Sciences, Khulna Agricultural University, Khulna, Bangladesh. Email: swarupkundu@kau.edu.bd

How to cite this article: Kundu, S.K., Khan, M.A.H.N.A. and Das, S.K. (2021). Cow Brain Consumption Causes Hypercholesterolemia: An in Vivo Study. Asian Journal of Dairy and Food Research. 40(2): 177-180. DOI: 10.18805/ajdfr.DR-216.

Submitted: 26-12-2020 **Accepted:** 19-03-2021 **Online:** 14-04-2021

MATERIALS AND METHODS

Statement of the experiment

The experiment was carried out during the period of August 2018 to March 2019, in the Department of Anatomy and Histology, Faculty of Veterinary Science, Bangladesh Agricultural University, Mymensingh-2202, Bangladesh. The samples were also processed in the same laboratory.

Rearing and care of the experimental animal

Cow brain was collected from the local market of Mymensingh, Dhaka, Bangladesh. Total twenty (20) Swiss albino mice of

either sex were purchased from the Department of Pharmacy, Jahangirnagar University, Dhaka and the mice were adapted at Animal Care Room in the Department of Anatomy and Histology, Faculty of Veterinary Science, Bangladesh Agricultural University for the period of 7 days before being used for the experiment.

Experimental procedure

Mice were randomly selected and divided into two (2) groups, group A and group B. Each group consisted of ten (10) mice. Standard mice-pellets (collected from ICDDR, B) and water was supplied as normal feed to the group A of mice. On the other hand, cow brain (2 gm/kg body weight) was mixed with mice pellets and supplied to the group B of mice for 28 days.

Sample collection

After the experimental tenure (28 days), mice from each group were sacrificed ethically and samples (blood, liver, kidney and heart) were collected in order to investigate the biochemical, gross and histological study. Finally Haematoxylin and Eosin (H&E) staining was done for histological study.

Preparation of serum

Blood sample was collected by sacrificing the mice. The mice were placed in an air tight container one by one containing chloroform presoaked cotton. They were checked for unconsciousness. Then mice were taken out and the blood was collected directly from heart by a sterile syringe. About 1.5ml of blood was collected and transferred to eppendrof tube without adding anticoagulant for serum preparation. The blood containing tube was placed in upright slanting position at room temperature for 6 hours. They were then incubated overnight in the refrigerator (4°C). The serum samples were separated by centrifugation and collected by using 200µl pipette. Serum sample were stored in capped tube at -20°C for biochemical study.

Statistical analysis

All the collected data were stored in Microsoft Excel 2013 and analysed by using Statistical Package for the Social Sciences (SPSS; version 20) software and reveal the results in tabular form. Statistical analysis was performed using one-way analysis of variance (ANOVA). Results were expressed as mean ± SEM. The differences were considered statistically significant at $^{**}p<0.01$ and $^{*}p<0.05$ level.

RESULTS AND DISCUSSION

Biochemical analysis

The results of serum biochemical tests are given in Table 1. In the present research, there were significant changes found in TC, TG, LDL and HDL level of group B compared to group A. In this research total cholesterol (TC) and total triglyceride (TC) level significantly increased (Fig 1 and Table 1) in cow brain consumed group B (179.044± 0.412); (231.294± 0.258 mg/dl) than group A (141.296±0.318); (115.108±1.067mg/dl). This finding is in agreement with Garg and Blake, (1997); Jeffery *et al.* (1996) and Akter *et al.* (2013) who found that high level of fat in diet increases the concentration of serum total cholesterol (TC) as well as total triglyceride (TC) level compared to normal. High Density Lipoproteins (HDL) level decreases (Fig 1 and Table 1) in cow brain consumed group B (78.906 ± 0.417mg/dl) of mice than group A of mice (94.481± 0.395mg/dl). Colandre *et al.* (2003) and Ibrahim *et al.* (2018) showed that trans fatty acids increase triglyceride, total cholesterol and low density lipoprotein but decrease high density lipoprotein level. Low Density Lipoproteins (LDL) level increases (Fig 1 and Table 1) in cow brain consumed group B (46.544 ± 0.203mg/dl) of mice than group A of mice (24.892± 0.273mg/dl). The result is also similar with Lichtenstein *et al.* (1998) who reported that diet high in saturated fatty acids and trans fatty acids increase LDL cholesterol levels.

Gross observations

The results of the current study revealed that in gross observation, normal morphological appearance (Reddish, smooth and shiny) of liver, heart and kidney were found in the group A of mice. On the other hand, pale and hemorrhagic liver, fat accumulation at the base of the heart and peri renal fat deposition were found in the group B of

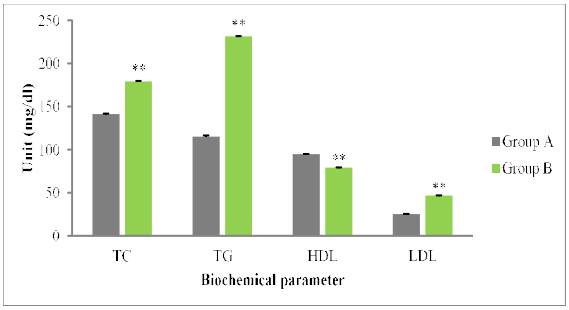

Fig 1: Total cholesterol (TC), total triglyceride (TG), low density lipoprotein (LDL) level increased significantly along with high density lipoprotein (HDL) level significantly decreased in group B. Results are represented as mean ± SEM ($^{**}p< 0.01$ significant difference) compared with the group A.

Table 1: Effects of cow brain consumption on serum biochemical parameter.1234567890-DFNM.

Biochemical parameters	Mean ± SEM		Level of signification	P-value
	Group A	Group B		
Total cholesterol (mg/dl)	141.296±0.318	179.044±0.412	**	0.00
Triglyceride (mg/dl)	115.108±1.067	231.294±0.258	**	0.00
HDL cholesterol (mg/dl)	94.481±0.395	78.906±0.417	**	0.00
LDL cholesterol (mg/dl)	24.892±0.273	46.544±0.203	**	0.00

mice (Fig 2-4). Similar findings were reported by Abreu *et al.* (2014) and Joles *et al.* (2000). They also observed that cow brain consumption causes some changes in gross architecture of some vital organs that may hampers the normal function of body system.

Histological observations

In the histological observation, congestion in both central and portal vein, dilation of central vein and portal vein, marked lymphocytic infiltration and fatty infiltration in liver; wide separation of cardiac muscle fiber in the ventricular myocardium of heart; glomerular and tubular fatty infiltration of kidney were found (Fig 5-8). Similar findings were found by Csonka *et al.* (2017). They stated that fatty liver, congestion and dilation of central and portal vein, marked lymphocytic infiltration occurred due to cow brain consumption. Fatty liver disease occurs when some of those fat molecules accumulate inside the liver cells. Regarding the histological study of the heart, wide separation of cardiac muscle fiber was found (Fig 7) in cattle brain consumed



Fig 2: Gross photographs of liver of group A and group B of mice. Group A showing normal gross morphology of liver. Liver became pale and hemorrhagic (black arrow) in group B of mice.



Fig 4: Gross photographs of kidney of group A and group B of mice. Group A showing normal gross morphology of kidney. Peri renal fat deposition found (black arrow) in group B of mice.



Fig 3: Gross photographs of heart of group A and group B of mice. Group A showing normal gross morphology of heart. Fat accumulated at the base of the heart (black arrow) in group B of mice.

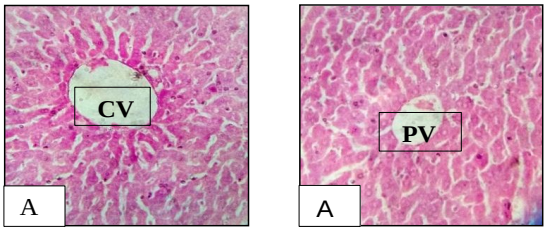

Fig 5: Histological architecture of liver of group A of mice showing normal central vein (CV) and portal vein (PV). Images were photographed with a 40X objective (H & E stain).

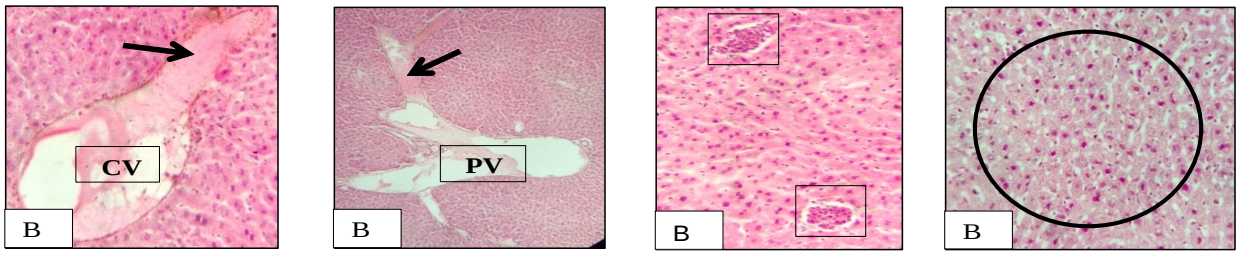

Fig 6: Histological architecture of liver of group B of mice showing congestion and dilation in both central vein (CV) and portal vein (PV) (black arrow), marked lymphocytic infiltration (rectangle) and fatty infiltration in the hepatocytes (circle). Images were photographed with a 40X objective (H & E stain).

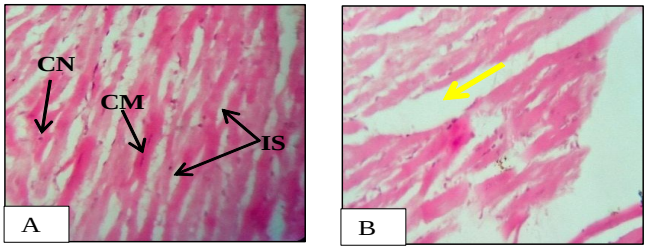

Fig 7: Normal histological architecture of heart of group A of mice (CM=Cardiac myofibers, IS=Interstitial space, CN=Central Nuclei). Wide separation of cardiac muscle fiber (yellow arrow) found in the ventricular myocardium heart of group B of mice. Images were photographed with a 40X objective (H & E stain).

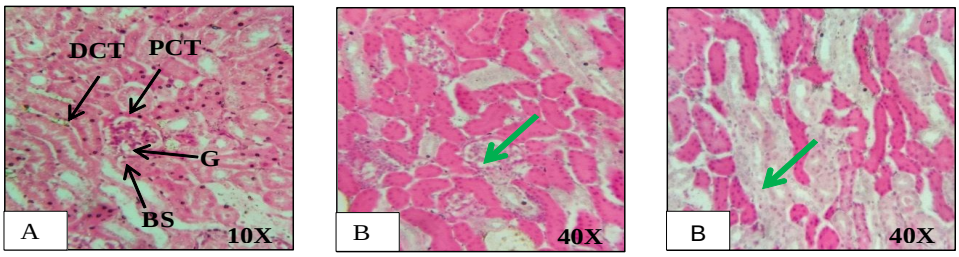

Fig 8: Normal histological architecture of kidney of group A of mice (G=Glomerulus, BS= Bowman's space, DCT=Distal convoluted tubules, PCT=proximal convoluted tubules). Glomerular and tubular fatty infiltration (green arrow) found in the kidney of group B of mice. Images were photographed with a 10X and 40 X objectives (H & E stain).

group B of mice. Seo *et al.* (2013) reported that high dietary fat intake is a major risk factor for development of cardiovascular and metabolic dysfunction including obesity, cardiomyopathy and hypertension. According to the present research, glomerular and tubular fatty infiltration was found (Fig 8) due to cow brain consumption. This was in agreement with Salim *et al.* (2018). They mentioned that hypercholesterolemia causes tubular damage and inhibits filtration rate that causes protein loss and renal tubular luminal leak and accumulate the fat droplets in tubular cells.

CONCLUSION

When the world is running after the herbal food but unfortunately some people are superstitious in their custom and frequently consume cow brain at a higher level. From this animal model trial, it is clearly evident that cow brain is a highly source of cholesterol that pose serious health risk. As a result, it is crying need to change the tradition that may give a healthy life.

ACKNOWLEDGEMENT

Sincere thanks to the Department of Anatomy and Histology, Faculty of Veterinary Science, Bangladesh Agricultural University, Mymensingh-2202 for technical help during this research tenure and a special acknowledgement to MoST (Ministry of Science and Technology), Bangladesh for providing the NST (National Science and Technology, 2018-2019) fellowship as a financial support to conduct the research smoothly.

REFERENCES

Abreu, I.C.M.E.D., Guerra, J.F.D.C., Pereira, R.R., Silva, M., Lima, W.G.D., Silva, M.E. and Pedrosa, M.L. (2014). Hyper--cholesterolemic diet induces hepatic steatosis and alterations in mRNA expression of NADPH oxidase in rat livers. Arquivos Brasileiros de Endocrinologia and Meta -bologia. 58(3): 251-259.

Ailhaud, G., Massiera, F., Weill, P., Legrand, P., Alessandri, J.M., and Guesnet, P. (2006). Temporal changes in dietary fats: role of n-6 polyunsaturated fatty acids in excessive adipose tissue development and relationship to obesity. Progress in Lipid Research. 45(3): 203-236.

Akter, S., Miah, M.A., Khan, M.A.H.N.A. and Islam, M.K. (2013). Effects of estrogen and folic acid on high fat induced hyper cholesterolemic mice. Biotechnology Journal International. 39-53.

Cho, S.J., Jung, U.J. and Choi, M.S. (2012). Differential effects of low-dose resveratrol on adiposity and hepatic steatosis in diet-induced obese mice. British Journal of Nutrition. 108(12): 2166-2175.

Colandré, M.E., Diez, R.S. and Bernal, C.A. (2003). Metabolic effects of trans fatty acids on an experimental dietary model. British Journal of Nutrition. 89(5): 631-638.

Csonka, C., Baranyai, T., Tiszlavicz, L., Fébel, H., Szűcs, G., Varga, Z.V., and Földesi, I. (2017). Isolated hyper-cholesterolemia leads to steatosis in the liver without affecting the pancreas. Lipids in Health and Disease. 16(1): 144.

Garg, M.L., and Blake, R. (1997). Cholesterol dynamics in rats fed diets containing either canola oil or sunflower oil. Nutrition Research. 17(3): 485-492.

Han, Q., Yeung, S.C., Ip, M.S., and Mak, J.C. (2018). Dysregulation of cardiac lipid parameters in high-fat high-cholesterol diet-induced rat model. Lipids in Health and Disease. 17(1): 255.

Ibrahim, S.M., Gomaa, R.S., Ismail, S.I. and Ibrahim, H.S. (2018). role of inflammation versus hypercholesterolemia in the development of atherosclerosis in male albino rats. Al-Azhar Assiut Medical Journal. 16(1): 58.

Jeffery, N.M., Yaqoob, P., Newsholme, E.A., and Calder, P.C. (1996). The effects of olive oil upon rat serum lipid levels and lymphocyte functions appear to be due to oleic acid. Annals of Nutrition and Metabolism. 40(2): 71-80.

Joles, J.A., Kunter, U.T.A., Janssen, U.L.F., Kriz, W., Rabelink, T.J., Koomans, H. A. and FLOEGE, J. (2000). Early mechanisms of renal injury in hyper-cholesterolemic or hyper-triglyceridemic rats. Journal of the American Society of Nephrology. 11(4): 669-683.

Katan, M B., Zock, P.L. and Mensink, R.P. (1995). Trans fatty acids and their effects on lipoproteins in humans. Annual Review of Nutrition. 15(1): 473-493.

Lichtenstein, A.H., Appel, L.J., Brands, M., Carnethon, M., Daniels, S., Franch, H.A., and Karanja, N. (2006). Diet and lifestyle recommendations revision 2006: a scientific statement from the American Heart Association Nutrition Committee. Circulation. 114(1): 82-96.

Lichtenstein, A.H., Kennedy, E., Barrier, P., and Danford, D. (1998). Dietary fat consumption and health/discussion. Nutrition Reviews. 56(5): S3.

Salim, H.M., Kurnia, L. F., Bintarti, T.W., and Handayani, H. (2018). The Effects of High-fat Diet on Histological Changes of Kidneys in Rats. Biomolecular and Health Science Journal. 1(2): 109-112.

Seo, Y.H., Lee, C.S., Yuk, H.B., Yang, D.J., Park, H.W., Kim, K.H., and Bae, J. H. (2013). Hypercholesterolemia and *in-vivo* coronary plaque composition in patients with coronary artery disease: a virtual histology-intravascular ultrasound study. Korean Circulation Journal. 43(1): 23-28.