RESEARCH ARTICLE Asian Journal of Dairy and Food Research, Volume 43 Issue 3: 501-508 (September 2024)

# Role of Transforming Growth Factor Beta 1 in Reducing Orthodontic Relapse: Rabbit Model Study

Saba H. Al Zubaidi[1], Niam R. Alsaleem[1], Muhammad A. Alkataan[2]

10.18805/ajdfr.DRF-401


## ABSTRACT

**Background**: This study attempted to evaluate clinically and histologically the effect of local injection of transforming growth factor beta 1 (TGFβ1) on the rate of orthodontic relapse.

**Methods**: 24 male albino rabbits were used, that grouped randomly into two groups (12 rabbits in each): positive control and TGFβ1 groups. Each group was further divided into 3 subgroups with 4 rabbits in each. Modified orthodontic appliances were cemented to the mandibular central incisors and tooth movement was carried out for 2 weeks, followed by a retention period for 3 weeks where positive control and TGFβ1 groups received local injections of phosphate buffer saline and TGFβ1 solutions, respectively, then the teeth allowed to relapse after removing the appliances for 20 days. The relapse was estimated clinically. Histological and immunohistochemical analyses were carried out following the completion of the experiment.

**Result:** The TGFβ1 group showed a significantly lower rate of relapse than the positive control group. Histologically, during the relapse period, a significant increase in the number of osteoblasts, a decrease in the number of osteoclast, which was also confirmed by immunohistochemical analyses and a lesser PDL width was seen in TGFβ1 group when compared to the positive control group. local injection of TGFβ1 can significantly reduce the orthodontic relapse in the rabbit model.


**Key words:** Alveolar bone, Bone remodeling, Orthodontic relapse, TGFβ1.

## INTRODUCTION

Orthodontic tooth movement is a procedure that includes mild, reversible periodontium damage along with physiologic adaptation of the alveolar bone to mechanical strains (Wise and King, 2008). Orthodontic tooth movement can take place by simultaneous activation of bone resorption by osteoclasts and bone synthesis by osteoblasts (Nakai *et al*., 2023).

Teeth tend to “relapse” or return to their original position, if there is no retention phase following successful orthodontic treatment (Martin *et al*., 2023). Relapse is thought to be a complex issue with multiple potential causes. It might be due to the time needed for gingival and periodontal tissue reorganization, unstable teeth position after orthodontic treatment and changes caused by growth (Abdulraheem *et al*., 2020; Giancotti *et al*., 2020).

The transforming growth factor beta (TGFβ) is a pleiotropic cytokine that regulates various biological functions like regulating inflammatory and cell cycle responses (Pokharel *et al*., 2016). TGFβ is a part of the superfamily. It has three isoforms in mammalian cells: TGFβ1, which is the most abundant and TGFβ2 and TGFβ3, which are rare (Katz *et al*., 2016).

Managing the remodeling of alveolar bone following orthodontic tooth movement is an essential approach in preventing relapse (Lin *et al*., 2023). Previous studies confirm the ability of the TGFβ1 to enhance proliferation and differentiation of osteoblast cells and their progenitor and subsequently enhance bone formation (Zhang *et al*., 2019 and Xu *et al*., 2020). Therefore, this study aimed to utilize the osteogenic properties of TGFβ1 to promote the formation of osteoblasts and subsequently generate more new bone on the relapse side, with the goal of reducing the rate of orthodontic relapse. To the best of our knowledge, this work represents the first attempt in the field of orthodontics to utilize TGFβ1 with the aim of minimizing relapse following orthodontic tooth movement.

[1]Department of Pedodontics Orthodontics Preventive Dentistry, College of Dentistry, University of Mosul, Mosul, Iraq.
[2]Department of Biochemistry, College of Medicine, Ninevah University, Mosul, Iraq.

**Corresponding Author:** Saba H. Al Zubaidi, Department of Pedodontics Orthodontics Preventive Dentistry, College of Dentistry, University of Mosul, Mosul, Iraq.
Email: saba.21dep2@student.uomosul.edu.iq

**How to cite this article:** Al Zubaidi, S.H., Alsaleem, N.R. and Alkataan, M.A. (2024). Role of Transforming Growth Factor Beta 1 in Reducing Orthodontic Relapse: Rabbit Model Study. Asian Journal of Dairy and Food Research. 43(3): 501-508. doi: 10.18805/ajdfr.DRF-401.

**Submitted:** 10-04-2024 **Accepted:** 09-07-2024 **Online:** 07-08-2024

## MATERIALS AND METHODS

The samples of the study consisted of (24) healthy male Albino rabbits, weighing 1000-2800 g, age 6-12 months. The rabbits were housed under standard animal care of food, water access, temperature and humidity (Yildiz-Gulay and Gulay, 2024). The male rabbits were chosen to ensure a hormonal balance for validating the study results and to exclude any hormonal fluctuations associated with the

estrous cycle in females, which could potentially impact bone metabolism and tooth movement (Alaa *et al*., 2023). The animals were divided randomly into two main groups (12 rabbits in each), positive control and TGFβ1 groups. Each group was further subdivided into three subgroups (4 rabbits in each) as follow (Fig 1).

**Positive control day 0 (PCD0), day 10 (PCD10) and day 20 (PCD20) groups**

All rabbits received 200 µl local injection of phosphate-buffered saline solution (PBS) (Himedia, India) every 3 days, during retention period. The animals in PCD0, PCD10 and PCD20 groups were euthanized on day 0, 10 and 20, respectively, after debanding of orthodontic appliance.

**Transforming growth factor beta 1 day 0 (TGFβ1D0), day 10 (TGFβ1D10) and day 20 (TGFβ1D20) groups**

All rabbits received local injection of TGFβ1 (1ng/ml) (Elabscience biotechnology Inc., USA) (200 µl) every 3 days (Zhang *et al*., 2019), during retention period. The animals in TGFβ1D0, TGFβ1D10 and TGFβ1D20 groups were euthanized on day 0, 10 and 20 receptively after debanding of orthodontic appliance.

**Experimental design**

Rabbits were anesthetized with an intramuscular injection of the mixture of 35 mg/kg body weight ketamine hydrochloride and 10 mg/kg body weight xylazine. Modified orthodontic appliance consisting of two bands (stainless steel, LA 00, Dentarum, Germany) into which bracket with 0.022 * 0.030" slot dimension is attached. A nickel titanium open coil spring, of about 5 circles length, was inserted along the sectional stainless steel wire (0.016*0.022") to exert a reciprocal lateral force of about 50 g on both mandibular incisors (Vani *et al.,* 2022). Ligature wire (0.01 inch) was used to ligate sectional wire into the bracket's slot and the wire was bended on both ends to avoid trauma to the rabbits (Al-Fakhry and Al-Sayagh, 2022; Vieira *et al*., 2019). Then the appliance cemented to the mandibular incisors and actived by removing the ligature wire that squeezed the open coil spring and allow the teeth to move for (2 weeks) (Fig 2).

After that, the appliance was retained in position for 3 weeks. Latter, the appliance was removed and the teeth were allowed to relapse. The amount of relapse was measured using electronic digital vernia (accurate to 0.01 mm) (Generic, China), at the level of the mesial tip of the two mandibular incisors at 0,2,4,7,10,13,17 and 20 days. During retention, TGFβ1 and PC groups received local injections of TGFβ1 and PBS solution respectively. The syringe tip inserted near the mesial side of the left mandibular incisor, into the mucogingival junction, in the vestibule (buccaly and lingually).

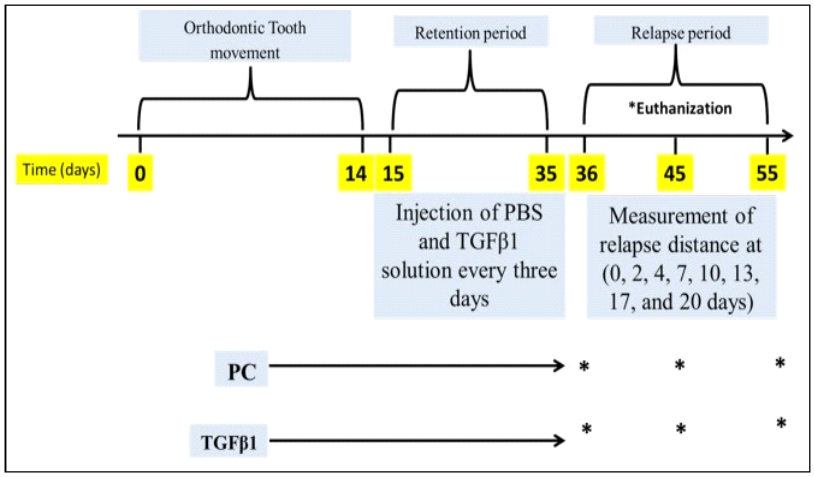


**Fig 1:** Timeline for establishing the rabbit relapse movement model.




**A)** Pre-orthodontic appliance insertion, B) Orthodontic separators between incisors, C) Orthodontic appliance in position.

**Fig 2:** Steps of orthodontic appliance insertion.

### Histological assessment

The lower jaw was fixed in 10% neutral buffered formalin for at least 48 h. After fixation, the specimens were passed through the following process: Decalcification, dehydration, clearing, infiltration and embedding (Yildiz-Gulay and Gulay, 2019). Longitudinal serial sections were cut for each specimen of 5 µm thickness in a labiolingual direction parallel to the long axis of the root of the mandibular incisor. The specimens were prepared for haematoxylin and eosin staining according to Suvana *et al*. (2019) and for immunohistochemistry analysis. The analysis was carried out in two areas and were determined by orienting the long axes of the tooth vertically. Then, two horizontal lines were drawn perpendicular to the long axes of the tooth. The first line (cervical) was drawn at level of alveolar crest and the other line (apical) was drawn at a distance of (9960 µm) from the first horizontal line, the distance between the two lines which represent the straight part of the mandibular incisor's root. The distance between the two lines was divided equally into two halves. The target area was the mesial aspect of the mandibular left incisor tooth.

### Histological evaluation includes

Number of osteoblasts, numbers of osteoclasts: that are counted on the alveolar wall next to the mesial side of the root of the left mandibular incisor. PDL width which represents the distance between the mesial surface of the mandibular left central incisor's root and new bone surface at 2 regions (at the level of cervical and apical line).

### Immunohistochemistry evaluation

Then the expression of bone alkaline phosphatase (bALP) and tartrate-resistant acid phosphatase (TRAP 5b) were evaluated on semi-quantitive scale measuring the intensity of immunoreaction. The score ranks usually lie in a range from "negative" (0) to "strong" (3) (Agustina *et al*., 2018).

The clinical and histological parameters were analyzed using IBM SPSS Statistics, Version 20. Nonparametric analysis including, descriptive statistics (mean±SD) and the Mann-Whitney test was used to compare the means of all parameters. Differences at $p<0.05$ were considered statistically significant.

## RESULTS AND DISCUSSION

### Clinical observations

Relapse occurred in both groups and the relapse distance increased over time to reach its maximum value at day (20). However, the greater RD occurred in the PC group (Table 1).

### Histological analysis

### The number of osteoblasts

on the day (0), highest counts of osteoblasts were seen in both groups with a gradual reduction in their number until reached the lowest number on the day (20). The TGFβ1 group was statistically significant the highest number of osteoblasts, (Table 2, Fig 3).

### The number of osteoclast

The lowest number of osteoclasts was recorded on day (0), with a highest number was reached on the day (10) and then there was a reduction in the number of osteoclasts on the day (20). In both upper and lower areas, TGFβ1 group was significant the lowest number of osteoclasts over the relapse period, Table 2, Fig 3.

### Periodontal ligament width

On day (0), the widest PDL width was recorded for both groups, with a gradual reduction in the width over time to

**Table 1:** Amount of space gained, remaining space, relapse distance and percentage of relapse for positive control and transforming growth factor beta 1 groups.

| Group | Days | Gaining space* | Remaining space* | RD* | PR*** |
|---|---|---|---|---|---|
| PC | 0 | 3.345 | 0 | 0 | 0% |
| | 2 | | 1.77 | 1.575 | 47.09% |
| | 4 | | 1.51 | 1.835 | 54.86% |
| | 7 | | 1.18 | 2.165 | 64.72% |
| | 10 | | 0.925 | 2.42 | 72.35% |
| | 13 | | 0.68 | 2.665 | 79.67% |
| | 17 | | 0.498 | 2.848 | 85.14% |
| | 20 | | 0.343 | 3.002 | 89.75% |
| TGFβ1 | 0 | 3.823 | 0 | 0 | 0% |
| | 2 | | 3.425 | 0.398 | 10.41% |
| | 4 | | 3.16 | 0.663 | 17.34% |
| | 7 | | 2.898 | 0.925 | 24.2% |
| | 10 | | 2.638 | 1.185 | 31% |
| | 13 | | 2.453 | 1.370 | 35.84% |
| | 17 | | 2.268 | 1.555 | 40.67% |
| | 20 | | 2.105 | 1.718 | 44.94 % |

*All measurements are in mm, **RD: Relapse distance, ***PR: Percentage of relapse.

record the narrowest width on day (20). In both regions, the PDL width was significantly the narrowest in TGFβ1 group during the relapse period, (Table 3, Fig 3).

**Bone ALP and TRAP 5b immunoreaction**

For BALP, on day (0), strong immunoreaction was detected in the TGFβ1 group when compared to the PC group and

**Table 2:** Comparison of osteoblasts and osteoclasts number among positive control and transforming growth factor beta 1 groups for three time intervals in two regions.

| | Area | Time/Day | Groups | Mean±SD | Test value | Sig.* |
|---|---|---|---|---|---|---|
| Osteoblasts | Upper half | 0 | PC | 104.75±9.323 | 16 | 0.021 |
| | | | TGFβ1 | 137±8.756 | | |
| | | 10 | PC | 76.25±3.304 | 16 | 0.021 |
| | | | TGFβ1 | 105.5±12.396 | | |
| | | 20 | PC | 51.5±13.478 | 16 | 0.021 |
| | | | TGFβ1 | 81.75±10.563 | | |
| | Lower half | 0 | PC | 109.25±14.683 | 16 | 0.021 |
| | | | TGFβ1 | 137.75±12.258 | | |
| | | 10 | PC | 80.25±3.862 | 16 | 0.021 |
| | | | TGFβ1 | 106.25±16.581 | | |
| | | 20 | PC | 56±6.481 | 16 | 0.021 |
| | | | TGFβ1 | 85.25±8.578 | | |
| Osteoclasts | Upper half | 0 | PC | 8±0.817 | 0 | 0.019 |
| | | | TGFβ1 | 5±0.817 | | |
| | | 10 | PC | 19±0.817 | 0 | 0.02 |
| | | | TGFβ1 | 13.75±1.708 | | |
| | | 20 | PC | 11.75±1.5 | 0 | 0.019 |
| | | | TGFβ1 | 8.5±0.577 | | |
| | Lower half | 0 | PC | 9±0.817 | 0 | 0.019 |
| | | | TGFβ1 | 5.5±0.577 | | |
| | | 10 | PC | 19.75±1.708 | 0 | 0.021 |
| | | | TGFβ1 | 15.5±1.291 | | |
| | | 20 | PC | 12±0.817 | 0 | 0.02 |
| | | | TGFβ1 | 8.5±1.291 | | |

*Significant difference existed at the P<0.05 level.

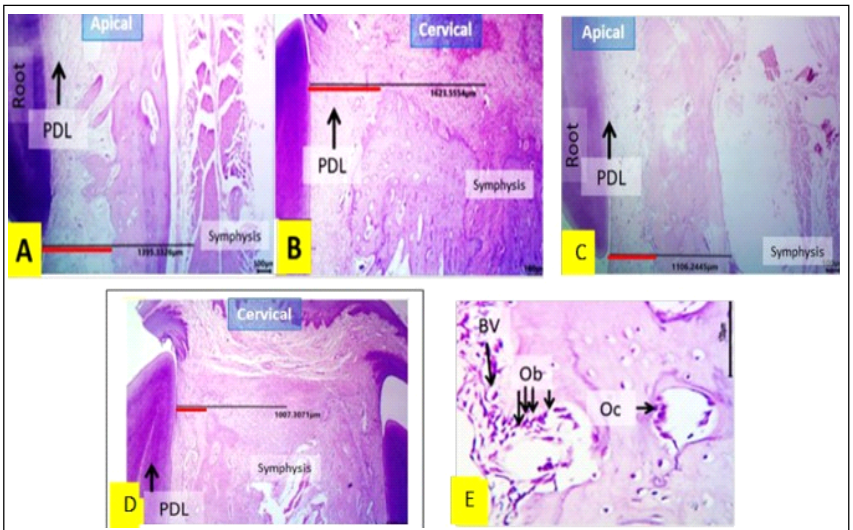


A,B,C,D): PDL width along apical and cervical lines at 0 and 20th day, respectively. E) the number of osteoblasts (Ob), osteoclast (OC) at day 0.

**Fig 3:** Hematoxylin and eosin stained section photomicrograph for the TGFβ1 group.

then the reaction decreased over the relapse period to record the weakest reaction on day (20), with the TGFβ1 group was the highest level of BALP during the experimental period with a significant differences on day 0 and 10. While for TRAP5b, on day 0, a low level of this marker can be seen in both groups, to reach its maximum value, with a significant elevated immunoreaction in PC group on day 10 in the upper half and on day 10 and 20 in the lower half. Then the immunoreaction slows down until reached day (20), (Table 4, Fig 4).

Higher rates of post-orthodontic relapse happened at the initial time after appliance removal. This result was in

**Table 3:** Comparison of the periodontal ligament width among positive control and transforming growth factor beta 1 groups for three time intervals in two regions.

| Area | Time/ Day | Groups | Mean±SD* | Test value | Sig.** |
|---|---|---|---|---|---|
| Cervical | 0 | PC | 629±12.832 | 0.0001 | 0.021 |
| | | TGFβ1 | 472.75±44.222 | | |
| | 10 | PC | 527.75±31.095 | 0.0001 | 0.021 |
| | | TGFβ1 | 382.5±10.97 | | |
| | 20 | PC | 470.25±27.536 | 0.0001 | 0.021 |
| | | TGFβ1 | 267.5±11.818 | | |
| Apical | 0 | PC | 643.25±19.67 | 0.0001 | 0.021 |
| | | TGFβ1 | 489.5±57.029 | | |
| | 10 | PC | 519.25±31.33 | 0.0001 | 0.021 |
| | | TGFβ1 | 354.25±23.2 | | |
| | 20 | PC | 476±19.95 | 0.0001 | 0.021 |
| | | TGFβ1 | 282.75±12.093 | | |

* The mean and SD are expressed in micrometers.** Significant difference existed at the P<0.05 level.

**Table 4:** Comparison of ALP and TRAP5b levels for positive control and transforming growth factor beta 1 at three experimental periods in the upper and lower halves.

| | Area | Time/ Day | Groups | Mean ± SD | test value | Sig.* |
|---|---|---|---|---|---|---|
| BALP | Upper half | 0 | PC | 1.5±0.577 | 15 | 0.032 |
| | | | TGFβ1 | 2.75±0.5 | | |
| | | 10 | PC | 0.75±0.5 | 14.5 | 0.04 |
| | | | TGFβ1 | 1.75±0.5 | | |
| | | 20 | PC | 0.5±0.577 | 12 | 0.127 |
| | | | TGFβ1 | 1±0 | | |
| | Lower half | 0 | PC | 1.5± 0.577 | 16 | 0.013 |
| | | | TGFβ1 | 3±0 | | |
| | | 10 | PC | 1±0 | 14 | 0.04 |
| | | | TGFβ1 | 1.75±0.5 | | |
| | | 20 | PC | 0.75±0.5 | 11.5 | 0.186 |
| | | | TGFβ1 | 1.25±0.5 | | |
| TRAP 5b | Upper half | 0 | PC | 1.75±0.5 | 4 | 0.186 |
| | | | TGFβ1 | 1.25±0.5 | | |
| | | 10 | PC | 3±0.00 | 0.0001 | 0.008 |
| | | | TGFβ1 | 2±0.000 | | |
| | | 20 | PC | 2.25±0.5 | 3 | 0.096 |
| | | | TGFβ1 | 1.5±0.577 | | |
| | Lower half | 0 | PC | 1.75±0.5 | 4 | 0.186 |
| | | | TGFβ1 | 1.25±0.5 | | |
| | | 10 | PC | 3±0.00 | 0.0001 | 0.008 |
| | | | TGFβ1 | 2±0.00 | | |
| | | 20 | PC | 2.25±0.5 | 1.5 | 0.04 |
| | | | TGFβ1 | 1.25±0.5 | | |

*Significant differences existed at the P<0.05 level.

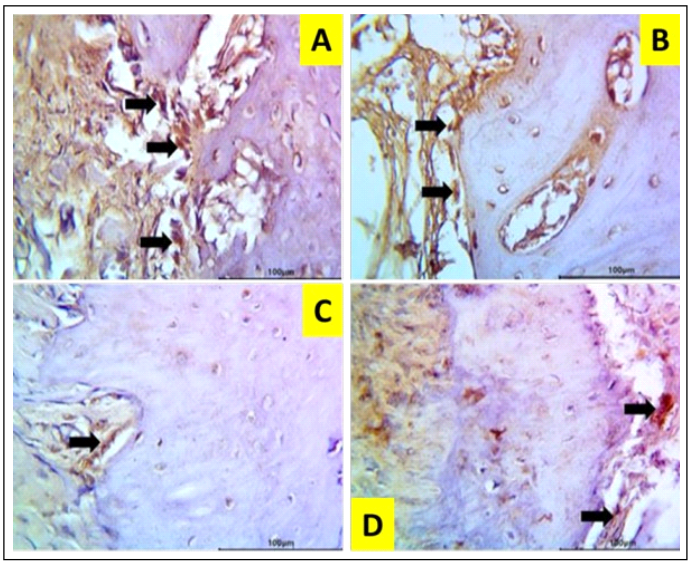


**Fig 4:** Immunohistochemical expression of: A,B) BALP for the TGFβ1 group on day 0 and 20 respectively, C,D) TRAP for the TGFβ1 group on day 0 and 10, respectively.

line with the findings of Reitan (1967), who observed that a higher initial relapse happens when the tooth experiences a rebound shift in the socket. More than half of the relapse distance occurred by 10$^{th}$ day, then the relapse rate decreased until the end of the experiment. This result is congruent with the findings of Al-Fakhry (2022).

The greater number of osteoblast in TGFβ1 group on day 0 was due to the effect of TGFβ1 on bone cells. TGFβ1 stimulates bone cell proliferation and osteogenic differentiation (Zhao *et al*., 2018), displays chemotactic attraction of osteoblasts (Karst *et al*., 2004), prevents osteoblast apoptosis (Indriasari *et al*., 2019) and activates differentiation of MSCs to into osteoblasts (Li *et al*., 2022). The gradual reduction in the number of osteoblasts on days 10 and 20 because during the relapse, the previous tension site became pressure site and alveolar bone resorption occurred according to pressure-tension theory (Viazis *et al*., 2023).

The presence and activity of ALP during osteogenic differentiation signal that MSCs are undergoing differentiation into osteoblasts (Capulli *et al*., 2014). ALP is an essential biomarker of osteoblastic activity (Sanchez *et al.,* 2020). The present study demonstrated a direct correlation between the number of osteoclasts and orthodontic relapse, underscoring the significance of bone resorption during the relapse period. Therefore, the control group showed a higher rates of relapse and osteoclast counts, while the TGFβ1 group displayed the opposite profile because of its impact on osteoblasts, as concluded by Takai *et al*. (1998) in that, high concentrations of TGFβ1 (1-10 ng/ml) increase the expression and secretion of OPG and decreased that of RANKL by osteoblasts.

TRAP functions to break down osteopontin, a protein that attaches to integrins on the surface of osteoclasts and enhances their adherence, thus, enhancing osteoclast migration by inhibiting this adhesion (Janckila and Yam, 2009). The level of TRAP5b comes in line with the number of osteoclast, since TRAP 5b is normally secreted by osteoclasts during bone resorption and can be measured as biochemical markers of bone resorption (Schini *et al*., 2023). TRAP reflect osteoclasts cell number (Park *et al*., 2024) and activity (Jiang *et al*., 2020).

TGFβ1 group showed the narrowest PDL width, which is due to the greater anabolic effect of TGFβ1. With time, there was a reduction in the width of the PDL fibers because it became the compression side during relapse. This implies that tension of periodontal ligament fibers plays a role in relapse. This result comes in agreement with Aoki *et al*. (2023).

Limitation of the study: The number of animals is limited, so to achieve more accurate and reliable results, the number of animals should be increased. In addition, there was difficulty in sample selection as well as difficulty in determination the exact age of the animals.

## CONCLUSION

Local injection of TGFβ1 during the retention period is associated clinically with a significant reduction of orthodontic relapse as compared to PC group. Histological finding support the clinical result which manifested by significant increase in the number of osteoblast and reduction in the number of osteoclast. The immunohistochemical reaction comes in line with the histological parameters and characterized by the highest level of BALP and the lowest level of TRAP 5b throughout the relapse period as compared to PC group. Also, TGFβ1 group had reduced PDL width as compared to PC group which confirm the anabolic effect of TGFβ1.

## ACKNOWLEDGEMENT

The authors are grateful to the University of Mosul, College of Dentistry, for continuous support.

### Ethical approval

The protocol of study was approved by the research ethics committee of University of Mosul / College of Dentistry, REC reference no. UoM.Dent/ DM.12/ 23.

### Conflict of interest

All authors declare that they have no conflict of interest.

## REFERENCES

Abdulraheem, S., Schütz-Fransson, U. and Bjerklin, K. (2020). Teeth movement 12 years after orthodontic treatment with and without retainer: Relapse or usual changes. European Journal of Orthodontics. 42(1): 52-59. https://doi: org/10.1093/ejo/cjz020.

Agustina, H., Asyifa, I., Aziz, A. and Hernowo, B.S. (2018). The role of osteocalcin and alkaline phosphatase immunohistochemistry in osteosarcoma diagnosis. Pathology Research international. https://doi: org/10.1155/2018/6346409.

Alaa, S., Fouda, A.M., Grawish, M.E. and Abdelnaby, Y.L. (2023). The effect of submucosal injection of platelet-rich fibrin vs. Platelet-rich plasma on orthodontic tooth movement in rabbits; 28 days follow-up. International Orthodontics. 21(1): 100715. https://doi: org/10.1016/j.ortho.2022.100715.

Al-Fakhry, H.H. (2022). Influence of local injection of platelet rich fibrin and osteoprotegerin on orthodontic relapse in a rabbit model. PhD. Dissertation. University of Mosul, College of Dentistry, Mosul, Iraq.

Al-Fakhry, H.H. and Al-Sayagh, N.M. (2022). Effects of Injectable platelet rich fibrin (i-PRF) on reduction of relapse after orthodontic tooth movement: Rabbits model study. Journal of Orthodontic Science. 11(1): 10. doi: 10.4103/jos.jos_165_21.

Aoki, Y., Kako, S., Miyazawa, K., Tabuchi, M., Kimura, F., Kataoka, K. and Goto, S. (2023). Dynamics and observations of long-term orthodontic tooth movement and subsequent relapse in C57BL/6 mice. Experimental Animals. 72(1): 103-111. https://doi: org/10.1538/expanim. 22-0099.

Capulli, M., Paone, R. and Rucci, N. (2014). Osteoblast and osteocyte: games without frontiers. Archives of Biochemistry and Biophysics. 561: 3-12. https://doi: org/10.1016/j.abb.2014.05.003.

Giancotti, A., Mozzicato, P. and Mampieri, G. (2020). Thermoformed retainer: An effective option for long-term stability. Case Reports in Dentistry, 2020. https://doi: org/10.1155/2020/8861653.

Indriasari, V., Suparwitri, S., Christnawati, C. and Alhasyimi, A.A. (2019). Different effects of soybean isoflavone genistein on transforming growth factor levels during orthodontic tooth movement among young and old rabbits. F1000 Research. 8. doi: 10.12688/f1000research.21211.2.

Janckila, A.J. and Yam, L.T. (2009). Biology and clinical significance of tartrate-resistant acid phosphatases: New perspectives on an old enzyme. Calcified Tissue International. 85: 465-483. https://doi: org/10.1007/s00223-009-9309-8.

Jiang, N., Guo, F., Xu, W., Zhang, Z., Jin, H., Shi, L. and Xu, H. (2020). Effect of fluoride on osteocyte-driven osteoclastic differentiation. Toxicology. 436: 152429. https://doi: org/10.1016/j.tox.2020.152429.

Karst, M., Gorny, G., Galvin, R.J.S. and Oursler, M.J. (2004). Roles of stromal cell RANKL, OPG and M CSF expression in biphasic TGFβ regulation of osteoclast differentiation. Journal of Cellular Physiology. 200(1): 99-106. https://doi: org/10.1002/jcp.20036.

Katz, L.H., Likhter, M., Jogunoori, W., Belkin, M., Ohshiro, K. and Mishra, L. (2016). TGF-β signaling in liver and gastrointestinal cancers. Cancer letters. 379(2): 166-172. https://doi: org/10.1016/j.canlet.2016.03.033.

Li, J., Ge, L., Zhao, Y., Zhai, Y., Rao, N., Yuan, X. and Yu, S. (2022). TGF-β2 and TGF-β1 differentially regulate the odontogenic and osteogenic differentiation of mesenchymal stem cells. Archives of Oral Biology. 135: 105357. https://doi: org/10.1016/j.archoralbio.2022.105357.

Lin, Y., Fu, M.L., Harb, I., Ma, L.X. and Tran, S.D. (2023). Functional biomaterials for local control of orthodontic tooth movement. Journal of Functional Biomaterials. 14(6): 294. https://doi: org/10.3390/jfb14060294.

Martin, C., Littlewood, S.J., Millett, D.T., Doubleday, B., Bearn, D., Worthington, H.V. and Limones, A. (2023). Retention procedures for stabilising tooth position after treatment with orthodontic braces. Cochrane Database of Systematic Reviews. (5). https://doi: org/10.1002/14651858.CD002283.pub5.

Nakai, Y., Praneetpong, N., Ono, W., Ono, N. (2023). Mechanisms of osteoclastogenesis in orthodontic tooth movement and orthodontically induced tooth root resorption. J Bone Metab. 30(4): 297-310. https://doi: org/10.11005/jbm.2023.30.4.297.

Park, S., Heo, J.S., Mizuno, S., Kim, M., An, H., Hong, E. and Kim, S.J. (2024). Tm4sf19 deficiency inhibits osteoclast multinucleation and prevents bone loss. Metabolism. 151: 155746. https://doi: org/10.1016/j.metabol.2023.155746.

Pokharel, S.M., Shil, N.K., and Bose, S. (2016). Autophagy, TGF-β and SMAD-2/3 signaling regulates interferon-β response in respiratory syncytial virus infected macrophages. Frontiers in Cellular and Infection Microbiology. 6: 174. https://doi: org/10.3389/fcimb.2016.00174.

Reitan, K. (1967). Clinical and histologic observations on tooth movement during and after orthodontic treatment. American Journal of Orthodontics. 53(10): 721-745. https://doi: org/10.1016/0002-9416(67)90118-2.

Sanchez, M.A., Felice, B., Sappia, L.D., Moura, S.L., Martí, M. and Pividori, M.I. (2020). Osteoblastic exosomes. A non-destructive quantitative approach of alkaline phosphatase to assess osteoconductive nanomaterials. Materials Science and Engineering. 115: 110931. https://doi: org/10.1016/j.msec.2020.110931.

Schini, M., Vilaca, T., Gossiel, F., Salam, S. and Eastell, R. (2023). Bone turnover markers: Basic biology to clinical applications. Endocrine Reviews. 44(3): 417-473. https://doi: org/10.1210/endrev/bnac031.

Suvana, S.K., Layton, C., Bancroft, J.D. (2019). Bancroft's Theory and Practice of Histological Techniques. 8th Edition. Elsevier Health Sciences. pp: 73-95.

Takai, H., Kanematsu, M., Yano, K., Tsuda, E., Higashio, K., Ikeda, K. and Yamada, Y. (1998). Transforming growth factor-β stimulates the production of osteoprotegerin/ osteoclastogenesis inhibitory factor by bone marrow stromal cells. Journal of Biological Chemistry. 273(42): 27091-27096. https://doi: org/10.1074/jbc.273.42.27091.

Vani, G., Veena, P., Kumar, R.V., Lashmi, M.S., Prameela, D.R. and Kundu, B. (2022). Efficacy of multi-ion doped plasma spray nano-hydroxyapatite coated titanium implants in long bone fracture repair in dogs-radiographical and bone markers evaluation. Indian Journal of Animal Research. 56(3): 348-352. https://doi:org/10.18805/IJAR.B-4508.

Viazis, A.D. and Pagonis, T.C. (2023). Prediction of orthodontic treatment duration based on the alveolar bone formula. J Dent Health Oral Disord Ther. 14(4): 142-149.

Vieira, G.M., Falcao, D.P., Queiroz, S.B.F.D., Lima, V.N.D., Bentes de Azevedo, R., Tiziane, V. and Amorim, R. (2019). A novel analysis via Micro-CT imaging indicates that chemically modified tetracycline-3 (CMT-3) inhibits tooth relapse after orthodontic movement: A pilot experimental study. International Journal of Dentistry. 1: 3524207. https:/ /doi: org/10.1155/2019/3524207.

Wise, G.E. and King, G.J. (2008). Mechanisms of tooth eruption and orthodontic tooth movement. Journal of Dental Research. 87(5): 414-434. https://doi: org/10.1177/154405910808 70050.

Xu, J., Liu, J., Gan, Y., Dai, K., Zhao, J., Huang. and Zhang, X. (2020). High-Dose TGF-β1 Impairs Mesenchymal Stem Cell-Mediated Bone Regeneration *via* Bmp2 Inhibition. Journal of Bone and Mineral Research. 35(1): 167-180. https://doi: org/10.1002/jbmr.3871.

Yildiz-Gulay, O. and Gulay, M.S. (2019). Punicalagin is beneficial for spermatogenesis in male New Zealand White rabbits. Indian Journal of Animal Research. 53(4): 457-460. https:/ /doi: org/10.18805/ijar.B-915.

Yildiz-Gulay, O. and Gulay, M.S. (2024). Punicalagin Improved the Oxidant-antioxidant Status in Male New Zealand White Rabbits. Indian Journal of Animal Research. 58(2): 215-219. doi: 10.18805/ijar.B-1295.

Zhang, Z., Zhang, X., Zhao, D., Liu, B., Wang, B., Yu, W. and Liu, Y. (2019). TGF β1 promotes the osteoinduction of human osteoblasts via the PI3K/AKT/mTOR/S6K1 signalling pathway. Molecular Medicine Reports. 19(5): 3505-3518. https://doi: org/10.3892/mmr.2019.10051.

Zhao, Y., Li, Y., Gao, Y., Yuan, M., Manthari, R.K., Wang, J. and Wang, J. (2018). TGF-β1 acts as mediator in fluoride-induced autophagy in the mouse osteoblast cells. Food and Chemical Toxicology. 115: 26-33. https://doi: org/10. 1016/j.fct.2018.02.065.