RESEARCH ARTICLE Indian Journal of Animal Research, Volume 57 Issue 2: 184-189 (February 2023)

Effect of Zinc Supplementation on Histomorphology of Testis and Epididymis in Male Wistar Rats

Juneet Kour[1], Jonali Devi[1], Kamal Sarma[1]

10.18805/IJAR.B-4312

ABSTRACT

Background: Bio potency of trace elements is very important in animal growth and reproduction. Among the trace minerals, zinc is very important as it is required for many normal physiological functions. It also plays an essential role in testicular steroidogenesis androgen metabolism and interaction with steroid receptors. Testes have a strict zinc requirement and severe zinc deficiency compromises spermatogenesis, sperm viability, motility and fertility in human beings. Zinc depletion studies in mice resulted in oligospermia with poor Leydig cell function and lowered testosterone concentration and was reversed by zinc supplementation. But, relatively few studies have been conducted on male animal responses to supplementation of important mineral like zinc at their critical phase of growth and reproduction. The present investigation was taken up to study the effect of zinc supplementation in two different doses with a view to assess its implication in testicular and epididymal sperm morphology during growth period in Wistar rats.

Methods: The study was conducted in 72 weaned Wistar male rats for a period of 8 weeks from 4 to 12 weeks of age, which were procured from Indian Institute of Integrative Medicine, CSIR Laboratory, Jammu. The experimental rats were divided in to three groups as control: rats fed diet without zinc supplementation, T1 (treatment 1): rats fed diet containing zinc sulphate @ 50 mg/kg body weight/day and T2 (treatment 2): rats fed diet containing zinc sulphate @ 100 mg/kg body weight/day. They were provided standard pelleted ration and clean drinking water *ad libitum* and maintained under standard managemental conditions. On 6, 8, 10 and 12 weeks of experiment, the rats were sacrificed after induction of proper anaesthesia. The reproductive organs (testes and epididymidis) were collected from each rat and tissue pieces from testes and three parts of the epididymis *viz*. caput, corpus and cauda, were fixed separately in 10 per cent Neutral Buffered Formalin solution and processed for paraffin sections by alcohol- xylene method. Sections 5 µ thickness was stained by Haematoxylin and Eosin (Luna, 1968) for histological studies.

Result: Elongated spermatids were seen in the seminiferous epithelium only in treatment (T1 and T2) groups at 6 weeks of age, not in the control rats. At 8 weeks of age, maximum number of spermatozoa were seen in the seminiferous tubular lumen in the T1 group as compared to T2 treatment group. At 10 weeks, spermatozoa were seen in the lumen of the seminiferous tubules in all the rats under study. The epididymis revealed no sperm pack in cauda epididymis in all group rats at 6 weeks of age. However, at 8 weeks of age, the sperm pack was seen in the lumen of the epididymal tubules of the cauda epididymis of T1 and T2 groups. The significant finding was that in T1 rats the sperm pack was very compact at 10 weeks in cauda epididymis as compared to T2 and control group rats.

Key words: Epididymis, Histomorphology, Testis, Wistar rats, Zinc supplementation.

INTRODUCTION

Scientific studies have shown the bio potency of trace elements in animal growth and reproduction. Among the trace minerals, zinc is very important as it is required for normal growth and development, testicular maturation, neurological function, wound healing and immunocompetence (European Commission, 2003). It plays an essential role in testicular steroidogenesis (Devi *et al*., 2012) androgen metabolism and interaction with steroid receptors (Bedwal and Bahuguna, 1994). Testes have a strict zinc requirement and severe zinc deficiency compromises spermatogenesis, sperm viability, motility and fertility in human beings (Croxford *et al*., 2011). Zinc deficient mice included delayed sexual maturation, testicular disruption, impaired spermatogenesis and infertility (Dissanayake *et al*., 2004). Zinc depletion studies in mice resulted in oligospermia with poor Leydig cell function and lowered testosterone concentration and was reversed by zinc supplementation (Abbasi *et al.,* 1979). These observations seem reasonable, given the high zinc uptake requirement by the testis, prostate and epididymis to maintain optimal function. But, relatively few studies have been conducted on male animal responses to supplementation of important mineral like zinc at their critical phase of growth and reproduction. Therefore, it was felt that

[1]Division of Veterinary Physiology and Biochemistry, Faculty of Veterinary Sciences and Animal Husbandry, Sher-e-Kashmir University of Agricultural Sciences and Technology, Jammu-181 102, Jammu and Kashmir, India.

Corresponding Author: Jonali Devi, Division of Veterinary Physiology and Biochemistry, Faculty of Veterinary Sciences and Animal Husbandry, Sher-e-Kashmir University of Agricultural Sciences and Technology, Jammu-181 102, Jammu and Kashmir, India.
Email: drjonali2011@gmail.com

How to cite this article: Kour, J., Devi, J. and Sarma, K. (2023). Effect of Zinc Supplementation on Histomorphology of Testis and Epididymis in Male Wistar Rats. Indian Journal of Animal Research. 57(2): 184-189. doi: 10.18805/IJAR.B-4312.

Submitted: 19-09-2020 **Accepted:** 19-03-2021 **Online:** 07-04-2021

a scientific study on the growth and functional responsiveness of male genital organs in male Wistar rat to zinc supplementation at their active phase of growth would yield valuable scientific information regarding possible role of dietary zinc in regulating the initiation of germ cell multiplication in the seminiferous tubules and optimizing suitable bio-environment in the epididymis for maturation of germ cells. The present investigation was taken up to study the effect of zinc supplementation in two different doses with a view to assess its implication in testicular and epididymal sperm morphology during growth period in Wistar rats.

MATERIALS AND METHODS

The study was conducted in 72 weaned Wistar male rats for a period of 8 weeks from 4 to 12 weeks of age in the Division of Veterinary Physiology and Biochemistry, Faculty of Veterinary Sciences and Animal Husbandry, Sher-e-Kashmir University of Agricultural Sciences and Technology, Jammu, R.S. Pura, Jammu, J&K, India in the year 2019. The experimental rats were divided in to three groups as control: rats fed diet without zinc supplementation, T1 (treatment 1): rats fed diet containing zinc sulphate @ 50 mg/kg body weight/day and T2 (treatment 2): rats fed diet containing zinc sulphate @ 100 mg/kg body weight/day. The rats were procured from Indian Institute of Integrative Medicine, CSIR Laboratory, Jammu. They were provided standard pelleted ration and clean drinking water *ad libitum* and maintained under standard managemental conditions. Prior to start of experiment, the rats were acclimatized in the laboratory conditions for a period of one week.

On 6, 8, 10 and 12 weeks of experiment, the rats were sacrificed after induction of proper anaesthesia. The reproductive organs (testes and epididymidis) were collected from each rat of all the 3 groups the testis was separated from the epididymis. Tissue pieces from testes and three parts of the epididymis *viz*. caput, corpus and cauda, were fixed separately in 10 per cent Neutral Buffered Formalin solution. All the tissues were processed for paraffin sections by alcohol- xylene method. Sections were cut at 5 ì thickness using a Rotary microtome and stained by Haematoxylinand Eosin (Luna, 1968) for histological studies.

RESULTS AND DISCUSSION

Histomorphology of testis

From the present findings, it could be observed that the development of the process of spermatogenesis was different in zinc-supplemented group of rats when compared with that of control rats. Histomorphological studies of the seminiferous tubules of the testes revealed that at 6 weeks of age, the tubules were compactly arranged in all the treatment groups (control, T1 and T2) of rats (Fig 1, Fig 2 Fig 3). In all the three groups, the seminiferous tubules had distinct lumina. While elongated spermatids were visible in the seminiferous epithelium only in treatment (T1 and T2) groups, more concentrations of the same being noticed in T1 group (Fig 4); no spermatozoa could be located in the

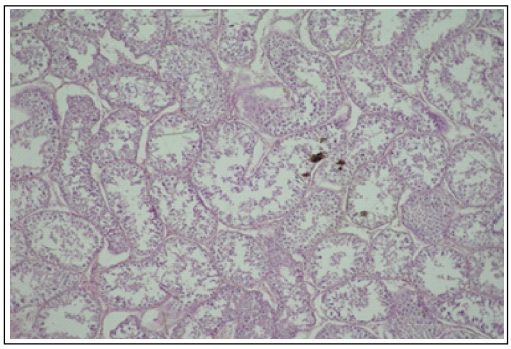

Fig 1: Photomicrograph showing compactness of seminiferours tubules of testis in a rat of control group at 6 weeks of age, H&E, 100X.

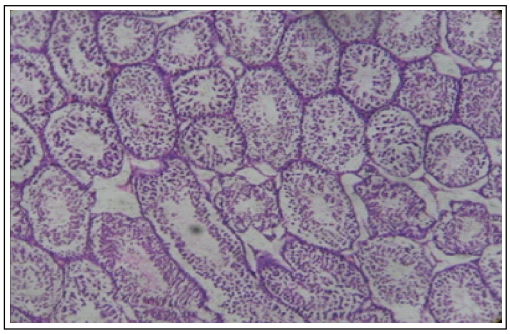

Fig 2: Photomicrograph showing compactness of seminiferours tubules of testis in a rat of T1 group at 6 weeks of age, H&E, 100X.

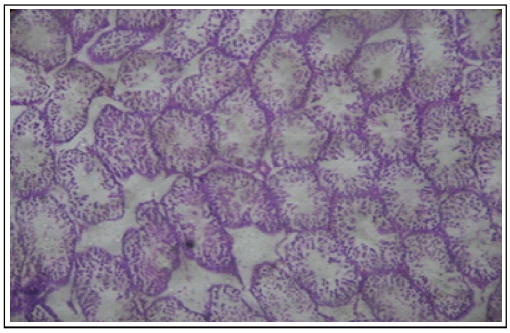

Fig 3: Photomicrograph showing compactness of seminiferours tubules of testis in a rat of T2 group at 6 weeks of age, H&E, 100X.

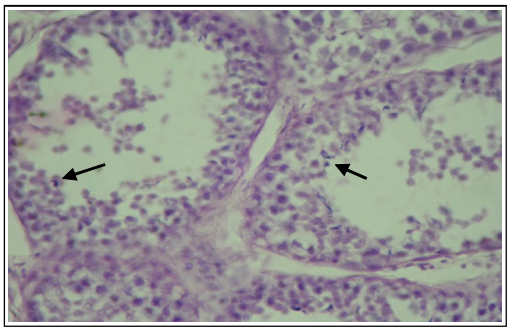

Fig 4: Photomicrograph showing elongated spermatids (arrows) in the seminiferours tubules of testis in a rat of T1 group at 6 weeks of age, H&E, 200X.

same site in the control rats. The developmental difference in the process of spermatogenesis in the treated group could be attributed to function of zinc because zinc is an important mineral for normal testicular development and maintenance of germinal epithelium (Anderson *et al*., 1993) and it is vital for spermatogenesis process (Davies, 1985). Spermatogenesis process in the male is impacted by dietary zinc levels (McDowell *et al*., 1993). It acts as a cofactor for several enzymes which help in steroidogenesis processes in the body. Impairment of spermatogenesis could be attributed to the direct action of zinc on testes or indirectly from Leydig cell degeneration indicating that zinc is a critical component for maintenance of both mitotic and meiotic stages of spermatogenesis. Other workers (Abdella *et al*., 2011; Omu *et al*., 2015) also found zinc supplementation in diet of rats resulted remarkable improvement of spermatogenesis. Al-Ani *et al.* (2015) studied the protective influence of zinc on reproductive parameters in male rats treated with cadmium and they found that testicular sections of the control group showed seminiferous tubules with normal germ cell population layer thickness with a normal orderly arranged pattern up to mature spermatid and no malignant or abnormal cell was seen within the germinal epithelium, whereas, in cadmium treated group, sections showed a decrease in thickness of germ cell layer, widening of the central seminiferous tubules lumen and prominent germ cell population necrosis. In the group treated with cadmium and zinc, sections of tubules showed recovery of germ cell population, normal germinal epithelium thickness and diameter with orderly arranged germ cell up to spermatid with adequate Sertoli and Leydig interstitial cells population. However, when the effect of lipid-zinc interaction was studied in testis of mice (Taneja *et al.,* 1995) it was observed that the testis in low lipid-zinc deficient diet, low lipid-zinc supplemented and high lipid-zinc supplemented groups did not display any abnormality in the germ cell population of the seminiferous tubules.

At 8 weeks of age, the seminiferous tubules were more organized than the previous age in all the three treatment groups (control, T1 and T2). The seminiferous tubules were separated forming well developed interstitial tissues which were more marked in T1 (Fig 5) as compared to the control and T2 groups (Fig 6) of rats. Sperm cells were seen adhering to the apical surface of the seminiferous epithelium and in its lumen in all the rats of T1 group (Fig 7). Again, in few of the rats of T2 group, sperm cells were seen adhering to the apical surface of the seminiferous epithelium and in its lumen however no such cells were visible in the rats of control group. The maximum number of spermatozoa seen in the seminiferous tubular lumen in the T1 group (Fig 7) as compared to T2 treatment group at 8 weeks could be ascribed to higher beneficial effect of zinc @ 50 mg/kg body weight in influencing the testicular function of spermatogenesis as it was also reported earlier by Egwurugwu *et al.* (2013) that oral zinc supplementation within tolerable level has beneficial effect. Turgut *et al*. (2003) observed that following high doses of zinc supplementation had degenerative changes including spermatic arrest, degeneration of seminiferous tubules and fibrosis in interstitial tissues and this could significantly alter sperm motility.

At the age of 10 weeks, the seminiferous epithelium of the rats of all the control (Fig 8), T1 (Fig 9) and T2 (Fig 10) groups showed spermatozoa in the lumen of the seminiferous tubules. Similar histological features in the testis of rats of the control, T1 (Fig 11) and T2 was seen at 12 weeks of age, however, the concentration of spermatozoa was seen more in the lumen of the seminiferous tubules as compared to the previous age in all the rats under study. In other studies (Campion *et al.,* 2013) sperms were detected in the caput, corpus and cauda epididymis in 45, 49 and 49

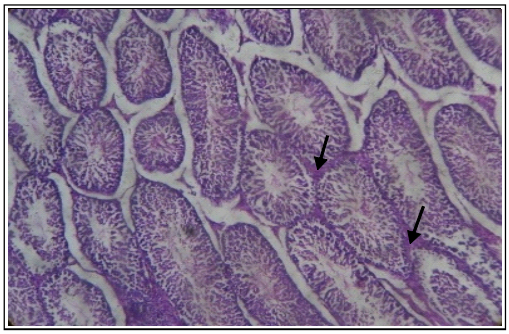

Fig 5: Photomicrograph showing well developed interstitial tissues (arrows) in the seminiferours tubules of testis in a rat of T1 group at 8 weeks of age, H&E, 100X.

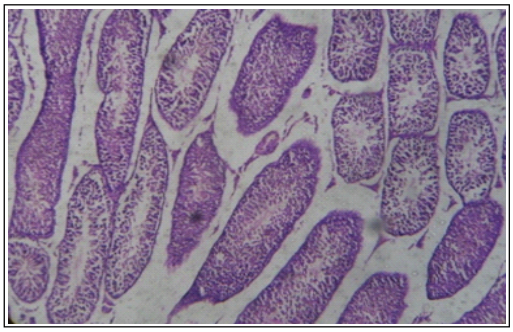

Fig 6: Photomicrograph showing interstitial tissues (arrows) in the seminiferours tubules of testis in a rat of T2 group at 8 weeks of age, H&E, 100X.

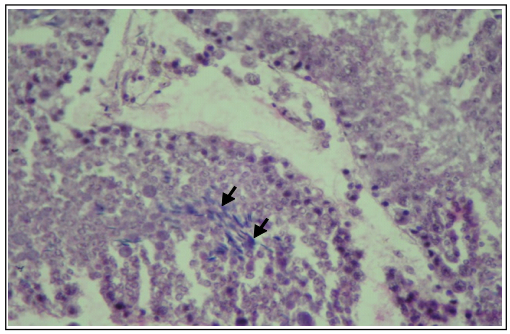

Fig 7: Photomicrograph showing sperm cells in the seminiferours tubules (arrows) of testis in a rat of T1 group at 8 weeks of age, H&E, 200X.

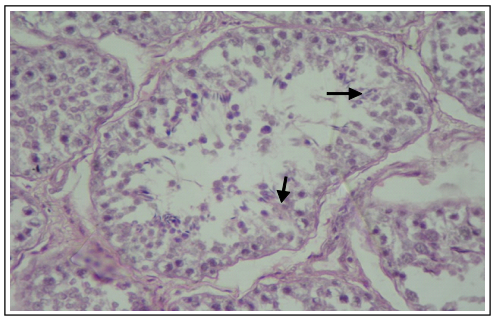

Fig 8: Photomicrograph showing spermatozoa (arrows) in the seminiferours tubules of testis in a rat of Control group at 10 weeks of age, H&E, 400X.

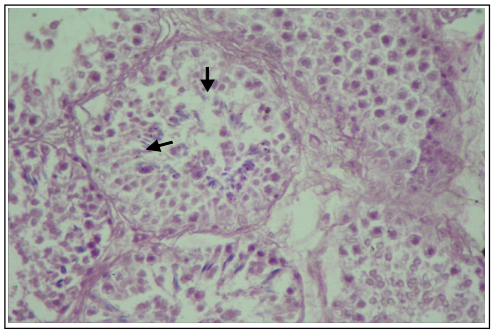

Fig 9: Photomicrograph showing spermatozoa (arrows) in the seminiferours tubules of testis in a rat of T1 group at 10 weeks of age, H&E, 400X.

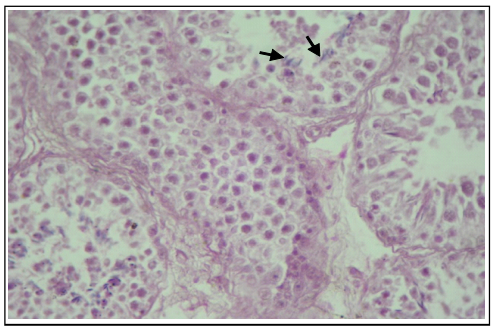

Fig 10: Photomicrograph showing spermatozoa (arrows) in the seminiferours tubules of testis in a rat of T2 group at 10 weeks of age, H&E, 400X.

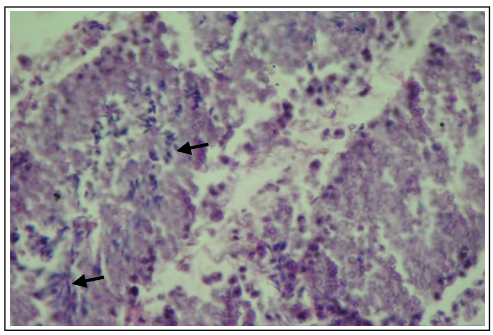

Fig 11: Photomicrograph showing more concentration of spermatozoa (arrows) in the seminiferours tubules of testis in a rat of T1 group at 12 weeks of age, H&E, 400X.

days after birth, respectively and the sperm count increased after 91 days of birth in male Wistar Han and Sprague-Dawley rats.

Histomorphology of Epididymis

Histomorphological studies revealed no sperm pack in cauda epididymis in all group rats at 6 weeks of age in the present investigation. However, at 8 weeks of age, the sperm pack was seen in the lumen of the epididymal tubules of the cauda epididymis of T1 (Fig 13) and T2 (Fig 14) groups but it was not seen in control (Fig 12) rats. The significant finding was that in T1 rats, the sperm pack was very compact at 10 weeks (Fig 15) onwards in cauda epididymis as compared to the control (Fig 16) and T2 (Fig 17) group of rats. This clearly

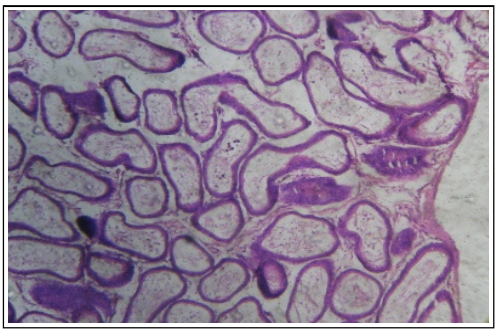

Fig 12: Photomicrograph showing lack of sperm pack in the epididymal tubules of cauda epididymis in a rat of control group at 8 weeks of age, H&E, 100X.

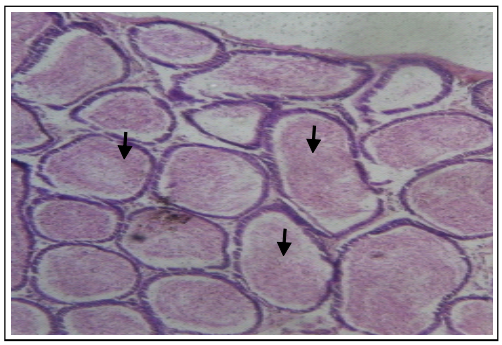

Fig 13: Photomicrograph showing sperm pack (arrows) in the epididymal tubules of cauda epididymis in a rat of T1 group at 8 weeks of age, H&E, 100X.

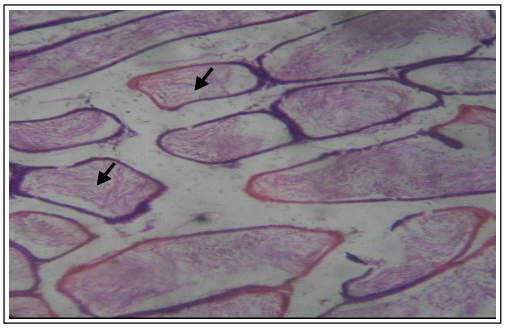

Fig 14: Photomicrograph showing sperm pack (arrows) in the epididymal tubules of cauda epididymis in a rat of T2 group at 8 weeks of age, H&E, 100X.

suggested that the zinc supplemented rats had received intrinsic stimulatory effect, most likely from zinc, on spermatogenesis to cause early appearance of male germ cells in the epididymis. McDowell *et al*. (1993) also stated that spermatogenesis and the development of primary and secondary sex organs in male are impacted by dietary zinc level. Further the present study showed that sperm pack in T1 group rats had more concentration of sperms as compared to the T2 group rats which might be due to beneficial effect of zinc @ 50 mg/kg body weight over dose rate of 100 mg/kg body weight per day.

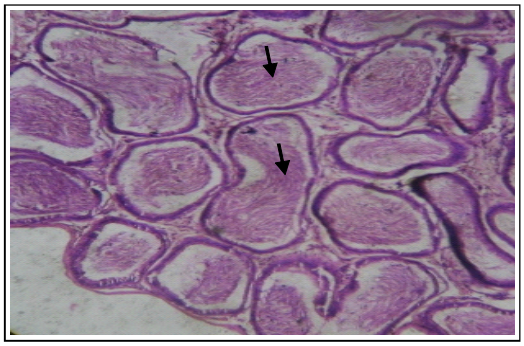

Fig 15: Photomicrograph showing very compact sperm pack (arrows) in the epididymal tubules of cauda epididymis in a rat of T1 group at 10 weeks of age, H&E, 100X.

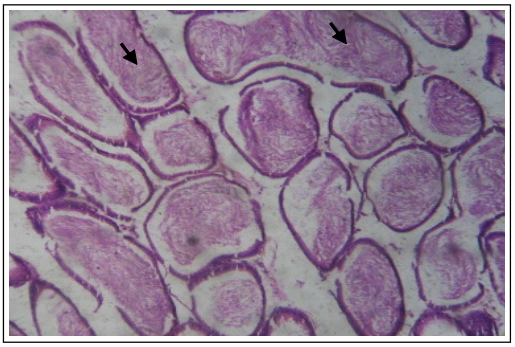

Fig 16: Photomicrograph showing compact sperm pack (arrows) in the epididymal tubules of cauda epididymis in a rat of control group at 10 weeks of age, H&E, 100X.

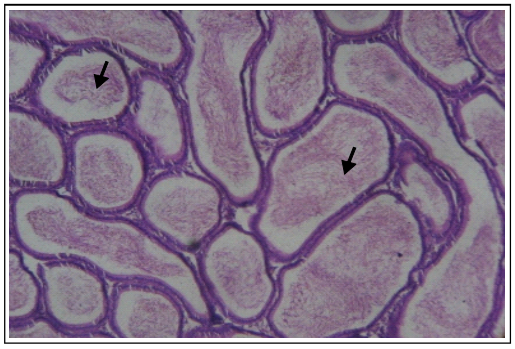

Fig 17: Photomicrograph showing compact sperm pack (arrows) in the epididymal tubules of cauda epididymis in a rat of T2 group at 10 weeks of age, H&E, 100X.

CONCLUSION

It was observed in this study that supplementation of zinc augmented the spermatogenesis in the experimental rats as elongated spermatids were visible in the seminiferous epithelium only in treatment (T1 and T2) groups at 6 weeks of age, with more concentrations being noticed in T1 group, no spermatozoa could be located in the same site in the control rats. Also, the concentration of spermatozoa seen in the seminiferous tubular lumen in the T1 group was more as compared to T2 treatment group at 8 weeks of age. So, it was seen that supplementation of zinc @50 mg/kg body weight/day gave better positive results in spermatogenesis as compared to zinc supplemented 50 mg/kg body weight/ day histomorphological studies of epididymis revealed no sperm pack in cauda epididymis in all groups of rats at 6 weeks of age. However, at 8 weeks of age, the sperm pack was seen in the lumen of the epididymal tubules of the cauda epididymis of T1 and T2 group. The significant finding was that in T1 rats the sperm pack was very compact at 10 weeks in cauda epididymis as compared to T2 and control group rats.

REFERENCES

Abbasi, A.A., Prasad, A.S. and Rabbani, P.R. (1979). Experimental zinc deficiency in man: Effect on spermatogenesis. Transactions of the Association of American Physicians 92: 292-302.

Abdella, A.M., Elabed, B.H., Bakhiet, A.O., Gadir, W.S.A. and Adam, S.E.I. (2011). *In vivo,* study on lead, cadmium and zinc supplementations on spermatogenesis in Albino rats. J. of Pharmacology and Toxicology. 6(2): 141-148.

Al-Ani, N.K., Al-Kawaz, U. and Saeed, B.T. (2015). Protective influence of zinc on reproductive parameters in male rat treated with cadmium. American Journal of Medical Science. 5(2): 73-81.

Anderson, M.B., Lepak, K., Farinas, V. and George, W.J. (1993). Protective action of zinc against cobalt induced testicular damage in the mouse. Reproductive Toxicology. 7: 49-54.

Bedwal, R.S. and Bahuguna, A. (1994). Zinc, copper and selenium in reproduction, Experientia. 50(7): 626-640.

Campion, S.N., Carvallo, F.R., Chapin, R.E., Nowland, W.S., Beauchamp, D., Jamon, R. and Hurtt, M.E. (2013). Comparative assessment of timing of sexual maturation in male Wistar Han and Sprague-Dawley rats. Reproductive Toxicology. 38: 16-24.

Croxford, T.P., McCormick, N.H. and Kelleher, S.L. (2011). Moderate Zinc deficiency reduces testicular Zip6 and Zip10 abundance and impairs spermatogenesis in mice. The Journal of Nutrition. 141: 359-365.

Davies, S. (1985). Zinc, Nutrition and Health. In: 1984-85 Yearbook of Nutritional Medicine. [Bland, J. (eds.)]. Keats Publishing, New Canaan, Conn. 113-152.

Devi, J., Goswami J., Sarmah B.C., Sarma K. and Bhattacharya, M. (2012). Histoenzymic studies on testis following oral zinc supplementation in Assam male goats. Indian Journal of Animal Sciences. 82(12): 1524-1525.

Dissanayake, D.M.A.B., Wijesinghe, P.S., Ratnasooriya, W.D. and Wimalasena, S. (2004). Effects of zinc supplementation on sexual behavior of male rats. Journal of Human Reproductive Science. 2(2): 57-61.

Egwurugwu, J.N., Ifedi, C.U., Uchefuna, R.C., Ezeokafor, E.N. and Alagwu, E.A. (2013). Effects of zinc on male sex hormones and semen quality in rats. Nigerian Journal of Physiological Science. 28: 017-022.

European Commission. (2003). Opinion of the Scientific Committee on Food on the Tolerable Upper Intake of Zinc. Health and Consumer Protection Directorate General. Directorate C-Scientific Opinions. Scientific Committee on Food SCF/CS/NUT/UPPLEV/62 Final.

Luna, L.G. (1968). Manual of Histological Staining Methods of Armed Forces Institute of Pathology. 3rd Edn. McGraw Hill Book Co., New York. pp. 153-173.

McDowell, L.R. and Conrad, J.H. (1993). Minerals for Grazing Ruminants in Tropical Regions, 2nd Edn. Animal Science Department, University of Florida.

McDowell, L.R. and Conrad, J.H., Hembry. (1993). Minerals for Grazing Ruminants in Tropical Regions, 2nd Edn. Animal Science Department, University of Florida.

Omu, A.E., Al-Azemi, M.K., Al-Maghrebi, M., Mathew, C.T., Omu, F.E., Kehinde, E.O., Anim, J.T., Oriowo, M.A., Memon, A. (2015). Molecular basis for the effects of zinc deficiency on spermatogenesis: An experimental study in the Sprague-dawley rat model. Indian Journal of Urology. 31: 57-64.

Taneja, S.K., Chadha, S. and Arya, P. (1995). Lipid-zinc interaction: Its effect on the testes of mice. British Journal of Nutrition. 73: 723-731.

Turgut, G., Abban, G., Turgut, S., Take, G. (2003). Effect of overdose zinc on mouse testis and its relation with sperm count and motility. Biological Trace Element Research. 96 (1-3): 271-279.