RESEARCH ARTICLE Indian Journal of Animal Research, Volume 57 Issue 3: 366-371 (March 2023)

Evaluation of Wound Healing Following Wide Surgical Resection and Subdermal Skin Flap Reconstruction for Management of Soft Tissue Tumours in 20 Dogs

Jasleen Kaur[1], N. Umeshwori Devi[1], Jitender Mohindroo[1], Devendra Pathak[2], Kuldip Gupta[3]

10.18805/IJAR.B-4323

ABSTRACT

Background: Tumours in dogs are increasing day by day and the mainstay of treatment is surgery. Wide surgical resection of soft tissue tumour in dogs is mandatory to prevent recurrence but it leads to the formation of a large skin defect requiring skin reconstruction. Among the various skin reconstruction techniques, subdermal skin flap is a simple reconstruction technique which can be performed by harvesting full-thickness skin from the surrounding skin without using special instruments. The current study was aimed to evaluate the healing and recurrence of tumours in dogs after wide surgical resection of tumour and subdermal skin flap reconstruction.

Methods: 20 dogs with soft tissue tumours presented to MSVH, GADVASU, Ludhiana, Punjab, during the period 2019-2020 were treated by wide surgical resection and subdermal skin flap technique. Routine clinico-physical, Hematobiochemical, Radiographic examinations, Fine Needle Aspiration Cytology, Histopathology and Culture Sensitivity Test were performed. Different types of flap were created according to the location of tumour and availability of the loose skin and wound healing was evaluated and complications recorded.

Result: Healing of subdermal flap was seen in 15 dogs (75%) while necrosis of subdermal flap was recorded in 5 dogs (25 %) of the cases of which 4 of them had mobility of flap base and were located in ventral abdomen (n=4) and limb (n=1). Overall tumour recurrence was recorded in 3 dogs (15%) which were located in limbs of which 2 dogs had lung metastasis and the tumours were malignant. It can be concluded that single pedicle advancement flaps for thoracic region; bipedicle advancement flap for thoracic and abdominal regions; rotational flaps for lateral thoracic region and transposition flap for proximal limb region are feasible skin reconstruction techniques for the repair of large skin defects in dogs.

Key words: Dogs, Soft tissue tumours, Subdermal skin flap.

INTRODUCTION

Subdermal plexus flap is a simple reconstruction technique in which full-thickness skin is separated from the surrounding skin and attached to the nearby defect by pulling or rotating the flap. As the flap can be harvested from surplus skin surrounding the defect, it can be used in various parts of the body like trunk, face and forehead (Hunt, 2012) but it cannot be performed in areas with movement or increased tension.

Wide surgical resection of soft tissue tumours performed in dogs to prevent local metastasis results in a large skin defect which cannot be covered by primary skin suturing. In such a situation where less skin in available for direct apposition, reconstruction techniques *viz.* subdermal plexus flaps, axial pattern flaps, skin grafts and other tension-relieving techniques is necessary (Tobias, 2010) to close wound and escalate the healing by primary intention. Besides this, wounds located on extremities have insufficient skin in the periphery of wound for primary closure (Kirpensteijn and Haar, 2013). The aim of the current study was to evaluate healing of subdermal skin reconstruction following wide surgical resection of soft tissue tumours in dogs. As subdermal skin flap receives blood supply from the terminal branches of the direct cutaneous vessels, the flap remains viable through the base of the flap. The elastic nature of dog's skin provide a suitable source for subdermal skin flap and can be exploited for coverage of large skin defects or in extremities. Since this technique requires minimal instrumentation and simple to perform, it can be used successfully for repair of large skin defect while reducing the healing time.

[1]Department of Veterinary Surgery and Radiology, College of Veterinary Science, Guru Angad Dev Veterinary and Animal Sciences University, Ludhiana-141 004, Punjab, India.
[2]Department of Veterinary Anatomy, College of Veterinary Science, Guru Angad Dev Veterinary and Animal Sciences University, Ludhiana-141 004, Punjab, India.
[3]Department of Veterinary Pathology, College of Veterinary Science, Guru Angad Dev Veterinary and Animal Sciences University, Ludhiana-141 004, Punjab, India.

Corresponding Author: N. Umeshwori Devi, Department of Veterinary Surgery and Radiology, College of Veterinary Science, Guru Angad Dev Veterinary and Animal Sciences University, Ludhiana-141 004, Punjab, India. Email: umeshwori.nameirakpam@gmail.com

How to cite this article: Kaur, J., Devi, N.U., Mohindroo, J., Pathak, D. and Gupta, K. (2023). Evaluation of Wound Healing Following Wide Surgical Resection and Subdermal Skin Flap Reconstruction for Management of Soft Tissue Tumours in 20 Dogs. Indian Journal of Animal Research. 57(3): 366-371. doi: 10.18805/IJAR.B-4323.

Submitted: 28-09-2020 **Accepted:** 04-03-2021 **Online:** 10-04-2021

MATERIALS AND METHODS

Twenty dogs of different breeds and either sex in the age group of 3 to 12.5 years suffering from soft tissue tumours, presented to Multi-speciality Veterinary Hospital, GADVASU, Ludhiana, from January 2019 to January 2020 were included in the current study. This clinical study was duly approved by the Institutional Ethics Committee.

Grouping: The dogs were divided into 3 groups based on the location of tumours *viz.*
Group I (n=8): Thorax.
Group II (n=8): Abdomen and Perineum.
Group III (n=4): Limbs.

Preoperative examinations

Routine clinico-physical and hematobiochemical examination on day 0 and 7 were performed. Chest radiography (lateral view) was taken to rule out metastatic lesions in the lungs. Fine Needle Aspiration Cytology (FNAC) of the tumours were done to reach a tentative diagnosis. Culture sensitivity test (CST) of blood was performed to select a suitable antibiotic.

Anaesthesia

All the dogs were kept off fed and off water for 12 hours prior to the surgery.

The dogs were premedicated by using a combination of Inj. Butorphanol (Inj. Butrum®, Aristo, New Delhi) @ 0.2 mg/kg; Inj. Atropine (Vulcan Laboratories Pvt. Ltd., Kolkata) @ 0.04 mg/kg and Inj. Acepromazine (Ilium-Acepril® -10, Troy Laboratories Pvt. Ltd., Australia) @ 0.05 mg/kg and inducted with Inj. Propofol (Neorof®, Neon Laboratories Ltd. India) @ 4 mg/kg after 10-15 minutes. Following Endotracheal intubation was performed and patient was maintained with Isoflurane (Isoflurane USP, Raman and Weil Pvt. Ltd. India) @ 1-2% in partial rebreathing system. Surgical site was prepared by clipping at least 20 cm of the hair on each side of incision site (Fossum, 2012).

Intraoperative

The operative site was painted using povidone iodine solution and a wide excisional margin of 2 cm around the tumour was kept and the tumour was removed. Different subdermal skin flap techniques like single pedicle advancement flap (SPAF), bipedicle advancement flap (BAF), rotational flap (RF) and transpositional flap (TF) were performed for reconstruction of large skin defects depending on the size of the skin defects, location of the growth and availability of loose skin around the skin defect. The skin flaps were sutured using monofilament nylon 1-0 in simple interrupted sutures. Indwelling catheters were placed in those cases where dead space is extensive. Type of flap (SPAF, BAF, RF and TF) and shape of flap (Rectangular, triangular, semilunar), adequacy of flap for coverage (adequate, non-adequate), skin tension at flap margins (mild-lengthening of flap, moderate-lenthening of flap with gapping at wound margin, severe-lengthening and conformational change of flap shape, gapping of wound margin), dog ear formation (present, absent) and surgical time (from marking of tumour margins to skin suturing) were noted.

Post-operative

Antibiotics were prescribed for a period of 5 days post-operatively. Inj. Intacef tazo (Intas Pharmaceuticals Ltd.) @ 15-25 mg/kg bid IM for 5 days and inj. Amikacin (Cadila Pharmaceuticals Ltd.) @ 10 mg/kg bid IM for 3 days as per the sensitivity test result. In cases of infection, the antibiotic therapy was prolonged for 7 days or more as per requirement of the case. Pain management was done prescribing NSAIDs Inj. Meloxicam (Intas Pharmaceuticals Ltd.) @ 0.2 mg/kg IM for 3 days once a day. Tab. Pantop-d (Aristo Pharmaceuticals Pvt. Ltd.) @ 1 mg/kg was given once a day for 5 days. Tablet Lyser forte (Comed Chemicals Ltd.) 10-20 mg per day. Dressing of wound was done using antiseptic dressing and antibiotic powder Nebasulf (Company Abbott). Pressure bandaging was done after the surgery and it was recommended to change the dressing after every 2-3 days till the suture removal. Suture removal was done on 14th or 15th day after the surgery depending upon the condition of the flap.

Tumour samples were processed for histopathological examination by the standard procedure (paraffin embedding technique and stained by H&E stain). Subdermal skin flaps were evaluated for healing postoperatively and scored using Southampton wound grading system (Bailey *et al.,* 1992): Grade 0- Normal healing; Grade I- Normal healing with a) some bruising, b- Considerable bruising, c- Mild erythema; Grade II- erythema plus other signs of inflammation: a- At one point, b- Around sutures, c- Along wound, d- Around wound; Grade III Clear or haemoserous discharge: a- At one point only (<2 cm), b- Along wound (>2 cm), c- Large volume, d) Prolonged (>3 days); Grade IV Pus/Purulent discharge: a- At one point only (<2 cm), b- Along wound (>2 cm); Grade V Deep or severe wound infection with or without tissue breakdown; haematoma requiring aspiration. Aesthetic appearance were graded as Excellent (normal healing without infection; no visible incision line and full hair growth), Good (healing with infection; full hair growth) and Scar formation (second intention healing of wound due to flap necrosis; no hair growth). Complications were recorded as minor (infection of suture line and discharges) and major (necrosis of flap, recurrence of growth).

RESULTS AND DISCUSSION

All the dogs had normal heart rate, respiration rate and rectal temperature at the time of presentation. Haematological parameters were also within the normal range, except ALKP the mean±standard deviation of ALKP was found higher in both preoperative (143.5±75.5) and postoperative period (230±127.8). This increase in ALKP may be tumour associated and surgery induced stress (Karayannopoulou *et al*., 2003; Karayannopoulou *et al.,* 2006 and Fernandez and Kidney, 2007). Chest radiography revealed metastatic lesions in the lungs in 2 dogs of age 4.5 years and 6 years.

FNAC of tumours in all dogs' revealed liposarcoma (n=2), hepatoid gland adenocarcinoma (n=2), mast cell tumour (n=2), osteochondrosarcoma (n=1), hemangiosarcoma (n=1) and abscess (n=1). Keratinzed cells with connective tissue were seen in 3 dogs and inflammatory cells were seen in 4 dogs. No tumour cells were detected in 2 dogs. Previous studies suggested that FNAC is reliable and useful diagnostic procedure for neoplastic masses and tumour type can be identified cytologically and histologically (Pavel *et al*., 2016 and Sabatlini *et al.,* 2017). In the current study too, FNAC was helpful in providing a tentative diagnosis and manage the tumour accordingly.

CST revealed systemic infection in 17 dogs with staphylococcus (n=14), streptococcus (n=2) and pseudomonas (n=1) which were resistant to 10 different antibiotics namely Cefaxime, Cefotaxime, Amikacin, Amoxycillin, Ampicillin, Cephalothin, Erythromycin, Trimethoprim, Sulfadiazine and Cephazolin. Cited literature reports that staphylococcus is the most common identified organism followed by streptococcus, enterococcus and pseudomonas (Normand *et al*., 2000; Prescott *et al*., 2002 and Awosile *et al.,* 2018) which is similar with the findings of the current study.

Single pedicle advancement flaps (n=3) (Fig1), bipedicle advancement flaps (n=8) (Fig 2) and rotational flap (n=8) (Fig 3) and transpositional flap (n=1) (Fig 4) were made in 20 dogs. Intraoperative findings revealed adequate skin defect coverage in all 20 dogs with severe skin tension (n=1), moderate skin tension (n=5) and mild skin tension (n=9) and no tension (n=5). A study by Prohaska and Cook (2020) reported that excessive tension or wound contracture occurs in rotation flap as tension does not disperse properly and results in distortion of surrounding tissue. Dog ears were present in 14 dogs (70%) resulting in uneven skin edges. Dog ear formation may increase the dead space which can increase the chance of post-operative complications but in the current study only two dogs with dog ear formation out of fourteen show dead space formation. Pressure bandaging in the post-operative period may have reduced the dead space below the flap. Previous studies by Weisberg *et al.* (2000) and Jaber *et al.* (2015) suggested that dog ears are common problem in plastic surgery practice and should be managed accordingly. The mean surgical time recorded was 72 minutes. Surgical resection and skin flap creation were time consuming procedures. Similar surgical time

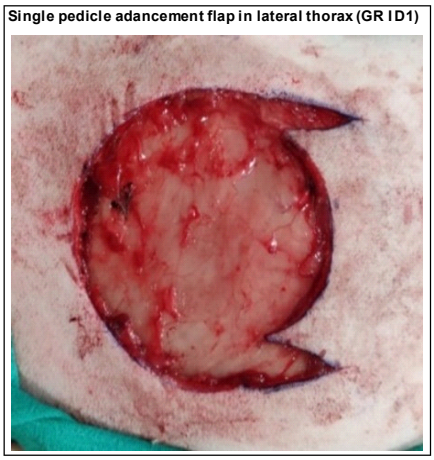

Fig 1a: Skin defect after resection of tumour from lateral chest wall (Grl D1) and creation of single pedicle advancement flap.



Fig 1b: Healthy skin flap margin on 3rd day post operative showing normal healing.



Fig 2a: Creation of large oval skin defect after resection of tumour from dorsum (GrII D1).



Fig 2b: Healthy skin flap margin on 3rd day post operative showing normal healing of bipedicle rectangular advancement flaps.

Rotational flap in perianal region (GR II D3)

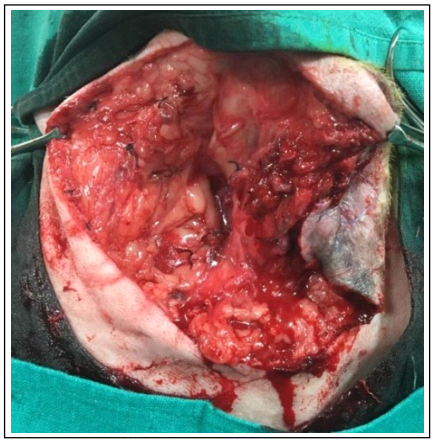

Fig 3a: Skin defect after tumour resection from perinum (GII, D3).



Fig 3c: Normal healing of rotational semilunar flap seen on 14^{h} day post operative.



Fig 3b: Healthy skin flap margin of rotational flap on 4th day post operative showing normal healing.



Fig 3d: Complete healing with hair growth over the incision line and skin flap on 30th post operative day.

was recorded by Salvatori *et al.* (2014) and Marsh *et al.* (2016) for skin reconstruction. The subdermal flaps were rectangular (n=3), H (n=8) and semilunar (n=9) in shape.

Postoperative evaluation revealed healing of flaps in 15 dogs (75%). Subdermal flap necrosis was recorded in 5 dogs accounting 25 % of the cases of which 4 of them had mobility of flap base. Movement around the flap may be a cause for flap necrosis (Prohaska and Cook 2020). Major complications were recorded in group II and III dogs of which flap necrosis was seen in growth located in ventral abdomen repaired with rotational flap (n=3) and single pedicle advancement (n=1) while one dog with transpositional flap of limb showed flap necrosis (Fig 4). Overall recurrence was recorded in 3 dogs (15%) from Group III of which 2 dogs had lung metastasis and the tumours were malignant. This implies the possibility of successful surgical management of malignant tumours by using wide surgical resection and skin reconstruction in those cases where there is no lung metastasis (Choi *et al.*, 2016). Another dog with mild interstitial lung pattern also showed recurrence of tumour in Group III even though it was benign. Recurrence in this dog may be due to insufficient growth removal and infection of the flap.

Wound scoring in Group I noted normal healing of all the skin flaps except one dog that recorded grade III. In Group II, Southampton wound grade V was recorded in 4 dogs and IV a in 2 dogs. In Group III, 2 dogs had 0 grade while the other dogs had V and IVb respectively. Wound score reveal better healing of subdermal flaps in Group I followed by Group III and Group II. The aesthetic appearances were excellent in all the subdermal flaps of Group I. In Group II, aesthetic appearance was excellent in two dogs, good in two, scar formation in three and could not be evaluated in one dog as the dog died in the post-operative period. In Group II, the aesthetic appearance was excellent in two dogs of which one had scar while another dogs had visible scar formation but one dog was euthanized due torecurrence of growth.

Histopathological findings revealed that 30% of the tumours were benign (n=6) while 65% of the tumours were malignant (n=13). FNAC findings of 10 dogs were in concurrent with the histopathological findings. But epidemiological study of canine neoplasm by Babu *et al.* (2012) shows that benign neoplasm are more common in dogs than malignant of which skin and soft tissue tumours

Transpositional flap at stifle (GR III D4)



Fig 4a: Circular skin defect after tumour resection around stifle region (Gr III, D4).



Fig 4c: Necrosis seen at the tip of the transpositional flap on 14^{h} day post operative.



Fig 4b: 3rd day post operative picture showing infection and blackening of tip of the transpositional flap.

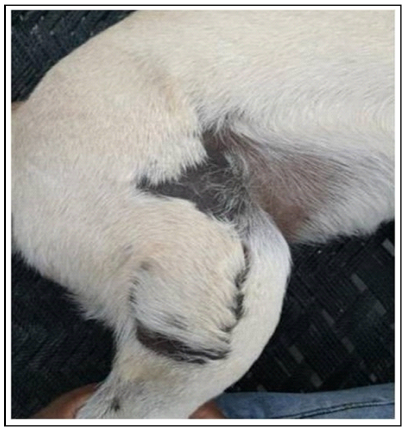

Fig 4d: 60th day post operative picture showing scar formation and less hair over the flap.

Table 1: Haematobiochemical parameters (mean±standard deviation) in normal healed and complicated dogs on day 0 (pre-operative) and day 7 (post-operative).

Variables	Normal healed (n=9)		Complications (n=11)	
	Day 0	Day 7	Day 0	Day 7
Haemoglobin	12.58±1.2	12.1±1.48	11.86±1.37*	11.00±1.68**
TLC	13484±2483.13	13788±2818.93	19437±7691.08	18383±6297.27
Neutrophil	83.55±10.19	80.00±3.5	84.54±6.83	81.72±8.05
Lymphocyte	9.44±4.47	11.11±2.08	11.63±6.37*	11.63±4.12
TEC	5.76×10^{6}±0.96	5.30×10^{6}±0.76	5.35×10^{6}±0.83*	5.15×10^{6}±0.66
PCV	39.07±3.52	37.51±3.35	39.40±4.35	37.51±4.71
ALKP	117.89±72.29	195.0±121.02	164.55±74.73*	258.64±131.57**

were frequently occurred. Majority of the skin tumours studied by Mathew *et al.* (2020), were also benign with more number of epithelial/melanocytic tumours.

Haematobiochemical analysis (Table 1) of normally healed and complicated dogs was performed by using SPSS 16 software and revealed that there was significant reduction in Hb on day 0 and day 7. Significant reduction in TEC value was seen in the complicated dogs as compared to normally healed dogs on day 0. The TLC value on day 0 and day 7 in both groups were higher than the normal but no significant difference was present in between normally healed and complicated dogs. Significant increase in lymphocyte count was recorded on day 0 in complicated group as compared to normally healed group. Significant increase in ALKP was recorded between normally healed group and complicated group preoperatively on day 0and postoperatively on day 7.

This concludes that low Hb, high lymphocyte count, low TEC and high ALKP may be prognostic factors for flap survival.

CONCLUSION

This study concludes that subdermal skin flap technique may be a suitable treatment for wide surgical excision of soft tissue tumour for prevention of recurrence but selection of suitable flap type will depend on the location of the defect. As per the study, subdermal rotational skin flap are unsuitable for ventral and abdominal defect coverage which may be due to infection and associated motion. Single pedicle advancement flaps for thoracic region; bipedicle advancement flap for thoracic and abdominal regions; rotational flaps for lateral thoracic region and transposition flap for proximal limb region are feasible skin reconstruction techniques for the repair of large skin defects in dogs.

ACKNOWLEDGEMENT

The authors duely acknowledge ICAR for funding the work under the scheme “All India Network Program on Diagnostic Imaging and Management of Surgical conditions in Animals”.

REFERENCES

Awosile, B.B., McClure, J.T., Saab, M.E. and Heider, L.C. (2018). Antimicrobial resistance in bacteria isolated from cats and dogs from the Atlantic Provinces, Canada from 1994-2013. The Canadian Veterinary Journal. 59(8): 885-893.

Babu, P., Abraham, M.J., Lalithakunjamma, C.R, Vijayan, N. and Narayanan, M.K. (2012). An epidemiological study of canine neoplasm. Indian Journal of Animal Research. 46: 196-198.

Bailey, I.S., Karran, S.E., Toyn, K., Brough, P., Ranaboldo, C. and Karran, S.J. (1992). Community surveillance of complications after hernia surgery. British Medical Journal. 304: 469-471.

Choi, J.W., Yoon, H.Y. and Jeong, S.W. (2016). Clinical oucome of surgically managed spontaneous tumors in 114 client owned dogs. Immune Network. 16(2): 116-25.

Fossum, T.W. (2012). Principles of Surgical Asepsis. In: Fossum T.W. Small Animal Surgery (4th Edn.) Elseiver Saunders, 3251 Riverport Lane, St. Louis, missouri 63043. Pp 22-31.

Fernandez, N.J. and Kidney, B.A. (2007). Alkaline phosphatase: Beyond the liver. Veterinary Clinical Pathology. 36(3): 223-233.

Hunt, G.B. (2012). Local or Subdermal Plexus Flaps. In: Veterinary Surgery Small Animal. [Johnston, S.A. and Tobias, K.M.], (1st Edn). Elseiver Saunders, 3251 Riverport Lane, St. Louis, Missouri 63043. Pp 1243-55.

Jaberm, O., Vischio, M., Faga, A. and Nicoletti, G. (2015). The three-bite technique: A novel method of dog ear correction. Archives of Plastic Surgery. 42(2): 223-25.

Karayannopoulou, M., Koutinas A.F., Polizopoulou, Z.S., Roubies, N., Fytianou, A., Saridomichelakis, M.N. and Kaldrymidou, E. (2003). Total serum alkaline phosphatase activity in dogs with mammary neoplasms: A prospective study on 79 natural cases. Journal of Veterinary Medicine. A, Physiology, Pathology, Clinical. 50(10): 501-05.

Karayannopoulou, M., Polizopoulou, Z.S., Roubies, N., Fytianou, A., Kaldrymidou, E., Koutinas, A.F., Tsiloi, V., Patsikas, M.N., Constantinidis, T.C. and Koutinas, C.K. (2006). Serum alkaline phosphatase isoenzyme activities in canine malignant mammary neoplasms with and without osseous transformation. Veterinary Clinical Pathology. 35(3): 287-290.

Kirpensteijn, J. and Haar, G.T. (2013). Reconstructive Surgery and Wound Management of the Dog and Cat (1st Edn). Department of Clinical Sciences of Companion Animals, Faculty of Veterinary Medicine, University of Utrecht, The Netherlands. Pp 13.

Kok, M.K., Chambers, J.K., Tsuboi, M., Nishimura, R., Tsujimoto, H., Uchida, K. and Nakayama, H. (2019). Retrospective study of canine cutaneous tumours in Japan, 2008-2017. Journal of Veterinary Medical Science. 81(8): 1133-1143.

Marsh, D., Patel, N.G., Rozen, W.M., Chowdhry, M., Sharma, H. and Ramakrishnan, V.V. (2016). Three routine free flaps per day in a single operating theatre: Principles of a process mapping approach to improving surgical efficiency. Gland Surgery. 5(2): 107-114.

Mathew, R., Sajitha, I.S., Nair, S.S., Krishna, B.D., Devi, S.S., Abraham, M.J. (2020). A Study of occurrence, gross and histopathological characteristics of canine cutaneous neoplasms. Indian Journal of Animal Research. 54: 1367-1372.

Normand, E.H., Gibson, N.R., Taylor, D.J., Carmichael, S. and Reid, S.W. (2000). Trends of antimicrobial resistance in bacterial isolates from a small animal referral hospital. Veterinary Record. 146(6): 151-155.

Pavel, G., Malancus, R. and Condrea, M. (2016). Fine needle aspiration cytology (FNAC) of neoplasms in dogs and cats, with emphasis on differential diagnosis - A retrospective study. Bulletin UASVM Veterinary Medicine. 73(1): 116-126.

Prescott, J.F., Hanna, W.J., Reid-Smith, R. and Drost, K. (2002). Antimicrobial drug use and resistance in dogs. The Canadian Veterinary Journal. 43(2): 107-116.

Prohaska, J. and Cook, C. (2020). Rotation Flaps. In StatPearls [Internet]. Treasure Island (FL): StatPearls Publishing. NCBI Bookshelf ID: NBK482371PMID: 29493993.

Sabattini, S., Renzi, A., Buracco, P., Defourny, S., Garnier-Moiroux, M., Capitani, O. and Bettini, G. (2017). Comparative assessment of the accuracy of cytological and histologic biopsies in the diagnosis of canine bone lesions. Journal of Veterinary Internal Medicine. 31(3): 864-871.

Salvatori, P., Paradisi, S., Calabrese, L., Zani, A., Cantu, G., Cappiello, J., Benazzo, M., *et al.* (2014). Patients’ survival after free flap reconstructive surgery of head and neck squamous cell carcinoma: A retrospective multicentre study. Acta Otorhinolaryngologica Italica. 34(2): 99-104.

Tobias, K.M. (2010). Lumpectomy and Primary Closure. In: Manual of Small Animal Soft Tissue Surgery. [Tobias K.M.], (1st Edn). 2121 State Avenue, Ames, Iowa 50014-8300, USA. Pp 17-26.

Weisberg, N.K., Nehal, K.S. and Zide, B.M. (2000). Dog-ears: A review. Dermatologic Surgery. 26(4): 363-370.