RESEARCH ARTICLE Indian Journal of Animal Research, Volume 57 Issue 4: 428-435 (April 2023)

Histological Studies on Ageing Changes in the Cornea of Indian Buffaloes (*Bubalus bubalis*)

A. Prasanth Babu[1], P. Jagapathi Ramayya[2], Y. Nagamalleswari[1], Makkena Sreenu[3], K. Lakshmi Kavitha[4]

10.18805/IJAR.B-4326

ABSTRACT

Background: Affections of eye commonly encountered in all the species of animals. If these not treated in time, the vision may be hampered, this may impair the physical ability, utility and productivity of animals leading to economic loss to the animal owners. Corneal dystrophies like basement membrane dystrophy, stromal dystrophy, endothelial dystrophy, corneal erosions and corneal ulcerations *etc*., seen in the aged buffaloes. The current study was carried out to establish basic data and to provide authentic information to the clinicians on ageing changes in eyes of buffaloes.

Methods: The study on age related changes in the cornea was conducted on 63 eye balls of locally available buffaloes of different breeds in and around Proddatur. These buffaloes were categorized into 3 groups based on their age *i.e*., group I (1-5 yrs), group II (6-10 yrs) and group III (11 yrs and above) buffaloes. The eyeballs were isolated and fixed with Davidson's fluid. The paraffin sections of cornea were subjected for routine histological study.

Result: The mean total thickness (µm) of cornea was increased from group I to III animals and it was 747.22±13.57, 853.33±11.05 and 897.22±8.06. Hence, The mean thickness (µm) of all five layers of cornea increased with advancement of age. Superficial corneal epithelial layer was made up of non keratinized stratified squamous epithelium with 6 to 7 layers at early age and 12-14 layers of cells in adult animals. The mean thickness (µm) of corneal epithelium in group I to III animals was 117.04±3.37, 122.59±2.23 and 133.71±3.55 respectively. Bowman's membrane of cornea was measured 12.97±0.86, 17.22±0.55 and 18.71±0.68 in group I, II and III animals respectively. The mean thickness (µm) of corneal stroma in group I to III animals was 600.75±10.33, 672.22±10.46 and 690.00±5.32 respectively. This was mainly due to progressive increase in number of collagenous lamellae. The keratocytes became thin in old animals. Thickness of posterior band zone (PBZ) of Descemet's membrane was increased with advancement of age. The mean thickness (µm) of Descemet's membrane and endothelium together was in group I, II and III animals was 16.48±0.91, 41.29±2.25 and 54.82±1.44 respectively. The corneal endothelial cells were enlarged and increased in size in old buffaloes. The age related pigmentation was also noticed in epithelium and stroma of cornea in animals of group III. Density of sub basal nerve plexuses between the stroma and the corneal epithelium was not altered with advancement of age.

Key words: Ageing changes, Cornea, Histology, Indian buffaloes.

INTRODUCTION

The buffalo holds an important role in Indian rural economy and contributing about 60% of total milk production in the country. Buffaloes are preferred over cattle in India because of their distinctive qualities such as better feed conversion efficiency, more resistance to diseases and higher milk fat percentage than in cows (Bandhopadhyay *et al*., 2003). Affections of eye were commonly encountered in all the species of animals. If these are not treated in time, the vision may be hampered, which may impair the physical ability, utility and productivity of animals leading to economic loss to the animal owners. Corneal dystrophies are most often seen in domestic old animals and were described according to localization within the cornea as basement membrane dystrophy, stromal dystrophy, endothelial dystrophy, corneal erosions, corneal ulcerations *etc*., (Bjerks, 2004). Even then very little research work has been done on sense organs like eyes in buffaloes. Hence, the present study was conducted to establish basic data on various layers of cornea to provide authentic information to the clinicians pertaining to ageing changes in eyes of buffaloes.

[1]Department of Veterinary Anatomy, College of Veterinary Science, Proddatur-516 360, YSR Kadapa, Andhra Pradesh, India.
[2]Department of Veterinary Anatomy, College of Veterinary Science, Tirupati-517 502, Chithoor, Andhra Pradesh, India.
[3]Department of Veterinary Surgery and Radiology, NTR College of Veterinary Science, Gannavaram-521 102, Krishna, Andhra Pradesh, India.
[4]Department of Microbiology, NTR College of Veterinary Science, Gannavaram-521 102, Krishna, Andhra Pradesh, India.

Corresponding Author: A. Prasanth Babu, Department of Veterinary Anatomy, College of Veterinary Science, Proddatur-516 360, Andhra Pradesh, India.
Email: prasanthankem@gmail.com

How to cite this article: Babu, A.P., Ramayya, P.J., Nagamalleswari, Y., Sreenu, M. and Kavitha, K.L. (2023). Histological Studies on Ageing Changes in the Cornea of Indian Buffaloes (*Bubalus bubalis*). Indian Journal of Animal Research. 57(4): 428-435. doi: 10.18805/IJAR.B-4326.

Submitted: 02-10-2020 **Accepted:** 04-05-2021 **Online:** 25-05-2021

MATERIALS AND METHODS

The present study was conducted during 2017 to 2019 on 63 eye balls collected from 63 buffaloes at Department of Veterinary Anatomy, College of Veterinary Science, Proddatur. The eye balls of buffaloes were collected from the slaughter houses in and around Proddatur town irrespective of breed and sex of the animal. The age of the buffaloes was estimated by dentition (Saini *et al*., 1982). These buffaloes were categorized into 3 groups based on their age *i.e*., group I (1-5 yrs), group II (6-10 yrs) and group III (11 yrs and above). The eyeballs were dissected out from the orbit immediately after slaughter and Davidson's fixative fluid was injected into the anterior and posterior compartments of eye balls for initial fixation. Then the samples were kept in the same fixative for 72 hours (Latendresse *et al*., 2009). After complete fixation the corneal samples were collected for histological studies (Luna, 1968). The paraffin sections were subjected to Hematoxylin and Eosin staining for routine histological study (Luna, 1968), van Gieson's stain for collagen fibers, Modified Palmgren's method for nerve fibers, Fontana-masson method for melanin pigment (Singh and Sulochana, 1996) were carried out. Micrometry was done to measure the different layers of the cornea *viz*., corneal epithelium, Bowman's layer, stroma or substantia propria and Descemet's membrane and endothelium were measured in the present study. These observations were subjected to statistical analysis (Snedecor and Cochran, 1994) by using SPSS software.

RESULTS AND DISCUSSION

In the present study the histological changes in the various layers of the cornea were noted in various groups of buffaloes. The cornea of buffaloes was made up of five layers *i.e*. corneal epithelium, anterior limiting membrane or Bowman's membrane, substantia propria or stroma, Descemet's membrane and corneal endothelium (Fig 1).

Ageing changes in the corneal epithelium

The corneal epithelium of buffaloes was made up of non keratinized stratified squamous epithelium and consisted of 6-7 layers in 5 months of age (Fig 2), whereas, the number of layers gradually increased to 12-14 at the end of first year (Fig 3). Dellmann and Eurell (2006) also reported 4-12 layers thick non keratinized stratified epithelium in domestic animals. In the present study three types of cellular layers were noted in the cornea without any distinct boundaries *viz*., stratum basale, stratum intermedium and stratum superficial layers. The stratum basale contained low columnar to high cuboidal type during 5 months of postnatal age and they became high columnar type with advancement of age as reported by Wiley *et al*., (1991) and Li *et al*., (2007) in humans. The base and apex of these cells were narrow but they were bulged at the middle due to the presence of rounded nucleus. These cells were capable of mitosis besides the stem cells and transient amplifying cells and were the source of wing and superficial cells in all three groups of animals (Fig 3).

The intermediate zone cells (wing cells) were round to oval and their cytoplasm was more granular. These cells were present in 2-3 cell layers at 5 months of postnatal age, but they were in 6-7 layers with advancement of age. The nuclei of these were round to oval in shape and heterochromatic in all age group of animals (Fig 3). Similar findings were also reported by Dellmann and Eurell (2006) in the cornea of adult domestic animals. But, Del Monte and Terry Kim (2011) observed that these cells were flat and 2 to 3 cells thick in the cornea of humans.

The outer or superficial cells were elongated with tapered ends and arranged in 4 to 5 layers. They showed

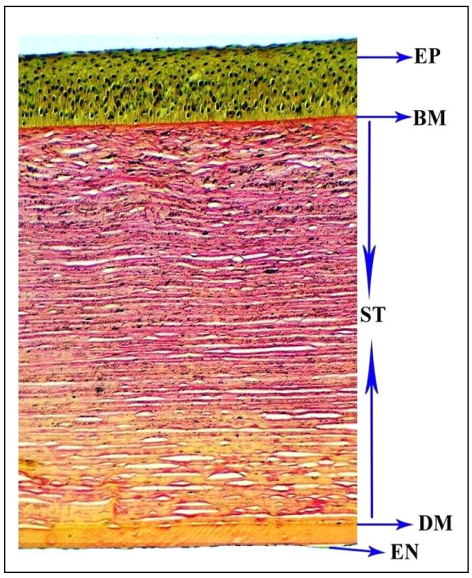

Fig 1: Photomicrograph of cornea of 4 years old buffalo showing Corneal Epithelium (EP), Bowman's membrane (BM), Stroma (ST), Descemet'smembrane (DM) and Corneal Endothelium (EN). Van Gieson's X 100.

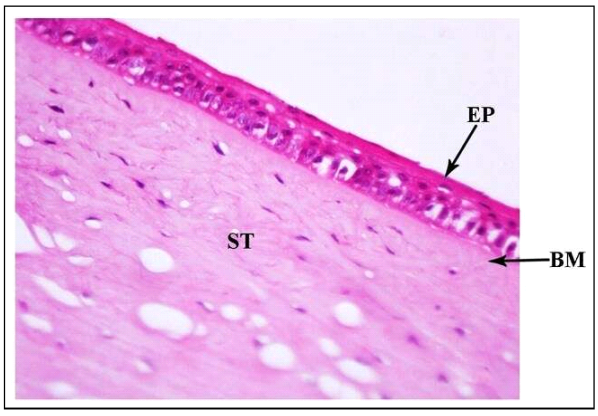

Fig 2: Photomicrograph of cornea of 5 months old buffalo showing 6-7 layers of Corneal Epithelium (EP), Bowman's membrane (BM) and Stroma (ST). Haematoxylin and Eosin X 400.

distinct nucleus with less cytoplasm. The shape of the nuclei in superficial cells of first group was flat and spindle shaped, but they became large and more elongated with advancement of age (Fig 3). Kelly *et al*., (1971) also stated that none of the corneal cells lost their nuclei in normal keratinisation process in corneal epithelium of humans similar to the present observations in buffaloes. Doughty *et al*., (1995) and Farjo *et al*., (2008) reported that matted microplicae and apical microvilli on superficial corneal epithelial cells of humans, but in the present study no cellular modifications were observed on the superficial cells of the cornea in buffaloes (Fig 3).

In the present study numerous sub basal nerve plexuses were observed in the superficial stroma, immediately under the Bowman's membrane. These plexuses were surrounded by numerous neurolemmocytes. The unmyelinated nerve fibers from these plexuses penetrated the Bowman's membrane and reached the epithelium and formed sub epithelial nerve plexuses and they were distributed deeply between the basal, wing and superficial cells of corneal epithelium (Fig 4 and 5). Similarly, Kelly *et al*., (1971; Schimmelpfennig, (1982); Muller *et al*., (1996), Oliveira-Soto and Efron (2001) and Muller *et al*. (2003) also noted sub basal nerve plexus in superficial epithelium of cornea of humans in support of our present findings. Further, in the present study the density of nerve fibres in corneal epithelium of buffaloes was not altered with age, similarly Erie *et al*., (2005) not reported any changes in distribution and density of nerve fibres in cornea of humans.

The pigmentation appeared sparsely between the basal cells and wing cells of the corneal epithelium in group I buffaloes, but it was increased from group II to group III buffaloes (Fig 6). This pigmentation was believed to be occurred from the dispersed melanocytes from the limbus. It was in accordance with the observations made by Holloway (1969) in the corneal epithelium of old dogs and hogs.

The mean thickness (µm) of corneal epithelium in group I, II and III was 117.04±3.37, 122.59±2.23 and 133.71±3.55 µm respectively. There was a significant ($P<0.01$) increase in thickness of epithelium of group III buffaloes when compared to group I and II (Table 1 and Fig 13).

Ageing changes in the anterior limiting membrane or Bowman's membrane

A homogenous and non cellular Bowman's membrane of cornea was noted below the basal layer of corneal epithelium (Fig 7). Contrary to this Raghavan (1964) and Banks (1993) stated that the Bowman's membrane may not be distinct in different domestic animals. In the present study it was made up of predominately collagen fibres. Whereas, Dellmann and Eurell (2006) noted more reticular fibers in Bowman's membrane of domestic animals and Mazher (2012) noted elastic fibers in goats.

In the present study the mean thickness (µm) of Bowman's membrane was increased with advancement of

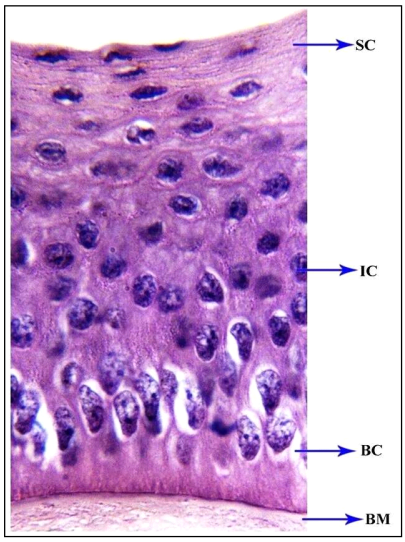

Fig 3: Photomicrograph of corneal epithelium of group 2 buffalo showing Basal cells with mitotic figures (BC), Intermediate Cells (IC), Superficial Cells (SC) and Bowman's membrane (BM). Haematoxylin and Eosin × 1000.

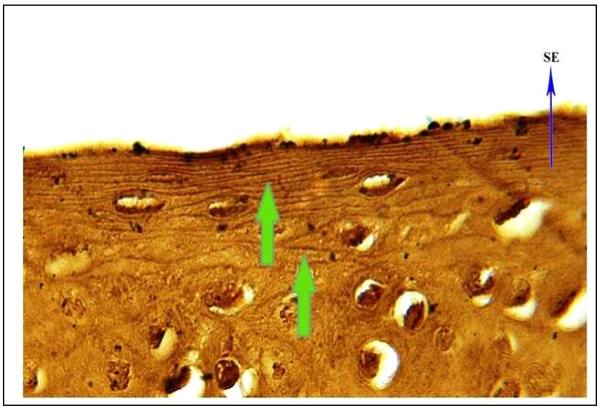

Fig 4: Photomicrograph of corneal epithelium of buffaloe showing nerve fibers (Arrow) between Basal cells (BC). Modified Palmgren's method × 1000.

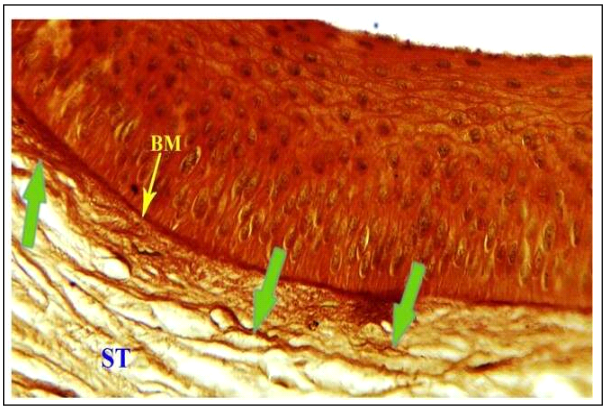

Fig 5: Photomicrograph of Corneal Stroma (ST) of 3-4 years old buffaloes showing subbasal nerveplexuses (Arrow) below the Bowman's membrane (BM). Modified Palmgren's method × 400.

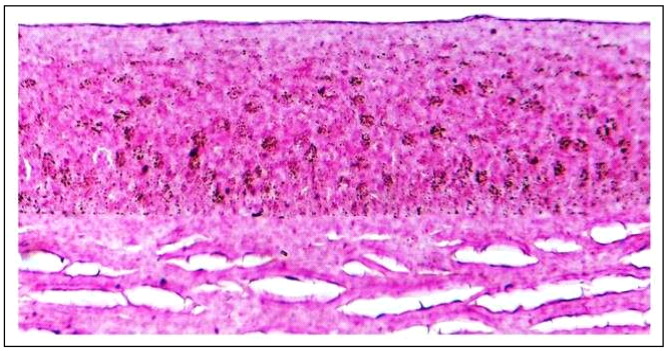

Fig 6: Photomicrograph of corneal epithelium of buffaloeshowing melanin pigment granules between the cells. Fontana - masson staining method × 100.

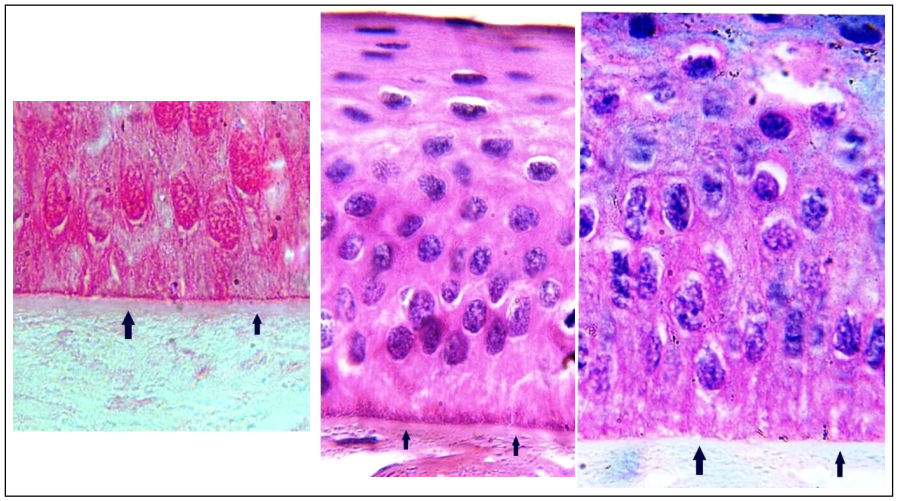

Group 1 **Group 2** **Group 3**

Fig 7: Photomicrograph of cornea of group 1, 2 and 3 buffaloes showing Bowman's membrane (Arrow). Haematoxylin and Eosin × 1000.

age in buffaloes *i.e.* from group I to III animals (Fig 7). Berlau *et al*., (2002) also reported an increase in thickness of Bowman's membrane with advancement of age in humans. Contrary to this, Jacobsen *et al*., (1984) reported a decrease in thickness of Bowman's membrane with advancement of age in humans.

The mean thickness (µm) of Bowman's membrane in group I, II and III was 12.97±0.86, 17.22±0.55 and 18.71±0.68 respectively. There was a significant (P<0.01) increase in thickness of Bowman's membrane of group III buffaloes when compared to group I and II (Table 1 and Fig 13).

Ageing changes in the substantia propria or stroma

The stroma of cornea was well developed and it constitutes the major component of the cornea in all age groups of buffaloes. The stroma was comprised of a uniform collagen fibril matrix with loosely arranged fibers in the rostral half and tightly packed in posterior half in early aged animals (Fig 8), whereas from 3rd year onwards to the group II and III animals the fibers were tightly packed in the entire stroma (Fig 9). Further, the stroma of cornea was different from other collagenous structures in its transparency, which was the result of precise organization of the stromal fibers and extracellular matrix. Fini and Stramer (2005) and Torricelli and Wilson (2014) described that these fibers were surrounded by specialized proteoglycans, keratin sulfate, chondroitin sulfate, dermatin sulfate side chains, which regulate hydration and structural properties of human eye.

The mean thickness (µm) of corneal stroma in group I, II and III was 600.75±10.33, 672.22±10.46 and 690.00±5.32 µm respectively. There was a significant (P<0.01) increase in thickness of stroma of group III buffaloes when compared to group I and II (Table 1 and Fig 13). The increase in the total thickness of stroma of cornea between group I and group III animals was principally due to progressive increase in number of collagenous lamellae. According to Daxer *et al*., (1998) the main factor causing increase in stromal thickness in adult humans was due to an increased collagen fibril diameter, axial period and intermolecular bragg spacing in the stroma of cornea. Pigmentation of the stroma was observed in aged buffaloes. This pigment represents the remnants of past metabolic activities of the stromal cells of the cornea as opined by Bohnke and Masters (1999) in old

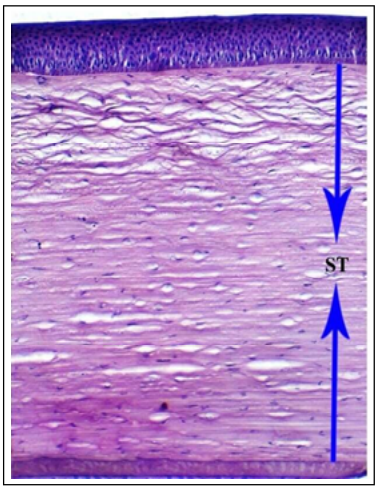

Fig 8: Photomicrograph of Corneal Stroma (ST) of group I (2 years) buffaloes showing loosely arranged collagen fibers in the rostral half and tightly packed fibers in posterior half. Haematoxylin and Eosin × 100

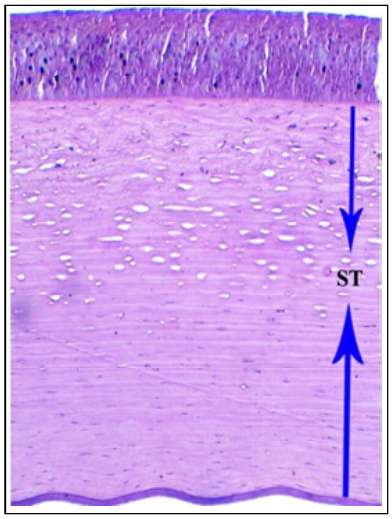

Fig 9: Photomicrograph of Corneal Stroma (ST) of group III (14 years) buffaloes showing tightly packed collagen fibers in the stroma. Haematoxylin and Eosin × 100.

aged humans. They also reported small highly reflective microdots in the stromal matrix of aged humans.

Keratocytes (Fibrocytes) were spindle shaped and interposed between the collagen fibers, which were elongated and comparatively thicker in the group I animals than the Group III animals. These cells were supposed to secrete collagen and matrix of the stroma. Jester *et al*., (1999) and Del Monte and Terry Kim (2011) noted that keratocytes were the major cells of the stroma, which maintain the integrity of this layer, producing collagen, glycosaminoglycans and matrix metalloproteinases in humans as noted in the present study. The number and density of keratocytes were decreased with advancement of age in buffaloes *i.e.* from group I to III animals. Similarly, Patel *et al*., (2001) also reported that keratocyte density was negatively correlated with increase in age and decreased 0.45 per cent per year in humans. Similarly, Berlau *et al*., (2002); Niederer *et al*., (2007) noted that keratocytes declined by 0.9% per year in the anterior stroma, 0.3% per year in the mid stroma and 0.3% per year in the posterior stroma in human with advancement of age. In the present study the nuclei of keratocytes were thick and spindle shaped in group I and they were thin in group II and III animals.

Ageing changes in the Descemet's membrane

The Descemet's membrane was a homogenous and non cellular fibrous band, plays a role in several important functions including collimation of light, endothelial cell differentiation, proliferation and structural integrity. It was predominately consisted of collagen fibers. It showed a dark anterior band zone and light posterior band zone in buffaloes (Fig 10). Kato *et al*., (2003); Gottsch *et al*., (2005) also noted similar findings in humans. In the cornea of mice collagen fibers in Descemet's membrane were mainly type IV, VIII, XVIII fibers and also non-collagenous components including fibronectin, laminin, nidogen, heparin sulfate and dermatin sulfate (Hopfer *et al*., 2005). The thickness of anterior band zone (ABZ) was not altered from group I to group III animals, whereas the posterior band zone (PBZ) thickness was altered and increased with age advancement *i.e.* in group III animals (Fig 11 and 12) as reported by Johnson *et al*., (1982) and Murphy *et al*., (1984) in human. Further, they reported that over the ensuing decades of life,



Fig 10: Photomicrograph of Descemet's membrane (DM) of cornea of buffaloes showing dark Anterior band zone (ABZ) and light Posterior band zone (PBZ) and Corneal Endothelium (EN). Haematoxylin and Eosin × 400.

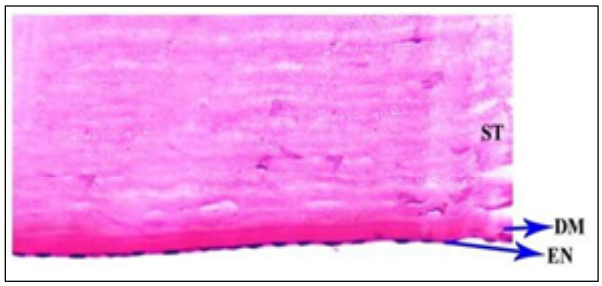

Fig 11: Photomicrograph of cornea of group I buffaloes showing closely arranged corneal endothelium (EN), Descemet's membrane (DM) and stroma (ST). Haematoxylin and Eosin × 400.

Table 1: Mean thickness (µm) of different layers of cornea in buffaloes of different age groups.

	Group I	Group II	Group III
Corneal epithelium	117.04±3.37^{b}	122.59±2.23^{b}	133.71±3.55^{a}
Bowman's membrane	12.97±0.86^{b}	17.22±0.55^{a}	18.71±0.68^{a}
Stroma	600.75±10.33^{b}	672.22±10.46^{a}	690.00±5.32^{a}
Decemet's membrane	16.48±0.91^{c}	41.29±2.25^{b}	54.82±1.44^{a}
Total thickness	747.22±13.57^{c}	853.33±11.05^{b}	897.22±8.06^{a}

Mean values with different superscripts in rows differ significantly (P<0.05 and 0.01) One way ANOVA, SE: Standard error.

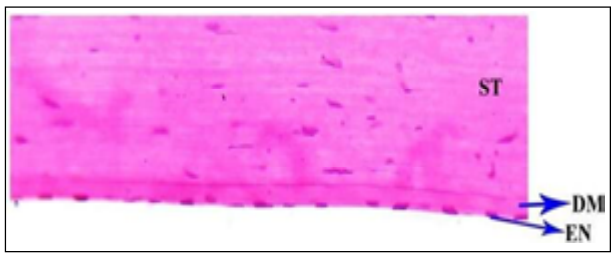

Fig 12: Photomicrograph of cornea of group III buffaloe showing sparsely arranged corneal endothelium (EN), Descemet's membrane (DM) and stroma (ST). Haematoxylin and Eosin X 400.

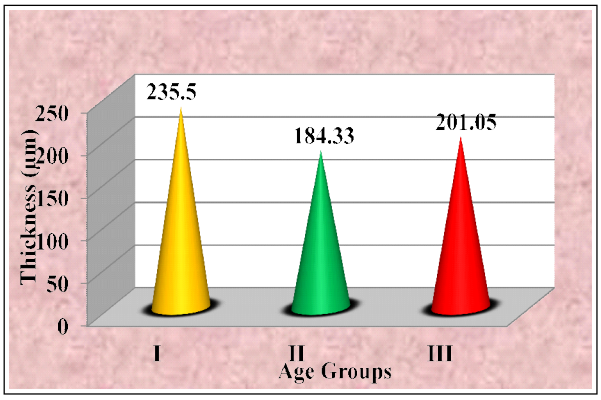

Fig 13: Graph showing mean total thickness (µm) of retina in buffaloes of different age groups.

the ABZ remains well-demarcated and stable in thickness and appearance. In contrast, the posterior portion of the membrane directly subjacent to the endothelium progressive thickening of the PBZ contributed to the age-dependent growth of Descemet's membrane from approximately 3 µm at birth to 5-6 µm at 20 years of age and to 13 µm at 80 years of age.

The mean thickness (µm) of Descemet's membrane and endothelium together in group I, II and III animals was 16.48±0.91, 41.29±2.25 and 54.82±1.44 µm respectively. There was a significant (P<0.01) increase in thickness of Descemet's membrane of group III buffaloes when compared to group I and II (Table 1 and Fig 13).

Ageing changes in the corneal endothelium

In buffaloes the corneal endothelial cells were squamous type and single layered. These cells were small and firmly adherent to each other and to the Descemet's membrane. In histological profiles the cells were tightly packed and their nuclei were small and placed close to each other with little intervening cytoplasm in buffaloes of group I (Fig 11). The size of the corneal endothelial cells was increased with advancement of age, whereas the number of corneal endothelial cells decreased with advancement of age in buffaloes. In group II animals, the cells were further increased in size and greatly enlarged in group III buffaloes when compared with the group I. In group III animals, the intercellular space is more and the cell numbers was relatively less when compared with the young animals (Fig 12). These observations suggested that there was a regular degeneration of corneal endothelial cells and there was no replacement of the endothelial cells, leading to decrease in their population with advancement of age in buffaloes. It is in accordance with the findings of Capella (1971) in humanbeings, he stated that the morphologic characteristics of the endothelium remain fairly consistent between the ages of 15 and 50 years, but the individual cells began to increase in size and showed an irregularity in their morphology at about 60-65 years in humans Jun *et al*., (2006) reported that in mouse central corneal endothelial cell density showed a rapid declined by 5232±892 cells/mm^2 at 2 weeks and 2532±112 cells/mm^2 at 16 weeks of age. There after, cell density declined more slowly, reaching 2004±134 cells/mm^2 at 24 months of age. Gambato *et al*., (2014) reported in the cornea of humans as endothelial cell density decreased from approximately 3000-4000 cells/mm^2 at birth to 2500 cells/mm^2 in late adulthood in humans.

The total thickness (µm) of cornea in group I, II and III animals was 747.22±13.57, 853.33±11.05 and 897.22±8.06 µm respectively. These findings suggested that there was a significant (P<0.01) increase in total thickness of cornea with advancement of age in buffaloes (Table 1 and Fig 13) due to the enhancement of cellular and fibrous population in different layers of cornea.

CONCLUSION

The study on age related changes in the cornea revealed that superficial corneal epithelial layer was made up of 6 to 7 layers at early age and 12-14 layers of cells in adult animals. Thickness of Bowman's membrane was increased with advancement of age. Collagen fibrils in stroma were loosely arranged in young animals and tightly packed in aged animals. The keratocytes were elongated and thick in young animals and thin in old animals. The total thickness of stroma

of cornea in group I to group III animals was increased mainly due to progressive increase in number of collagenous lamellae. The thickness of posterior band zone (PBZ) of Descemet's membrane was increased with advancement of age. The corneal endothelial cells were enlarged and increased in size in old buffaloes. The age related pigmentation was also noticed in epithelium and stroma of cornea in animals of group III. The mean total thickness of cornea was increased from group I to III animals.

REFERENCES

Bandyopadhyay, A.K., Ray, P.R. and Ghatak, P.K. (2003). Effective Utilization of Buffalo Milk for Manufacturing Dairy Products. 4th Asian Buffalo Congress Lead Papers, 191.

Banks, W.J. (1993). Applied Veterinary Histology. 3rd Edn. Mosby Year Book. St. Louis, Baltimore.

Berlau, J., Becker, H.H., Stave, J., Oriwol, C. and Guthoff, R.F. (2002). Depth and age-dependent distribution of keratocytes in healthy human corneas: A study using scanning-slit confocal microscopy *in vivo*. Journal of Cataract and Refractive Surgery. 28: 611-616.

Bjerks, E. (2004). Ocular Diseases of the Aging Dog. World Small Animal Veterinary Association Congress Proceedings. Norwegian School of Veterinary Science, Department of Companion Animal Clinical Sciences, Oslo, Norway.

Bohnke, M. and Masters, B.R. (1999). Confocal microscopy of the cornea. Progress in Retinal and Eye Research. 18(5): 553-628.

Capella, J.A. (1971). The pathology of corneal endothelium. Annals of Ophthalmology. 3: 397-400.

Daxer, A., Misof, K., Grabnerj, B., Ettl, A. and Fratzl, P. (1998). Collagen fibrils in the human corneal stroma: Structure and aging. Investigative Ophthalmology and Visual Science. 39: 644-648.

Del Monte, D.W. and Terry Kim. (2011). Anatomy and physiology of the cornea. Journal of Cataract and Refractive Surgery. 37: 588-598.

Dellmann, H. and Eurell, J.A. (2006). Eye and Ear. Textbook of Veterinary Histology. 6th Edn. Lea and Febiger. Philadelphia. pp. 423-456.

Doughty, M.J., Petrou, S. and Macmillan, H. (1995). Anatomy and morphology of the Cornea of bovine eyes from a slaughterhouse. Canadian Journal of Zoology. 73: 2159-2165.

Erie, J.C., McLaren, J.W., Hodge, D.O. and Bourne, W.M. (2005). The effect of age on the corneal sub basal nerve plexus. Cornea. 24(6): 705-709.

Farjo, A., Mc Dermott, M. and Soong, H.K. (2008). Corneal Anatomy, Physiology and Wound Healing. [Yanoff, M. and Duker, J.S. Ophthalmology]. 3rd Edn. St. Louis, M.O., Mosby. pp: 203-208.

Fini, M.E. and Stramer, B.M. (2005). How the cornea heals; Cornea-specific repair mechanisms affecting surgical outcomes. Cornea. 24(1): 2-11.

Gambato, C., Longhin, E., Catania, A.G., Lazzarini, D., Parrozzani, R. and Midena, E. (2014). Ageing and corneal layers: An *in vivo* corneal confocal microscopy study. Grafe's Archive for Clinical and Experimental Ophthalmology. 53(2): 267-275.

Gottsch, J.D., Zhang, C., Sundin, O.H., Bell, W.R., Stark, W.J. and Green, W.R. (2005). Fuchs *Corneal dystrophy*: Aberrant collagen distribution in an L450W mutant of the COL8A2 gene. Investigative Ophthalmology and Visual Science. 46: 4504-4511.

Holloway, C.L. (1969). Changes with Age in the Eye of the Dog and Hog from Birth to Senility. Thesis submitted to Iowa State University.

Hopfer, U., Fukai, N., Hopfer, H., Wolf, G., Joyce, N., Li, E. and Olsen, B.R. (2005). Targeted disruption of Col8a1 and Col8a2 genes in mice leads to anterior segment abnormalities in the eye. Faseb Journal.19: 1232-1244.

Jacobsen, I.E., Jensen, O.A. and Prause, J.U. (1984). Structure and composition of Bowman's membrane. Study by frozen resin cracking. Acta Ophthalmologica (Copenhagen). 62(1): 39-53.

Jester, J.V., Moller-Pedersen, T., Huang, J., Sax, C.M., Kays, W.T., Cavangh, H.D., Petroll, W.M. and Piatigorsky, J. (1999). The cellular basis of corneal transparency: Evidence for corneal crystalline. Journal of Cellular Science. 112: 613-622.

Johnson, D.H., Bourne, W.M. and Campbell, R.J. (1982). The ultra structure of Descemet's membrane changes with age in normal corneas. Archives of Ophthalmology. 100: 1942-1947.

Jun, A.S., Chakravarti, S., Edelhauser, H.F. and Kimos, M. (2006). Ageing changes of mouse corneal endothelium and Descemet's membrane. Experimental Eye Research. 83: 890-896.

Kato, T., Chang, J.H. and Azar, D.T. (2003). Expression of type XVIII collagen during healing of corneal incisions and keratectomy wounds. Investigative Ophthalmology and Visual Science. 44: 78-85.

Kelly, E.D., Wood, L.R. and Enders, A.C. (1971). Bailey's Textbook of Microscopic Anatomy. 8th Edn. Williams and Wilkins, Baltimore. pp: 822-865.

Latendresse, J.R., Warbrittion, R.A., Jonassen, H. and Creasy, M.D. (2009). Fixation of testis and eyes using a modified Davidson fluid: Comparison with Bouin's fluid and conventional Davidson's fluid. Toxicology Pathology. 30: 524-533.

Li, W., Hayashida, Y., Chen, Y.T. and Tseng, S.C.G. (2007). Niche regulation of corneal epithelial stem cells at the limbus. Cell Research. 17: 26-36.

Luna, L.G. (1968). Manual of Histological Staining Methods of Armed Forces Institute of Pathology. 3rd Edn. Mc Graw Hill Book Co. NewYork. pp: 153-173.

Mazher, K.M. (2012). Light and scanning electron microscopical studies of goat's cornea. Assiut Veterinary Medicine Journal. 58(135): 121-124.

Muller, L.J., Marfurt, C.F. and Kruse, F. (2003). Corneal nerves: Structure, contents and function. Experimental Eye Research. 76: 521-542.

Muller, L.J., Pels, E. and Vrensen, G.F. (1996). Ultra structural organization of human corneal nerves. Investigative Ophthalmology and Visual Science. 37: 476-488.

Murphy, C., Alvarado, J. and Juster, R. (1984). Prenatal and postnatal growth of the human Descemet's membrane. Investigative Ophthalmology and Visual Science. 25(12): 1402-1415.

Niederer, R.L., Perumal, D., Sherwin, T. and Mc Ghee, C.N.J. (2007). Age-related differences in the normal human cornea: A laser scanning *in vivo* confocal microscopy study. British Journal of Ophthalmology. 91: 1165-1169.

Oliveira-Soto, L. and Efron, N. (2001). Morphology of corneal nerves using confocal microscopy. Cornea. 20(4): 374-384.

Patel, S., McLaren, J., Hodge, D. and Bourne, W. (2001). Normal human keratocyte density and corneal thickness measurement by using confocal microscopy *in vivo*. Investigative Ophthalmology and Visual Science. 42(2): 333-339.

Raghavan, D (1964). Anatomy of the Ox; With Comparative Notes on the Horse, Dog and Fowl. Indian Council of Agricultural Research, New Delhi.

Saini, A., Gill, R.S. and Gill, S.S. (1982). Dentition and ageing in Murrah buffaloes. Indian Journal of Dairy Science. 35(3): 257-262.

Schimmelpfennig, B. (1982). Nerve structures in human central corneal epithelium. Graefe's Archives for Clinical and Experimental Ophthalmology. 218: 14-20.

Singh, U.B. and Sulochana, S. (1996). Hand Book of histological and Histochemical Techniques. Premier Publishing House. Hyderabad. pp: 1-111.

Snedecor, G.W. and Cochran, W.G. (1994). Statistical Methods. 6th Edn. Oxford and IBH Publishing Co. Bombay.

Torricelli, A.A., Singh, V., Santhiago, M.R. and Wilson, S.E.(2013). The corneal epithelial basement membrane: Structure, function and disease. Investigative Ophthalmology and Visual Science. 54(9): 6390-6400.

Torricelli, A. and Wilson, S.E. (2014). Cellular and extracellular matrix modulation of corneal stromal opacity. Experimental Eye Research. 129: 151-160.

Wiley, L., Sundar Raj, N., Sun, T.T. and Thoft, R.A. (1991). Regional heterogeneity in human corneal and limbal epithelia: An immunohistochemical evaluation Investigative. Ophthalmology and Visual Science. 32: 594-602.