RESEARCH ARTICLE Indian Journal of Animal Research, Volume 57 Issue 5: 662-665 (May 2023)

Soil-borne Septicaemic Colibacillosis in Neonatal Lambs: Salient Observations

S. Jegaveera-Pandian[1], Jyoti Kumar[2], G.G. Sonawane[1], G.R. Gowane[3], C.P. Swarnkar[1], S.R. Sharma[1]

10.18805/IJAR.B-4327

ABSTRACT

Background: In sheep, *Escherichia coli* infection can occur as asymptomatic entity to septicaemic episode. Chiefly, it causes heavy mortality in lambs and devastates the farm economy. With an objective of documenting the salient epidemiological and clinico-pathological observations in this naturally occurred outbreak of septicaemic colibacillosis, this communication is made herewith.

Methods: In February 2019, sudden death in lambs was observed in three flocks of sheep. Carcasses were subjected for necropsy and histopathological examination. Swab samples from heart, abomasum, intestines, liver and lung were examined for bacteriological and molecular confirmation.

Result: The mean (±SE) age of lambs that were affected was 11.00±0.49 days (n=404). Lambs of native Malpura breed (87.5%) and other two crossbred sheep were affected. Overall mortality of lambs was 23.76%. Gross pathological observations were pulmonary edema, ecchymotic lesions in lungs, congestion in kidney and liver and presence soil-mixed ingesta in abomasum. From the morbid materials including stomach and intestinal swabs, 45 *E. coli* isolates were identified and they were also confirmed on polymerase chain reaction (PCR). Consequently, virulence genes for shiga toxin (stx_2) and intimin (*eae*) were identified from the isolates. Although antibiotics were administered, only probiotics could control the new infection rate.

Key words: *Eschericia coli*, Lamb mortality, Neonatal, Probiotic, Septicaemia, Shiga toxin.

INTRODUCTION

In sheep husbandry, neonatal lamb (<4 weeks) mortality is a cause of grave concern as it can drastically diminish the farm returns. Enteric infections are quite commonly observed in week-old lambs. Enteric colibacillosis and septicaemic colibacillosis are the two most common forms of illness and *E. coli* accounted for 65% of septicaemic cases in lambs and major cause of diarrhoea in young calves (Sharma and Joshi, 2020). Septicaemic colibacillosis is highly fatal in young pre-ruminants and therapeutic options are limited even if they are exercised in time. In the semi-arid tropical geography of Rajasthan, India, an outbreak of septicaemic colibacillosis occurred in three sheep flocks. Perusal of literature revealed that there is dearth of epidemiological information on septicaemic colibacillosis. Hence, in this article, the salient epidemiological, pathological observations and response to management are reported herewith.

MATERIALS AND METHODS

Location and flock particulars

The flocks were located in the ICAR-Central Sheep and Wool Research Institute, Avikanagar, Rajasthan, India (Geocoordinates: 75°28′E and 26°17′N) and mean annual rainfall had been around 500 mm (Swarnkar and Singh, 2011). Flock A had only native Malpura breed of sheep and flock B had both Malpura and crossbred (Avikalin- 50% Malpura and 50% Rambouillet) sheep whereas flock C had only crossbred (Garole and Malpura crosses) sheep. All three flocks were maintained in semi-intensive system and standard feeding practices were followed along with grazing. Deworming, vaccination and dipping were carried out as per planned flock health programme.

Clinical examination and necropsy

During February 2019, sudden death of neonatal lambs was observed. Information pertaining to the onset of epidemic and preceding management activities were collected. As soon as possible, all ailing and dead lambs were subjected for clinical and post-mortem examination, respectively. Tissue samples like liver, lung, heart and kidney were collected and histopathological examination was carried out as per standard procedure (Culling, 1968). While performing the necropsy, swab samples from the liver, lung, heart and gastrointestinal tract were also collected and subjected for

[1]Division of Animal Health, ICAR-Central Sheep and Wool Research Institute, Avikanagar-304 501, Rajasthan, India.
[2]Division of Livestock and Fisheries Management, ICAR Research Complex for Eastern Region, Patna-800 014, Bihar, India.
[3]Dairy Cattle Breeding Division, National Dairy Research Institute, Karnal-132 001, Haryana, India.

Corresponding Author: S. Jegaveera-Pandian, Division of Animal Health, ICAR-Central Sheep and Wool Research Institute, Avikanagar-304 501, Rajasthan, India. Email: jeganicar@gmail.com

How to cite this article: Pandian, S.J. Kumar,, J., Sonawane, G.G. Gowane,, G.R., Swarnkar, C.P. and Sharma, S.R. (2023). Soil-borne Septicaemic Colibacillosis in Neonatal Lambs: Salient Observations. Indian Journal of Animal Research. 57(5): 662-665. doi: 10.18805/IJAR.B-4327.

Submitted: 05-10-2020 **Accepted:** 28-01-2021 **Online:** 02-03-2021

standard bacteriological examination and antibiogram by Kirby-Bauer disc diffusion method.

Virulence characterization of the *E. coli* by PCR

Genomic DNA was extracted from pure cultures of *E. coli* using Qiagen DNeasy® Blood and Tissue kit, according to manufacturer's instructions. The eluted genomic DNA was quantified using a Quawell UV-Vis Q5000 spectrophotometer (Quawell Technology Inc., San Jose, CA, USA). After checking the DNA purity on 0.8% agarose (Sigma, USA) gel electrophoresis, they were stored at-20°C till further use in the PCR assay. The conventionally identified *E. coli* strains were confirmed by 16S rRNA PCR, PCR product sequencing and NCBI blast analysis. The presence of some selected virulence genes like shiga toxin (stx2) and intimin (eae) were studied by PCR. The oligonucleotide primer sequences along with their amplicon sizes are listed in Table 1. All the primers were synthesized from Sigma Aldrich (Bengaluru, India). The condition adopted for their amplification like annealing temperature, primer concentration *etc*. were standardized and the optimized cycling and reaction conditions were used to screen samples in a thermo cycler (peqSTAR 96 Universal Gradient, peqlab, Germany) As negative control, all components of the reaction mixture without DNA template was included in the PCR. The PCR products were analyzed as described by Sambrook and Russell (2001). For sequencing of the amplicons, standard PCRs were run and PCR products (50 µl) were resolved on agarose gel. The desired sized bands were excised from agarose gel under UV light and were subsequently purified using MinElute® Gel Extraction Kit (Qiagen). The purified products were sequenced (Xcelris Genomics, Ahmedabad, India) and searched with the sequences available in the NCBI database.

RESULTS AND DISCUSSION

Epidemiological observations

Inclement conditions like cold, wet and windy weather are the major precipitating factors for colisepticaemia (Sonawane *et al*., 2012). During this outbreak, the mean maximum and minimum temperatures were 25.4°C and 12.6°C, respectively. In the first incidence (Flock A) that occurred in the beginning of February 2019, there were 163 lambs (males 77; females 86). Number of susceptible lambs in flocks B and C were 68 and 173, respectively. The mean age and birth weight of the dead lambs (n=404) were 11.00±0.49 days and 3.09±0.82 kg for males and 2.94±0.68 kg for females, respectively. Native Malpura lambs (87.5%) were predominantly affected. Lamb mortality of 44.79% (73/163), 20.59% (14/68) and 5.2% (09/173) was observed in flocks A, B and C, respectively. Many a times, *E coli*, especially shiga toxin-producing *E. coli* (STEC), organisms are shed by ruminants like sheep and cattle.

Clinical and necropsy observations

The septicaemic form of colibacillosis causes per acute death without recognizable premonitory signs (Radostits *et al*., 2006). In this outbreak, 46.87% lambs were found dead. However, some lambs exhibited tachypnea (>52/min), fever (>104.2°F) and remain isolated from flock. Evidently, respiratory distress had abdominal component. Bacterial lipopolysaccharides (LPS) can bring about cascade of hemodynamic changes in vasculature, particularly pulmonary vessels. This results in acute development of pulmonary edema, mucus nasal discharge and hypovolemia (Shabankare *et al*., 2015). Lesions like edema, congestion, haemorrhage, blood-tinged froth in trachea (5.21%) and tracheal mucosal hyperemia were characteristic of acute endotoxaemia (Kusiluka and Kambarage, 1996).

In all carcasses, rapid disappearance of *rigor mortis* was seen. Necropsy further revealed severe congestion and enlargement of liver (90.62%), highly congested renal parenchyma to the extent of haemorrhage (84.38%) and severe pulmonary edema and multifocal petichiae to ecchymotic lesions on the lung surface (89.58%). Very importantly, 57.29% of the lambs had soil-mixed ingesta giving a dirty appearance to the abomasal contents. Among the dead lambs, 25% had hyperemia and necrotic spots on abomasal mucosa. Despite many hypotheses, Slabach *et al*. (2015) reiterated that geophagy, also a type of pica, is a proximate mechanism to self-address the mineral nutritional demand. In the present study, lambs had dirt/soil in their abomasum which suggested that a possible underlying micro-mineral deficiency in the affected flocks. Autolytic changes were rapid in kidneys (Otter and Davies, 2015) as they are highly metabolically active. Histopathogical findings were engorged pulmonary vasculature, fibrinous exudation in alveoli, mural thickening of hepatic blood vessels and coagulation necrosis of renal tubules.

Bacteriological examination and antibiogram

A total of 54 bacterial colonies (from 61 sets gastrointestinal swabs, heart blood/swab, lung swabs and liver swabs) were

Table 1: Details of the Oligonucleotide primers used in current study.

Target gene	Primer	Sequence (5′-3′)	Amplicon size (bp)	References
16S rRNA	Forward 27F	AGAGTTTGATCMTGGCTCAG	~1466	Lane, 1991
	Reverse 1492R	CGGTTACCTTGTTACGACTT		
stx_2	Forward	CTGGCGTTAATGGAGTTCAGTGG	381	Sallam *et al*., 2013
	Reverse	CCTGTCGCCAGTTATCTGACA		
eae	Forward	GTGGCGAATACTGGCGAGACT	890	Fagan *et al*., 1999.
	Reverse	CCCCATTCTTTTTCACCGTCG		

isolated and 45 of them were identified as *Escherichia coli*, confirming it as an outbreak of septicaemic colibacillosis. Organisms were sensitive to amikacin (68%), cefixime (60%), ceftazidime (64%), imipenem (33%), chloramphenicol (100%), kanamycin (24%), co-trimoxazole (65%), amoxyclav (25%), gentamicin (91%) and nitrofurantoin (91%). A total of 16 (36%) isolates were resistant to ceftazidime (a third generation cephalosporin), which is suggestive of an extended spectrum β-lactamases (ESBL) producer strains. The conventionally identified *E. coli* strains were tested for the presence of some selected virulence genes like shiga toxin (stx_2) and intimin (*eae*) gene by PCR. The *E. coli* isolates were detected positive for harboring major virulence factor genes like shiga toxin (*stx2*; 381 bp) and intimin (*eae*; 890 bp) gene by PCR (Fig 1 and 2).

Epidemic management and response

In light of ABST, sulphamethoxazole + trimethoprim was given intramuscularly to all susceptible lambs and thereafter the mortality showed a declining trend. However, eventually, only after the use of probiotics, outbreak could be controlled. On the next week, similar outbreak occurred in flock C where only probiotic (*Lactobacillus* spp.) was administered for three days. In both the flocks B and C, lamb mortality could be reduced to 20.59% (14/68) and 5.2% (9/173), respectively.

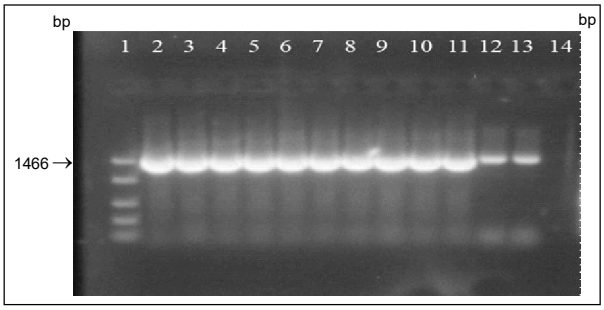

Fig 1: Agarose gel electrophoresis showing PCR amplified bands of the expected molecular size of 1466 bp for 16S rRNA gene of *E. coli* lane 1: FastRuler Low Range DNA ladder (#SM1103, Thermo Scientific), lane 2 to 13:- 1466 bp amplicon of 16S rRNA, lane 14: PCR reaction negative control.

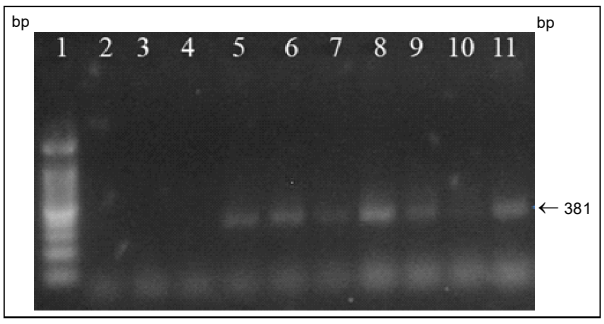

Fig 2: Agarose gel electrophoresis showing PCR amplified bands of the expected molecular size of 381 bp for stx_2 gene of *E. coli*. lane 1: NEX-GEN DNA Ladder (PG 100-500DI, Puregene), lane 5 to 11:- 381 bp amplicon of stx_2 gene, lane 2 and 3: stx_2 negative *E. coli,* lane 4:-PCR reaction negative control.

Especially in young pre-ruminants, probiotics exert their action by promoting optimal maturation of ruminal microbiota, increasing the digestive safety at weaning and reducing the pathogen colonization in gut (Chaucheyras-Durand and Durand, 2010; Dar *et al*., 2018).

CONCLUSION

Albeit conventional antibiotic therapy, this outbreak caused heavy mortality in lambs. Ingestion of faeces-contaminated soil by lambs could have resulted in this outbreak. However, it is concluded that climatic factors play vital role in precipitating soil-borne STEC infection. It can be inferred that the use of probiotics could be an effective preventive strategy against soil-borne septicaemic colibacillosis.

ACKNOWLEDGEMENT

The authors are grateful for the support rendered by Director, ICAR-CSWRI and ICAR-All India Network Project on Neonatal Mortality in Farm Animals for providing financial assistance for this study.

REFERENCES

Chaucheyras-Durand, F. and Durand, H. (2010). Probiotics in animal nutrition and health. Beneficial Microbes. 1(1): 3-9.

Culling, C.F.A. (1968). Handbook of Histopathological Techniques. Second edition, (Butterworth-Heinemann, London).

Fagan, P.K., Hornitzky, M.A., Bettelheim, K.A. and Djordjevic, S.P. (1999). Detection of Shiga-like toxin (stx_1 and stx_2), intimin (*eaeA*) and enterohemorrhagic *Escherichia coli* (EHEC) haemolysin (EHEC hlyA) genes in animal feces by multiplex PCR. Applied and Environmental Microbiology. 65(2): 868-872.

Kusiluka, L. and Kambarage, D. (1996). Disease of Small Ruminants: A Handbook; Common Diseases of Sheep and Goats in Sub-Saharan Africa, Vetaid Centre for Tropical Veterinary Medicine, Scotland, ISBN0952229951.

Lane, D.J. (1991). 16S/23S rRNA Sequencing. In: Nucleic Acid Techniques in Bacterial Systematics. [Stackenbrandt, E., Goodfellow, M. (editors)]. Chichester, United Kingdom: John Wiley and Sons, pp. 115-175.

Otter, A. and Davies, I. (2015). Disease features and diagnostic sampling of cattle and sheep postmortem examination. In Practice. 37: 293- 305.

Radostits, O., Gay, C., Hinchcliff, K. and Constable, P. (2006). A Textbook of the Diseases of the Cattle, Horses, Sheep, Pigs and Goats, Saunders Limited, p 2065.

Sallam, K.I., Mohammed, M.A., Ahdy, A.M. and Tamura, T. (2013). Prevalence, genetic characterization and virulence genes of sorbitol-fermenting *Escherichia coli* O157: H- and *E. coli* O157:H7 isolated from retail beef. International Journal of Food Microbiology. 165: 295-301.

Sambrook, J. and Russell, D.W. (2001). Molecular Cloning: A Laboratory Manual, 3rd ed. Cold Spring Harbor Laboratory Press, New York.

Shabankare, N.N.T., Zarei, M., Chalmeh, A. and Badiei, K. (2015). Acute pulmonary edema during endotoxaemia in sheep. 3rd International Congress of Large Animal Practitioners (ICLAP), Iran.

Sharma, S.K. and Joshi, M. (2020). Etio-epidemiological studies on diarrhoea in cattle and buffalo calves. Indian Journal of Animal Research. 54(11): 1391-1399.

Slabach, B.L., Corey, T.B., Aprille, J.R., Starks, P.T. and Dane. B. (2015). Geophagic behavior in the mountain goat (*Oreamnos americanus*): support for meeting metabolic demands. Canadian Journal of Zoology. 93(8): 599-604.

Sonawane, G.G., Singh, F., Tripathi, B.N., Dixit, S.K., Kumar, J. and Khan, A. (2012). Investigation of an outbreak in lambs associated with *Escherichia coli* O95 septicaemia. Veterinary Practitioner. 13(1): 72-75

Swarnkar, C.P. and Singh, D. (2011). Role of bioclimatographs in forecasting of strongyle infection in Rajasthan. Indian Journal of Animal Science. 81: 216-23.

Dar, A.H., singh, S.K., Mandal, B.C., Palod, J., Kumar, A., Singh, V., Sharma, R.K and Khadda, B.S. (2018). Effect of probiotic, prebiotic and synbiotics on fecam microbial count and cell-medaited immunity in crssbred calves. Indian Journal of Animal Research. 52(10): 1452-1456.