RESEARCH ARTICLE Indian Journal of Animal Research, Volume 57 Issue 6: 730-735 (June 2023)

Histomorphological and Cytochemical Characters of Endocrine Cells of the Gastrointestinal Mucosa of Duck (*Anas platyrhynchos*)

R. Patra[1], U.K. Mishra[1], S. Palai[2], P.R. Sahoo[3], S. Mohapatra[4]

10.18805/IJAR.B-4336

ABSTRACT

Background: It is known that balance diet is the key success for better production in poultry. The digestive physiology is regulated by the neurocrine and endocrine secretions. Growth, secretion, motility, cell signalling, vasoregulation, cell proliferation and differentiation of the epithelial cells of the alimentary canal are reported to be controlled by the peptides or amines released from the gut endocrine cells and enteric neurons. References particularly on systematic study of gastrointestinal endocrine cells in duck as regards to histomorphology and cytochemistry are gravely scanty. Hence the present investigation envisages authenticating the histomorphological characters and cytochemical behaviour of the gastrointestinal endocrine cells in duck.

Methods: For this study the abdomen of six Khaki campbell ducks from either sex was cut open following euthanasia. Tissue pieces from different segments of gut were collected and processed routinely to get 7-8 µ thick serial paraffin sections. The tissue sections were stained for evaluation of histomorphological and histochemical characters of the entero-endocrine cells.

Result: A panel of seven cytochemical stains identified nine endocrine cell types in the digestive mucosa of Khaki Campbell duck *i.e.* basally granulated oval cell, densely granulated spindle shaped cell, densely granulated oval cell, diffusely granulated oval cell, pyramidal cell, densely granulated elongated cell, densely granulated pyriform cell, peripherally granulated spherical cell and non-argentaffin chromaffin oval cell. The cells occurred in single or in small clusters in the basal or middle or neck part of glandular epithelium or in the surface epithelium. All the endocrine cells were 'close type'. Cytochemically they were four types *i.e.* argentaffin, argyrophil, chromaffin and APUD (Amine precursor uptake and decarboxylation) cells.

Key words: Argentaffin cell, Duck, Endocrine cell, Gut.

INTRODUCTION

The argentaffin cells or gastro-entero-chromaffin cells are now authenticated as true endocrine cells (Fujita and Kobayashi, 1977). These cells are located in the mucosa (Zhang and Wang, 2018) of alimentary tract. In response to luminal or blood born stimuli they secret several protein hormones and peptides in different segments of the digestive tract to regulate motility, secretions, growth of glandular epithelium, cell signaling, proliferation and differentiation of the epithelial cells of the alimentary canal. These hormones are reported to exert paracrine, neurocrine as well as endocrine controls over the gut segments (Argenzio, 2004). Solcia *et al*. (1975) designated these cells as the paraneurons. Cytochemically these cells were reported to be argentaffin positive (Fujita and Kobayashi, 1977) and argyrophilic in nature (Singh, 1966). Another category among them is the cells belonging to the amine precursor uptake and decarboxylation (APUD) series (Pearse, 1968). In addition to the morphological variations, these cells also reveal variable tinctorial affinity to different histochemical staining techniques (Barka and Anderson, 1963). Since reports on this aspect of endocrine cells in the digestive mucosa of Khaki Campbell (KC) duck is gravely scanty in the literature, the present investigation was carried out to establish a light microscopic classification of endocrine cells depending on their histomorphological character and cytochemical behavior.

[1]Department of Anatomy and Histology, College of Veterinary Science and Animal Husbandry, Odisha University of Agriculture and Technology, Bhubaneswar-751 003, Odisha, India.
[2]Department of Pharmacology and Toxicology, College of Veterinary Science and Animal Husbandry, Odisha University of Agriculture and Technology, Bhubaneswar-751 003, Odisha, India.
[3]Department of Veterinary Biochemistry, College of Veterinary Science and Animal Husbandry, Odisha University of Agriculture and Technology, Bhubaneswar-751 003, Odisha, India.
[4]Department of Veterinary Physiology, College of Veterinary Science and Animal Husbandry, Odisha University of Agriculture and Technology, Bhubaneswar-751 003, Odisha, India.

Corresponding Author: R. Patra, Department of Anatomy and Histology, College of Veterinary Science and Animal Husbandry, Odisha University of Agriculture and Technology, Bhubaneswar-751 003, Odisha, India. Email: ritun37v04@gmail.com

How to cite this article: Patra, R., Mishra, U.K., Palai, S., Sahoo, P.R. and Mohapatra, S. (2023). Histomorphological and Cytochemical Characters of Endocrine Cells of the Gastrointestinal Mucosa of Duck (*Anas platyrhynchos*). Indian Journal of Animal Research. 57(6): 730-735. doi: 10.18805/IJAR.B-4336.

Submitted: 17-10-2020 **Accepted:** 05-04-2021 **Online:** 22-04-2021

MATERIALS AND METHODS

Adult Khaki Campbell ducks aged seven months, six each, from male and female sex, were procured from Central Avian

Research Institute, Regional Centre, Bhubaneswar, India. The research work was carried out in the College of Veterinary Science and Animal Husbandry, OUAT, Bhubaneswar in the year 2018. As per the guidelines of Institutional Animal Ethical Committee of the College, after euthanasia by decapitation, the abdomen of the duck was cut open, eviscerated and representative tissue pieces from esophagus, proventriculus, gizzard, pylorus, duodenum, jejunum, ileum, caecum and colo-rectum were fixed in (a) 10% buffered neutral formalin and (b) 10% potassium iodate followed by 10% buffered neutral formalin for routine paraffin technique. The following histochemical staining methods were applied (as per the procedure of Bancroft and Stevens, 1996) to serial paraffin sections to demonstrate the gut endocrine cells: (i) Singh's modified Masson-Hamperl silver reaction for argentaffin cells (ii) Grimelius silver for argyrophil cells (iii) Lead haematoxylin stain for APUD cells (iv) Ferric ferricyanide reduction reaction for neuroendocrine cells (v) Vulpian's reaction for chromaffin/catecholamine cells (vi) Ninhydrin reaction for chromaffin cells and (vii) Potassium iodate technique for adrenaline storing cells. The histomorphological characters and tinctorial affinity of the gut endocrine cells to different cytochemical salts were recorded using the trinocular research microscope with photographic attachment (Leica, DM 2500, Digital Camera system DFC 290, Germany).

RESULTS AND DISCUSSION

In each region of gastrointestinal tract of KC duck, a selective group of endocrine cells was stained by any one of the seven histochemical staining techniques employed in the present study. The Ferric ferricyanide reduction reaction was proved to be the stain of choice for histochemical identification of the gut endocrine cells as it clearly revealed the distribution pattern of secretion granules within the cells and thereby the cell morphology. Ferric ferricyanide was seen to react with a large population of the endocrine cells whereas the Argyrophil reaction, Argentaffin reaction, Lead hematoxylin reaction, Potassium iodate, Ninhydrin and Vulpian's reaction were next to the Ferric ferricyanide reaction in descending order. Thus, Vulpian's reaction revealed the smallest population of the endocrine cells. The silver impregnation techniques like Argentaffin and Argyrophil reactions discerned distinct cell outline and morphology as compare to that revealed by the Ferric ferricyanide reaction. Application of silver salt appears to be the only technique to demonstrate endocrine cell processes as no other stain could reveal the endocrine cell processes. However as per Mishra and Das (1992), Argentaffin reaction is the stain of choice to localize a maximum population of endocrine cells in the gut mucosa of ruminants. Pearse (1968) reported these cells to be capable of handling amine precursors and decarboxylate them into biogenic monoamines and hence, designated them to be the members of APUD series giving a positive reaction to Lead hematoxylin (Bancroft and Stevens, 1996). According to Fujita and Kobayashi, (1977) the secretion granules of these endocrine cells contain at least four important substances *i.e.* a peptide hormone and/ or its precursor, biogenic monoamines, an ATP and other adenine nucleotides and a large molecule of compound protein; where the complex protein is the main chromogen and is responsible for the histochemical staining affinity of the cells. In the present study since most cell types gave a positive reaction to more than one staining technique, it is affable to conclude that their granules might contain a common chromogen responsible for reaction with more than one staining techniques and that a particular histochemical property is shared by more than one class of gut endocrine cells. The similarity in the chemical nature of amine and peptide moieties in secretion granules of the cell types as advocated by Fujita and Kobayashi, (1977) probably contributes for their affinity for a particular staining sequence. Earlier in 1961, Lillie considered them to be the phenolic granules. In the present study, depending on the histomorphological characters of the endocrine cells and distribution pattern of the secretion granules within the cells, the endocrine cells were categorized into 9 different types: basally granulated oval cells (cell-type I); densely granulated spindle shaped cells (cell-type II); densely granulated oval cells (cell-type III); diffusely granulated oval cells (cell-type IV); pyramidal cells (cell-type V); densely granulated elongated cells (cell-type VI); densely granulated pyriform cells (cell-type VII) and peripherally granulated spherical cells (cell-type VIII) and non-argentaffin chromaffin oval cells (cell-type IX) (Fig 1). Each cell type possessed certain differential characters from the rest of the types. Each of these endocrine cell types in the digestive mucosa of KC duck reacted to more than one staining technique and was found in particular segments of the digestive tract. Such kind of segmental distribution of endocrine cells has also been noted by Yamada, (1981) *i.e.* proventriculus of duck is devoid of the argentaffin cells but revealed argyrophilic cells. This proventricular endocrine cell group was also identified using rest of the stains employed in this study. This suggests that endocrine cells belonging to different categories occupied specific segments of the gastrointestinal tract of the KC duck. The cells were present in isolated manner or in small groups of 1-2 cells in the basal, middle and apical parts of gastrointestinal glands; surface epithelium; villus epithelium and also, occasionally in the lamina propria (Fig 2). In our study the densely granulated oval cells (type-III) revealed the apical cell process which terminated in the subluminal zone of the glandular epithelium. This is a clear cut structural evidence to support the view that these cells exert paracrine control over adjacent exocrine cells (Fujita and Kobayashi, 1977).

The cell types I, III and IV were oval in outline. Their nuclei were oval or circular and vesicular. In cell type I the position of the nucleus was towards the apical part of the cell with very little cytoplasm (Fig 3) and secretion granules at their basal region. The cell type III had central nucleus with uniform, dense and compact granulation pattern

(Fig 4). Some of these cells revealed beaded cytoplasmic processes as apical cell projections. These processes insinuated between adjacent glandular cells and terminated in a region below the luminal margin of the epithelium (Fig 4). In cell type IV, the nucleus was positioned either centrally or eccentrically. These cells had uniform and diffuse granulation. The cells of type II were spindle shaped with elliptical, euchromatic and central nucleus. Some of these cells revealed a polarized distribution (Fig 5) and some had compact distribution (Fig 6) of secretion granules in their cytoplasm. The cell type V was distinctly pyramidal in shape with their broad basal border remaining in contact with the basal lamina and the bluntly rounded apex was devoid of luminal contact. The secretion granules were scattered at the basal part of some of the cells (Fig 6 and 7) and in others the granules had uniform and compact distribution. The nucleus of this cell type was oval, vesicular and centrally positioned. Cells of type VI were elongated in shape with uniform and compact granulation pattern. Their nucleus was elliptical, euchromatic and centrally placed. The cells of type VII were almond shaped with oval, vesicular and eccentric nucleus (Fig 3). Some cells revealed uniform and some cells had either apical or basal distribution of secretion granules. The cells of type VIII were spherical in outline with spherical, vesicular and central nucleus (Fig 7) and peripherally distributed secretion granules. Cells of type IX were characterized by their small size and oval shape. The granules were sparingly visible in the cytoplasm. The nucleus was circular, centrally placed and was faintly stained. The cell contour was indistinct.

All the nine cell types were 'closed type' means they did not appear to maintain luminal contact either with the

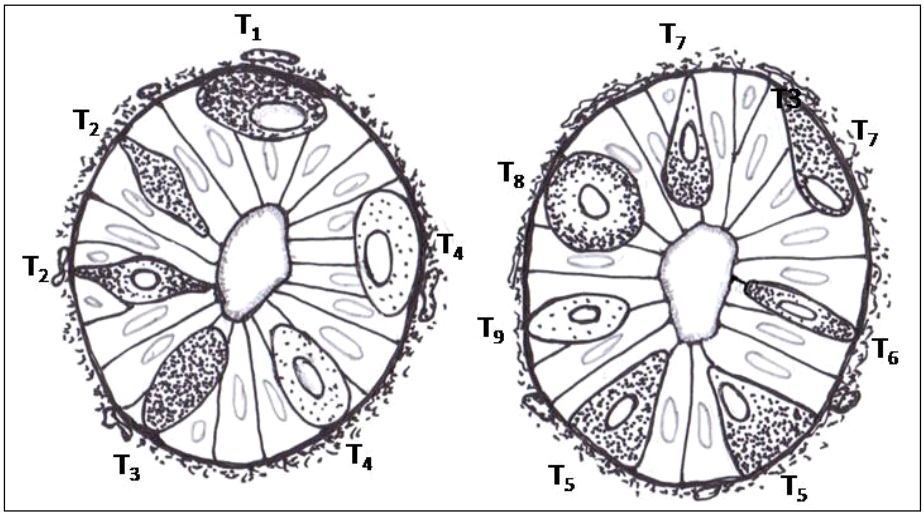

Fig 1: Schematic representation of histomorphological characters of nine kinds of endocrine cells in the digestive mucosa of Khaki Campbell (KC) duck *i.e.* basally granulated oval cell (T_1), densely granulated spindle shaped cell (T_2), densely granulated oval cell (T_3), diffusely granulated oval cell (T_4), pyramidal cell (T_5), densely granulated elongated cell (T_6), densely granulated pyriform cell (T_7), peripherally granulated spherical cell (T_8) and Non-argentaffin chromaffin oval cell (T_9).

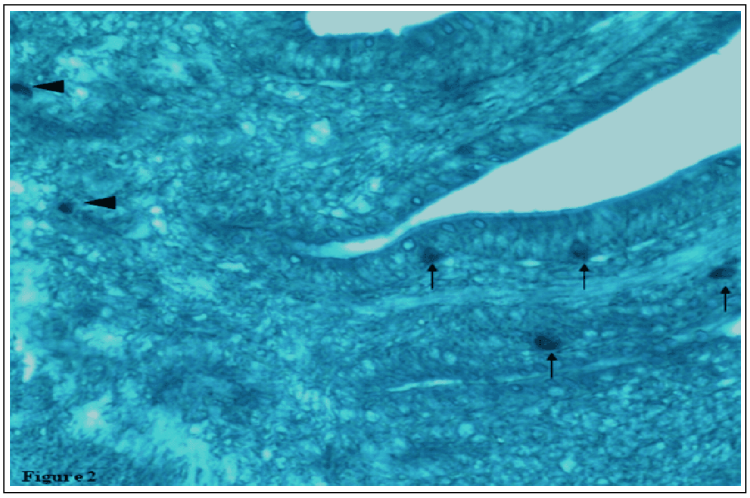

Fig 2: Histological section of jejunum of KC duck showing distribution of endocrine cells in the basal part of villar epithelium (arrow) and in the lamina propria (arrow head). (Ferric ferricyanide reduction reaction X 100).

gland or with that of the gut. The cytoplasm of these endocrine cells stained light blue to prussian blue colour with Ferric ferricyanide reduction reaction; in shades of light brown, light grey, dark brown, brownish black and dark black colour with Argentaffin and Grimelius argyrophil reactions; light blue, greyish blue and dark blue with Lead hematoxylin stain; light green to a deep greenish hue with Vulpian's reaction; light brown to dark brown with Potassium iodate reaction; and a light orange, red and orange-red colour with Ninhydrin reaction. The cell types II, IV and VIII revealed negative reaction to lead haematoxylin. Cell types III, IV and VI showed no tinctorial affinity towardsVulpian's reaction. Cell types VII did not give any reaction with Ninhydrin technique. Cell type IX gave negative reaction to silver stains and ferricferricyanide reduction reaction. These neuroendocrine cells were evident mainly in the basal and body part of the crypts of intestine, occasionally found in the neck part of the crypt and villar epithelium. All the cell types were distributed over pylorus, duodenum, jejunum, ileum, caecum and colo-rectum and in addition to these locations the cell types III, V, VI and VII were found in proventriculus.

Gut endocrine cells in chicken are reported to be pleomorphic (Yan *et al*., 2012). Besides histomorphology several other criteria such as distribution, hormone secretion and manifestation to chemical stimuli like fasting, luminal acidification, denervation, cytochemical reactions, luminal contact, ultrastructure of secretion granules *etc*. can be chosen to classify the endocrine cells of the digestive mucosa of the mammals and birds (Fujita and Kobayashi, 1977; Solcia *et al*., 1975; Usellini *et al*., 1983). Histomorphological features of the gut endocrine cells and their hormone content have been the most ideal basis for classifying these cells (Polak and Bloom, 1982). Depending

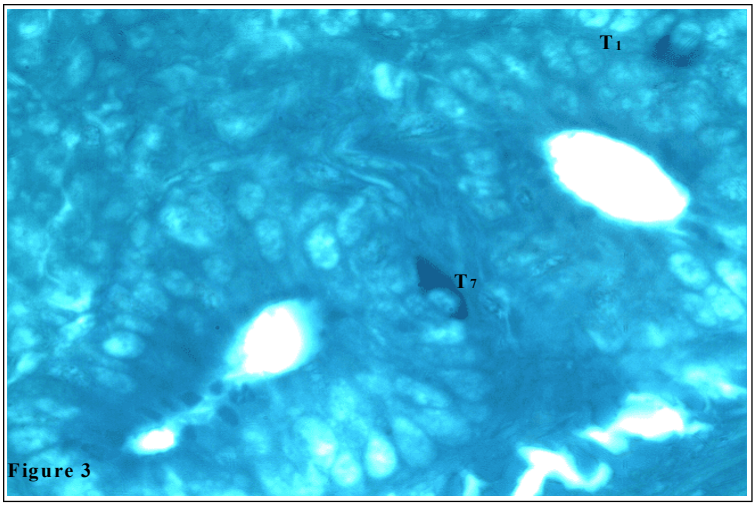

Fig 3: Histological section of duodenum of KC duck showing distribution of secretion granules in the cytoplasm of basally granulated oval cell (T_1) and densely granulated pyriform cell (T_7). (Ferric ferricyanide reduction reaction X 400).



Fig 4: Histological section of proventriculus of KC duck showing distribution of the densely granulated oval cells (T_3) in the glandular epithelium. Note the termination of the apical cell process in the subluminal zone of the glandular epithelium (6a) (Grimelius silver X 100).

on the histomorphological character and cytochemical behavior, the present study established a broad classification of gut endocrine cells into two categories *i.e.*, Argentaffin and non-argentaffin-chromaffin cells. This kind of classification would help to elucidate the role of particular cell-type in physiology of digestion of the duck and would also elucidate the possible involvement of specific cell-type(s) in a particular case of gastro-intestinal disorder. All the nine categories of endocrine cells did not have luminal contact though each of them had contact with the basal lamina and were thus sorted into 'closed cell types. About three histomorphologically different cell types were seen in the enteric mucosa of pigeon (Xia *et al*., 1999) and four types in chicken, kite and common finch (Yamada, 1981; Yamada *et al*., 1985), five types in proventriculus of duck (Yamada, 1981), six types in the digestive mucosa of 21 day old chick (Usellini *et al*., 1983), seven types in the gut mucosa of OUAT synthetic broiler chicken (Mishra, 2006) and nine types in gut mucosa of Vencob broiler chicken (Mandal, 2000). All these nine kinds of histomorphologically distinct endocrine cells of the present study were cytochemically categorized into four different classes *i.e*. Argentaffin, Argyrophil, Chromaffin and APUD which is in agreement with reports of Barka and Anderson (1963); Bancroft and Stevens (1996) in higher vertebrates and Mishra and Das (1992) in broiler chicken. Das (1984) revealed only two cell types (argentaffin and chromaffin) in the gut mucosa of buffalo. Such variations may be attributed to species and/or regional characters of the tract as part of digestive physiology.



Fig 5: Localization of the spindle shaped endocrine cell (T_2) and densely granulated elongated cell (T_6) in the caecum of KC duck. (Argentaffin reaction X 400).

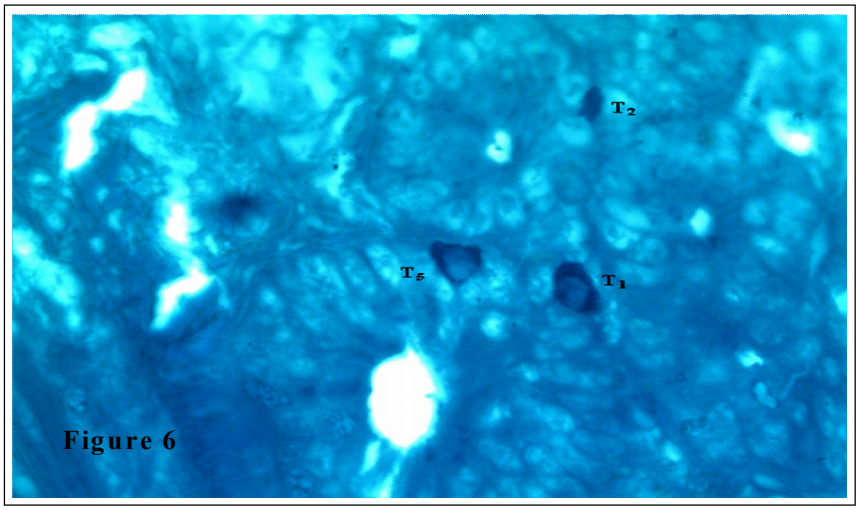

Fig 6: Histological section of duodenum of KC duck showing localization of basally granulated oval cell (T_1), densely granulated spindle shaped cell (T_2) and pyramidal cell (T_5) in the basal part of crypts. Note all the cells are closed type. (Ferric ferricyanide reduction reaction X 400).

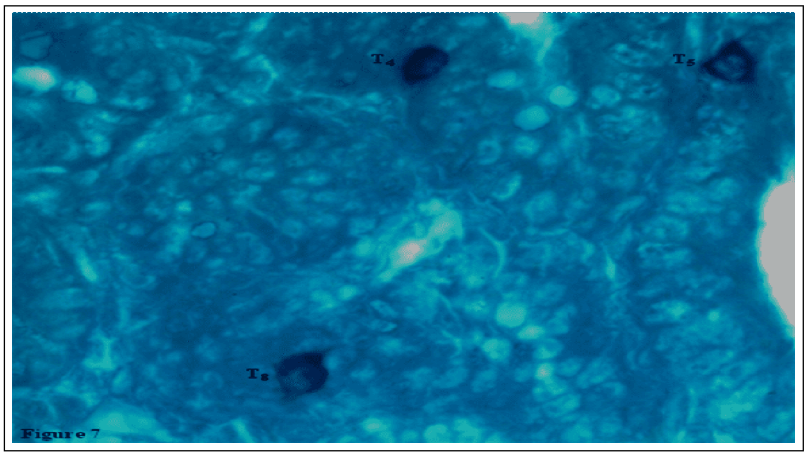

Fig 7: Histological section of jejunum of KC duck showing the morphology of the diffusely granulated oval cell (T_4), pyramidal cell (T_5) and peripherally granulated spherical cell (T_8). (Ferric ferricyanide reduction reaction X 400).

CONCLUSION

The present study authenticated the histomorphological character and cytochemical behaviour of the neuroendocrine cells in different segments of the gastrointestinal tract of Khaki Campbell duck. It can be concluded that Ferric ferricyanide reduction is the stain of choice for identification of the gut endocrine cells. There is a great variation in histomorphology of different gut endocrine cell types. All most all endocrine cells are of 'closed type' in duck digestive tract. The endocrine cells of the gastrointestinal mucosa have preferential location, such as glandular mucosa in proventriculus and pylorus and crypts as well as villi of the intestine. The customary light microscopic classification of gut endocrine cells of KC duck in the present study has provided data to ascertain involvement of specific type of endocrine cells in a particular case of digestive ailment as well as in the physiology of digestion of KC duck.

REFERENCES

Argenzio, R.A. (2004). General Functions of Gastrointestinal Tract and Yours Control. Dukes' Physiology of Domestic Animals, 12th Edn. Panima Publishing Corporation, New Delhi. pp. 381-390.

Bancroft, J.D. and Stevens, A. (1996). Theory and Practice of Histological Techniques. 4th Edn. Churchill Livingstone, New York.

Barka, T. and Anderson, P.J. (1963). Histochemistry: Theory, Practice and Bibliography. Harper and Row Publishers Inc., London. pp. 182-186: 192-202.

Das, L.N. (1984). A note on the occurrence of enterochromaffin cells in the gastrointestinal tract of Indian buffalo. The Utkal Veterinarian. 14(4): 1-5.

Fujita, T. and Kobayashi, S. (1977). Structure and function of gut endocrine cells. International Review of Cytology. Suppl 6: 187-233.

Lillie, R.D. (1961). Investigations on the structure of the enterochromaffin substance. Journal of Histochemistry and Cytochemistry. 9(2): 184-189.

Mandal, A.K. (2000). Studies on diffuse neuroendocrine system in the gastroentero-pancreaticobiliary mucosae of post-hatch broiler chicken. Ph. D. thesis submitted to Odisha University of Agriculture and Technology.

Mishra, U.K. (2006). Cytochemical characterization of the endocrine cells of gastrointestinal mucosa of broiler chicken. Orissa Veterinary Journal. 21(4): 25-30.

Mishra, U.K. and Das, L.N. (1992). Histomorphological study on the endocrine cells of grastrointestinal mucosa of domestic ruminants. Indian Journal of Animal Sciences. 62(9): 802-806.

Pearse, A.G. (1968). Histochemistry, Theoretical and Applied. 3rd Edn. Vol.I, Little Brown and Co., Boston. pp. 294-397

Polak, J.M. and Bloom, S.R. (1982). Localization of regulatory peptides in the gut. British Medical Bulletin. 38(3): 303-308.

Singh, I. (1966). Argyrophile and argentaffin reactions in individual granules of enterochromaffin cells of the guinea pig. Zeitschrift Für Zellforschung Und Mikroskopische Anatomie. 73(4): 549-552.

Solcia, E., Capella, C., Vassallo, G. and Buffa, R. (1975). Endocrine cells of the gastric mucosa. International Review of Cytology. 42: 223-286.

Usellini, L., Tenti, P., Fiocca, R., Capella, C., Buffa, R., Terenghi, C., Polak, J. M. and Solcia, E. (1983). The endocrine cells of the chicken proventriculus. Basic and Applied Histochemistry. 27(2): 87-102.

Xia, L., Zhe, T. and Shulan, L. (1999). Distribution and morphological observation of argyrophil cells in intestines of *Columba livia domestica*. Journal of Natural Science. 12(6): 321-327.

Yamada, J. (1981). Light microscopic and electron microscopic studies on the endocrine cells in the duck proventriculus. Japanese Journal of Veterinary Science. 37: 863-870.

Yamada, J., Kitamura, N. and Yamashita, T. (1985). The relative frequency and topographical distribution of somatostatin-, GRP-, APP-, glucagon-, 5-HT-and neurotensin-immunoreactive cells in the proventriculus of seven species of birds. Archivum Histologicum Japonicum. 48(3): 305-314.

Yan, P., Min, H.E. and Qiong, L. (2012). Distribution and morphology of argentaffin cells in the digestive tract of 300-day-old Chinese yellow quail. Chinese Agricultural Science Bulletin. 28: 40-45.

Zhang, H. and Wang, J. (2018). Morphology of the proventriculus of the African ostrich. Indian Journal of Animal Research. 52: 37-40.