RESEARCH ARTICLE Indian Journal of Animal Research, Volume 57 Issue 7: 857-859 (July 2023)

Histology of Hair Follicles in Different Breeds of Rabbits

K.M. Lucy[1], N. Ashok[1], S. Maya[1], V.R. Indu[1], A.R. Sreeranjini[1], K. Karthiayini[1]

10.18805/IJAR.B-4343

ABSTRACT

Background: Rabbit farming provides a valuable additional source of income in the rural areas of the county. Skin is the largest organ in the body and the hair coat forms the first line of defense against the invading pathogenic organisms as well as the physical environment. So far, no detailed comparative study has been conducted on the skin of various breeds of rabbits. Hence, the present work was undertaken to compare the structure and distribution of hair follicles in different breeds of rabbits commonly reared in Kerala.

Methods: The study was conducted on the skin of six breeds of rabbits namely, Soviet Chinchilla, New Zealand White, Grey Giant, White Giant, Angora and crossbred. In total, 36 animals were used for the study. From each animal, skin samples were collected from eight representative areas of the body *viz*., dorsal nasal region, pinna, dorsal neck, dorsal thorax, dorsal abdomen, ventral abdomen, perineal and carpal regions. Standard procedures were adopted for histological studies.

Result: All the six breeds of rabbits showed compound hair follicles with primary and secondary follicles with associated sebaceous glands. Arrangement of hair follicles showed differences among the breeds. There was no difference in the histology of hair/hair follicle among the breeds. This work will form a basis for further breed specific research in the area of fur and leather industry and skin penetration studies.

Key words: Hair follicles, Histology, Rabbit breeds, Skin.

INTRODUCTION

Rabbit farming provides a valuable additional source of income in the rural areas of the county. The hair coat forms the first line of defense against the invading pathogenic organisms as well as the physical environment. The skin and fur of rabbits have some unique properties. The fur is very dense and fine and can tear easily. High quality rabbit skins are used in fur garments and trimmings in medical and cosmetic research. Skin of rabbit is also used as a barrier for skin penetration studies, for both lipophilic and hydrophilic permeants in transdermal permeation experiments. So far, no detailed comparative study has been conducted on the skin of various breeds of rabbits. Hence, the present work was undertaken to study the histology of hair follicles in different breeds of rabbits.

MATERIALS AND METHODS

Histological studies on the hair follicles were conducted on the skin of six breeds of rabbits namely, Soviet Chinchilla, New Zealand White, Grey Giant, White Giant, Angora and crossbred rabbits. In total, 36 animals were used for the study. The study was conducted at College of Veterinary and Animal Sciences, Mannuthy, Thrissur, Kerala during 2012-13. Skin samples were collected from six adult healthy animals from each breed. Samples were collected from eight representative areas of the body *viz*., dorsal nasal region, pinna, dorsal neck, dorsal thorax, dorsal abdomen, ventral abdomen, perineal and carpal regions (Fig 1). Standard procedures were adopted for histological studies. The sections were stained using Haematoxylin and Eosin (H&E), van Gieson's method for collagen, Gomori's trichrome method for muscle and collagen fibres (Luna, 1968) and Verhoeff's elastic stain (Singh and Sulochana, 1996).

[1]Department of Veterinary Anatomy and Histology, College of Veterinary and Animal Sciences, Mannuthy-680 651, Thrissur, Kerala, India.

Corresponding Author: K.M. Lucy, Department of Veterinary Anatomy and Histology, College of Veterinary and Animal Sciences, Mannuthy-680 651, Thrissur, Kerala, India. Email: lucy@kvasu.ac.in

How to cite this article: Lucy, K.M., Ashok, N., Maya, S., Indu, V.R., Sreeranjini, A.R. and Karthiayini, K. (2023). Histology of Hair Follicles in Different Breeds of Rabbits. Indian Journal of Animal Research. 57(7): 857-859. doi: 10.18805/IJAR.B-4343.

Submitted: 26-10-2020 **Accepted:** 23-03-2021 **Online:** 06-04-2021

RESULTS AND DISCUSSION

All the six breeds of rabbits showed compound hair follicles. Two types of hair follicles were distinguished in all the breeds under study. The primary follicles had a larger diameter and rooted deep in the dermis (Fig 2). The secondary follicles were smaller in diameter and their roots were superficially located. Even though there were variations in the arrangement of hair follicles among different breeds, there was no difference in the histology of hair/hair follicle among the breeds. Hair was composed of a shaft that projected beyond the surface of the skin and a root, which was inserted obliquely into the dermis. The hair roots were situated in tubular pockets in the epidermis, the hair follicles being extended into the dermis (Fig 3). The hair root was enlarged at its ventral end to form the hair bulb that was indented by the hair papilla.

Hair shaft was composed of a cuticle, cortex and medulla (Fig 4). Cuticle was formed by a single layer of flat, keratinized, anucleated squamous cells (Fig 5). Abit *et al.* (2009)

compared the scanning electron microscopic features of hair cuticular cells in sheep, goat, water buffalo and cattle. Hair of sheep was thin with tight, regular, jagged cuticular cells while free ends of cuticular hairs in water buffalo had more numerous cytoplasmic extensions. Cortex of the hair was made up of several layers of dense, compact, keratinized, spindle-shaped cells with their long axes parallel to the hair shaft–Medulla of the hair shaft was composed of loosely filled cuboidal or polygonal cells The primary and secondary follicles were usually associated with sebaceous glands as reported by Oznurlu *et al.* (2009) in rabbits. Arrangement and histology of hair follicles of Madras Red sheep were studied by Ahmad *et al.* (2012) who observed that the follicles were arranged in rows either as single or in groups. No sweat glands could be identified in all the breeds under study in the eight body regions selected.

Hair follicle was composed of four parts namely, the hair papilla, hair matrix, inner root sheath and outer root sheath (Fig 6). Hair papilla was the part of dermis encapsulated by the hair matrix cells that formed a structure called the hair bulb. The inner root sheath was composed of inner cuticle, middle granular epithelial layer, the Huxley's layer and outer pale epithelial layer, the Henle's layer. Cuticle of inner root sheath was similar to the cuticle of the hair. Cuticular layers of both the hair and the hair follicle were interlocked. Huxley's layer lay between the cuticle and the Henle's layer. This layer was composed of two to three rows of granular cells. Henle's layer was the outer most and was composed of a single layer of columnar cells with darkly stained nuclei. Similar observations were made in pigs by Sumena *et al.* (2010).

The external root sheath was composed of several layers of cells and was continuous with the upper portion of the hair follicle (Fig 6). It consisted of a single layer of stratum basalis and several layers of stratum spinosum cells. The entire hair follicle was enclosed by connective tissue sheath, which was composed of internal and external layers of



Fig 3: Section of skin of dorsal thoracic region, White Giant. H&E x 400.
1. Epithelial invagination of primary follicle; 2. Secondary follicle; 3. Hair bulb; 4. Dermis.



Fig 1: Regions of body from where skin samples collected - White Giant.
1. Dorsal nasal; 2. Pinna; 3. Dorsal neck; 4. Dorsal thorax; 5. Dorsal abdomen; 6. Ventral abdomen; 7. Carpal; 8. Perineum.

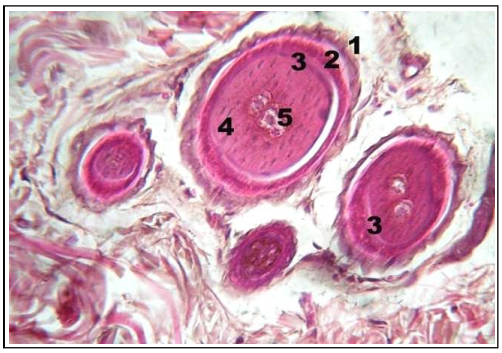

Fig 4: C.S. of hair follicles of dorsal nasal region, Crossbred. H&E. x 400.
1. Outer root sheath; 2. Inner root sheath; 3. Cuticle; 4. Cortex; 5. Medulla.

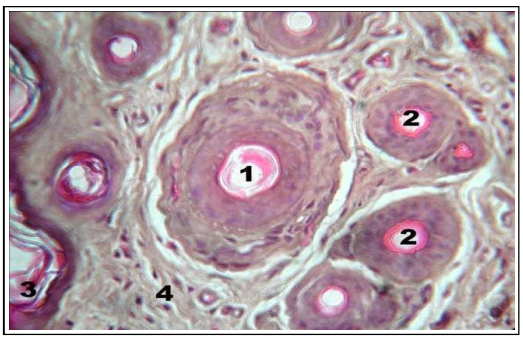

Fig 2: Section of skin of dorsal neck region, White Giant. H&E x 400.
1. Primary follicle; 2. Secondary follicle; 3. Epidermis; 4. Dermis.

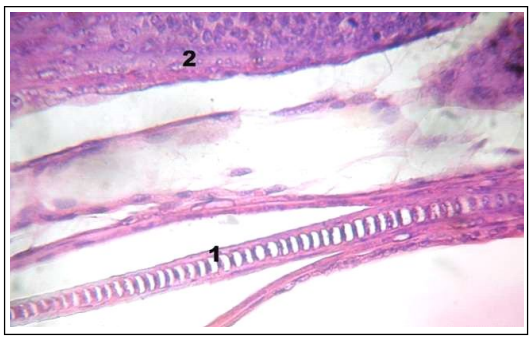

Fig 5: L.S. of hair in the pinna, Soviet Chinchilla. H&E x 400.
1. Cuticular cells; 2. Inner root.

collagen and elastic fibres (Fig 7). The inner layer was made up of circularly arranged fibres which surrounded individual clusters whereas the outer layer of longitudinal fibres surrounded the compound hair follicle as whole. Wagner and Bailey (2006) reported that its base, the hair was shaped like a bell, the hair bulb, surrounding a small dermal papilla. The cells next to the papilla represented the germinative zone of the hair and its surrounding tissue. This tissue consisted of five different concentric layers. The first three innermost layers were united to form the inner root sheath. Directly in contact with the cuticle of hair was the cuticle of inner root sheath, followed by next two layers - the Huxley's layer and the Henle's layer. Outer most layer was the outer root sheath that surrounded the other layers, hair in the lower part of hair follicle and the hair channel.

Different stages of hair follicles were noticed in the dermis. Anagen bore mitotically active cells in the hair bulb; while catagen showed regressive type of cells. The hair papilla was reduced to a ball of cells located below the capsule of the hair matrix cells of the bulb. Hair follicle at this stage was the telogen. Similar observations were made in domestic animals by Monteiro-Riviere *et al.* (1998).

Arrangement of hair follicles showed some differences among the breeds. In Angora and White Giant, the compound hair follicle consisted of one primary hair follicle and six to twelve secondary follicles the number being less in the latter (Fig 2). In New Zealand White, Soviet Chinchilla, Grey Giant and crossbred, each compound hair follicle was formed of a primary hair follicle in the centre with small clusters of secondary follicles surrounding the primary follicle (Fig 7).

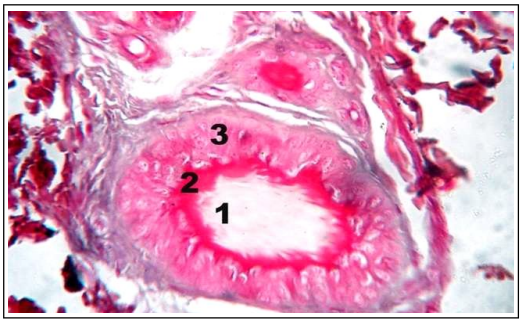

Fig 6: Section of the hair follicle in the carpal region, Crossbred. Gomori's trichrome method x 400.
1. Hair matrix; 2. Inner root sheath; 3. Outer root sheath.

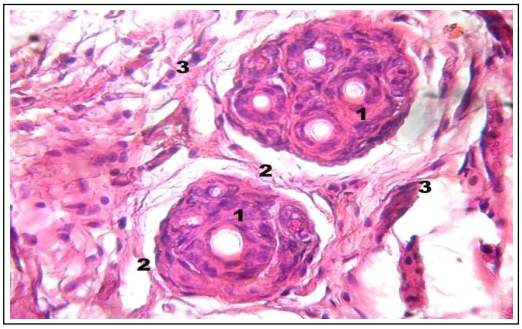

Fig 7: C.S. of hair follicles of dorsal neck region, Soviet Chinchilla. H&E x 400.
1. Primary and secondary hair follicles; 2. Internal layer of connective tissue sheath; 3. External layer of connective tissue sheath.

CONCLUSION

All the six breeds showed compound hair follicles with primary and secondary follicles. There was no difference in the histology of hair/hair follicle among the breeds. Hair shaft was composed of a cuticle, cortex and medulla. Hair follicle was composed of four parts namely, the hair papilla, hair matrix, inner root sheath and outer root sheath. The primary and secondary follicles were associated with sebaceous glands. No sweat glands could be identified in all the breeds under study in the eight body regions selected. Arrangement of hair follicles showed some differences among the breeds. In Angora and White Giant, the compound hair follicle consisted of one primary follicle and six to twelve secondary follicles, the number of secondary follicles being less in the latter. In others, each compound hair follicle was formed of a primary hair follicle in the centre with small clusters of secondary follicles surrounding the primary follicle.

REFERENCES

Abit, A., Firat, U.B., Bozkurt, H.H., Esener, O.B.B. and Suzan, D. (2009). Scanning electron microscopic properties of hair cuticular cells in ruminants. Indian Veterinary Journal. 86: 397-399.

Ahmad, M.S., Sathyamoorthy, O.R., Geetha, R., Ushakumary, S., Sabiha, H.B. and Balachandran, C. (2012). Microscopic analysis of the hair follicle of Madras Red sheep. Indian Veterinary Journal. 89(1): 46-49.

Luna, L.G. (1968). Manual of Histological Staining Methods of the Armed Forces Institute of Pathology. 2nd Ed. Mc Graw Hill Book Company, New York, pp. 258.

Monterio-Riviere, N.A., Stinson, A.W. and Calhoun, H.L. (1998). Integument. Text Book of Veterinary Histology [(Eds. Dellmann, H.D. and Eurell, J.A.]. 5th Ed. Lippincott Williams and Wilkins, Philadelphia, pp. 285.

Oznurlu, Y., Sur, E., Ozparlak, H., Celik, I. and Telater, T. (2009). Comparative skin histology of White New Zealand and Angora rabbits: Histometrical and immunohistochemical evaluations. Journal of Animal Veterinary Advances. 8: 1694-1701.

Singh, U.B. and Sulochana, S. (1996). Handbook of Histological and Histochemical Techniques. Premier Publishing House, Hyderabad, pp.111.

Sumena, K.B., Lucy, K.M., Chungath, J.J., Ashok, N. and Harshan, K.R. (2010). Regional histology of papillary dermis in large white Yorkshire pigs. Indian Veterinary Journal. 87: 908-910.

Wagner, M. and Bailey, D.G. (2006). Structure of Bovine skin and hair root - A scanning electron microscope investigation. http://www.tfl. com/pdfs/others/structrue of bovine skin. pdf (12/05/06).