RESEARCH ARTICLE Indian Journal of Animal Research, Volume 57 Issue 2: 196-200 (February 2023)

Post Natal Gross Anatomical Studies on the Harderian Gland of *Pati* Duck (*Anas platyrhynchos domesticus*) of Assam

Jiten Rajkhowa[1], Kabita Sarma[1], Manmath Talukdar[1], Munmun Sarma[1], Snehangsu Sinha[1], Jakir Hussain[2]

10.18805/IJAR.B-4348

ABSTRACT

Background: The agro-climatic condition of Assam is suitable for duck rearing. Duck rearing contributes a major part to uplift the socio-economic condition of the rural poor people of Assam as well as others states located in the coastal regions of India. The *Pati* duck (*Anasplatyrhynchos domesticus*) population constitutes a major indigenous non-descript economically important duck variety in the state of Assam. The Harderian gland acts as a part of the Head Associated Lymphoid Tissue (HALT) Olah *et al.* (1992) and provides local innate immunity to the upper respiratory system, to the eye and oral cavity. Since literature on the postnatal development of Harderian gland of *Pati* duck is scant, hence the present study was designed to establish the basic anatomical details on Harderian gland at different stages of postnatal development of *Pati* duck of Assam.

Methods: The present study was conducted on total forty five (45) numbers *Pati* duck of Assam at different stages of postnatal development. The experimental birds were brought to the Department of Anatomy and Histology, College of Veterinary Science, Assam Agricultural University, Khanapara, Guwahati-22 and was sacrificed according to the method of Gracy (1986). After slaughter, the birds were placed on a clean dissecting table and skin and fascia were reflected carefully without disturbing the other organs of the head region. The Harderian gland was collected by opening the orbital cavity. Thereafter, length, breadth and thickness of the Harderian gland of all age group were recorded with the help of the Vernier Callipers (McCance, 1974) and topographical location of the gland was observed. The weight of the Harderian gland of all age group was also recorded with the help of electronic balance.

Result: The Harderian gland of *Pati* duck (*Anas platyrhynchos domesticus*) was located within the orbit. The gland was flat, oval and coma shaped with irregular border. The gland had two surfaces *i.e.* the parietal and visceral surfaces, two borders and two blunt poles. The parietal surface was found convex and attached to fascia covered by the nasal bones and interorbital septa. The visceral surface was concave and it was attached loosely to the eye ball with fascia. The lobes of the Harderian gland became more prominent with the advancement of the age. The gland was light pink in colour. The arterial blood and the venus drainage was by provided by the ophthalmic artery and vein, respectively. The slender branch of oculomotor nerve innervated the Harderian gland. The result reflected an ascending trend from 0 week age group to 42 week age group in regard to all the gross parameters. There were slight difference between left and right glands for all the gross parameters but such variations were not statistically significant (P>0.05). Each lobe of the Harderian Gland of *Pati* duck (*Anas platyrhynchos domesticus*) had a single short duct which opened into the conjunctival sac at the base of the 3rd eyelid.

Key words: Gross anatomical, Harderian gland, Parietal, *Pati* duck, Visceral surfaces.

INTRODUCTION

The *Pati* duck (*Anas platyrhynchos domesticus*) population constitutes a major indigenous non-descript duck variety in the state of Assam. Its egg has a great demand in the North-Eastern states. The Annual egg production per *Pati* duck is 70-95 eggs, (Kalita *et al*., 2009). The National Bureau of Animal Genetic Resources, India has enlisted this duck variety found in Assam in its list of livestock. This indigenous duck variety of Assam is the only duck enlisted by the Bureau under the name '*pati*' (0200 PATI 11001).

The Harderian gland acts as a part of Head associated Lymphoid tissue (HALT) Olah *et al.* (1992) that provides local innate immunity to the upper respiratory system- to the Eye and oral cavity. The Harderian gland is the major exocrine paraocular gland and a peripheral lymphoepithelial organ of the domestic fowl. In water fowl, they also have osmoregulatory functions (Wight *et al*., 1971).

[1]Department of Veterinary Anatomy and Histology, College of Veterinary Science, Assam Agricultural University, Khanapara-781 022, Assam, India.
[2]Department of Livestock Production Management, College of Veterinary Science, Assam Agricultural University, Khanapara-781 022, Assam, India.

Corresponding Author: Jiten Rajkhowa, Department of Veterinary Anatomy and Histology, College of Veterinary Science, Assam Agricultural University, Khanapara-781 022, Assam, India.
Email: rjiten10@rediffmail.com

How to cite this article: Rajkhowa, J., Sarma, K., Talukdar, M., Sarma, M., Sinha, S. and Hussain, J. (2023). Post Natal Gross Anatomical Studies on the Harderian Gland of *Pati* Duck (*Anas platyrhynchos domesticus*) of Assam. Indian Journal of Animal Research. 57(2): 196-200. doi: 10.18805/IJAR.B-4348.

Submitted: 29-10-2020 **Accepted:** 11-05-2021 **Online:** 08-06-2021

Any research finding of the postnatal development of the Harderian gland of *Pati*duck (*Anas platyrhynchos domesticus*) of Assam had not been recorded as such, so in the present study an attempt was made to establish a base line information regarding the postnatal development the gland in *Pati* duck of Assam.

MATERIALS AND METHODS

The present study was conducted on total forty five (45) numbers *Pati* duck of Assam at different stages of postnatal development. The Ducks were divided into five (5) age groups *viz.* group-1 (0 week), group-2 (4 weeks), group-3 (16 weeks), group-4 (24 weeks) and group-5 (42 weeks). The ducks were procured from Pathsala and nearby areas of Barpeta district of Assam and the duck farm under the project of Physiology department.

Details of *pati* ducks utilized in this study.

Group	Age group	No. of ducks
Group 1	0 week	9
Group 2	4 week	9
Group 3	16 week	9
Group 4	24 week	9
Group 5	42 week	9
Total		45

The experimental birds were brought to the Department of Anatomy and Histology, College of Veterinary Science, Assam Agricultural University, Khanapara, Guwahati-22 and were sacrificed (approved by the Institutional Animal Ethics Committee vide approval number: 770/ac/CPCSEA/FVSc/AAU/IAEC/17-18/491 dated 09.08.2017) according to the method of Gracy (1986). After slaughter, the birds were placed on a clean dissecting table, skin and fascia was reflected carefully without disturbing the other organs of the head region. The Harderian gland was collected by opening the orbital cavity. Thereafter, length, breadth and thickness of the Harderian gland of all age group were recorded with the help of the Vernier Callipers (Mc Cance, 1974) and location of the gland was observed. The weight of the Harderian gland of all age group were also recorded with the help of electronic balance.

RESULTS AND DISCUSSION

The Harderian gland of *Pati* duck (*Anasplatyrhynchos domesticus*) was located within the orbital cavity at the ventro medial aspect. The gland was attached along with the eye ball with the help of orbital fascia (Fig 1 to 5). The Harderian gland was exposed after removal of the nasal bones. The gland was related with the medial rectus, superior and inferior oblique muscles of the eye ball. The findings of the present study was in agreement with the findings of Slonaker (1918) in Sparrow (*Passer domesticus*), Wight *et al.* (1971) in domestic fowl, Dimitrov (2012) in pheasants and Ali *et al.* (2016) in Pigeon. The gland was not well developed in 0 weeks and 4 week age groups, so the oblique muscles could



Fig 1: Photograph showing the in-situ position of the Harderian gland (HG) of *pati* duck (0 week).

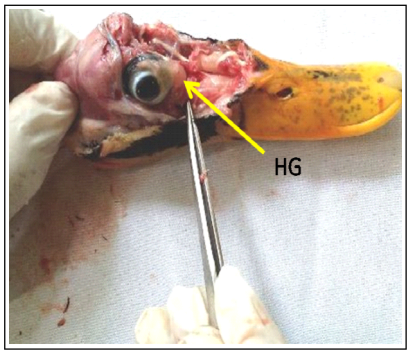

Fig 2: Photograph showing the in-situ position of the Harderian gland (HG) of *pati* duck (4 weeks).

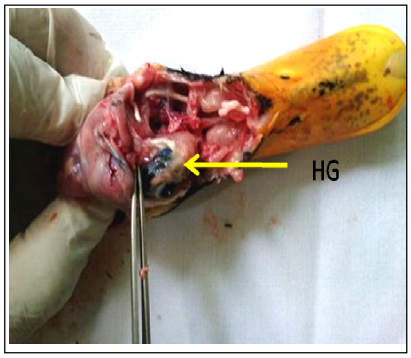

Fig 3: Photograph showing the in-situ position of the Harderian gland (HG) of *pati* duck (16 weeks).

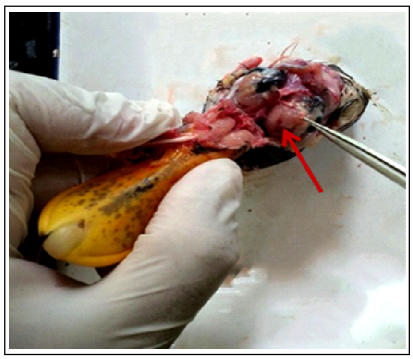

Fig 4: Photograph showing the in-situ position of the Harderian gland (HG) of *pati* duck (24 weeks).

not establish thick attachment along the dorsal and ventral pole of the gland. The relationship between the Harderian gland and the muscles of the orbit was more prominent at 16 weeks, 24 weeks and 42 weeks of age. Ventrally one part of the gland reached the optic nerve and over lied on it. Frahmand and Mohammadpour (2015) also reported similar findings in the adult Canadian Ostrich.

The gland was flat, oval and coma shaped with irregular borders. The gland had two surfaces *i.e.* the parietal and visceral surfaces, two borders and two blunt poles (Fig 6 and 7). The parietal surface was found convex and attached to fascia covered by nasal bones and interorbital septa of the orbit. The visceral surface was concave and it was attached loosely to the eye ball with fascia. The posterior border was smooth and it became convex in adult. Towards the dorsal aspect of the anterior border, there was a notch which divided the gland apparently into two lobes (Fig 7, 8 and 9). The notch was more pronounced at the 16 weeks, 24 weeks and 42 weeks age group. The similar result was also reported by Indu *et al*. (2014) in the Harderian gland of adult white Pekin Duck. The dorsal lobe was curved towards ventral direction and smaller where as the ventral lobe was found larger (Fig 8). The lobes were not so prominent in the 0 weeks and 4 weeks age group because of the smaller size of the gland. But the lobe of the Harderian gland became more prominent along with the advancement of the age. The gland was light pink colour while freshly collected and colour became distrinct at adult (Fig 6 and 7). The arterial blood supplied by the ophthalmotemporal branch of the external ophthalmic artery and the venus drainage was by the ophthalmic vein. A slender branch of oculomotor nerve innervated the gland. Similar observations were also described by Getty (1975) in the avian species, Slonaker (1918) in Sparrow (*Passer domesticus*), Wight *et al.* (1971) in Fowl, Altunay and Kozlu (2004) in Ostrich, Frahmand and Mohammadpour, (2014) in Ostrich, Kleckowska-Nawrot *et al.* (2014) in ostrich and Ali *et al*. (2016) in pigeon.

The average length of the gland was recorded as 7.37±0.32 mm and 7.55±0.38 mm; 10.34±0.25 mm and 10.42±0.22 mm; 12.60±0.13 mm and 12.77±0.39 mm; 13.72±0.16 mm and 13.82±0.24 mm; 14.12±0.24 mm and 14.23±0.21 mm in left and right gland respectively in

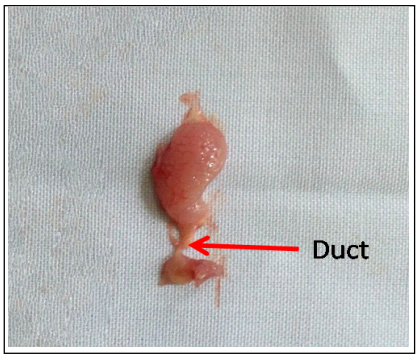

Fig 7: Photograph showing the duct of the Harderian gland (HG) of *Pati* duck (16 weeks).

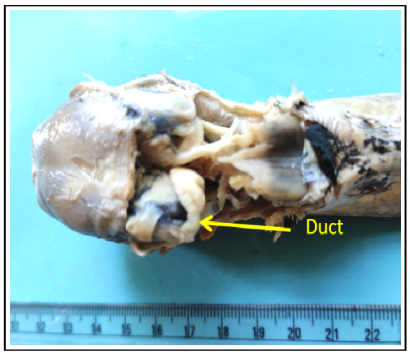

Fig 5: Photograph showing the in-situ position of the Harderian gland (HG) of *Pati* duck with the duct (42 weeks).

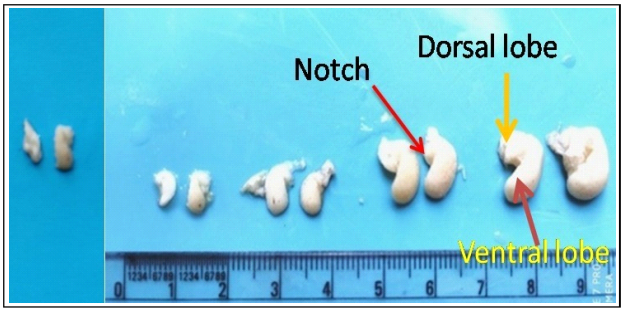

Fig 8: Photograph showing the lobes of the Harderian gland (HG) of *Pati* duck.

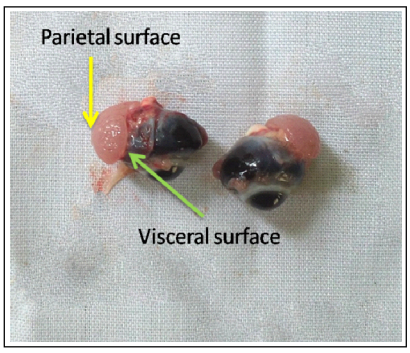

Fig 6: Photograph showing surfaces of the Harderian gland (HG) of *Pati* duck (16 weeks).

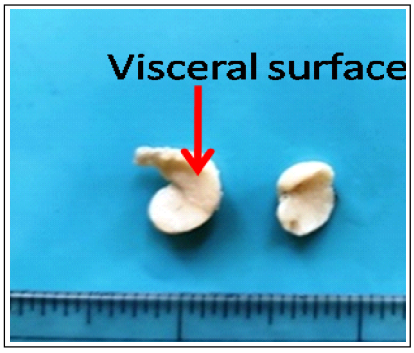

Fig 9: Photograph showing the visceral surface of the Harderian gland (HG) with duct of *Pati* duck (24 weeks).

Table 1: Average length, breadth, thickness and weight of the left and right harderiangland of pati duck during post natal development.

Age group	Length (mm)		Breadth (mm)		Thickness (mm)		Weight (mg)	
	Left	Right	Left	Right	Left	Right	Left	Right
0 week	7.37±0.32	7.55±0.38	3.78±0.20	3.79±0.21	1.22±0.12	1.25±0.12	94.16±2.87	94.33±3.05
4 week	10.34±0.25	10.42±0.22	5.83±0.16	5.84±0.16	1.46±0.09	1.50±0.08	165.67±3.98	167.83±3.12
16 week	12.60±0.13	12.77±0.39	6.18±0.17	6.19±0.17	1.60±0.15	1.65±0.16	196.16±6.18	198.21±6.46
24 week	13.72±0.16	13.82±0.24	6.74±0.20	6.75±0.21	1.85±0.12	1.88±0.14	282.17±8.86	284.67±9.31
42 week	14.12±0.24	14.23±0.21	7.13±0.15	7.28±0.12	2.12±0.11	2.14±0.15	392.17±4.94	398.67±3.54

p value ≥ 0.5.

0 weeks, 4 weeks, 16 weeks, 24 weeks and 42 weeks age group. The average breadth was recorded as 3.78±0.20 mm and 3.79±0.21 mm; 5.84±0.16 mm and 5.83±0.16 mm; 6.18±0.17 mm and 6.19±0.17 mm; 6.74±0.20 mm and 6.75±0.21 mm and 7.13±0.15 mm and 7.28±0.12 mm of the left and right gland respectively in 0 weeks, 4 weeks, 16 weeks, 24 weeks and 42 weeks age group. The average thickness was recorded 1.22±0.12 mm and 1.25±0.12 mm; 1.46±0.09 mm and 1.50±0.08 mm; 1.60±0.15 mm and 1.65±0.16 mm; 1.85±0.12 mm and 1.88±0.14 mm and 2.12±0.11 mm and 2.14±0.15 mm of the left and right gland respectively in 0 weeks, 4 weeks, 16 weeks, 24 weeks and 42 weeks age group. The weight of the Harderian gland of *Pati* duck of 0 weeks, 4 weeks, 16 weeks, 24 weeks and 42 weeks age groups was recorded as 94.16±2.87 mg and 94.33±3.05 mg; 165.67±3.98 mg and 167.83±3.12 mg; 196.16±6.18 mg and 198.21±6.46 mg; 282.17±8.86 mg and 284.67±9.31 mg and 392.17±4.94 mg and 398.67±3.54 mg of the left and right respectively (Table 1). Findings of the present study in the adult age group were similar with the observation in adult white Pekin duck by Indu *et al*. (2014). In the macrometrical study of the Harderian gland of the Canadian Ostrich by Frahmand and Mohammadpour (2015) recorded little higher value and it might be due to species difference and higher body weight of the Ostrich.

The result reflected an ascending trend from 0 weeks age group to 42 weeks age group in all the parameters (Table 1). The Harderian gland of *Pati* Duck of Assam grew slowly till it reached the adult age. There were slight difference between left and right gland in all the parameter of the gross measurement but it was statistically not significant (P>0.05).

In the present research work, a single duct was observed in the Harderian Gland of *Pati* duck (*Anas platyrhynchos domesticus*). The duct was emerged from the anterior border of the dorsal lobe near the notch (Fig 5 and 7). Wight *et al.* (1971) also reported that the duct of the Harderian gland of fowl was single and sometimes it was pigmented. In the fowl, turkey and duck a single duct left the anterior tip of the Harderian gland to open into the conjunctival sac at the base of the nictitating membrane as reported by Burns and Maxwell (1978). In the 0 weeks and 4 weeks it was difficult to locate and measure the duct as it was blended with the fascia. In 16 weeks, 24 weeks and 42 weeks the duct was noticeable and clearly differentiate from the fascia. The average length of the duct was recorded as 4.34±0.45 mm and 4.41±0.36 mm; 5.15±0.52 mm and 5.22±0.46 mm and 5.78±0.63 mm and 5.82±0.68 mm of the left and right Harderian gland of 16 weeks, 24 weeks and 42 weeks of age group respectively. The duct ultimately opened into the conjunctival sac at the base of the 3rd eyelid. The present findings revealed similarity with the finding of Payne (1992) in Fowl, Indu *et al*. (2014) in white Pekin duck and Ali *et al*., (2016) in pigeon.

Summary and Conclusion

The Harderian gland of *Pati* duck (*Anas platyrhynchos domesticus*) was located at the medio-ventral aspect of the orbital cavity, attached to the eye ball with the help of orbital fascia. The medial rectus muscle, superior and inferior oblique muscles of the eye ball were in relation with the gland. Ventrally one part of the gland reached the optic nerve and over lied on it. The gland was flat, oval and coma shaped with irregular border. The gland had two surfaces *i.e.* the parietal and visceral surfaces, two borders and two blunt poles. The parietal surface was found convex and attached to the nasal bones and inter orbital septa of the orbit. The visceral surface was concave and it was attached loosely to the eye ball with fascia. Towards the dorsal aspect of the anterior border there was a notch which divided the gland apparently into two lobes. The lobe of the Harderian gland became more prominent with the advancement of the age. The gland was light pink while freshly collected. The arterial blood supplied and the venus drainage was by the ophthalmic artery and vein. The slender branch of oculomotor nerve innervated the Harderian gland.

References

Ali, F.R., Ilaf H.H. and Hadaf, H.M. (2016). Morphological and histochemical study of harderian gland of domestic pigeon (*Columba liviadomestica*). Bull. Iraq nat. Hist. Mus. 14 (2): 161-170.

Altunay, H. and Kozlu, T. (2004). The fine structure of the Harderian gland in the ostrich (*Struthio camelus*). Anatomia Histologia Embryologia. 33: 141-145.

Burns, R.B. (1978). Histology of Harder's gland of the rockhopper, penguin, Eudyptes crestatus. Zoological Journal of the Linnean Society. 64: 129-133.

Dimitrov, D. (2012). Histometry of third eyelid (Harderian) gland in helmeted guinea fowl (*Numida meleagris*). Agricultural Science and Technology. 4(4): 368-370.

Frahmand, S. and Mohammadpour, A.A. (2015). Harderian gland in Canadian ostrich (*Struthio camelus*): A morphological and histochemical study. Anat. Histol. Embryol. 44: 178-185.

Getty, R. (1975). The Anatomy of the Domestic Animals. Volume 2. Fifth edition.

Gracy, J.F. (1986). Bleeding Method of Slaughtering-Slaughter. Meat Hygiene. 8th edn., Pp. 144-145.

Indu, V. R., Lucy, K.M., Sreeranjini, A.R., Maya, S.,Ashok, N. and Chungath, J.J. (2014). Gross and histological studies on the Harderian gland of White Pekin ducks (*Anas platyrhynchos*). Indian Journal of Veterinary Anatomy. 26(1): 25-26.

Kalita, N., Barua, N.,Bhuyan, J. and Chidananda, B.L. (2009). Present Status of Duck Farming in Assam. Proceeding of IV World Waterfowl Conference Held at Thrissur, Kerala, India, 11-13 Nov, Pp. 359-363.

Kleckowska-Nawrot, J., GoŹdziewska-HarŁajczuk, K.G., Barszcz, K. and Kowalczyk, A. (2014). Morphological studies on the Harderian gland in the Ostrich (*Struthio camelus domesticus*) on the embryonic and post-natal period. Anat. Histol. Embryol. 44: 146-156.

McCance, R.A. (1974). The effect of age on the weights and lengths of pigs intestine. Journal of Anatomy. 117(3): 475-479.

Olah, I., Scottr, T.R., Gallego, M., Kendall, C. and Glick, B. (1992). Plasma cells expressing immunoglobulins M and A but not immunoglobulin G develop an intimate relationship with centralcanal epithelium in the Harderian gland of the chicken. Poultry Science. 71: 664-676.

Payne, A.P. (1994). The Harderian gland: A tercentennial review. Journal of Anatomy. 185: 1-49.

Slonaker, J.R. (1918). A physiological study of the anatomy of the eye and its accessory parts of the English sparrow (*Passer domesticus*). Journal of Morphology. 31: 351-459.

Wight, P.A.L., Burns, R.B., Rothwell, B. and Mackenzie, J.G.M. (1971). The Harderian gland of the domestic fowl. I. Histology, with reference to the genesis of plasma cells and Russell bodies. Anat. 110(2): 307-315.