RESEARCH ARTICLE Indian Journal of Animal Research, Volume 57 Issue 7: 922-927 (July 2023)

Radiographic Assessment of Dogs with Congestive Heart Failure

N. Saini[1], S.K. Uppal[1], A. Anand[1]

10.18805/IJAR.B-4352

ABSTRACT

Background: Radiography is widely used for diagnosis of congestive heart failure as it enables non-invasive assessment of cardiac size, shape and pulmonary vasculature. So, the present study was conducted to record the radiographic changes in dogs with congestive heart failure.

Methods: Fifty-one dogs with cardiac insufficiency brought to Teaching Veterinary Hospital of GADVASU, showing one of the clinical signs of chronic cough, dyspnea, exercise intolerance, abdominal distension, syncope and cyanosis were selected and were subjected to Lateral and Ventro-dorsal chest radiography.

Result: Dilated cardiomyopathy was present in 24 dogs. Radiographically, pulmonary edema, cardiomegaly, vessel congestion were more common in dilated cardiomyopathy (DCM). Valvular diseases were present in 16 dogs and radiographically left atrial (LA) dilatation was present in dogs with valvular diseases. Pericardial effusions were present in 11 dogs showing enlarged globoid heart radiographically.

Key words: Dilated cardiomyopathy, Dogs, Pericardial diseases, Radiography, Valvular diseases.

INTRODUCTION

The radiographic diagnosis of heart failure is based upon the fact that circulatory imbalances leads to reduced cardiac output in pulmonary or systemic circulation. So, depending on which side of the heart is most severely affected, blood is shifted from the systemic to the pulmonary circulation in left sided heart failure and from the pulmonary to the systemic circulation in right sided heart failure. In dilated cardiomyopathy (DCM), there is cardiomegaly of left side chambers or both left and right sided heart enlargement. However, in valvular diseases, severe left atrial enlargement and widening of bronchus leading to bowleg appearance is observed (Abbott, 2008). The pulmonary venous congestion, tracheal elevation and alveolar edema is seen in both DCM and valvular diseases. An enlarged and globoid cardiac silhouette is cardinal radiographic feature of pericardial effusions (Tobias and Mcniel, 2008).

MATERIALS AND METHODS

The study was conducted on 51 clinical cases of cardiac insufficiency brought to Teaching Veterinary Hospital of GADVASU. The dogs were selected on the basis of clinical signs, clinical examination and radiographic examination. Animals showing one of the clinical signs of chronic cough, dyspnea, exercise intolerance, abdominal distension, syncope and cyanosis were selected and were subjected to electrocardiography and echocardiography to confirm the diagnosis.

Patient positioning

All the dogs were positioned in Lateral and Ventro-dorsal (VD) position. For lateral views, the sternum and spine were in horizontal plane and front legs were pulled as far cranially as possible. For VD views, dogs were positioned to assure that sternum and vertebrae are superimposed.

[1]Department of Veterinary Medicine, Guru Angad Dev Veterinary and Animal Sciences University, Ludhiana-141 001, Punjab, India.

Corresponding Author: N. Saini, Department of Veterinary Medicine, Guru Angad Dev Veterinary and Animal Sciences University, Ludhiana-141 001, Punjab, India.
Email: sainin26@gmail.com

How to cite this article: Saini, N., Uppal, S.K. and Anand, A. (2023). Radiographic Assessment of Dogs with Congestive Heart Failure. Indian Journal of Animal Research. 57(7): 922-927. doi: 10.18805/IJAR.B-4352.

Submitted: 30-10-2020 **Accepted:** 04-05-2021 **Online:** 09-06-2021

The heart size in the lateral view was evaluated by using vertebral heart scale (VHS) as described by Buchanan and Bucheler (1995). In lateral radiographic view, the long axis (L) of the heart was measured from the ventral border of the carina to the most distant ventral contour of the heart and the short axis (S) of the heart was measured perpendicular to the long axis at the level of the caudal vena cava as shown in schematic diagram. Measurements of both long and short axis were repositioned over the thoracic vertebra, starting at fourth thoracic vertebrae. The lengths in vertebrae (v) of the long and short axes were then added to obtain a vertebral heart scale (VHS).

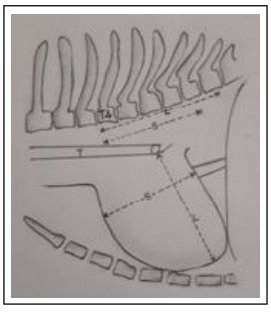

In lateral view, cranial mediastinum was checked for any effusions or edema. The intercostal width of cardiac shadow was made at an axis perpendicular to long axis of the ribs. The sternal contact was scored as mild (+), moderate (++) and severely (+++) increased. The position of trachea was graded as mildly elevated (+), converging (++), parallel to thoracic vertebrae (+++) and almost touching ventral aspect of thorax (++++). The tracheal bifurcation angle was scored as normal, mildly increased (+), moderately increased (++)and severely increased (+++). The pulmonary vasculature was compared with 4th rib and graded as normal, mildly increased (+), moderately increased (++) and severely increased (+++). The pulmonary changes in form of fluid or edema or both were evaluated in cranial lung lobe, caudal lung lobe and perihilar region. The lung pattern was either interstitial or alveolar or both. The lungs were checked for the presence or absence of pleural effusions. The apex of heart was checked for elevation.

In VD view, the heart size was evaluated by measuring cardio thoracic index comparing the widest part of the heart to the widest part of the thorax. The cardiac shadow was scored as ≥66%, ≤66% and =66%. The chamber enlargement was checked in left atrium (LA), left ventricle (LV), right atrium (RA) and right ventricle (RV) and scored as normal, mildly increased (+), moderately increased (++) and severely increased (+++). The apex of heart was scored as normal *i.e.*, near the median, mildly shifted from median (+), towards lateral thoracic margin (++). The tracheal bifurcation angle was graded as normal, increased and bowleg. The VD view was checked for presence of pleural reflections. The pulmonary vasculature at the level of 9th rib was checked for normal, mildly increased (+), moderately increased (++) and severely increased (+++).

RESULTS AND DISCUSSION

Radiographic findings in dogs with Dilated cardiomyopathy (DCM)

The overt stage of DCM was characterized by presence of clinical signs of heart failure however occult stage of DCM was characterized by morphological or electrical derangement in the absence of clinical signs. So, the dog was normal in this stage but had biochemical/electrocardiographic/ echocardiographic evidence of abnormality (O'Grady and O'Sullivan, 2004). In the present study, fifty-one dogs were diagnosed with cardiac problems, out of which, DCM was diagnosed in 24 dogs. Out of 24 DCM dogs, 13 dogs were affected with overt form and 11 dogs with occult form of DCM.

(i) Radiographic findings in overt DCM

Radiographic changes observed in dogs with overt DCM are presented in Fig 1. In lateral chest radiograph, cranial mediastinum showed edema in nine cases, edema + effusions in two cases and two cases were normal. The intercostal width of cardiac shadows was 3.5-4 in 11 cases and >4

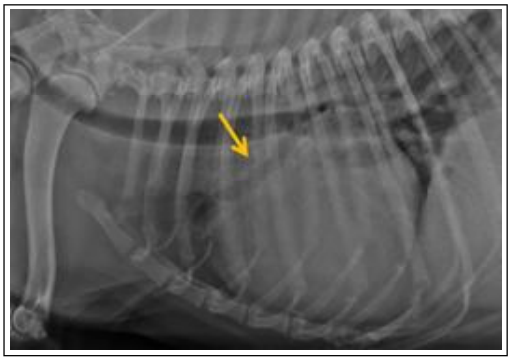

Fig 1: Cardiomegaly (4 ICS), pulmonary vessel dilation and trachea lifted.

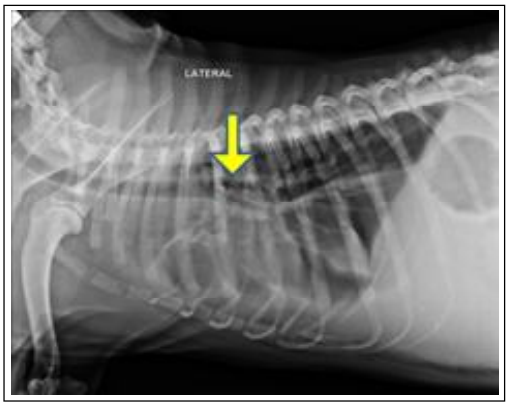

Fig 2: Lateral chest radiograph indicating increased tracheal bifurcation angle.

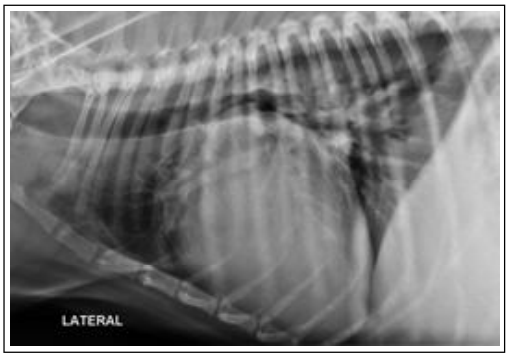

Fig 3: Severe pulmonary congestion and alveolar edema.

(Fig 1) in 2 cases. Vertebral heart score (VHS) was 11-12 in 5 cases and more than or equal to 12 in 8 cases. Buchanan and Bucheler (1995) reported that normal canine VHS reference range is 8.7 to 10.5 in different dog breeds. Gugjoo *et al.* (2013) observed that VHS increased significantly in dogs affected with DCM. Lamb *et al.* (2001) also concluded that VHS value above 10.7 was found to be an accurate sign of cardiac disease in most of the cases.

The tracheal elevation was very severe (++++) *i.e.*, touching the ventral aspects of thoracic vertebrae in 6 cases (Fig 1), severe (+++) *i.e.*, parallel to the thoracic vertebrae in 3 cases, moderate (++) *i.e.*, converging towards thoracic

vertebrae in 2 cases. The dorsal elevation of the trachea, carina and mainstem bronchus occurred due to the left atrial enlargement (Poteet, 2008). Tracheal bifurcation angle was severe (+++) in 4 cases (Fig 2), moderate (++) in 6 cases and mild (+) in 1 case. Pulmonary vasculature at the level of 4th rib was markedly dilated (++++) in 5 cases (Fig 3), severely dilated (+++) (Fig 4) in 4 cases. Distended pulmonary veins were due to pulmonary venous hypertension (Charles and Bahr, 2002). On the lateral view, the average pulmonary vein diameter at the fourth rib was >75% of the width of the proximal one-third of that rib indicating dilation. Pulmonary edema was present in perihilar region in 12 cases (Fig 4). However, pulmonary edema in perihilar region as well as caudal and cranial lung lobe in 4 cases. Suter and Lord (1984) observed that cardiogenic pulmonary edema was manifested in the hilar and caudodorsal lung regions usually with a symmetric distribution in the caudal lung lobes. Cardiogenic pulmonary edema was caused by an increase in pulmonary venous hydrostatic pressure resulting from an increased left atrial pressure as a result of more interstitial fluid produced than that accommodated by the lymphatic vessels (Hughes, 2004). Alveolar lung pattern (Fig 3) was seen in 7 cases, alveolar + interstitial pattern mixed in 5 cases. Severe pleural effusions (++++) were present in 1 case, moderate (++) in 3 cases and mild (+) in 3 cases. Apex of the heart was elevated in 3 cases.

In VD view, the radiographic changes in dogs observed were as follows: The cardio thoracic shadow was 95% in 2 cases (Fig 5) and ≥66% in 11 cases and =66% in 1 case. Markedly severe (++++) LA enlargement was present in 1 case, severe (+++) LA enlargement was present in 2 cases, moderate (++) LA enlargement in 6 cases and mild (+) LA enlargement in 3 cases. Markedly severe LV enlargement was present in 1 case, severe in 1, moderate in 7 and mild in 3 cases. RA enlargement was markedly severe in 2 cases, severe in 3, moderate in 4, mild in 1 and normal in 3 cases. RV enlargement was markedly severe in 1 case, severe in 4 case, moderate in 6 cases, mild in 1 case. The position of apex was towards the lateral thoracic margin in 8 cases. Bowleg was observed at tracheal bifurcation angle (Fig 6) and markedly severe in 2, severe in 4, moderately increased in 3 cases. Pulmonary vasculature at the level of 9th rib was severely increased in 4 cases and moderately increased in 6 cases. The prominence of pulmonary veins indicated venous congestion and left-sided CHF.

(ii) Radiographic findings in occult DCM

The lateral chest radiograph showed edema in 1 case, increased intercostal shadow up to 3.5 ICS in 3 cases, increased sternal contact in 6 cases. Tracheal elevation was severe in 4 cases, moderately elevated in 1 case and normal in rest of the dogs with occult DCM. Tracheal bifurcation angle was moderately increased in 1 case. Pulmonary vasculature at the level of 4th rib was moderately increased in 2 cases. Pulmonary edema in perihilar region was present in 1 case. However, pulmonary edema in cranial and caudal lung lobes were present in 3 cases and only in caudal lung lobe in 1 case. Alveolar lung pattern was observed in 1 case, interstitial lung pattern in 5 cases, alveolar and interstitial mixed in 1 case only. Mild pleural effusions were present in 1 case only. Apex of the heart was elevated in 3 cases. The cardiothoracic shadow was > 66% in 1 case. LA was normal in all cases, LV was moderately increased in 1 case, mild increase in 1 case. RA was moderately increased in 1 case and mildly increased in 1 case. RV was moderately increased in 1 case and mildly increase in 1 case. Mildly



Fig 4: Cardiomegaly and pulmonary oedema.



Fig 5: VD chest radiograph showing cardiomegaly and Bowleg trachea (arrow).



Fig 6: Bowleg trachea.

increased Bowleg of tracheal bifurcation angle was observed. Pulmonary vasculature at the level of 9th rib was mildly increased.

Radiographic changes in Valvular diseases

In the present study, 16 dogs were diagnosed with chronic valvular diseases. Out of 16 dogs, 5 dogs were having stage C heart failure (severe mitral regurgitation and severe clinical signs of heart failure) whereas 11 dogs were in stage B heart failure (mild mitral regurgitation with no clinical signs of heart failure).

(i) Radiographic findings in stage C valvular diseases

The lateral chest radiograph showed edema in 2 cases, however edema + effusions were present in 2 cases in cranial mediastinum. The ICS was 3.5-4 in 4 cases. Vertebral heart score (VHS) was more than 12 in 1 case and in range of 11-12 in 4 cases. The sternal contact was increased in 4 cases. The trachea was markedly lifted in 2 cases (Fig 7), severely lifted in 2 cases, moderately lifted in 1 case. Tracheal bifurcation angle was severely increased in 1 case, moderately increased in 4 cases. Pulmonary vasculature at the 4th rib was severely dilated in 1 case and moderately dilated in 1 case. Pulmonary edema + effusions were present in 2 cases. Pulmonary edema was observed in cranial, caudal lung lobe as well as perihilar region in 1 case only, pulmonary edema in cranial and caudal lung lobe in 2 cases. Alveolar lung pattern was observed in 1 case, mixed (alveolar + interstitial) pattern in 1 case and interstitial only in 4 cases. The unstructured interstitial pattern reflected an early stage of pulmonary involvement during congestive heart failure, however, transudate leakage into the alveolar spaces in the later stages indicated alveolar pattern of cardiogenic pulmonary edema (Thrall, 2002).

The VD chest radiograph of the dogs affected with valve stage C diseases indicated severe pleural effusions in 2 cases and moderate pleural effusions in 2 cases. The cardiothoracic shadow ≥66% in 3 cases. LA enlargement was markedly severe in 2 cases (Fig 8), severe in 1 case and normal in 4 cases. Bowleg of tracheal bifurcation angle was severely increased in 1 case and moderately increased in 1 case. Due to severe left atrial enlargement, there was displacement and separation of the main stem bronchi as it reached the cranial border of the left atrium and bifurcate around left atrium thus producing a “bow-legged cowboy” appearance to the bronchial tree (Hamlin, 2006).

LV was moderately increased in 4 cases, normal in 3 cases. Pleural reflections were present in 1 case. Pulmonary vasculature at the level of 9th rib was severely dilated in 3 cases.

ii) Radiographic findings in stage B valvular diseases

In the lateral chest radiograph, the cranial mediastinum showed edema in 3 cases and edematous fluid in 1 case. ICS was > 3.5 in 3 cases only. Sternal contact was moderately increased in 4 cases. Trachea was moderately lifted and converging in 6 cases. Tracheal bifurcation angle was severely increased in 1 case, moderately increased in 1 case and mildly increased in 3 cases. Pulmonary edema in perihilar region was present in 3 cases. Edematous fluid was present in 1 case. Edema in cranial and caudal lung lobe was present in 3 cases. Lung pattern was alveolar in 1 case, mixed in 1 case, interstitial in 4 cases and interstitial + bronchial in 1 case. Moderate pleural effusions were present in 2 cases. Apex of the heart was elevated in 1 case.

The VD view of chest radiograph of the dogs affected with valvular stage B heart diseases indicated cardiac shadow > 66% in 5 cases. Severe LA enlargement was present in 1 case, mild in 1 case. Severe LV enlargement was present in 3 cases, moderate in 1 case and mild enlargement in 1 case. Moderate RA enlargement was observed in 2 cases, mild RA enlargement in 1 case, normal in 6 cases. Mild RV enlargement was seen in 3 cases only. Severe Bowleg of tracheal bifurcation angle was observed in 3 cases. Pulmonary vasculature at the level of 9th rib was moderately increased in 1 case.

C) Radiographic findings in pericardial diseases

11 dogs were diagnosed with pericardial and pleural effusions. Lateral chest radiographic findings in animals with



Fig 7: Lateral chest radiograph showing left atrial enlargement indicating mitral valve insufficiency.



Fig 8: VD chest radiograph showing left atrial enlargement indicating mitral valve insufficiency.

pericardial and pleural effusions were: Cranial mediastinum showed severe effusions + edema (++++) in 5 cases, only edema in 2 cases and only effusions in 4 cases. The ICS of cardiac shadow was >3.5 in 4 cases (Fig 9) and not detected in rest of the cases due to effusions. VHS was found to be greater than 12 in all the cases. Vishnurahav *et al.* (2019) also found that in lateral thoracic radiograph, the cardiac silhouette was globoid and masked with fluid. Sternal contact was markedly severe (++++) in 2 cases, severely increased in 1 case, moderately increased in 1 case. Trachea was markedly elevated in 2 cases, severely elevated in 6 cases, moderately elevated in 3 cases. Tracheal bifurcation angle was severely increased in 1 case, moderately increased in 6 cases, mild to moderate in 2 cases. Pulmonary vasculature at the level of 4th rib was markedly increased in 4 cases and moderately increased in 2 cases. Pulmonary changes indicated edema in cranial, caudal and perihilar region in 3 cases, edema in either caudal or cranial lung lobe in 4 cases and severe effusions in 2 cases. Lung pattern was alveolar in 7 cases, interstitial in 3 cases. Pleural effusions were markedly severe in 9 cases (Fig 10) and mild in 1 case. Apex of the heart was elevated in 1 case.

VD view of the chest radiograph showed cardiac shadow ≥66% in 4 cases. In rest of the other cases, shadow was not detected due to effusions. Globoid heart was observed in 1 case due to pericardial effusions (Fig 11). The enlargement of cardiac silhouette in a "basketball" shape with elimination of all normal cardiac margin contours was the diagnostic feature of pericardial effusion (Poteet, 2008). Due to pleural effusions in 7 cases, cardiac boundaries were not clear. In 4 cases, in which cardiac silhouette was clear, LA and LV were moderately increased in 1 case. However, RA and RV were severely increased in 1 case and moderately increased in 1 case. Position of the apex was towards lateral thoracic wall in 2 cases. Bowleg of tracheal bifurcation angle was markedly severe in 2 cases, moderately increased in 2 cases. Severe pleural reflections/ fissures were present in 4 cases and severe in 1 case (Fig 12). Development of pleural fissure lines and pleural effusion was usually a sign of biventricular CHF and a fluid retentive state (Bonagura and Samii, 2006). The thickness and number of interlobar fissures seen with pleural fluid varied according to the amount of fluid and the relative position of the patient and the X-ray beam (Thrall, 2002). Pulmonary vasculature at the level of 9th rib was markedly increased in 1 case and moderately increased in 1 case.

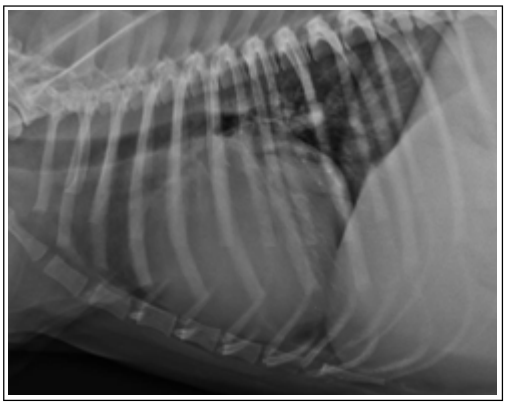

Fig 9: Lateral chest radiograph showing pericardial effusions.

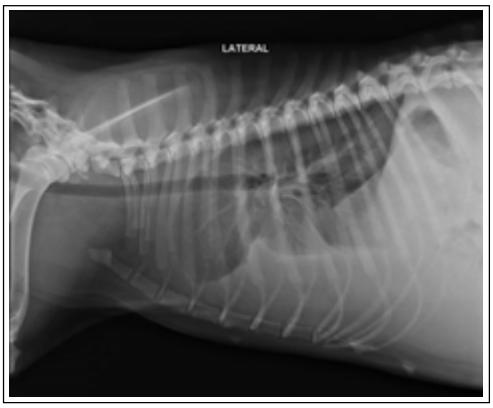

Fig 10: Lateral chest radiograph indicating pleural effusions.



Fig 11: VD chest radiograph showing pericardial effusions.



Fig 12: VD chest radiograph showing pleural reflections indicating pleural effusions.

CONCLUSION

Thoracic radiography can also be used in patients suspected of cardiac disease and allows assessment of cardiac size, pulmonary vasculature and its parenchyma. However conclusive diagnosis of the congestive heart failure should be done after physical examination and other imaging techniques.

ACKNOWLEDGEMENT

The authors wish to thank faculty, Department of Veterinary Medicine as well as Department of Veterinary Surgery and Radiology, Guru Angad Dev Veterinary and Animal Sciences University (GADVASU) for providing facilities to conduct this study.

Conflict of interest statement

We declare that we have no conflict of interest.

REFERENCES

Abbott, J.A. (2008). Acquired Valvular Diseases. In: Manual of Canine and Feline Cardiology. 4th edn, Saunders, St. Louis, Missouri. pp. 110-138.

Bonagura, J.D. and Samii, V.F. (2006). Cardiovascular Radiography. In: Saunders Manual of Small Animal Practice. 3rd edn. Saunders, Elsvier. pp. 1430-1440.

Buchanan, J.W. and Bucheler, J. (1995). Vertebral scale system to measure canine heart size in radiographs. Journal of American Veterinary Medical Association. 206(2): 194-199.

Charles, R.R. and Bahr, R.J. (2002). The Heart and Great Vessels. In: Textbook of Veterinary Diagnostic Radiology. 4th edn. Saunders, Elsvier. pp 402-419.

Gugjoo, M.B., Hoque, M., Saxena, A.C. and Zama, M.M.S. (2013). Radiographic, electrocardiographic and echocardiographic features of dilatation cardiomyopathy in dogs. Indian Veterinary Journal. 90(12): 54-56.

Hamlin, R.L. (2006). Auscultation and Physical Diagnosis In: Saunders Manual of Small Animal Practice. 3rd edn. Saunders, Elsvier. pp 1421-1429.

Hughes, D. (2004). Pulmonary Edema In: Respiratory Disease in Dogs and Cats. G. St Louis, Saunders. pp. 487-497.

Lamb, C.R., Wikeley, H., Boswood, A. and Pfeiffer, D.U. (2001). Use of breed-specific ranges for the vertebral heart scale as an aid to the radiographic diagnosis of cardiac disease in dogs. Veterinary Record. 148: 707-711.

Poteet, B.A. (2008). Radiology of the Heart. In: Manual of Canine and Feline Cardiology. Saunders. Elsvier. pp 24-48.

Suter, P.F. and Lord, P.F. (1984). Lower Airway and Pulmonary Parenchymal Disease. In: Thoracic Radiography: A Text-Atlas of Thoracic Diseases of the Dog and the Cat. Wettswill, Switzerland. pp 553-568.

Thrall, D.E. (2002). The Pleural Space. In: Textbook of Veterinary Diagnostic Radiology. 4th edn. Saunders, Elsvier. pp. 390-401.

Tobias, A.H. and McNiel, E.A. (2008). Pericardial Disorders and Cardiac Tumors. In: Manual of Canine and Feline Cardiology. 4th edn. Saunders, Elsvier. pp 200-14.

Vishnurahav, R.B., Kumar, S.A., Pillai, U.M. and Unny, N.M. (2019). Diagnosis and management of cardiac tamponade due to pericardial effusion secondary to aortic body tumor in a Spitz. The Pharma Innovation Journal. 8(1): 82-85.