RESEARCH ARTICLE Indian Journal of Animal Research, Volume 57 Issue 8: 1091-1095 (August 2023)

Sterilization of Male Dogs by Intra-testicular Administration of Calcium Chloride Solution

Tushar Thakre[2], S.N. Shukla[1], Aditya Mishra[3], Nidhi Gupta[4], Pratyush Kumar[5]

10.18805/IJAR.B-4356

ABSTRACT

Background: Chemical castration is one of the methods of non surgical contraception which has been suggested as a fast and low cost alternative to control a wide range of canine population.

Methods: The potency of intra-testicular 20% calcium chloride solution was tested in 12 fertile, healthy and stray adult male dogs. Dogs were divided randomly into two groups, consisting six animals in each. The animals of group-I were administered intra-testicular 1.0 ml of 20% calcium chloride solution. Bilateral intra-testicular injection was performed using 21 gauge needle directed from the caudo-ventral aspect of each testis approximately 1 cm from the cauda epididymis and towards the dorso-cranial aspect of testis as per the procedure adopted by Jana and Samanta (2007). In group-II, 1.0 ml of normal saline was injected intra-testicular as placebo. Its efficacy was assessed by testicular morphometry, scrotal circumference (on day 0, 7, 15 and 30), histo-morphology (on day 0 and 30) and serum testosterone assay (on day 0, 15 and 30 of treatment).

Result: The testicular morphometry of both the testicles was found to be increased size of testes significantly on day 7 in the treatment group as compared to day 0 and then decreased gradually and significantly on day 15 and 30. Histo-morphological study revealed significant changes including complete derangement of seminiferous tubules on day 30 post-treatment. Out of six animals the testes of four animals represented complete destruction of outline of seminiferous tubules. The germinal epithelium and Leydig cells were degenerated and parenchyma was replaced by fibro-collagenous tissue which was evident by the presence of numerous fibrocytes and fibroblast. There was no evidence of mature germ cells in section of both the testes. In some areas small blood capillaries were observed which may indicate neo-vascularisation. Discrete inflammatory infiltration of leucocytes was also observed in the parenchyma. Decrease in serum testosterone level after the end of study, *i.e.,* day 30 indicated degeneration of Leydig cells. It can be concluded that 20% calcium chloride solution has a potential for testicular degeneration and thus sterilization of male dogs.

Key words: Calcium chloride, Chemical sterilization, Male dog, Testicular morphometry.

INTRODUCTION

Canine overpopulation has become a global problem with significant public health impacts (Ahmed, 2015). India has approximately 25 million dogs, with an estimated dog to man ratio of 1:36 and approximately 80% dogs are community dogs which are unrestricted and partially dependent on others (Menezes, 2008). Dogs also play an evident role as a vector in transmission of rabies which is a major zoonotic disease in humans and livestock.

For controlling stray dog population, the most widely accepted and followed protocol is castration or bilateral orchidectomy. The main methods of castration are surgical, hormonal, immunological and chemical castration. The present common method of dog's population control is surgical sterilization which requires anaesthesia, medical equipment, a suitable surgical facility, post-operative care and the advanced training of a veterinarian and bears different risks. However, chemical castration has been suggested as a fast and low cost alternative that can be used in a wide range of canine population, especially in regions where the problem is more intense (Soto *et al.,* 2007). Hence, present study was conducted to evaluate the efficacy of intra-testicular administration of 20% calcium chloride solution on testicular degeneration and serum testosterone concentration in dogs.

[1]Department of Veterinary Gynaecology and Obstetrics, College of Veterinary Science and Animal Husbandry, Nanaji Deshmukh Veterinary Science University, Jabalpur-482 001, Madhya Pradesh, India.
[2]Veterinary Polytechnic College, Rewa-486 550, Madhya Predesh, India.
[3]Department of Veterinary Physiology, College of Veterinary Science and Animal Husbandry, Nanaji Deshmukh Veterinary Science University, Jabalpur-482 001, Madhya Pradesh, India.
[4]Department of Veterinary Anatomy, College of Veterinary Science and Animal Husbandry, Nanaji Deshmukh Veterinary Science University, Jabalpur-482 001, Madhya Pradesh, India.
[5]Department of Veterinary Gynaecology and Obstetrics, National Dairy Research Institute, Karnal-132 001, Haryana, India.

Corresponding Author: S.N. Shukla, Department of Veterinary Gynaecology and Obstetrics, College of Veterinary Science and Animal Husbandry, Nanaji Deshmukh Veterinary Science University, Jabalpur -482 001, Madhya Pradesh, India. Email: snshukla2@gmail.com

How to cite this article: Thakre, T., Shukla, S.N., Mishra, A., Gupta, N. and Kumar, P. (2023). Sterilization of Male Dogs by Intra-testicular Administration of Calcium Chloride Solution. Indian Journal of Animal Research. 57(8): 1091-1095. doi: 10.18805/IJAR.B-4356.

Submitted: 05-11-2020 **Accepted:** 24-03-2021 **Online:** 14-04-2021

MATERIALS AND METHODS

The study was performed for a period of nine months from August, 2018 to April, 2019 in Department of Veterinary

Gynaecology and Obstetrics, College of Veterinary Science and Animal Husbandry, Nanaji Deshmukh Veterinary Science University Jabalpur and approved by Animal Ethics Committee of College. A total of 12 fertile, healthy adult stray male dogs were selected for the present study and randomly divided into two groups consisting six animals in each. The animals of group-I were administered bilateral intra-testicular 1.0 ml of 20% w/v calcium chloride solution in normal saline while in group-II, 1.0 ml of normal saline was injected intra-testicular as placebo. Clinical signs following treatment, if any, were recorded.

For the assessment of effects of calcium chloride, testicular morphology and scrotal circumference were measured in both the groups on day 0, 7, 15 and 30. Measurement of testicular length, width, thickness and scrotal circumference were taken by vernier callipers and testicular volume was calculated by the following formula.

$$\text{Paired volume of testes } (cm^3) = 0.0396(\text{avg. TL})\ (SC)^2$$

Where,
TL= Testicular length.
SC= Scrotal circumference.

Histo-morphological studies were also conducted on the testicular biopsy samples obtained from each dog on day 0 and 30 using 18 G biopsy gun. Serum testosterone was measured on day 0, 15 and 30 using commercial sandwich ELISA kit.

The quantitative data were analyzed by two way ANOVA for testicular morphometry and scrotal circumference and one way ANOVA for testosterone concentration to compare the mean values between the days and within the group using SAS 9.4 and SPSS 24 software.

RESULTS AND DISCUSSION

Testicular morphometry

In this study, the mean values of all the parameters of testicular morphometry were found to be increased significantly on day 7 as compared to day 0, *i.e.* start of treatment and then decreased gradually and significantly in group I on day 15 and 30 post-treatment, but no such changes were noted in group II (Table 1). Literature is scant regarding effect of intra-testicular injection of 20% calcium chloride in normal saline on testicular morphometry. However, few reports are published where calcium chloride was used for chemical sterilization in animals using different concentration for different study periods (Ahmed, 2015; Chatterjee *et al.,* 2009; Jana and Samanta, 2007).

The results of decreased testicular volume after intra-testicular injection of calcium chloride in dogs indicated degenerative effect of this chemical in testicles. Silva *et al.* (2017) also reported reduction in testicular volume using 7.5% calcium chloride in 0.5% DMSO during 60 days of study in dogs. However, Pereira *et al*. (2018) reported no change in testicular volume after intra testicular injection of 20% and 40% calcium chloride solution. Leoci *et al.* (2014) reported decrease in testicular width upto 50% for a period of 12 months in dogs. However, it was only 23-25% in this study which was due to comparatively short period of observation, *i.e.,* upto 30 days only.

In present study, no significant side effects were observed in any of the treatment groups, except temporary local testicular inflammation due to injection and biopsy which disappeared within a week. Discomfort to dogs was found to disappear within 3 days. General symptomatic treatment along with intra-testicular injection can overcome this problem. It was also reported that single bilateral injection of calcium chloride solution resulted in necrosis along with concomitant production of reactive oxygen species at testicular level without imposing testicular pain, general stress response, metabolic toxicity or any toxic and untoward side effects (Jana *et al.,* 2002; 2005; Jana and Samanta, 2006).

Testicular atrophy found in the present study was also responsible for change in testicular volume and it supported the findings of Canpolat *et al.* (2006) in bull, Jana and Samanta (2006) in rats, Chatterjee *et al.* (2009) in stray dogs and Ahmed (2015) in dogs. The probable mechanism of action of intra-testicular injection of calcium chloride solution is stated to be higher extracellular calcium that leads to higher level of intracellular calcium which activates calcium dependent protease chaplain and initiates necrosis and thus leads to atrophy of testicles (McGinnins *et al*., 1999; Jana and Samanta, 2007).

Histo-morphological changes

The histo-morphological changes in testicles of all dogs of both the groups were studied at day 0 (pre injection) and day 30 (post injection). At day 0 there was normal histo-morphological pattern with intact germinal epithelium and distinct interstitial spaces. The Leydig cells were demarcated with no cellular changes (Plate 1 and 2 shows day 0 image of group I and Plate 3 and 4 shows day 0 image of group II).

However, at day 30 of treatment in group I, the microscopic sections showed significant morphological changes including complete derangement of seminiferous tubules. Out of six animals the testes of four animals represented complete destruction of outline of seminiferous tubules. The germinal epithelium and Leydig cells were degenerated and parenchyma was replaced by fibro-collagenous tissue which was evident by the presence of numerous fibrocytes and fibroblast cells. There was no evidence of mature germ cells in section of both the testes. In some areas small blood capillaries were observed which may indicate neo-vascularization. Discrete inflammatory infiltration of leucocytes was also observed in the parenchyma. In one case, the testicular section showed comparatively less fibrosis with vacuolation in some areas and complete derangement of seminiferous tubule (Plate 5 and 6).

In the present study germinal epithelium were completely degenerated, the chances of regeneration of epithelium were negligible. Secondly, there was extensive

Table 1: Testicular morphometry before and after treatment in dogs.

Testicular parameters	Group	Testicle	Day 0	Day 7	Day 15	Day 30	Reduction of testicular size on day 30 (%)
Length (mm)	I	Left	36.76^{b}±1.25	41.95^{a}±1.48	36.50^{b}±1.33	28.95^{c}±2.95	21.55±7.27
		Right	36.75^{b}±1.61	41.68^{a}±1.55	35.66^{b}±2.11	28.48^{c}±2.36	22.54±6.86
	II	Left	36.40±0.69	37.30±0.64	36.47±0.72	36.13±0.70	0.91±0.24
		Right	37.07±0.89	37.76±0.94	37.23±0.96	36.86±0.89	0.55±0.21
Width (mm)	I	Left	25.78^{b}±1.00	30.20^{a}±1.14	25.16^{b}±0.86	19.88^{c}±2.02	23.72±6.99
		Right	25.67^{a}±0.83	25.77^{a}±1.00	25.21^{a}±1.20	19.89^{b}±2.28	25.33±7.90
	II	Left	28.24±0.75	28.86±0.74	28.23±0.73	27.76±0.84	1.70±0.46
		Right	26.41±0.52	26.85±0.54	26.41±0.63	26.01±0.67	0.90±0.22
Thickness (mm)	I	Left	22.63^{b}±1.70	27.25^{a}±1.55	23.98^{ab}±1.29	18.31^{c}±2.12	22.76±5.76
		Right	23.44^{b}±1.19	28.44^{a}±1.67	23.77^{b}±0.99	17.25^{c}±1.81	25.86±7.53
	II	Left	23.93±0.90	24.51±0.91	23.96±0.95	23.57±0.93	1.50±0.48
		Right	23.91±0.57	24.46±0.59	23.95±0.58	23.48±0.56	1.68±0.55
Scrotal Circumference (cm)	I		13.43^{b}±0.85	16.15^{a}±0.57	13.50^{b}±1.00	10.57^{c}±1.31	22.97±7.23
	II		14.01±0.41	14.23±0.45	14.28±0.49	13.89±0.46	3.25±0.56
Paired volume (cm^3)	I		26.97^{b}±3.77	43.40^{a}±3.07	27.10^{b}±4.99	14.27^{c}±4.45	47.38±13.63
	II		28.78±1.98	30.78±1.95	28.83±1.94	26.72±2.02	7.36±1.12

Mean values with different superscripts (a, b and c) in a row differ significantly ($p<0.05$).

Plate 1: Photomicrograph of testicle (group I) at day 0 showing normal structure of seminiferous tubules. H&E×100.

Plate 2: Photomicrograph of testicle (group I) at day 0 showing normal structure of seminiferous tubules and leydig cells (L). H&E×200.

Plate 3: Photomicrograph of testicle (group I) at day 30 showing fibrosis. H&E×200.

Plate 4: Photomicrograph of testicle (group I) at day 30 showing neovascularization (Nc) and fibrocytes (Fc). H&E×400.

Table 2: Mean serum testosterone before and after treatment in dogs.

Groups	Mean testosterone concentration (ng/ml)		
	Day 0	Day 15	Day 30
I	9.07^{Aa}±1.02	7.64^{Bab}±0.64	6.09^{Bb}±0.76
II	8.48^{A}±0.49	8.54^{A}±0.57	8.38^{A}±0.35

Mean values with different superscript (a,b) in a row and (A,B) in a column differ significantly ($p<0.05$).

fibrosis in the parenchyma which was evident by presence of numerous fibroblasts and fibrocytes. This is in accordance with the findings of Jana and Samanta (2007), Leoci *et al.* (2014), Puri *et al.* (2018) and Silva *et al.* (2018) in dogs. Similar finding was also reported by Jana *et al.* (2005) in male goat, Jana *et al.* (2006) in albino rat, Canpolat *et al.* (2006) in bull, Jana and Samanta (2011) in tom cat and Pereira *et al.* (2018) in bull after chemical castration by calcium chloride. It can be concluded that chemical sterilization with calcium chloride in normal saline showed complete derangement of seminiferous tubules in animals of group I. Similar findings were also reported by Jana *et al.* (2002) in rats and Chatterjee *et al.* (2009) in dog by using intra-testicular injection of calcium chloride with the greatest effect at dose rate of 20 mg.

The occurrence of lesions may be due to oxidative damage caused by calcium chloride in the testicular tissue. This damage increased calcium influx into the cells, due to ion channels opening, destabilizing plasma membrane by lipid peroxidation. Calcium chloride is also responsible for promoting the disruption of cellular integrity leading to apoptosis. This functional correlation supports the presence of areas of vacuolation in the testicular sections of group I.

In animals of group II on day 30, the microscopic sections did not show any remarkable change in histo-morphology of testicular tissue parenchyma (Plate 7 and 8). This may be due to the fact that normal saline do not produce any inflammatory response in the testes.

Serum testosterone assay

In this study decrease in serum testosterone level at the end of study (day 30) in treatment group I indicated degeneration of Leydig cells of testicles along with other cells (Table 2). Similar results were also reported by Chatterjee *et al.* (2009) where significantly decreased serum concentration of testosterone was in graded manner at the doses of 100 mg, 150 mg and 200 mg in stray dogs. Leoci *et al.* (2014) reported same trend in dogs after using graded concentration of calcium chloride (10, 20, 30 and 60%) in saline solution. Ahmed (2015) also reported similar results in dogs treated with 20% calcium chloride or clove oil. However, Silva *et al.* (2018) reported no change in serum testosterone level after chemical sterilization of dogs using intra testicular 7.5% calcium chloride (15 mg/kg) combined with dimethyl sulphoxide.

Jana *et al.* (2002), Jana and Samanta (2006) and Das and Karmakar (2016) studied chemo-sterilization using intra-

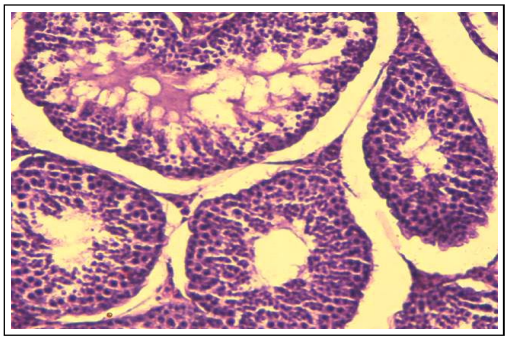

Plate 5: Photomicrograph of testicle (group II) at day 0 showing normal histological structure. H&E×100.

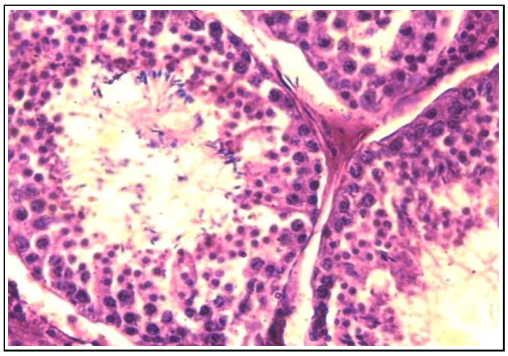

Plate 6: Photomicrograph of testicle (group II) at day 0 showing normal arrangement of spermatocytes. H&E×200.

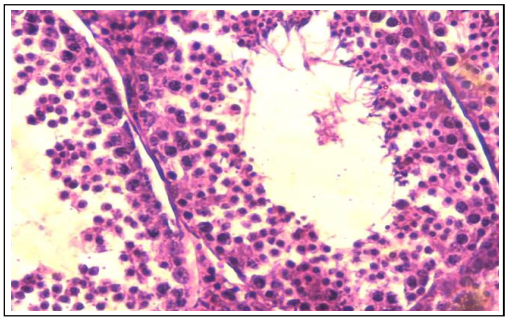

Plate 7: Photomicrograph of testicle (group II) at day 30 showing intact seminiferous tubule with normal pattern of spermatocytes. H&E×200.

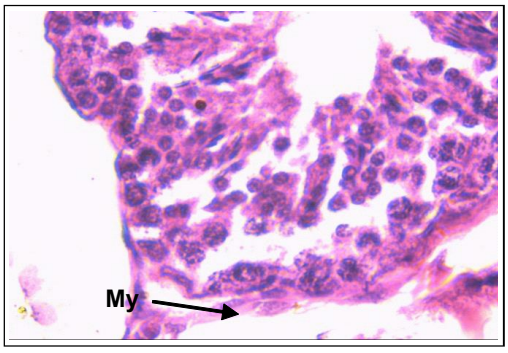

Plate 8: Photomicrograph of testicle (group II) at day 30 showing normal structure of seminiferous tubule and myoid cell (My). H&E×400.

testicular calcium chloride in different doses in adult albino rats and found significant decrease in the plasma testosterone concentration. Jana *et al.* (2005) reported same results in male goats by intra-testicular injection of calcium chloride solution at the doses of 10, 20 or 40 mg/kg body weight in 2.0 ml normal saline. Canpolat *et al.* (2006) also reported fall in testosterone concentration in bulls after injection of 10.0 ml absolute ethanol or 10.0 ml of a 30% calcium chloride solution. However, Jana and Samanta (2011) in male cats reported 70% reduction in testosterone concentration after 60 days of 20% calcium chloride administration. The decrease in the testosterone concentration can be attributed to the mass destruction of the testicular tissue especially Leydig cells which are responsible of secretion of the testosterone as reported by Das and Karmakar (2016).

CONCLUSION

It can be concluded that bilateral 1.0 ml intra-testicular injection of 20% calcium chloride in saline causes testicular degeneration along with decrease in a serum testosterone on day 30 post-treatment indicating its efficacy for chemical castration in male dogs.

ACKNOWLEDGEMENT

The authors are extremely grateful to the authorities of College of Veterinary Sciences and Animal Husbandry NDVSU, Jabalpur for their support and MPCST Bhopal for providing financial assistant to conduct the research work.

REFERENCES

Ahmed, H.M.A. (2015). Chemical sterilization of dogs using single bilateral intra-testicular injection of calcium chloride or clove oil. Alexandria Journal of Veterinary Sciences. 45: 26-32.

Canpolat, I., Gur, S., Gunay, C., Bulut, S. and Eroksuz, H. (2006). An evaluation of the outcome of bull castration by intra testicular injection of ethanol and calcium chloride. Revue De Medecine Veterinaire. 157: 420-425.

Chatterjee, K., Ali, K.M., Malick, C. and Ghosh, D. (2009). Induction of chemosterlization by single intra testicular calcium chloride injection in stray dogs. Research Journal of Animal and Veterinary Sciences. 4: 22-29.

Das, S.K. and Karmakar, S.N. (2016). Potential effect of calcium chloride as chemical castrative agent on male albino rat. International Journal of Applied Biology and Pharmaceutical Technology. 7: 114-120.

Ibrahim, A., Ali, M.M., Khalil, N.S.A. and Ali, M.F. (2016). Evaluation of chemical castration with calcium chloride versus surgical castration in donkeys: Testosterone as an endpoint marker. BMC Veterinary Research. 12: 46.

Jana, K. and Samanta, P.K. (2006). Evaluation of single intra-testicular injection of calcium chloride for nonsurgical sterilization in adult albino rats. Contraception. 73: 289-300.

Jana, K. and Samanta, P.K. (2007). Sterilization of male stray dogs with a single intra-testicular injection of calcium chloride: A dose dependent study. Contraception. 75: 390-400.

Jana, K. and Samanta, P.K. (2011). Clinical evaluation of non surgical sterilization of male cats with single intra testicular injection of calcium chloride. BMC Veterinary Research. 7: 39.

Jana, K., Samanta, P.K. and Ghosh, D. (2005). Evaluation of single intratesticular injection of calcium chloride for nonsurgical sterilization of male Black Bengal goats (*Capra hircus*): A dose dependent study. Animal Reproduction Science. 86: 89-108.

Jana, K., Samanta, P.K. and Ghosh, D. (2002). Dose dependent response to an intra testicular injection of calcium chloride for induction of chemo-sterilization in adult albino rats. Veterinary Research Communications. 26: 651-673.

Leoci, R., Aiudi, G., Silvestre, F., Lissner, E.A., Marino, F. and Lacalandra, G.M. (2014). A dose finding, long term study on the use of calcium chloride in saline solution as a method of non surgical sterilization in dogs: Evaluation of the most effective concentration with the lowest risk. Acta Veterinaria Scandinavica. 56: 63.

McGinnis, K.M., Wangi, K.K. and Genegy, M.E. (1999). Alteration of extra-cellular calcium elicits selective modes of cell death and protease activation in SH-SY5Y human neuroblastoma cells. Journal of Neurochemistry. 72: 1853-1863.

Menezes, R. (2008). Rabies in India. Canadian Medical Association Journal. 178: 564-566.

Pereira, L.F., Dias, F.G.G., Miguel, M.P., Honsho, C.S., Tavares, D.C., Hellu, J.A.A. and Souza F.F. (2018). Testicular histological evaluation and serum testosterone concentreation of bull after chemical castration with calcium chloride. Livestock Diseases. 38: 1554-1563.

Puri, B., Shah, M. K., Thakur, B., Regmi, B. and Dhakal, I. (2018). Intra testicular injection of calcium chloride is a useful alternative for neutering the male dog. International Journal of Applied Sciences and Biotechnology. 6: 158-163.

Silva, R.C.A., Paranzini, C.S., Franco, I.G, Miguel, M.P., Honosho, C.S. and Souza, F.F. (2018). Calcium chloride combination with dimethyl sulphoxide for the chemical sterilization of dogs. Reproduction of Domestic Animals. 1: 1-9.

Snedecor, G.W. and Cochran, W.G. (1994). Statistical Methods, 8th Edn., Oxford and IBH Publishing Co., Bombay, India, 593p.

Soto, F., Viana, W., Sousa, A., Pinheiro, S., Mucciolo, G. and Hosomi, F. (2007). Evaluation of zinc gluconate, either associated or not to dimethyl sulfoxide, as contraceptive method for male dogs. Journal of Animal Reproduction. 4: 119-124.