RESEARCH ARTICLE Indian Journal of Animal Research, Volume 57 Issue 8: 1096-1100 (August 2023)

Evaluation of Diagnostic, Prognostic Indicators and Surgical Outcome in 20 Cases Treated for Equine Intestinal Colic

J.S. Khosa[1], Arun Anand[1], V. Sangwan[1], S.K. Mahajan[1], J. Mohindroo[1], S.S. Singh[1]

10.18805/IJAR.B-4359

ABSTRACT

Background: Colic is one of the most common and challenging problem encountered by equine practitioners. In practise majority of horses suffering from colic can be treated with medical management but around 10% of horses with colic require surgical intervention in an effort to save the life of animal. In India, equine abdominal surgery is not popular because there is lack of infrastructure, manpower and expertise therefore, there is a need to conduct clinical studies to document outcome of equine colic cases managed surgically. The present report describes diagnostic, prognostic indicators and post-operative outcome of exploratory celiotomy performed to manage various cases of colic surgical outcome of colic surgery in Indian horse breeds.

Methods: The present study was conducted on 20 horses having intestinal colic (n=20). The affected patients were selected for exploratory celiotomy on an emergency basis having moderate to severe persistent abdominal pain, lack of response to medicinal treatment with absence of intestinal borborygmi. Preoperative physical assessment, biochemical analysis and peritoneal fluid analysis were done in all the clinical cases. The preoperative physical assessment and various blood parameter estimation helped in decision making.

Conclusion: The result of intestinal colic cases showed that mean heart rate and respiration rate (mean±SE) were significantly higher in non-survivors as compared to survivors. Blood lactate level was significantly higher in non survivors than survivors. Large colon affectation (n=8) were the primary cause of the colic, followed by small colon (n=6), cecum (n=3) and small intestine (n=3). Postoperative complications were peritonitis and ileus (n=6), subcutaneous seroma (n=7), pyrexia (n=4), diarrhoea (n=6). Short term survivability in intestinal colic patients was 55% and long term survivability was 50%.

Key words: Celiotomy, Colic, Equine, Postoperative complications, Survivability.

INTRODUCTION

Colic is one of the most prevalent and challenging disease condition faced by equine veterinarians and is a common reason requiring emergency surgery. The decision is best based on diagnosis, however, a specific diagnosis is not always possible and use of clinical signs is often necessary to make the decision (Braun *et al.,* 2002). Abdominal exploratory surgery is a diagnostic as well as a therapeutic procedure for colic. However, a thorough examination must be performed prior to deciding a horse for surgery since each clinical sign by itself has inherent error when used alone to finalize the decision. There are circumstances when the diagnosis cannot be made and there are no definitive rectal examination findings to help in making the decision. However, unrelenting pain, which does not respond to analgesics, or recurring pain after analgesic administration are indications for surgery if no diagnosis has been made (Singer and Smith, 2002). In India, equine abdominal surgery is not popular because of lack of infrastructure, manpower and expertise therefore, there is a need to conduct clinical studies to document surgical outcome of equine suffering from colic. The present report describes diagnostic, prognostic indicators and post-operative outcome of exploratory celiotomy to manage various cause of colic surgical outcome of colic surgery in Indian horse breeds.

MATERIALS AND METHODS

This study was performed at Department of Veterinary Surgery and Radiology, Guru Angad Dev Veterinary and Animal Sciences University, Ludhiana from 2015-2018. Twenty horses with moderate to severe persistent abdominal pain and abdominal distension, abnormal physical examination and lack of response to medical treatment, absence of intestinal borborygmi and abnormal per rectal findings were selected for exploratory celiotomy.

The horses were premedicated with xylazine (1.1 mg/kg b.wt, i.v.) and the anaesthesia was induced after 10 min with ketamine (2.2 mg/kg b.wt, i.v.). Endotracheal intubation was done and anaesthesia was maintained with isoflurane (2%) in partial rebreathing system. The horses were

[1]Department of Veterinary Surgery and Radiology, College of Veterinary Sciences, Guru Angad Dev Veterinary and Animal Sciences University, Ludhiana-141 001, Punjab, India.

Corresponding Author: J.S. Khosa, Department of Veterinary Surgery and Radiology, College of Veterinary Sciences, Guru Angad Dev Veterinary and Animal Sciences University, Ludhiana-141 001, Punjab, India. Email: jasmeetkhosa@gmail.com

How to cite this article: Khosa, J.S. Anand, A., Sangwan, V., Mahajan, S.K., Mohindroo, J. and Singh, S.S. (2023). Evaluation of Diagnostic, Prognostic Indicators and Surgical Outcome in 20 Cases Treated for Equine Intestinal Colic. Indian Journal of Animal Research. 57(8): 1096-1100. doi: 10.18805/IJAR.B-4359.

Submitted: 06-11-2020 **Accepted:** 06-02-2021 **Online:** 08-03-2021

positioned in dorsal recumbency and a wide ventral midline area was prepared for aseptic surgery. The surgical site was properly scrubbed and draped and about 25-30-cm midline celiotomy incision was made between the umbilicus and xiphoid to explore the abdominal cavity. Once the abdomen was opened a systematic exploration was done in order to identify the nature of the colic problem and to take the necessary corrective action. It was followed by the replacement of the intestines in normal anatomic orientation. The abdominal cavity was lavaged and the abdomen closed routinely. Postoperatively, fluid therapy was accompanied along with antibiotics and the analgesics. Flunixin megulumine (Virbac Animal Health India Pvt Ltd) was administrated (1.1 mg/kg b.wt, i.v., b.i.d.) for four days postoperatively. Antimicrobial therapy consisted of a combination of piperacillin tazobactum (Abbott Healthcare Pvt Ltd- 50 mg/kg b.wt, i.v., b.i.d.), amikacin (Ranbaxy Lab. Ltd- 10 mg/kg b.wt, i.v., OD) and metronidazole (Pfizer Animal Health Ltd.- 10 mg/kg b.wt, i.v., b.i.d.) for 10 postoperative days. Blood collected in EDTA vials was used immediately to determine haemoglobin (g %), packed cell volume (PCV%), total leukocytes count (TLC) by ADVIA Haematology System (Siemens). Blood smears were prepared and were evaluated for differential leukocytes count (DLC) after staining the slides with Wright's stain. Blood samples were collected to compare blood parameters of survivors and non-survivors. Serum biochemistry was done for aspartate aminotransferase (AST), alkaline phosphatase (ALKP), Gamma-Glutamyl Transferase (GGT), Lactate, blood urea nitrogen (BUN), Creatinine and Total serum proteins, Sodium, Potassium and Chloride using VITROS DT-II Chemistry System (Ortho-Clinical Diagnostics, Johnson and Johnson).

Statistical analysis

Results are expressed as mean±S.E.M with 'equal to the number of replicates'. The statistical significance between survived and not-survived group was analysed by applying 'T'test using Graphpad Prism V.6. Software program (San Dieago, CA, USA).

RESULTS AND DISCUSSION

The present study comprised of 20 colic cases out of which 14 (70%) were females and 6 (30%) were male. Females were over represented for colic in present study. Most of the animals presented with colic were in the age group range of 15 days to 15 years. Out of total 20 cases included in study, 5 (25%) were below 2 years of age and 3 (15%) were above 10 years of age. Rest 12 (70%) of the colic cases were between 2 to 10 years of age. History revealed that 15/20 (75%) horses were fed on wheat straw while 9/20 (45%) horses were daily fed grain more than 2 kg. Course roughage with low digestibility or particularly course fibre is associated with impaction colic (White and Dabareiner, 1997). Only 8/20 (40%) animals were having history of regular deworming. As per previous studies the risk for colic reported is 2.2 times higher in horses which do not receive any regular deworming treatment Cohen *et al.* (1999). Previous history of colic was recorded in 5/20 (25%) horses of present study. Cohen *et al.* (1995) observed that a horse is more likely to develop colic if it has previously suffered from colic. The duration of colic ranged from 6 hours to 120 hours mean±SE (74.60±7.23). Colic was found to be severe in cases with small intestine strangulation and large colon obstruction whereas it was mild to moderate in cecum and small colon impactions. Southwood (2013) noted that duration of colic is vital for determining a diagnostic and selection of cases for medicinal or surgical treatment. The water consumption was found to be markedly decreased. Loss of defecation was found in six horses with fecoliths in small and large colon. Further three horses with large colon impaction had decreased fecal output with or without having mucous in rectum. Urination frequency had markedly decreased in all the presented cases.

The most common clinical signs observed were abdominal pain and abdominal distension. Out of the 20 horses, 60% (n=12) had moderate abdominal pain and 40% (n=8) had severe pain. The presence of abdominal distension was recorded in 80% horses (n=16). Severe abdominal distension was observed in all cases having small colon impaction, Mild to moderate distensions was observed in all cases of cecum and large colon impactions whereas abdominal distension was absent in small intestine cases. Abdominal pain and distension are the characteristics of horses in which abdominal surgery is recommended (Dabareiner and White, 1995).

The results showed that mean heart rate and respiration rate (mean±SE) were significantly higher in non-survivors in comparison to survivors (Table 1). Similar findings were observed by Suthers *et al.* (2013).

Table 1: Mean±SE values of temperature (*f), heart rate (per min) and respiratory rate (per min) in survived and non-survived animals.

	Temperature	Heart rate (per min)	Respiratory rate (per min)
Survived	100.9±0.59	69.5^{a}±3.30	23.83^{b}±7.16
Non-survived	101.2±0.31	84.5^{b}±4.96	34.88^{b}±7.80

Mean values within different superscripts differ significantly ($p<0.05$) between groups.

Table 2: Haematological parameters (mean±standard error) in survivor and non-survivor horses.

Variables	Survivors (n=11)	Non survivors (n=9)
Haemoglobin (g%)	11.52±0.40	12.51±0.56
TLC (cumm)	10596±929.50	8747±1140.9
PCV (%)	41.18±1.16	44.54±1.59
Neutrophil (%)	68.55±1.93	70.22±2.52
Lymphocyte (%)	31.45±2.8	29.78±2.52

Values did not differ significantly between groups.

Gastrointestinal tract was evaluated in all four quadrants for borborygami. Normal hypomotile and hypermotile intestinal movements were noted pre and post-operatively. In the present study it was found that survivors had normal or hypomotile intestinal borborygami while non-survivors had hypomotile or amotile intestines. If borborygmi do not return after an analgesic or other treatment, the disease should be considered more serious, possibly requiring surgery. (Reeves *et al.,* 1991; White *et al.,* 2005).

Table 3: Biochemical parameters (mean±standard error) in survivor and non-survivor horses.

Variables	Survivors (n=11)	Non Survivors (n=9)
AST (U/L)	427.55±37.12	487.56±41.36
ALKP (U/L)	215.73±20.9	250±21.92
Total protein (g/dL)	6.2±0.20	5.7±0.195
GGT (U/L)	29.36±1.97	35.00±4.32
BUN (mg/dL)	26.09±2.86	31.00±2.59
Creatinine (mg/dL)	1.92±0.220	2.52±0.405
Lactate (mmol/L)	3.6±0.20[a]	7.122±1.032[b]
Sodium (mEq/L)	111.09±1.73	116.8±4.29
Potassium (mEq/L)	3.064±0.144	4.067±0.526
Chloride (mEq/L)	81.56.±3.40	79.27±2.43

Value with different superscripts differ significantly between groups (P<0.05).

Nasogastric intubation was performed in 15 equines and only 2 cases had positive nasogastric reflux (8 and 9 litres respectively). According to Southwood (2013) findings positive nasogastric reflux is considered only when the volume is more than 6 litres.

In the present study, serum lactate level (Table 2 to 4) (mean±SE) was found to be significantly (P=0.007) increased among non-survived (7.122±1.032) in comparison to survived (3.6±0.20) horses. Blood and peritoneal fluid Lactate were accurate indicators of the tissue perfusion which is an estimate of the cardiovascular status of the horse (Dunkel *et al,* 2013).

Large colon affectation (n=8) were the primary cause of the colic, followed by small colon (n=6), cecum (n=3) and small intestine (n=3) (Fig 1). Short-term survivability was 55 per cent as (11/20) of the animal discharged from the hospital while long term survival was 50 per cent (10/20) which was 90.9 per cent (10/11) of the short term survived animals. Similar short term survival (54.5%) was also reported by Wormstand *et al.* (2014). In the present study affections of the small and large colon had better survival rate in comparison to small intestine or cecum as also observed by Morton and Blikslager (2002).

Post-operative complications

In the present study, incisional complications commonly seen were oedema, drainage and infection, while incisional

Table 4: Survivability of colic affected equines with different parts of gastrointestinal involvements.

No. of cases	Part of GI involved	Type of affection	Short term survival rate (%)
	Small intestine (n=3)	Strangulation (n=2)	0
		Intussusception (n=1)	0
	Caecum (n=3)	Strangulation (n=1)	0
		Impaction (n=2)	50
N=20	Large colon (n=8)	Transverse colon (n=4) impaction	75
		Pelvic flexure (n=3) Impaction/foreign body	66.6
		Right dorsal displacement (n=1)	100
	Small colon (n=6)	Fecolith/impaction (n=5)	60
		Foreign body (n=1)	100
	Overall survival rate		55



A. B.

Fig 1: Continue...

Fig 1: Continue...

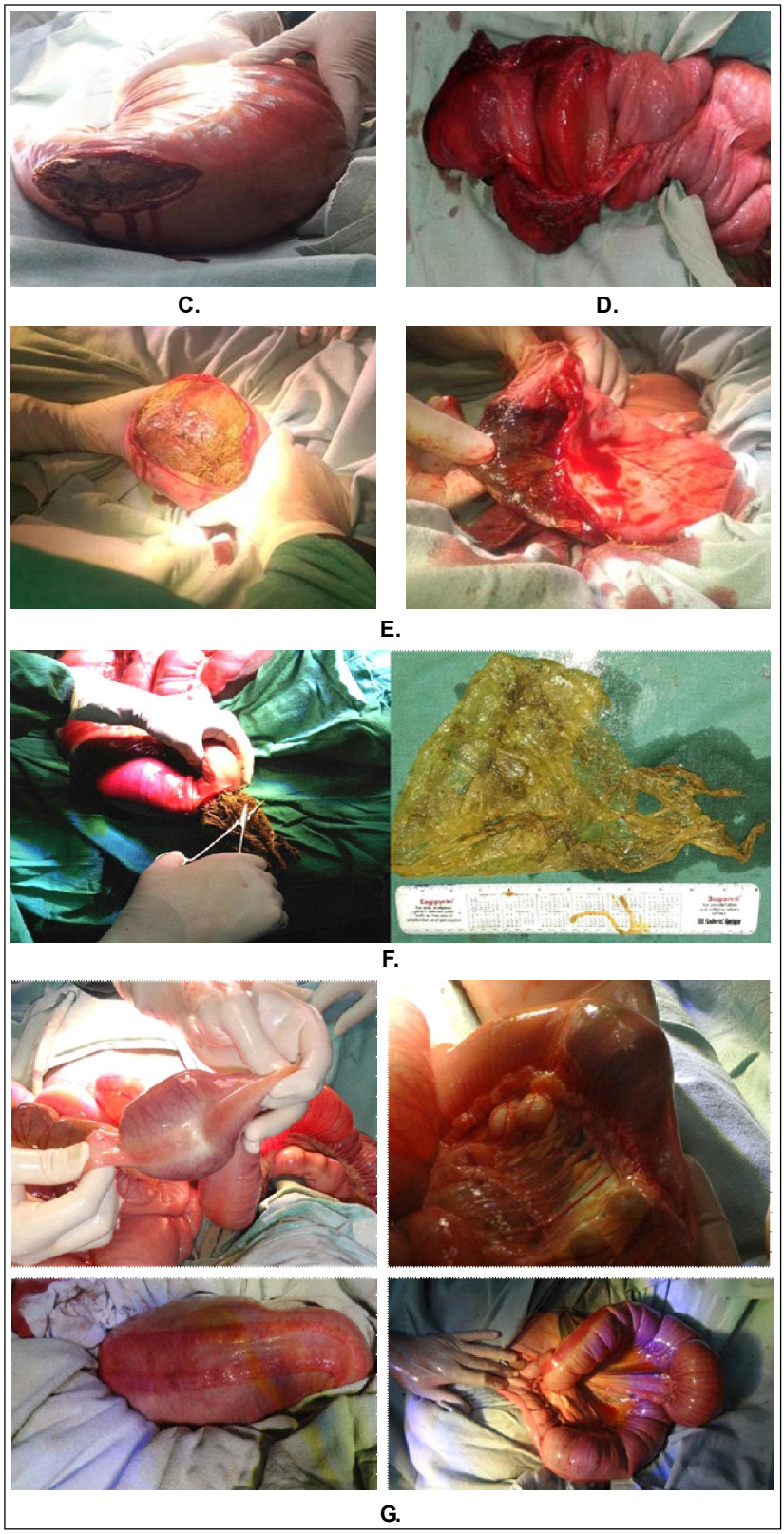

Fig 1: Intra operative photograph showing A) Intususception in foal B) Strangulation of small intestine due to volvulus C) Impacted cecum D) Strangulation and congestion of the cecum: E) Fecolith obstruction of the pelvic flexure and several haemorrhage at site of fecolith Intra-operative photograph showing F) Foreign body obstruction of pelvic flexure G) Fecolith obstruction of small colon, observe distended small colon cranial to fecolith and collapsed small colon caudal to fecolith.

herniation was observed in one equine (5%). Most common incisional complication encountered in this study was oedematous swelling around the incision line found in the 7/11 survived horses. Post-operative pyrexia was seen in 20% cases of cecum strangulation (n=1), small colon impaction (n=3). Equine with cecum strangulation had maximum extent of pyrexia (105°F), which was non-responsive to antipyretics.

Post-operative laminitis was seen in equine with cecum strangulation and in a one animal suffering with small colon impaction. In all it was seen in about 10 per cent (2/10) of the cases. Post-operative diarrhoea was seen in all small and large colon with fecolith obstruction removed by surgery, as also reported by (Salem *et al*., 2016).

Thrombophlebitis was seen in 20 per cent (4/20) of the cases. Post-operative peritonitis and postoperative ileus were major life threatening complications encountered in 40% (8/20) horses of this study. Recurrent mild colic was found in five out of eleven long-term survived horses. Mild colic was seen in horses with change of feed and responded satisfactorily to analgesic (Flunixin meglumine@ 1.1 mg/kg IV) and was seen up to 2 months after surgery. Changes in feeding schedule and regular exercise helped in management of the colic.

Conclusion

In conclusion, perioperative mean heart rate less than 70 bpm, respiration rate less than 23/min, total leukocyte count more than 7500 and blood lactate level 3.6 mmol/l are reliable indicators for favourable surgical outcome. Small colon, transverse colon and pelvic flexure are major sites for obstructive colic in horse.

Acknowledgement

The authors would like to acknowledge the Indian Council of Agriculture Research for funding the research under the scheme, “Diagnosis and management of surgical conditions in animals”.

References

Braun, U., Schoberl, M., Bracher, V., Geyer, H. and Feige, K. (2002). Prognostic factors in equine colic. Tierarztliche Umschau. 57(1): 15-22.

Cohen, N., Gibbs, P. and Woods, A. (1999). Dietary and other management factors associated with equine colic. Journal of American Veterinary Medical Association. 45: 96-98.

Cohen, N.D., Matejka P.L., Honnas, C.M. and Hooper, RN. (1995). Case-control study of the association between various management factors and development of colic in horses. Journal of American Veterinary Medical Association. 206: 667-673.

Dabareiner, R.M. and White, N.A. (1995). Large colon impaction in horses: 147 cases (1985-1991). Journal of the American Veterinary Medical Association. 206(5): 679-685.

Dunkel, B., Kapff, J.E., Naylor, R.J. and Boston, R. (2013). Blood lactate concentrations in ponies and miniature horses with gastrointestinal disease. Equine Veterinary Journal. 45(6): 666-670.

Morton, A.J. and Blikslager, A.T. (2002). Surgical and postoperative factors influencing short term survival of horses following small intestinal resection: 92 cases (1994-2001). Equine Veterinary Journal. 34(5): 450-454.

Reeves, M.J., Curtis, C.R., Salman, M.D., Stashak, T.S. and Reif, J.S. (1991). Multivariable prediction model for the need for surgery in horses with colic. American Journal of Veterinary Research. 52(11): 1903-1907.

Salem, S.E., Proudman, C.J. and Archer, D.C. (2016). Prevention of post-operative complications following surgical treatment of equine colic: Current evidence. Equine Veterinary Journal. 48(2): 143-151.

Singer, E.R. and Smith, M.A. (2002). Examination of the horse with colic: Is it medical or surgical. Equine Veterinary Education. 14(2): 87-96.

Suthers, J.M., Pinchbeck, G.L., Proudman, C.J. and Archer, D.C. (2013). Survival of horses following strangulating large colon volvulus. Equine Veterinary Journal. 5(2): 219-223.

Southwood, L.L. (2013). Practical Guide to Equine Colic. Wiley-Blackwell Publishers.

White, N.A. and Dabareiner, R.M. (1997). Treatment of impaction colics. Veterinary Cliniancs North America-Equine Practise. 13(2): 243-259.

White, N.A., Elward, A., Moga, K.S., Ward, D.L. and Sampson, D.M. (2005). Use of web-based data collection to evaluate analgesic administration and the decision for surgery in horses with colic. Equine Veterinary Journal. 37(4): 347-350.

Wormstrand, B.H., Ihler, C.F., Diesen, R. and Krontveit, R.I. (2014). Surgical treatment of equine colic - A retrospective study of 297 surgeries in Norway 2005-2011. Acta Veterinaria Scandinavica. 56(1): 38. DOI: 10.1186/1751-0147-56-38.