RESEARCH ARTICLE Indian Journal of Animal Research, Volume 57 Issue 8: 970-974 (August 2023)

Ocular Ultrasonography and Echobiometry in Goats of Different Age and Breed

H. Athar[1], J.D. Parrah[1], A.Q. Mir[1], B.A. Moulvi[1], D.M. Makhdoomi[1], M.U. Dar[1], N. Handoo[1] 10.18805/IJAR.B-4360

ABSTRACT

Background: Bhakarwali, a recognized goat breed of India is native to region of Jammu and Kashmir, plays a significant role in sustaining the livelihood of small and marginal farmers especially the nomadic tribes of Gujjars and Bhakarwals. Keeping in view, its importance to the farming community, high number of cases handled and lack of literature available in the country regarding baseline echobiometric values of eye in goats in general, the present study was undertaken.

Methods: Ocular sonography and echobiometry was performed in Bhakarwali (n=60) and Non-descript goats (n=32) and normal echobiometric values for eye structures in different age groups were established.

Result: There was significant (P>0.05) increase in the different ocular echobiometric measurements as the animal aged. Further, echobiometric values were non-significantly higher in Bhakarwali goats than local non-descript breed in all the age groups.

Key words: Bhakarwali goat, Non-descript goat, Ocular sonography.

INTRODUCTION

Bhakarwali is one of the well-recognized goat breeds of India. It is native to the region of Jammu and Kashmir and is named after nomadic tribes of the valley. These animals are highly adaptable to temperate climatic conditions of the valley and show excellent nutritional efficiency, attaining an appreciable body weight under a low input production system (Ahad *et al.,* 2016). It has played a significant role in sustaining the livelihood of these nomadic tribes as well as in shaping the economic and social development of the large number of small and marginal farmers of Jammu and Kashmir (Ganai *et al.,* 2016).

Ocular diseases produce a lot of discomfort to the farm animals owing to pain and also due to impairment of vision which leads to decreased performance and even culling of animals. It causes economic losses to the farmers and indirectly to the society and the losses due to the various ocular diseases in food producing animals is well documented (Reichmann, 2008; Slater, 1990; Waklridge and Colitz, 2002; Whittaker *et al.,* 1999). The ocular diseases are difficult to diagnose with the naked eyes particularly in the initial stages of the disease and need elaborate diagnostic facilities (Athar *et al.,* 2018; Tamilmahan *et al.,* 2013).

Ocular sonography is a very helpful in diagnosis of various eye conditions where the conventional techniques have limited use. Conditions like lid problems due to severe edema, partial or total tarsorrhaphy, keratoprosthesis, corneal opacities, scars, or vitreous opacities resulting from hemorrhage and inflammatory debris are easily diagnosed by ocular sonography (Hughes, 1972). It is also useful in evaluating the contents of the globe and orbit routinely in companion animal medicine (Qureshi and Laghari, 2010). Apart from ocular sonography ocular biometry is also a useful tool for the assessment of abnormalities such as phthisis bulbi, microphthalmia, pseudoexophthalmia, scleral ectasia and congenital glaucoma (Potter *et al.,* 2008).

Knowledge of the ultrasonographic appearance and normal dimensions (biometry) of the eye would serve as a basis for ultrasonographic examinations when ocular disease may have caused alterations in the dimensions and appearance (Singh *et al.,* 2015, 2016). However, knowledge of ophthalmic parameters in goats is limited and none is available for the Bhakarwali goat (Broadwater *et al.,* 2007; Galan *et al.,* 2006; Morales *et al.,* 2006; Ribeiro *et al.,* 2009, 2010).

For this reason, the current study was undertaken to establish the baseline parameters for biometry and the ultrasonographic aspects of the eyes of Bakarwal and its comparative analysis with the local non-descript crosses with particular focus on sonographic changes with age so that it will help in efficient diagnosis and prompt treatment.

[1]Faculty of Veterinary Sciences and Animal Husbandry, Sher-e-Kashmir University of Agricultural Sciences and Technology of Kashmir, Shuhama, Alusteng-190 006, Jammu and Kashmir, India.

Corresponding Author: H. Athar, Faculty of Veterinary Sciences and Animal Husbandry, Sher-e-Kashmir University of Agricultural Sciences and Technology of Kashmir, Shuhama, Alusteng-190 006, Jammu and Kashmir, India. Email: hakimathar@gmail.com

How to cite this article: Athar, H., Parrah, J.D., Mir, A.Q., Moulvi, B.A. Makhdoomi, D.M., Dar, M.U. and Handoo, N. (2023). Ocular Ultrasonography and Echobiometry in Goats of Different Age and Breed. Indian Journal of Animal Research. 57(8): 970-974. doi: 10.18805/IJAR.B-4360.

Submitted: 10-11-2020 **Accepted:** 22-03-2021 **Online:** 15-04-2021

MATERIALS AND METHODS

Animals

The animals involved in the study comprised sixty Bhakarwali and thirty two local non-descript goats subdivided into four equal groups of one, six, twelve and thirty six months of age. Bhakarwali goats screened were obtained from university farm (Mountain Research Centre for Sheep and Goat, Faculty of Veterinary Sciences and Animal Husbandry, Sher-e-Kashmir University of Agricultural Sciences and Technology of Kashmir, Shuhama) while, local non-descript group comprised of goats brought to university clinics, Shuhama for treatment of diseases affecting organs other than the eyes during the study period from 2015-2017.

Eye examination

All the animals were subjected to thorough ophthalmic examination and only those with normal eyes and vision formed part of the study. Transcorneal sonography was performed after instilling topical local anesthetic into eyes and application of ultrasound jelly using a 10-18 MHz linear transducer (My Lab 40 Vet).

RESULTS AND DISCUSSION

Ultrasonographic appearance of goat eye

Goat eyes in different age group appeared similar as well defined ovoid structures with mostly anechoic contents (Fig 1). A standoff pad is usually required to visualize the cornea (Hager *et al.,* 1987). Copious amount of ultrasound gel was used for ocular scanning during the study, which obviated the use of standoff pad. The cornea appeared as a double peaked echo *i.e*. two convex interfaces with a central narrow anechoic space as reported earlier (Hager *et al.,* 1987; El Maghraby *et al.,* 1995; MacKay and Mattoon, 2015). Additionally, El Maghraby *et al.* (1995) observed an area of hyper-reflectivity centrally within the corneal image with an echoic region posterior to it. No such observation was recorded in any of the normal eyes scanned during the study.

The anterior and posterior chambers of the aqueous chamber appeared as a single indistinguishable planoconvex anechoic space similar to earlier findings (El Maghraby *et al*., 1995; Potter *et al.,* 2008; Toni *et al*., 2010).

The iris and ciliary body appeared as moderately echoic linear shaped structure. The iris is considered difficult to be imaged but can be seen under ideal conditions in contact with the anterior lens capsule by use of a standoff and a high-frequency transducer (Dziezyc and Hager, 1988; LeMay, 1978; Smith *et al.,* 1986; Wilkie and Gilger, 1998). The iris was located immediately adjacent to the anterior lens capsule with the thicker, more irregular ciliary body lying peripheral (Whitcomb, 2002).

The lens appeared as two curvilinear echogenicities representing the anterior and posterior lens capsules. The internal appearance of the lens was anechoic. Similar observations were made earlier (Potter *et al*., 2008; Soroori *et al*., 2009).

The vitreous chamber was imaged as a homogenous, anechoic region between the posterior lens capsule and ciliary body anteriorly and retina posteriorly. The posterior ocular wall had the highest echogenicity. Retinal, choroidal or scleral layers were not individually identifiable on ultrasonography. Several parallel linear echogenicites seen within the retino-choroid-sclera complex were representing one or more of these layers, as recorded earlier (El Maghraby *et al*., 1995; Hager *et al*., 1987; Potter *et al*., 2008; Ribeiro *et al*., 2009; Soroori *et al*., 2009).

On ultrasonography, the retrobulbar region appeared as an area of moderate echogenicity due to the large amount of fat. The optic nerve could be scanned in only few animals. It appeared as a funnel-shaped hypoechoic-to-anechoic shadow posterior to the optic disc. The extraocular muscles looked as homogeneous, hypoechoic structures running tangentially to the back of the eye. Similar observations have been reported by Barr (1990); Simon (1996); Gonzalez *et al.,* (2001).

Ocular echobiometry in animals

Ocular biometry was one of the early uses of ultrasound in human ophthalmology (Coleman, 1979). The axial measurements of the globe are important in evaluating conditions such as glaucoma, micro-ophthalmia, macro-ophthalmia, phthisis bulbi or persistent hyperplastic primary vitreous (Gonzalez *et al*., 2001). In veterinary medicine, ocular biometry can be used in establishing lens implant size, calculating lens power and estimating prosthetic globe size after enucleation (MacKay and Mattoon, 2015). The echobiometric values obtained in different age group of Bhakarwali and local non-descript goats is summarized in Table 1.

Central corneal thickness (CCT)

For more accurate measurement of the IOP, CCT is an important factor that has to be taken into consideration and adjustments in the measured IOP are needed for the clinical management of glaucoma patients (Shih *et al*., 2004; Patwardhan *et al*., 2008). In present study, there was steady increase in the overall Mean±SE value of central corneal thickness till 12 months of age which incidentally also was the age at which the difference ($P<0.05$) became significant from the preceding values. Ribeiro *et al.* (2009) also reported increase in the value of CCT in 549 days old goats as compared to 45 day old goat. Higher corneal thickness was recorded in Bhakarwali goat than nondescript goats at all the ages but the significant difference between the two groups of goats was recorded only at the age of 6 months. The central corneal thickness (CCT) values of both the breeds of goats of the present study were higher as compared to CCT values of either Sannen (0.064±0.007 cm) or Iraqi goats (0.059±0.001 cm) at any stage of age (Ribeiro *et al.,* 2009; Al-Redah, 2016). A thick cornea provides falsely elevated intraocular pressure while as a thin cornea is associated with the falsely low intraocular pressure (Caster *et al*., 2007).

Table 1: Ocular ultrasonographic biometric measurements in Bhakerwal and cross bred goats at different age interval (Mean±SE).

Parameter (cm)	Breed	Age (month)			
		1	6	12	>36
Central corneal thickness	Bakerwal	0.083±0.003^{A}	0.092±0.0024^{aAB}	0.0967±0.003^{B}	0.10±0.006^{B}
	Nondescript	0.076±0.004^{A}	0.076±0.005^{bA}	0.090±0.004^{A}	0.09±0.003^{A}
	Mean	0.079±0.003^{A}	0.087±0.003^{AB}	0.092±0.002^{B}	0.092±0.002^{B}
Anterior chamber depth	Bakerwal	0.213±0.018^{A}	0.234±0.11^{AB}	0.26±0.026^{B}	0.27±0.023^{B}
	Nondescript	0.2±0.01^{A}	0.24±0.022^{AB}	0.26±0.01^{AB}	0.28±0.03^{B}
	Mean	0.20±0.009^{A}	0.24±0.010^{AB}	0.26±0.02^{B}	0.27±0.02^{B}
Anterio-posterior depth of lens	Bakerwal	0.64±0.025^{A}	0.7673±0.103^{B}	0.873±0.009^{C}	0.883±0.26^{C}
	Nondescript	0.68±0.031^{A}	0.77±0.035^{B}	0.93±0.01^{C}	0.92±0.014^{C}
	Mean	0.664±0.021^{A}	0.769±0.012 ^{B}	0.89±0.02^{C}	0.90±0.012^{C}
Latero-medial diameter of lens	Bakerwal	0.923±0.009^{A}	1.082±0.011^{B}	1.187±0.145^{C}	1.16±0.006^{aC}
	Nondescript	0.93±0.041^{A}	1.06±0.05^{AB}	1.19±0.00^{BC}	1.28±0.04^{bC}
	Mean	0.93±0.025^{A}	1.07±0.016^{B}	1.19±0.01^{C}	1.23±0.029^{C}
Vitreous chamber depth	Bakerwal	0.927±0.032^{A}	0.921±0.018^{aA}	1.03±0.0233^{B}	1.02±0.030^{B}
	Nondescript	0.89±0.026^{A}	1.00±0.033^{bB}	1.02±0.04^{B}	0.99±0.02^{B}
	Mean	0.91±0.02^{A}	0.94±0.02^{AB}	1.03±0.02 ^{BC}	1.0±0.0104 ^{C}
Axial length	Bakerwal	1.87±0.045^{A}	2.026±0.02^{B}	2.27±0.047^{C}	2.29±0.01^{C}
	Nondescript	1.83±0.064^{A}	2.13±0.09^{B}	2.25±0.15^{B}	2.30±0.032^{B}
	Mean	1.84±0.042^{A}	2.06±0.032^{B}	2.28±0.02^{C}	2.29±0.023^{C}
Retinal rim thickness	Bakerwal	0.183±0.009^{aA}	0.232±0.009^{aB}	0.25±0.00^{B}	0.223±0.14^{B}
	Nondescript	0.16±0.005^{bA}	0.16±0.01^{bA}	0.22±0.03^{B}	0.21±0.017^{B}
	Mean	0.17±0.006^{A}	0.21±0.011^{B}	0.23±0.01^{C}	0.22±0.01^{C}

Values with different small and capital superscript differ significantly at P<0.05 between breeds and age group respectively.

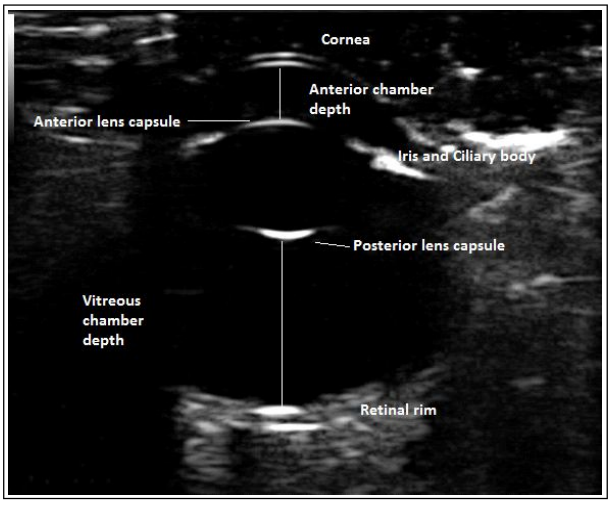

Fig 1: Ultrasonographic appearance of goat eye.

Anterior chamber depth

The overall Mean±SE value of anterior chamber depth increased with the advancement of the age. This increase was significant (P<0.05) in Bhakarwali and non-descript-goats at 12 months and at > 36 months of age, respectively. Comparison between the breeds did not reveal any significant difference at any age interval. Ribeiro *et al*. (2009) also reported that ACD values of the Sannen goats increased with the advancement of age. however, the ACD values in Sannen breed were higher than values obtained in the present study. ACD has been described as an important preoperative parameter in the anterior segment surgery (Feng *et al*., 2011).

Antero posterior depth of lens

The Mean±SE values (cm) of antero posterior depth of lens of goats showed increasing trend with the advancement of age, however, significant increase (P<0.05) in the overall antero-posterior depth of lens was observed from 6 month onwards as compared to value of one month. The increase in the values from 12 to 36 months of age was not significantly different. The APDL value of Bhakarwali group of goats was non-significantly lower than those of non-descript goat at every age level. Similar observations have been made by Ribeiro *et al*. (2009).

Latero-medial diameter of lens

Significant (P<0.05) increase in the latero-medial diameter of the lens was observed from 6 month onwards in the overall and in Bhakarwali groups of goats from the corresponding 1 month age values. Comparison within the groups revealed significant (P<0.05) difference in latero-medial diameter of the lens at 36 month of age. Significant increase in LMDL values were observed in non-descript goats form 12 months onward as compared to the corresponding 1 month value.

Vitreous chamber depth

Vitreous chamber depth (VCD) also increased with the age, but the increase was significant in Bhakarwali and

non-descript goats at 12 and 6 month of age, respectively. Similar increase in values was recorded by Ribeiro *et al.* (2009). The VCD values of Sannen goats at 549 days of age (1.203±0.83 cm; Ribeiro *et al.,* 2009) were higher than those of Bhakarwali (1.02±0.030 cm) as well as nondescript goats (0.99±0.02 cm) even at 36 month of age, recorded during the study. Comparison between the breeds revealed significant difference (P<0.05) only at 6 month of age.

Axial length

The axial length of globe (cm) was 1.87±0.045 and 1.83±0.064 at 1 month age in the goats of Bhakarwali and non-descript breeds respectively, which continuously and significantly (P<0.05) increased with the advancement of age in both the groups of goats. Comparison revealed no significant difference in the value of globe axial length at any stage of age between the breeds. In consonance with the earlier findings of Ribeiro *et al.* (2009) which recorded that globe increased with the advancement of age, thus substantiating the findings of our study. Again the axial globe length in Sannen goats (24.37±1.16) was higher (Ribeiro *et al*., 2009) than AGL of either Bhakarwali or non-descript goats of this study.

Retinal rim

The retinal rim thickness (cm) at 1 month of age was 0.183±0.009 and 0.16±0.005 in the goats of Bhakarwali and non-descript breeds respectively. The retinal rim thickness values started increasing significantly (P<0.05) at 6 and 12 months of age in Bhakarwali and non-descript goats, respectively. Comparison between the breeds revealed significant (P<0.05) difference in the values of retinal rim thickness at the corresponding 1 and 6 month of age.

CONCLUSION

In conclusion, this work establishes the baseline ecobiometric values of different eye structures in Bhakarwali and non-descript goats from Jammu and Kashmir. This study records no statistically significant difference in the measurement of various ocular structures between the Bhakarwali and non-descript breeds of goats of the valley. The present work will help the veterinarians in diagnosis of ocular diseases in goats.

ACKNOWLEDGEMENT

The authors acknowledge the Division of Veterinary Surgery and Radiology for providing the financial and basic facilities for research work. The authors also acknowledge the Mountain Research Centre for Sheep and Goat for providing the animals for the work and also, Division of Veterinary Clinical Complex for facilitating the research work.

Conflict of interest statement

None.

REFERENCES

Ahad, A.W., Sajad, A.B., Mehraj, M., Masroor, H., Hina, F.B., Riaz, A.S., Mudasir, A.S. (2016). Sequence characterization of coding regions of the myostatin gene (GDF8) from Bhakarwali goats (*Capra hircus*) and comparison with the sheep (*Ovis aries*) sequence. Open Journal of Animal Science. 6: 157-162.

Al-Redah, S.A.A. (2016). Ultrasonographic anatomy of the goat eye. Al-Qadisiya Journal of Veterinary Medical Science. 15(1): 160-164.

Athar, H., Parrah, J.D, Makhdoomi, D.M., Dar, S.H., Fazili, M.R., Dar, M.U. (2018). A retrospective study of eye affections in animals of Kashmir valley. Haryana Veterinarian. 57(2): 234-238.

Barr, F. (1990). Diagnostic Ultrasound in the Dog and Cat. Oxford: Blackwell Scientific Publications.

Broadwater, J.J., Schorling, J.J., Herring, I.P., Pickett, J.P. (2007). Ophthalmic examination findings in adult pygmy goats (*Capra hircus*). Veterinary Ophthalmology. 10(5): 269-273.

Caster, A.I., Friess, D.W., Potvin, R.J. (2007). Absence of keratectasia after LASIK in eyes with preoperative central corneal thickness of 450 to 500 microns. Journal of Refractive Surgery. 23(8): 782-788.

Coleman, D.J. (1979). Ultrasonic measurements of eye dimensions. Ophthalmic Clinic. 19(4): 225-236.

Dziezyc, J., Hager, D.A. (1988). Ocular Ultrasonography in veterinary medicine. Seminar in Veterinary Medicine and Surgery (Small Animal). 3(1): 1-9.

El-Maghraby, H., Nyland, T.G., Bellhorn, R.W. (1995). Ultrasonographic and biometric evaluation of sheep and cattle eyes. Veterinary Radiology and Ultrasound. 36: 148-151.

Feng, M.T., Belin, M.W., Ambrosio Jr, R., Grewal, S.P.S., Yan, W., Shaheen, M.S., McGhee, C., Maeda, N., Neuhann, T.H., Dick, B.H., Alageel, S.A., Steinmueller, A. (2011). Anterior chamber depth in normal subjects by rotating scheimpflug imaging. Saudi Journal of Ophthalmology. 25(3): 255-259.

Galan, A., Martin-Suarez, E.M., Molleda, J.M. (2006). Ophthalmoscopic characteristics in sheep and goats: Comparative study. Journal of Veterinary Medical Series A. 53(4): 205-208.

Ganai, N.A., Bhat, Z.I., Sheikh, F.A. (2016). Policy Planning for Conservation and Sustainable Use of Farm Animal Genetic Resources in Jammu and Kashmir. National Symposium on Policy Planning for Livelihood Security through Domestic Animal Biodiversity and XII Annual Convention of Society for Conservation of Domestic Animal Biodiversity. February 11-12, pp 85.

Gonzalez, E.M., Rodriguez, A., Gracia, I. (2001). Review of ocular Ultrasonography. Veterinary Radiology and Ultrasound. 42: 485-495.

Hager, D.A., Dziezyc, J., Millchamp, N.J. (1987). Two-dimensional real-time ocular Ultrasonography in the dog- technique and normal anatomy. Veterinary Radiology. 28: 60-65.

Hughes, A.A. (1972). Schematic eye for the rabbit. Vision Research. 12: 123-138.

LeMay, M. (1978). B-scan Ultrasonography of the anterior segment of the eye. British Journal of Ophthalmology. 62: 651-656.

MacKay, C.S., Mattoon, J.S. (2015). Eye. In: Small Animal Diagnostic Ultrasound, [Mattoon, J.S., Nyland, T.G., (eds)], 3rd edition, (Elsevier, Saunders) pp. 128-154.

Morales, I., de Leon, M., Morales, M., Dalla, F., Gutierrez, C., (2006). Ocular lesions associated with *Trypanosoma evansi* in experimentally infected goats. Veterinary Parasitology. 141(3-4): 325-329.

Patwardhan, A.A., Khan, M., Mollan, S.P., Haigh, P. (2008). The importance of central corneal thickness measurements and decision making in general ophthalmology clinics: A masked observational study. BMC Ophthalmology. 8(1). https://doi.org/10.1186/1471-2415-8-1.

Potter, T.J., Hallowell, G.D., Bowen, I.M. (2008). Ultrasonographic anatomy of the bovine eye. Veterinary Radiology and Ultrasound. 49: 172-175.

Qureshi, M.A., Laghari, K. (2010). Role of B-Scan Ultrasonography in pre-operative cataract patients. International Journal of Health Sciences. 4(1): 31-37.

Reichmann, P. (2008). Occurrence of ophthalmologic diseases in horses used for urban cart hauling in Londrina, PR, Brazil. Ciencia Rural. 38: 2225-2528.

Ribeiro, A.P., Santos, N.L., Silva, V.C., Campos, A.F., Teixeria, I.A.M.A., Laus, J.L. (2010). Ultrasonographic and echobiometric findings in the eyes of adult goats. Ciência Rural. 40(3): 568-573.

Ribeiro, A.P., Silva, M.L., Rosa, J.P., Souza, S.F., Teixeira, I.A.M.A., Laus, J.L. (2009). Ultrasonographic and echobiometric findings in the eyes of Saanen goats of different ages. Veterinary Ophthalmology. 12(5): 313-317.

Shih, C.Y., Zivin, J.S.G., Trokel, S.L., Tsai, J.C. (2004). Clinical significance of central corneal thickness in the management of glaucoma. Archives of Ophthalmology. 122(9): 1270-1275. doi: 10.1001/archopht.122.9.1270.

Simon, M. (1996). Diagnostic Kchographique en Ophtalmologie. EncycopCdie VCtCrinaire. Paris (Elsevier), IMAGERIE 3000, pp 1-10.

Singh, S., Purohit, S., Malik, V., Yadav, S., Singh, R.K., Gangwar, N.K., Pandey, R.P. (2016). Echo-morphometric evaluation of ocular affections in Murrah buffaloes: Review of 15 cases. Ruminant Science. 5(1): 117-122.

Singh, S., Purohit, S., Pandey, R.P. (2015). B-mode intraocular echo-morphometry of Murrah buffalo (*Bubalus bubalis*). Ruminant Science. 4(2): 249-254.

Slater, D. (1990). Fundamentals of Veterinary Ophthalmology, (W.B. Saunders, Philadelphia).

Smith, M.E., Coleman, D.J., Haik, B.G. (1986). Ultrasonography of the eye. International Ophthalmology Clinics. 26: 25-50.

Soroori, S.I., Masoudifard, M.I., Raoofi, A.I., Aghazadeh, M. (2009). Ultrasonographic findings of some ocular structures in Caspian miniature horse. Iranian Journal of Veterinary Research. 10: 329-333.

Tamilmahan, P., Zama, M.M.S., Pathak, R., Muneeswaran, N.S., Karthik, K. (2013). A retrospective study of ocular occurrence in domestic animals: 799 cases. Veterinary World. 6(5): 274-276.

Toni, M.C., Meirelles, A.É., Gava, F.N., Camacho, A.A., Laus, J.L., Canola, J.C. (2010). Rabbits' eye globe sonographic biometry. Vetreinary Ophthalmology. 13(6): 384-386.

Waklridge, B.M., Colitz, C.M.H. (2002). Diseases of the Eye. In: Sheep and Goat Medicine, [D.G. Pugh (ed)], 1st edn. (W.B. Saunders Company, Philadelphia, PA). pp 317-339.

Whitcomb, M.B. (2002). How to diagnose ocular abnormalities with ultrasound. American Association of Equine Practitioners Proceedings. 48: 272-275.

Whittaker, C.J.G., Gelatt, K.N., Wilkie, D.A. (1999). Food Animal Ophthalmology. In: Veterinary Ophthalmology, [Gelatt K.N. (ed)], 3rd edn. (Lippincott Williams and Wilkins, Philadelphia, PA). pp 1117-1176.

Wilkie, D.A., Gilger, B.C. (1998). Equine Diagnostic Ocular Ultrasonography. In: Equine Diagnostic Ultrasonography. [Rantanen, N.W. and McKinnon, A.O. (eds)]. (Philadelphia: Williams and Wilkins), pp 637-643.