RESEARCH ARTICLE Indian Journal of Animal Research, Volume 57 Issue 10: 1314-1321 (October 2023)

Cadaveric, Organ Bath and Real Time Ultrasonographic Studies on Liver and Associated Structures in Calves

Anwar Hussain Nagoo[1], J.D. Parrah[1], Dil M. Makhdoomi[1], Hakeem Ather[1], Uiase bin Farooq[1], Ommer Bashir[1]

10.18805/IJAR.B-4383

ABSTRACT

Background: Hepatic disorders though prevalent in cattle especially in calves received negligible attention for their definitive diagnosis. Clinical evaluation of liver remained dependent on laboratory estimation of hepato specific biochemicals which often lead to misdiagnosis. The present detailed three phase study was aimed at determining ultrasonographic evaluation of liver and its associated structures in calves up to 9 months of age to develop a baseline data that could be used for their diagnostic evaluation.

Methods: Calves were divided in three groups *viz*. neonatal, preruminant and ruminating; Cadaveric and *in vitro* organ bath ultrasonographic studies (*n*=2 in each group) was followed by comparative real time *in vivo* ultrasonography on live calves (*n*=6 in each corresponding group).

Result: Liver was seen in right 5th to 11th Intercostal space (ICS) in most neonatal calves, 6th to 11th ICS in preruminant calves and from 8th ICS to the area just beyond the last rib in ruminating calves. Parenchyma appeared smooth isoechogenic intercepted with portal vein branches. Echobiometric parameters showed statistically significant difference among three groups of animals. Gallbladder appeared pyriform depicted mostly in 9th ICS. Caudal vena cava appeared triangular and was seen at 9th to 11th ICS, except in ruminating calves. Portal vein was prominent in 10 ICS. Amongst identical age groups, the comparative parameters, resembled largely in different studies.

Key words: Cadaveric, Gallbladder, Liver parenchyma, Organ bath, Real time ultrasonography.

INTRODUCTION

Liver diseases in cattle are manifested by nonspecific signs; include weight loss, poor appetite and anterior abdominal pain causing an arched back and even laminitis or encephalopathy. The definitive diagnosis by evaluating hepatospecific enzyme is insufficient and usually difficult resulting unsuccessful treatment. Hepatic pathologies were common in calves of 6 weeks age but were also seen in day old and even in aborted foetus (Doll *et al.,* 1989). Textural, vascular and ductal derangements in calves sometime leading to fatal sequale (Weiland *et al*., 2017) were absolutely difficult to predict or diagnose. With the advent of Ultrasonographic examination and its applicability on ruminants for hepatic evaluation provided detailed information about the size, position and ultrasonographic parenchymal pattern of the liver, the size and position of the gallbladder and the intra- and extra hepatic bile ducts and the topography of the major vessels in adult cattle (Braun, 2009) and in calves (Braun and Kruger, 2013).

MATERIALS AND METHODS

The study was conducted (at Mountain Livestock Research Institute and Teaching veterinary clinical services complex of SKUAST-K) in three phase's *viz* cadaveric study, *in vitro* organ bath ultrasonographic study to gain the knowledge about the topographic anatomy and echo texture of calf liver and associated structures respectively, followed by actual comparative phase; the real time *in vivo* ultrasonography of normal live calf liver *etc*. at different age stages as tabulated below (Table 1). Organ bath study was done by immersing liver in water bath at 36°C temperature and subjecting morbid material to repeated ultrasonography by a 7.5 to 12 MHz linear transducer (Plate 1).

Instrumentation

A real time B-mode ultrasound machine Esoate My Lab 40 Vet fitted with linear and sector transducers of 3.5-12 MHz frequency ware used. Copious amount of Sonography transmission gel "Aquasone 2000" was applied on the body surface before fixing of the transducer. Calves were secured in standing position without any sedation. The abdominal area of each calf, from tuber-coxae to 5th intercostal space in horizontal plane and from dorsal midline of vertebral column to linea alba on both sides in vertical plane were shaved and cleaned with tap water first followed by isopropyl alcohol (Plate 2).

[1]Department of Animal Husbandry, Government of Jammu and Kashmir, Kashmir-190 001, Jammu and Kashmir, India.

Corresponding Author: Anwar Hussain Nagoo, Department of Animal Husbandry, Government of Jammu and Kashmir, Kashmir-190 001, Jammu and Kashmir, India. Email: vetanwar@gmail.com

How to cite this article: Nagoo, A.H., Parrah, J.D., Makhdoomi, D.M., Ather, H., Farooq, U.B. and Bashir, O. (2023). Cadaveric, Organ Bath and Real Time Ultrasonographic Studies on Liver and Associated Structures in Calves. Indian Journal of Animal Research. 57(10): 1314-1321. doi: 10.18805/IJAR.B-4383.

Submitted: 18-12-2020 **Accepted:** 05-04-2021 **Online:** 29-04-2021

Scanning technique

Calves were examined with a 3.5 MHz curvilinear transducer followed by 10-12 MHz linear transducer. The maximum depth of field for this transducer was 7-12 cm.

Structures studied

Liver including Gall bladder, caudal Vena cava (CVC) and portal vein (PV).

Sonographic parameters included were acoustic window, echogenicity patterns, location of the organs and biometry of the organs.

The loci of transducer placement at which proper acoustic window was identified for obtaining the optimal images were recorded taking the guidance from studies Braun and Kruger (2013) and Braun (1990). Dimensions were measured and their mean±SE were recorded. The positions of the dorsal and ventral margins were measured in relation to the midline of the back to calculate their size as per Braun and Kruger (2013). The effective length of liver were calculated by measuring the distance between the transducer fixing sites depicting visible margins of the organs along the long axis of organs through intercostal spaces and the transducer fixing sites where the margins of the organs became invisible.

Statistical analysis

The data was statistically analyzed by SPSS software using "one way ANOVA" for comparing the means and calculating the significance of the data. The means were subjected to DMRT to compare groups.

RESULTS AND DISSCUSSION

Cadaveric study

From right side of the abdomen, two lobes *i.e.* caudate (caudal) lobe and diaphragmatic (Cranial) lobe of liver, separated from one another by umbilical fissure located distal to L_2 vertebra were evident in Group 1 (G1), neonatal calves (Plate 3). Of the two lobes, caudate lobe (which is actually the caudate process of left liver lobe) was significantly smaller than cranial. Caudate lobe, triangular in shape, had apex on caudal side and base on cranial side adjacent to umbilical fissure. The apex of caudate lobe of liver was found distal to L_4 vertebra, which continued dorsocranially by its dorsal surface. Dorsal surface of caudate lobe was spread dorsally from L_4 to L_2 vertebrae. The apex and dorsal surface of caudate lobe was rested upon hilar surface of right kidney while ventral surface is associated with descending duodenum (Plate 3).

Cranial, the bigger lobe, evident on right side of abdomen was somewhat rectangular in shape placed obliquely at an obtuse angle to longitudinal axis of the body bounded caudally by caudate lobe of liver, anteriorly by abdominal surface of diaphragm and dorsally by cranial pole of right kidney and ventrally by spiral colon (Plate 3). Cranial liver lobe and right lung interface was located in a space adjacent ventrally to T_{12} to T_9 vertebra medial to 8th to 11th Intercostal spaces. Average largest size (dorsal to ventral plane) of anterior lobe of liver was 14 cm. and that of caudate lobe 6.2 cm. The average length of both the lobes on right side of the abdomen from abdominal surface of diaphragm to apex of caudate lobe was 14 cm. In the animals of Group 2 and 3, apex of caudate lobe moves cranially and lies ventral to L_3 vertebrae. In these groups maximum size of anterior lobe was 14.5 and 17 cm respectively. Average length in these two groups was 18 and 28 cms respectively (Table 2).

Liver is the largest gland in the body constituting about 1-2% of total body weight. Liver is immediately caudal to diaphragm and tend to locate in right side especially in ruminants (Frandson *et al.,* 2009). In new born calf liver is comparatively much larger than adult with deep umbilical



Plate 1: Organ bath study.



Plate 2: Animal preparation.

Table 1: Category and group size for different phases of study.

Group	Category of the calf	Age	Number of animals	
			Cadaveric and organ bath studies	RTU studies
G1	Neonatal calves	1-30 days	02	06
G2	Pre-ruminant calves	2-3 months	02	06
G3	Ruminant calves	6-9 months	02	06

Table 2: Dimensions of liver and gall bladder in calves of different groups (all values in cm).

Group	Liver			Gall bladder	
	Average size		Average length	Average longitudinal axis length	Average vertical axis length
	cranial lobe	*caudate lobe*			
G1	14	6.2	14	6	3.5
G2	14.5	7.2	18	6.8	3.9
G3	17	9.5	28	7.1	4.2

fissure (Habel, 1975) and lies across the midline extensively to abdomen, with the development of the rumen and reticulum, liver is pressed to right and dorsally and it rotated such that its left lobe comes to lie cranioventrally to right lobe and out of reach of abdomen (Singh, 2017). Liver in calves weights relatively greater compared to adult (Budras and Habel, 2003a) as it always decreases with the age (Schummer *et al*., 1979a). Present study recorded umbilical fissure not only in neonatal calves but also in the animals of other groups however, it was comparatively deep in neonatal calves and mostly located distal to 2nd lumber (L_2) vertebrae. The position and changes in the location of liver with the development of forestomach was also recorded in present study and fairly resembled the above studies. There was fair evidence of decrease in size and weight as reported above and present study was affirmative regarding these changes with the advancement of age of calf.

In calves aged one week cranial lobe extends from 8th to 13th rib (7th to 12th ICS) and that of caudate lobe from 13 rib (12th ICS) to 2nd or 3rd lumber transverse process while as adult liver is situated between 6th to 13th rib with apex of caudate lobe (caudate process) situated at mid of 13th rib (Raymond and Stanlay, 2010). In present study however, the cranial lobe in neonatal calves was seen extending from 10th rib to 2nd lumbar vertebrae and caudate lobe extends from L_2 to L_4. In other groups, cranial as well as caudate lobe moves forward so that anterior part of cranial lobe and apex of caudate lobe are positioned at 7th rib and L_3 transverse process, respectively.

Gall bladder is pear shaped in cattle. In neonatal calves of 1 week age gall bladder is located below the costal arch of 13 rib and medial to the descending duodenum (Raymond and Stanley, 2010). Similar observation was observed in present study and Gall bladder was seen to be positioned at last ICS in all groups of calves.

In adult cattle the length is about 10-15 cm (Habel, 1975) and may reach the diameter of about 10 cm (Schummer *et al.,* 1979b). In present study neonatal calves showed the length of 6 cm while in pre ruminating and ruminant calves length of 6.8 and 7.1 cm were recorded. Breadth was recorded as 3.5, 3.9 and 4.2 cm in G1, G2 and G3 animals respectively and the difference could be attributed to age.

Gall bladder was pear shaped located ventral to umbilical fissure at last ICS. It was partially attached to visceral surface of cranial lobe of liver (Plate 3). Gall bladder was enclosed ventromedially by spiral colon. In G1 calves average longitudinal and vertical axis length of gall bladder was about 6 cm and 3.5 cm, respectively.



Plate 3: Cadaveric appearance of liver and gall bladder in neonatal calf.



1. Parenchyma 2. Capsule 3. Base of container.

Plate 4: *In vitro* sonogram of liver.



1. Wall 2. Contents 3. Base of container.

Plate 5: *In vitro* sonogram of gall bladder.

In the animals of G2 and G3 no change in location of gall bladder was observed with respect to that of G1 animals. However, 10% and 18% increase in dimensions of gall bladder was observed) in the animals of G2 and G3 respectively as compared to G1 animals (Table 2).

Gall bladder is partly associated with visceral surface of liver to which it is attached however its large part is associated directly with right abdomen wall (Habel, 1975). Similar to the result of present study.

Organ bath study

The liver parenchyma appeared isoechogenically hypoechogenic and smooth as compared to echogenicity of splenic parenchyma. Liver capsule appeared hyperechogenic as compared to the liver parenchyma. The liver capsule appeared hyperechoic at some places and not well appreciated at others (Plate 4). Vasculature like portal vein and caudal vena cava were invisible. Vena cava sulcus, triangular in shape was faintly visible.

The liver parenchyma appeared uniformly hypoechogenic and smooth as compared to echogenicity of splenic parenchyma. This is attributable to the fact that liver parenchyma is more compact and has got uniformity of its reflecting surface which is composed of slightly coarse-grained texture. Similar views were also reported during recording of the observations in other studies (Mannion, 2006). Liver capsule appeared hyperechogenic as compared to the liver parenchyma due to its high acoustic impedance. The liver capsule was clearly viewed in present study in contrast to the reports made by Imran *et al.* (2011) nevertheless capsule was not well appreciated at some places. Vasculature like portal vein and caudal vena cava were invisible owing to their collapse and off course due to coagulation of their luminal contents (Imran *et al.,* 2011) however, the Vena cava sulcus, was faintly visible in present study.

Gallbladder appeared pear shaped anechogenic structure with a hyperechogenic wall (Plate 5). Cystic and extra hepatic ducts were not visible.

Gallbladder appeared pyriform anechogenic structure with a hyperechogenic wall. Fluid nature of bile did not produce any echo thereby appeared anechogenic. Duct system was invisible due to their collapse. Similar view was also reported by Imran *et al.,* 2011.

Real time ultrasonography

Liver

Acoustic window

It was seen in right side of the abdomen in the animals of all groups (Fig 1). In G1 animals it was constantly depictable through ultrasonography from 5th to 11th Intercostal spaces (ICS) in 5 animals and from 4th to11th ICS in one animal. In all the animals of G2 liver was scanable from 6th to 11th ICS. Liver was scanable from 8th ICS to the area just beyond the last rib in all the animals of G3.

The bovine liver is situated immediately adjacent and medial to the right body wall. The ultrasonographic examination is performed as described by Braun, 2009[b]. Liver was constantly depicted on right side from 5th to 11th intercostal spaces (ICS) in G1 animals, 16th to 11th ICS all the animals of G2 and 8th ICS to the area just beyond the last rib in all the animals of G3 similar to the finding of Braun and Kruger (2013).

Dorsal margin of liver in the animals of G1 was visible ultrasonographically in distal third portion of 5th ICS and upper third of 12th ICS with upward trend in the intercostal spaces ranging from 6th to 12th. Almost similar trend was observable in the animals of other groups. Ventral margin of liver in the animals of all groups was visible in lower third portion of intercostal spaces ranging from 5th to 7th and then in mid portion of intercostal spaces ranging from 8th to 12th. Lung-Liver interface was seen in 9th ICS in the animals of G1 and G2 and in 10th ICS in the animals of G3 (Plate 6A). Kidney-liver interface was seen at 11th ICS in the animals of all groups (Plate 6B).

Ventral margin was seen mostly from 5th to 7th and mid portion of 8th to 12th ICS in all groups. Lung-Liver interface

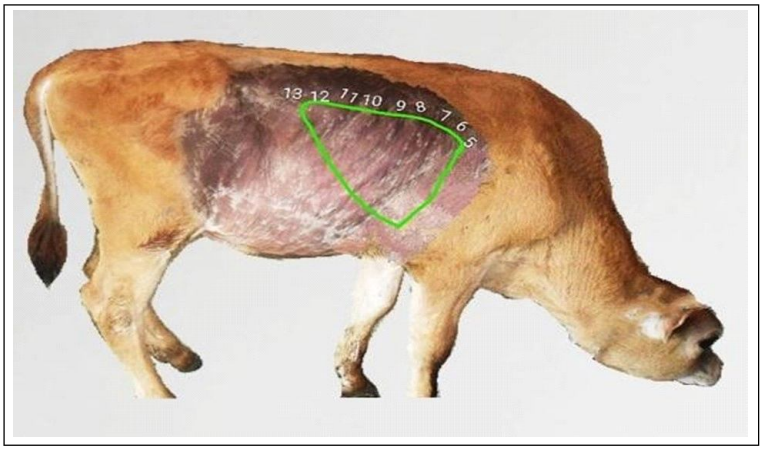

Fig 1: Acoustic window for liver in calves.

was seen in 9th-10th ICS. Kidney liver interface was seen at 11th ICS. Dorsal margin of the liver was found treading upward trend from cranial to caudal vertebrae exactly as described by Braun and Kruger (2013).

Echogenicity patterns

Numerous fine echoes homogeneously distributed over the entire parenchymal area of the liver were scanable. Liver parenchyma was intercepted with branches of portal vein in the form of anechoic tubular structures with prominent stellar ramifications during sagittal view and in circular form during traverse view (Plate 6C). Diaphragmatic surface of the liver was seen as hyperechoic line adjacent to the peritoneum, while as visceral surface was not clearly defined. Distal angle was generally rounded (Plate 6D).

Homogeneously smooth echotexture of parenchyma was intercepted by portal vein branches as anechoic tubular structures with prominent stellar ramifications. Diaphragmatic surface appeared hyperechoic line adjacent to the peritoneum, while as visceral surface was not clearly defined. Distal rounded angle was generally prominent. Similar observations were reported by Braun and Kruger (2013).

Location

Cranially the liver was adjacent to the diaphragm and dorsally it was superimposed by the lungs as far back as the 11th or 12th intercostal space. Visible dorsal margin of the liver ran parallel to the ventral border of the lungs from cranioventral to caudodorsal position (Plate 6A).The distance between dorsal midline and visible dorsal margin of the liver decreased caudally because the liver became less obscured by the lung. Animals of all the groups possessed the longest distance between the visible dorsal margin of the liver and the dorsal midline at 5th ICS, but shortest in the 11th intercostal space in the animals of G1 and G2 and 12 ICS in the animals of G3. Almost similar course was seen with respect to the ventral margin of the liver; it was furthest from the dorsal midline at the 5th intercostal space and closest to the dorsal midline at dorsocranial angle of right flank.

Cranially the liver was adjacent to the diaphragm and dorsally it was superimposed by the lungs mostly up to 12th intercostal space. The findings substantiate the observations of Braun (2009b), who reported that in bovine the cranial

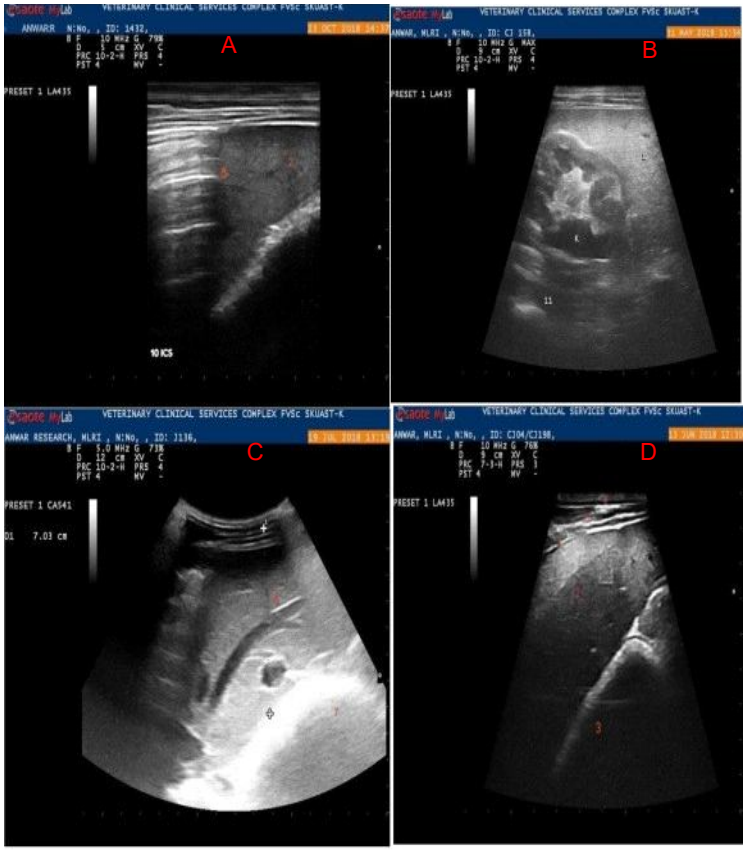

1. Capsule; 2. Parenchyma; 3. Reticulum; 4. Abdominal wall; 5. Muscles and fascia; 6. Ramification of portal vein; 7. Omasum; 8. Lung-liver interface at 10ICS; 9. Kidney liver interface at 11 ICS.

Plate 6: Real time ultrasonogram of liver.

aspect of the liver is hidden by the lung. Animals of all the groups possessed the longest distance between the visible dorsal margin of the liver and the dorsal midline at 5th ICS, but shortest in the 11th - 12th ICS. Almost similar course was seen with respect to the ventral margin of the liver. Largest liver size was recorded in the intercostal spaces from 8th to 11th in the animals of all groups. Liver in the calves showed steady increase in size with corresponding advancement in age. Liver length increased by 33% from neonatal stage to pre-ruminating stage and by 27% from pre-ruminating to ruminating stage. Perusal of available literature suggests that such an observation in growing calves is being recorded for the first time. Maximum liver thickness was noticed in 8th 10th and11th intercostal spaces in the animals of G1, G2 and G3, respectively. These findings were almost in agreement with Braun and Kruger (2013).

Biometry

Mean±SE (cm) of liver size was 13.81±0.52, 13.96±0.40 and 14.66±0.47 in the animals of G1, G2 and G3 respectively. Liver size in G1 animals was significantly (P>0.05) different from the animals of other 2 groups (Table 3). Largest liver size was recorded in the intercostal spaces from 8th to 11th in the animals of all groups.

Effective liver length increased significantly (P<0.05) with the increase in age of the animals. Liver length values (Mean±SEcm) recorded were 14.71±0.61, 19.64±0.80 and 24.96±1.03 in the animals of G1, G2 and G3 respectively. Percent increase in liver length from the animals of G1 to G2 was 33% and from G2 to G3 animals 27%.

Liver thickness increased significantly (P<0.05) from G1 animals (5.45±0.29) to G2 animals (7.10±0.22) and to animals of G3 (11.56±0.60) (Table 3). Maximum liver thickness was noticed in 8th 10th and 11th intercostal spaces in the animals of G1, G2 and G3, respectively.

Gall bladder

Acoustic window

Gallbladder was visible from 7th to 10th intercostal spaces (ICS) in the animals of all groups; however it was more depictable in 9th ICS.

Echogenicity patterns

Gall bladder when distended usually appeared pyriform in shape in most of the animals (Plate 6). Circular or oval shaped gall bladders were also seen in few animals of different groups. Gallbladder was identified with anechoic contents surrounded by an echoic wall (Plate 7).

Location

Gall bladder was scanable mostly near the ventral margin of liver, however extended beyond it when fully distended with bile.

Biometry

The length of gall bladder in G1 animals varied from 2.76-4.27 cm (3.52±0.29) and width of distended gall bladder between 1.22-1.81 cm (1.52±0.11). Increase in the length of gall bladder recorded was 20% from G1 to G2 animals, 15% from G2 to G3 animals and 38% from G1 to G3 animals (Table 3). Gall bladder length and width of G3 animals were significantly higher (P>0.05) than those of other groups.

Variation in the location of the gall bladder could be obviously attributable to the increased size of large cross bred cows as compared to those of the calves of different age groups, who formed the material of the study. Gall bladder was viewed near the ventral margin of liver, however extended beyond it when fully distended with bile.



1. Wall, 2. Contents (bile) 3. Liver.

Plate 7: Real time ultrasonogram of gall bladder.

Table 3: Mean±SE (cm) of calf liver "upper values", gall bladder and vascular echobiometry in animals of different groups.

Groups	Parameters						
	Liver			Gall bladder		Vessels	
	Size	Length	Thickness	Length	Width	Circumference (CVC)	Diameter PV
G1	13.81±0.52[a]	14.71±0.61[a]	5.45±0.29[a]	3.52±0.29[a]	1.52±0.11[a]	4.33±0.54[a]	0.66±0.09[a]
	(12.45-15.17)	(13.12-16.30)	(4.67-6.22)	(2.76-4.27)	(1.22-1.81)	(2.95-5.72)	(0.43-0.88)
G2	13.96±0.40[b]	19.64±0.80[b]	7.10±0.22[b]	4.20±0.20[ab]	1.70±0.13[a]	7.02±0.53[b]	1.13±0.08[a]
	(12.60-15.29)	(17.58-21.70)	(6.51-7.68)	(3.69-4.71)	(1.37-2.03)	(5.65-8.38)	(0.92-1.35)
G3	14.66±0.47[b]	24.96±1.03[c]	11.56±0.60[c]	4.85±0.23[b]	3.42±0.17[b]	7.40±0.75[b]	2.52±0.29[b]
	(13.44-15.89)	(22.29-27.63)	(10.01-13.12)	(4.25-5.45)	(2.98-3.85)	(5.48-9.32)	(1.76-3.27)

Values with same superscript [a,b,c] represents statistical non significance range in parentheses as 95% CI.

Dimensions of the gall bladder increased correspondingly with the advancement in the age of the calves, as 20% and 38% increase in the length of gall bladder was observed in G2 and G3 animals respectively as compared to the G1 animals. All these findings are mostly in agreement with those of Braun and Kruger (2013).

Caudal vena cava

Acoustic window

Caudal vena cava was seen at 9th to 11th ICS in the animals of G1 and G2 and at 8th to 10th ICS in the animals of G3.

Echogenicity patterns

The caudal vena cava appeared triangular in cross section (Plate 7). Caudal vena cava was identified with echogenic wall and anechoic lumen (Plate 8).

Location

Caudal vena cava was situated above the portal vein towards diaphragmatic surface of liver. The distance between caudal vena cava and portal vein varied from 4 cm in G1 animals to 6 cm in G3 animals.

Biometry

Circumference of caudal vena cava was 4.33±0.54, 7.02±0.53 and 7.40±0.75 cm respectively in the animals of G1, G2 and G3 (Table 3). Circumference values of G1 animals were significantly (P<0.05) lower from those of G2 and G3 animals.

It appeared triangular in cross section having echogenic wall and anechoic lumen, situated above the portal vein towards diaphragmatic surface of liver. These findings are inconsonance with those of Braun (1990) and Braun and Gerber (1994), who reported that caudal vena cava was triangular in shape and was located more dorsal and medial than the portal vein. They further reported that the walls of the CVC and hepatic veins were not distinct, thus substantiating the findings of this study. The distance between caudal vena cava and portal vein varied from 4 cm in G1 animals to 6 cm in G3 animals. The circumference of caudal vena cava was 4.33±0.54 in G1 animals and increased to 7.40±0.75 cm in G3 animals. The study was fairly in agreement with Braun and Kruger (2013).

Portal vein

Acoustic window

Portal vein was constantly seen in the intercostal spaces (ICS) from 6th to 12th however it was visible prominently in 10 ICS in the animals of all groups.

Echogenicity patterns

Portal vein was circular in 12 (67%) animals and oval in 6 (33%) animals (Plate 9A and 10B). Portal vein was conspicuous because of its satellite ramifications branching into the liver parenchyma (Plate 6C) and hyperechogenic wall as compared to that of caudal vena cava, its identity was confirmed with colour Doppler (Plate 9).

Location

The portal vein was always located more ventral and closer to the diaphragmatic surface of the liver. The distance between the portal vein and the dorsal midline decreased on moving cranial to caudal in the animals of all groups.

Biometry

Diameter (Mean ±SE) in cm. of portal vein was 0.66±0.09, 1.13±0.80 and 2.52±0.29 in the animals of G1, G2 and G3 respectively (Table 3). Mean diameter values of G3 animals were significantly (P>0.05) higher than those of other groups.

Echobiometry, Locations and echogenicity patterns of liver and associated structures obtained during RTU of live animals largely resembled with those of biometry, position seen during cadaveric study and organ bath observations respectively. Exception being that vasculature including vascular triangle consisting of portal vein, hepatic artery and caudal vena cava (Plate 10) were not seen during water bath studies. Echotexture of liver parenchyma in water bath studies was smoother, as compared to real time ultrasonographic studies.



1. Liver parenchyma (P= Portal vein, C= CVC).

Plate 8: Real time ultrasonogram of caudal vena cava (CVC).



1. Lumen of vein 2: Liver parenchyma.

Plate 9: Real time ultrasonogram and doppler view of portal vein.



1. Liver capsule 3. Liver parenchyma
(P= Portal vein; C= CVC; H= Hepatic artery.

Plate 10: Real time ultrasonogram of hepatic vasculartriangle seen at 9th ICS.

Portal vein was visible from 6th to 12th ICS but was prominent at 10th ICS in the calves of all groups. It appeared circular in 2/3rd of calves scanned. The findings are in agreement with those of Braun and Kruger (2013), who reported that portal vein was always seen at the 7th to 11th intercostal spaces and sometimes also at the 6th and 12th intercostal spaces in Holstein Friesian bull calves. The difference of one intercostal space visibility on either side could be because of breed variation as our study was conducted on Jersey calves. However both the studies are equivocal in the sense that the portal vein is circular or oval in cross section and had stellate ramifications branching into the liver parenchyma. Similar shape of the vein and the stellate ramifications had been described in adult cattle, sheep (Braun and Hausammann, 1992) and goats (Braun and Steininger, 2011).

In cross bred cows portal vein was imaged characteristically as a star-shaped anechogenic structure with a hyperechogenic wall, ventral to the CVC, in the last 2 intercostal spaces in all the cows (Imran *et al.,* 2011). Portal vein was found ventral and closer to the diaphragmatic surface of the liver in the calves of different age groups of this study. This observation is in total consonance with those of Braun and Kruger (2013). Diameter of portal vein increased steadily with advancement in age of the calves, ranging from 0.66±0.09 cm in G1 animals to 2.52±0.29 cm in G3 animals of this study, thus even surpassing the values (2.38±0.12 cm) recorded in cross bred cows by Imran *et al.* (2011a).

CONCLUSION

The bovine liver is situated immediately adjacent and medial to the right body wall. Liver was seen in right side of the abdomen in the animals of all groups. The ultrasonographic attributes of liver and its associated structures vary according to age of the calves and also differ from adult animals. Ultrasonography is an excellent tool for evaluating the liver in normal and diseased calves.

REFERENCES

Braun, U. and Gerber, D. (1994). Influence of age, breed and stage of pregnancy on hepatic ultrasonographic findings in cows. American Journal of Veterinary Research. 55(9): 1201-1205.

Braun, U. (1990). Ultrasonographic examination of the liver in cows. American Journal of Veterinary Research. 51(3): 1522-1526.

Braun, U. and Krüger, S. (2013). Ultrasonography of the spleen, liver, gall bladder, caudal vena cava and portal vein in healthy calves from birth to 104 days of age. Acta Veterinaria Scandinavica. 55: 68. doi: 10.1186/1751-0147-55-68.

Braun, U. and Steininger, K. (2011). Ultrasonographic characterization of the liver, caudal venacava, portal vein and gallbladder in goats. American Journal of Veterinary Reseasch. 72(2): 219-225.

Braun, U. (2009b). Ultrasonography of the liver in cattle. Veterinary Clinics of North America (Food Animal Practice). 25: 591-609.

Braun, U. and Hausammann, K. (1992). Ultrasonographic examination of the liver in sheep. American Journal of Veterinary Research. 53: 198-202.

Budras, K.D. and Habel, R.E. (2003a). Bovine Anatomy an Illustrated Text 1st Ed. Sclutersche Gmbh and Co. Germany. P: 70-74.

Doll, K., Erer, H., Hanichen,T., Bauer, J., Gunzler, D. (1889). Liver Cirrhosis in young calves. Tieraaztl Prax. 17(2): 149-156.

Frandson, R.D., Wilke, W.L. and Fails, A.D. (2009). Anatomy and Physiology of Farm Animals 7th Ed. Wiley Blackwell. P: 358.

Habel, R.E. (1975). In Sisson and Grossman's The Anatomy of the Domestic Animals 5th Ed. W.B Saunders Company; Philadelphia. P: 885-913.

Imran, S., Tyagi, S.P., Kumar, A., Adarsh, K. and Sharm, S. (2011). Comparative ultrasonographic imaging of spleen and liver in healthy crossbred cows. Journal of International Scholarly Research Network. 2. doi: 10.5402/2011/419591.

Mannion, P. (2006). Diagnostic Ultrasound in Small Animal Practice, Blackwell, Ames, Iowa, USA, 1st edition.

Raymond, R.A. and Stanlay, H.D. (2010). Colour Atlas of Veterinary Anatomy Vol 1, 2nd Ed. Elsevier P. 109-127.

Schummer, A., Nickel, R. and Sack, W.O. (1979b). The Viscera of Domestic Mammals; Text Book of the Anatomy of Domestic Animals, 2nd Ed. P178.

Schummer, A., Nickel, R. and Sack, W.O. (1979a). The Viscera of Domestic Mammals; Text Book of the Anatomy of Domestic Animals, 2nd Ed. P114.

Singh, B. (2017). In Dyce, Sack and Wensing's Text Book of Veterinary Anatomy, Elsevier 5th Ed. P: 668-684.

Weiland, M., Mann, S., Hafner-Marx, A., Ignatius, A. and Matzner, M. (2017). Hepatic lipodystrophy in Galloway calves. Veterinary Pathology. 54(3): 467-474.