RESEARCH ARTICLE Indian Journal of Animal Research, Volume 57 Issue 10: 1293-1295 (October 2023)

Gross Morphological and Light Microscopic Studies of the Spleen of Malayan Sun Bear (*Helarctos malayanus*)

P.C. Kalita[1], A. Kalita[1], O.P. Choudhary[1], P.J. Doley[1], S. Debroy[1], R. Sarkar[1]

10.18805/IJAR.B-4390

ABSTRACT

Background: Bear specialist group recommended that the basic research on the Malayan sun bear is the highest priority need. Without such information, the establishment and implementation of scientifically-sound conservation plans is difficult. Therefore, present study was designed to provide information on gross morphological and light microscopic architecture of the spleen.

Methods: The present study was conducted on the spleen of one Malayan sun bear. After doing the gross parameters the tissues were fixed in 10% neutral buffered formalin and were processed for light microscopic studies. Blocks were cut at 6µ thickness by Leica Semimotorized Rotary Microtome and stained by Harris' haematoxylin and eosin for routine study.

Result: The spleen of Malayan sun bear was located in the left hypogastric region and entirely intrathoracic as the stomach was almost empty. The parietal surface faces the diaphragm and left lateral abdominal wall, whereas the visceral surface was divided into gastric face and intestinal face by the ridge like hilus. The spleen of Malayan Sun Bear was surrounded by a thick connective tissue capsule invested by the peritoneum. The capsule, trabeculae and reticular fibers support the splenic parenchyma composed of a red pulp and a white pulp.

Key words: Gross morphology, Light microscopy, Malayan sun bear.

INTRODUCTION

The Malayan sun bear (*Helarctos malayanus*) is the only bear species inhabiting equatorial lowland rain forest (Servheen *et al.*, 1999). In 1996, it has been classified as Data Deficient (DD) by IUCN red list of threatened species (IUCN, 1996), because of a lack of knowledge about its distribution, area of occupancy and population trends even though it was listed as a vulnerable (VU) species in 2008 (Nazeri *et al.*, 2012). Due to lack of basic information regarding Malayan sun bear ecology, habitat loss and human-caused mortality inhibits managers' abilities to prioritise threats and develop strategies to address the most important issues (Peyton *et al.,* 1999). The world's smallest species of bear, the Malayan sun bear (*Helarctos malayanus*), has been classed as Vulnerable, in the endangered category on the IUCN red list of threatened species. Habitat destruction is causing these bears to live in smaller and more isolated patches. The diet of the sun bear consists mainly of invertebrates and fruits buts as omnivores they will eat a wide variety of foods including small vertebrates, such as lizards, birds and turtles, eggs, the young tips of palm trees, nest of bees, berries, roots, shoots, rhizomes and fruits and coconuts (Kynaston, 1995). Bear Specialist Group recommended that the basic research on the Malayan sun bear is the highest priority need (Servheen, 1999). Without such information, the establishment and implementation of scientifically-sound conservation plans is difficult. Therefore, present study was designed to provide information on gross morphological and light microscopic architecture of the spleen, the organ of reticulo-endothelial system.

[1]Department of Veterinary Anatomy and Histology, College of Veterinary Sciences and Animal Husbandry, Central Agricultural University (I), Selesih, Aizawl-796 015, Mizoram, India.

Corresponding Author: P.C. Kalita, Department of Veterinary Anatomy and Histology, College of Veterinary Sciences and Animal Husbandry, Central Agricultural University (I), Selesih, Aizawl-796 015, Mizoram, India. Email: kaliatpc@yahoo.co.in

How to cite this article: Kalita, P.C., Kalita, A., Choudhary, O.P., Doley, P.J., Debroy, S. and Sarkar, R. (2023). Gross Morphological and Light Microscopic Studies of the Spleen of Malayan Sun Bear (*Helarctos Malayanus*). Indian Journal of Animal Research. 57(10): 1293-1295. doi: 10.18805/IJAR.B-4390.

Submitted: 30-12-2020 **Accepted:** 23-03-2021 **Online:** 10-04-2021

MATERIALS AND METHODS

The present study was conducted on the spleen of one Malayan sun bear that was brought for postmortem to the Department of Veterinary Pathology, College of Veterinary Sciences and Animal Husbandry, Central Agricultural University, Selesih, Aizawl, Mizoram. The abdominal cavity of the Malayan sun bear was carefully opened to record the *in situ* relationship of the spleen with various other organs. The spleen was then carefully taken out from the carcass and the samples after doing the gross parameters fixed in 10% neutral buffered formalin for histomorphology. After fixation the tissues were processed for paraffin sectioning as per the method described by Luna (1968). The paraffin blocks were cut at 6 µ thickness by Leica Semimotorized Rotary Microtome and stained by Harris' haematoxylin and eosin for routine study. The histomorphological

characteristics of the vital organ was observed and interpreted for cellular details with the help of Olympus trinocular research microscope (BX-51) fitted with image analysis software and photomicrography attachment. The photomicrographs of selected slides were taken for typical demonstration.

RESULTS AND DISCUSSION

Gross morphology

The spleen of Malayan Sun Bear was located in the left hypogastric region and entirely intrathoracic as the stomach was almost empty. It was purple in color. The spleen was narrow in the middle and wider at either ends, with the ventral end being the widest and often curled inwards (Fig 1). The dorsal extremity was narrower and deeply curved and was fitted into the crus of the diaphragm while the ventral extremity was wider and its free end lay over the urinary bladder. Such findings were also reported by Crouch (1969), where he reported that in cat the free ventral end of the spleen lies over the urinary bladder. The organ presents parietal and visceral surfaces, with the latter containing the long hilus, which were in accordance to the findings of Konig and Leibich (2009). The parietal surface faces the diaphragm and left lateral abdominal wall. The visceral surface was divided into gastric face and intestinal face by the ridge like hilus. The hilus contains numerous blood vessels.

Light microscopic studies

The spleen of Malayan Sun Bear was surrounded by a thick connective tissue capsule invested by the peritoneum (Fig 2). The capsule consists of two layers; a layer of dense irregular connective tissue and a layer of smooth muscle. Trabeculae composed of collagen and elastic fibers and smooth muscle cells extend from the capsule and the hilus into the parenchyma. The trabeculae contain arteries, veins, lymph vessels and nerves. They tend to be especially large in Malayan Sun Bear (Fig 2). The capsule, trabeculae and reticular fibers support the splenic parenchyma composed of a red pulp involved in the storage of red blood cells and a white pulp rich in lymphocytes and active in immune responses.

Most of the splenic parenchyma is red pulp, owing its name to the vast amount of blood held within the reticular network. The red pulp is composed of venous sinuses or venules and splenic cords (Fig 3). The Malayan Sun Bear spleen has typical venous sinuses. Similar findings were also reported by Dellmann and Eurell (1998) in dogs. The splenic sinuses are wide vascular channels lined with elongated, longitudinally oriented endothelial cells that contain contractile microfilaments aligned in bands parallel and adjacent to the lateral cell margins. Gaps or slits in the sinus wall are created upon contraction of these filaments, thus allowing erythrocytes to migrate from the surrounding splenic cords into the sinus lumen. The lining cells rest on fenestrated basal lamina and are supported by reticular fibers, some of which form hooplike structures encircling the sinus at right angles to the long axis. Openings between endothelial cells in this wall are common. The red pulp stained red because of the large numbers of erythrocytes it contains in its reticular meshwork and blood vessels. A portion of the capillaries of the penicillus becomes surrounded by concentric layers of macrophages contained in a reticular framework. These cellular and fibrous thickening was the ellipsoids (Fig 4). Ellipsoids were especially abundant in the marginal zone. The narrow splenic cords situated between the sinuses form a vast three-dimensional network composed of reticular fibers with enmeshed reticular cells, erythrocytes, macrophages,

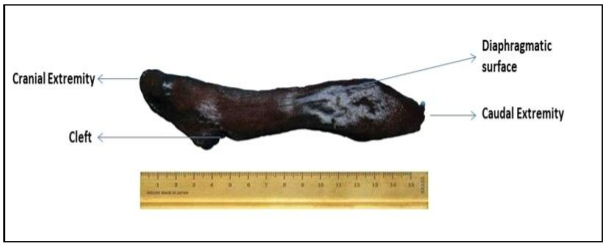

Fig 1: Spleen of Malayan Sun Bear.

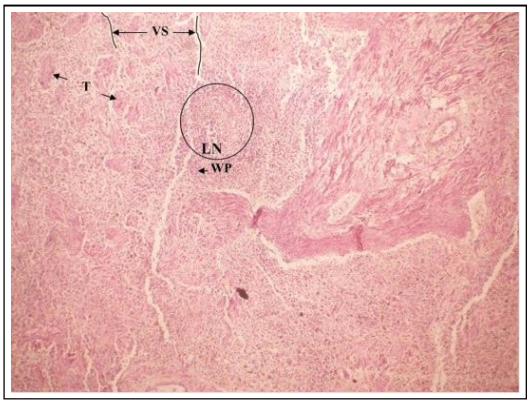

Fig 2: Photomicrograph of spleen of Malayan Sun Bear showing the lymphatic nodule (LN) in the white pulp (WP), trabecula (T) and abundant venous sinus (VS). H&E X100.

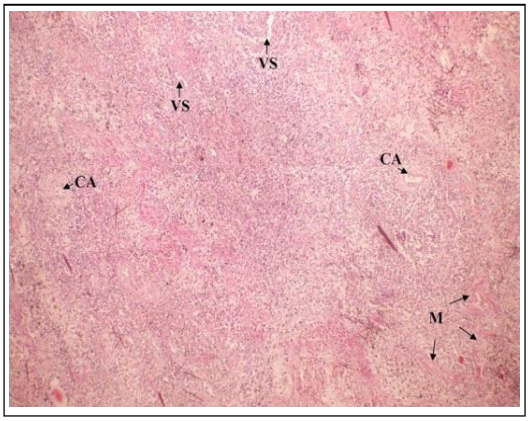

Fig 3: Photomicrograph of Spleen of Malayan Sun Bear showing the central artery (CA) and venous sinuses (VS) and smooth muscle (M). H&E X100.

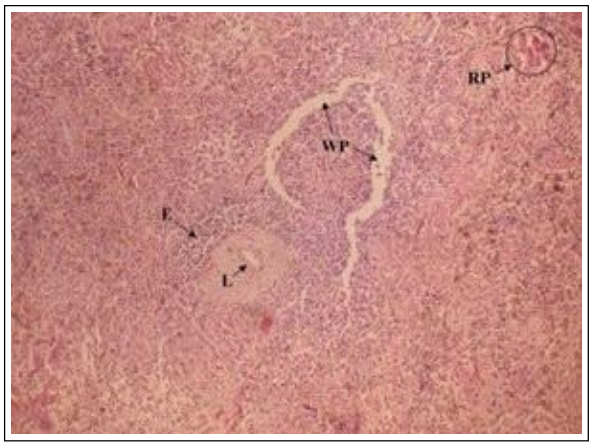

Fig 4: Photomicrograph of Spleen of Malayan Sun Bear. Ellipsoids are especially abundant in the spleen of the Malayan Sun Bear. Each consists of macrophages and reticular fibers that surround a capillary showing ellipsoid (E), capillary lumen (L), white pulp (WP) and red pulp (RP). H&E X100.

lymphocytes, plasma cells and other leukocytes. The membranous processes of the reticular cells tend to form channel-like structures that may function to conduct blood toward the endothelial slits in the sinus walls. Dense accumulations of lymphocytes, arranged around central arteries, form the periarterial lymphatic sheaths (PALS). Lymphatic nodules along with PALS, comprise the white pulp (Fig 2) which is in accordance with the findings of Dellmann and Eurell (1998) in dogs and pigs. Nodules of the white pulp are B-cell zones and may or may not have germinal centers, depending on their functional state. The PALS are organized along the artery of the white pulp. Within the PALS, T cells are concentrated adjacent to the tunica media of the artery, whereas the peripheral region of the sheaths contains a more diverse mixture of T cells and B cells, macrophages, and dendritic cells. Throughout the white pulp, reticular cells and associated reticular fibers form a three-dimensional stroma containing lymphocytes, macrophages and dendritic cells similar to those seen in lymph nodes.

ACKNOWLEDGEMENT

The authors would like to thank the Central Agricultural University, Imphal, India for financial support. The authors are very grateful to Dean, College of Veterinary Sciences and Animal Husbandry, Aizawl, Mizoram, PCCF, Aizawl, Mizoram, Veterinary Officer, Aizawl State Zoo, India for providing the animal as well as permission for the present study.

REFERENCES

Crouch, J.E. (1969). Text-Atlas of Cat Anatomy, Philadelphia, Lea and Febiger.

Dellmann, H.D. and Eurell, J.A. (1998). Immune System. Textbook of Veterinary Histology. 5th Edn. Williams and Wilkins, Baltimore. pp. 128-147.

IUCN. (1996). Red List of Threatened Animals. IUCN, Gland, Switzerland and Cambridge, UK.

Konig, H.E and Liebich, H.G. (2009). Veterinary Anatomy of Domestic Mammals Textbook and Colour Atlas, Schattauer GmbH, Stuttgart, Germany.

Kynaston, P.S. (1995). Bears of the World, Blanford Press.

Luna, L.G. (1968). Manual of Histological Staining Methods of the Armed Forces Institute of Pathology. The Blakiston Division, McGraw Hill Book Co. N.Y. pp. 162-163 and 164.

Nazeri, M., Jusoff, K., Madani, N., Mahmud, A.R., Bahman, A.R., and Kumar, L. (2012). Predictive modeling and mapping of malayan sun bear (*Helarctos malayanus*) distribution using maximum entropy. PLoS ONE. 7(10): e48104. doi:10.1371/journal.pone.0048104.

Peyton, B., Servheen, C. and Herrero, S. (1999). An overview of Bear Conservation Planning and Implementation. IUCN, Gland, Switzerland. Pp: 8-24.

Servheen, C. (1999). Sun Bear Conservation Action Plan. Bears: Status Survey and Conservation Action Plan IUCN, Gland, Switzerland. pp: 219-224.

Servheen, C., Herrero, S. and Peyton, B. (1999). Bears: Status Survey and Conservation Action Plan. IUCN, Gland, Switzerland. pp.309.