RESEARCH ARTICLE Indian Journal of Animal Research, Volume 57 Issue 11: 1544-1549 (November 2023)

Clinical Signs, Activity Indices and Prognostic Indicators in Dogs with Idiopathic Inflammatory Bowel Disease

M. Sandhya Bhavani[1], S. Kavitha[2], S. Vairamuthu[2], K. Vijayarani[2], Abid Ali Bhat[2]

10.18805/IJAR.B-4399

ABSTRACT

Background: Canine inflammatory bowel disease (IBD) includes a set of diseases characterized by the presence of recurrent gastrointestinal clinical signs and histologic evidence of intestinal inflammation. Diagnosis can only be made by excluding other possible causes of enteritis. Since the diagnosis of this disease is of great challenge to the veterinarians and currently very little work have been carried out in India, the present study was planned and conducted to study the clinicopathological changes and prognostic indicators of idiopathic inflammatory bowel disease (IBD) in dogs.

Methods: After a detailed clinical, laboratoty and endoscopic examination, 33 IBD dogs with signs of chronic gastrointestinal disorders and histologic evidence of mucosal lymphocytic plasmacytic infiltration were selected for the study.

Result: Moderate to severe form of IBD with haematochezia as a chief complaint was predominantly recorded. Haematobiochemical changes were not remarkable except a rise in serum alkaline phosphatase level. Decreased IgA expression was observed in serum by flowcytometry indicating impaired mucosal immunity in IBD dogs. It was observed that, increased clinical inflammatory bowel disease activity index score (CIBDAI), increased C-Reactive Protein, decreased cobalamin and folate may act as negative predictors in idiopathic IBD.

Key words: Canine, CIBDAI, IBD, Prognostic indicators.

INTRODUCTION

Inflammatory bowel disease (IBD) has been an important topic of discussion and research in canine gastroenterology for more than 20 years. IBD has been stated to be the most common cause of chronic gastrointestinal signs in dogs. A thorough workup of the patient should be performed in order to rule out many other diseases that may cause intestinal inflammation. Once a diagnostic exclusion protocol has been carried out, gastrointestinal endoscopy with intestinal biopsy is the diagnostic test of choice. Definitive diagnosis ultimately depends on documentation of histopathologic changes in the biopsy specimens (Garcìa-Sancho *et al.*, 2007). Since the diagnosis of this disease is of great challenge to the veterinarians and currently very little work have been carried out in India, the present study was planned and conducted to study the clinicopathological changes and prognostic indicators of idiopathic inflammatory bowel disease (IBD) in dogs.

[1]Department of Clinics, Madras Veterinary College, Tamil Nadu Veterinary and Animal Sciences University, Chennai-600 007, Tamil Nadu, India.

[2]Department of Veterinary Clinical Medicine, Madras Veterinary College, Tamil Nadu Veterinary and Animal Sciences University, Chennai-600 007, Tamil Nadu, India.

Corresponding Author: M. Sandhya Bhavani, Department of Clinics, Madras Veterinary College, Tamil Nadu Veterinary and Animal Sciences University, Chennai-600 007, Tamil Nadu, India. Email: sanjuri02@gmail.com

How to cite this article: Bhavani, M.S., Kavitha, S., Vairamuthu, S., Vijayarani, K. and Bhat, A.A. (2023). Clinical Signs, Activity Indices and Prognostic Indicators in Dogs with Idiopathic Inflammatory Bowel Disease. Indian Journal of Animal Research. 57(11): 1544-1549. doi: 10.18805/IJAR.B-4399.

Submitted: 11-01-2021 **Accepted:** 01-04-2021 **Online:** 21-05-2021

MATERIALS AND METHODS

Clinical cases and control

Out of total no of 30,535 dogs presented to the Small Animal Medicine Out-Patient Unit of Madras Veterinary College during the study period (2014 to 2016), 67dogs with history and signs of chronic gastrointestinal disorders and no response to previous antibiotic therapy were selected for this study. Detailed clinical examination, laboratory examination (haematology, serum biochemistry and faecal analysis) and pancreatic elastase 1 ELISA test were carried out. Six out of 67 dogs diagnosed to have exocrine pancreatic insufficiency based on pancreatic elastase 1 ELISA test and were excluded from the study. In the remaining 61 cases, endoscopy was performed in 49 cases only based on owner's consent. Gastroduodenoscopy and colonoscopy were performed with Veterinary Video endoscope, Karl Storz type No. 60914 PKS (Germany). Four to five representative biopsy samples were taken using pinch biopsy forceps and samples were processed for histopathological examination and interpretation. The characterization of the histologic changes in the endoscopic biopsy samples was performed according to the histopathologic standards established by the WSAVA Gastrointestinal Standardization Group (Washabau *et al.,* 2010).

Lymphocytic plasmacytic infiltration was evident in all the 49 cases. However, four cases were excluded due to infestation of *Trichuris vulpis* which was evident only after colonoscopic procedure as faecal examination was negative. Four dogs with rectal polyp (2), intestinal lymphoma (1) and foreign body (1) were also eliminated. Further eight dogs positive for *Helicobacter spp*. from intestinal biopsy samples by PCR were excluded. 33 dogs without any underlying etiology were taken up for the study.

The control group consisted of ten apparently healthy brought for routine health check up and vaccination. Owners of the control dogs voluntarily consented to be part of the study.

Clinical activity indices and fecal scoring

Faecal consistency score was carried out as per Westermarck *et al.* (2005).

Specialized serum diagnosis

Quantitative estimation serum CRP, cobalamin and folate were done with C-Reactive Protein kit (Biosystems, Cat No.13921, Barcelona) using A15 Biosystems analyser (Biosystems S.A., Barcelona), canine cobalamin ELISA kit (Bioassay Technology Laboratory, Cat No. E0265Ca, China) and canine folate ELISA kit (Bioassay Technology Laboratory, Cat No.E0264Ca, China) respectively.

Flowctometry

The frequency of IgA+ CD21+ PBMCs from fresh EDTA blood samples was examined by flow cytometry. PE-conjugated mouse monoclonal antidog CD21 antibody (1:10) and a FITC-conjugated goat polyclonal antidog IgA antibody (1: 100) were used for staining the cells. The data were processed by FlowJo software.

Statistical analysis

All data are expressed as the mean plus or minus the standard error of the mean. A P value < .05 was considered significant. For correlation data was analysed by Pearson correlation coefficient.The data obtained in the study were subjected to statistical analysis using SPSS 23.0 and were discussed.

RESULTS AND DISCUSSION

Incidence of IBD in the present study was found to be 0.1 per cent (33 dogs) out of 30,535 diseased dogs presented to the Small Animal Medicine Unit with various ailments. However, Arslan (2017) stated that there is no information about incidence for IBD in dogs and cats. This is because, characterisation of many cases remains incomplete and detailed histopathological criteria for the medical diagnosis are needed.

Though there is no apparent age or gender predisposition, IBD is most commonly seen in middle aged and male dogs (Volkmann *et al.,* 2017). Similarly, in our study 5-10 years of aged male dogs (25/33) were affected. However, the reason for highest prevalence in male dogs might be due to over representation of population and owners preference for male dogs.

The documentation of various breeds such as Non-descript (10/33), German shepherd (8/33), Labrador (5/33), Doberman (4/33), Rottweiler (1/33), Pug (1/33), Lhasapso (1/33) and Dachshund (1/33) in the study well correlated with previous studies (Volkmann *et al.,* 2017; Heilmann *et al*., 2018). The high incidence of IBD recorded in non-descript in the present study might be due to over representation of this breed in the study area. It is interesting that two indigenous breeds of Tamil Nadu *viz* Rajapalayam and Combai were also documented to have IBD. There is no published data so far that these breeds are affected or predisposed to IBD and future studies should aimed to do research on native breeds.

Clear history is crucial in directing the investigation in diagnosing IBD due to the waxing and waning nature of the disease. Haematochezia (11/33), diarrhoea (7/33) and vomiting (7/33) recorded as major presenting signs in our study were in accordance with Heilmann *et al.* (2018). Further, the clinical signs were present for 3 months prior to diagnosis. This delay in the diagnosis of IBD in our study might be due to the owner's negligence and ignorance towards the disease. The dogs were presented to the hospital only when gastrointestinal signs were severe as the disease progressed. This was further supported by weightloss (6/33) and altered appetite (10/33) reported in the study which refers to the severity of the disease. Pica or altered appetite reported in the study can be an important sign as Hall and German (2010) opined that the dogs eating grass can be significant signs even in the absence of other signs.

Clinical signs associated with canine inflammatory bowel disease are primarily gastrointestinal symptom (Roth-Walter *et al*., 2017). They comprise vomiting, small bowel diarrhoea (loose-watery or melena), large bowel diarrhoea (tenesmus, fresh blood /mucus and urgency), anorexia, weight loss, flatulence and borborygmus and abdominal

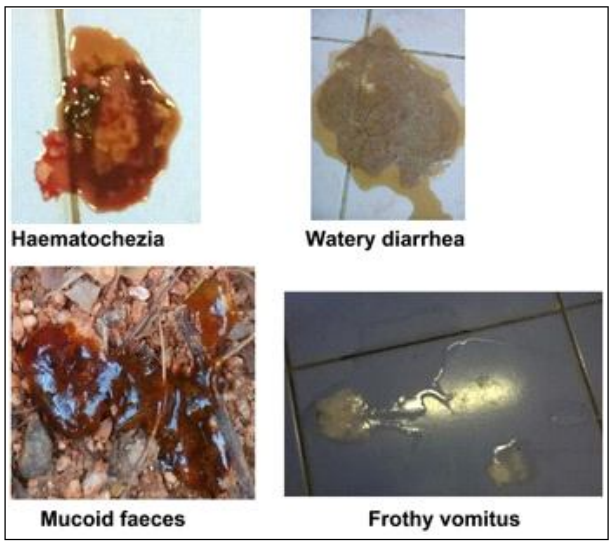

Fig 1: Clinical signs.

pain. Similarly, in our study tenesmus combined with haematochezia and mucoid faeces (11/33), vomiting and diarrhea (8/33), watery diarrhoea alone (5/33), vomiting alone (4/33), haematochezia (2/33), melena (3/33), thickened intestinal loops (3/33), weight loss and emaciation (10/33) were recorded (Fig 1). The fecal scoring of 4.5 (very soft) to 5 (very watery diarrhoea) recorded in our study was comparable with the study of Westermarck *et al.* (2005) (Fig 2).

Clinical indices utilize scoring systems derived from GI signs alone (CIBDAI) or in combination with laboratory testing (CCECAI) to quantify intestinal activity. CIBDAI and CCECAI supports a preliminary classification of the severity of inflammatory changes, enabling the selection of the appropriate therapy, treatment monitoring and early relapse detection (Jergens *et al.,* 2003 and Allenspach *et al.,* 2007). Disease severity based on CIBDAI and CCECAI scores was indicative of moderate IBD in our study. The median CIBDAI score was 7 (range 5-13) and the affected cases were classified as mild (3/33), moderate (18/33) and severe disease (12/33). The CCECAI score was 8 (range 4-13) and was classified as mild (4/33), moderate (17/33), severe (10/33) and very severe (2/33) (Fig 3). Similarly, Heilmann *et al.* (2018) recorded moderate form IBD in his study. CCECAI helps to detect whether IBD has progressed to Protein losing enteropathy (PLE) (Dossin and Lavoue, 2011). In the present study serum albumin levels of the IBD dogs were normal. Even though ten dogs had hypoalbunemia, they had only mild decrease. Further there were no signs of ascites or pedal edema in the affected IBD dogs. This indicates that the IBD dogs in this study have not progressed to PLE.



Fig 2: Faecal scoring.

The Mean S.E values of routine and special blood parameters of control and IBD dogs are given in Table 1. Haematological analysis revealed decreased haemoglobin and packed cell volume with no significant change in the total erythrocyte count. Anaemia (decreased haemoglobin, packed cell volume and total erythrocyte count) was observed in three IBD dogs. Leukocytosis, neutrophilia and monocytosis were the other change recorded. These changes were comparable with Ristic and Stidworthy (2002). They suggested that chronic gastrointestinal blood loss may result in non regenerative iron deficiency anaemia and leukocytosis was related to stress and chronic inflammatory disease.

The biochemical changes such as elevated alkaline phosphatase and mild hypoalbunemia (albumin 1.5-1.99

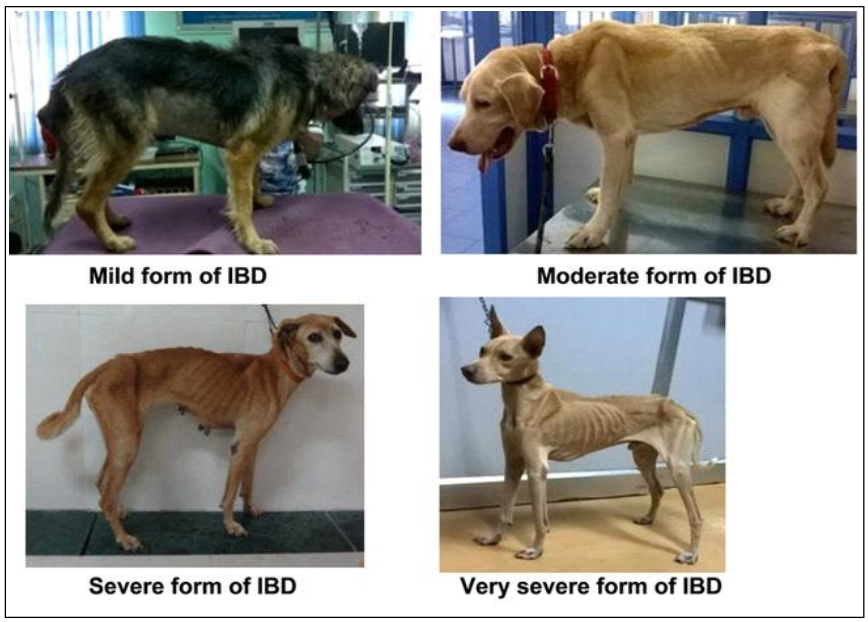

Fig 3: Classification of IBD based on clinical disease activity indices.

g/dL in ten dogs) in the present study were similar to previous studies (Jergens *et al.,* 2010 and Heilmann *et al*., 2018). Elevated alkaline phosphatase may reflect liver damage secondary to the intestinal inflammation and uptake of toxins through the damaged intestinal mucosa and are of no direct consequence (Hall and German, 2010).

Elevated serum CRP levels, reduced serum cobalamine values and hypofolataenemia of IBD dogs were similar to previous studies by Jergens *et al.* (2010) and Heilmann *et al.* (2018). Definite hypocobalanemia was seen only in 10 cases while other IBD dogs had values within the normal range (normal range 225-860 ng/l). Serum concentration

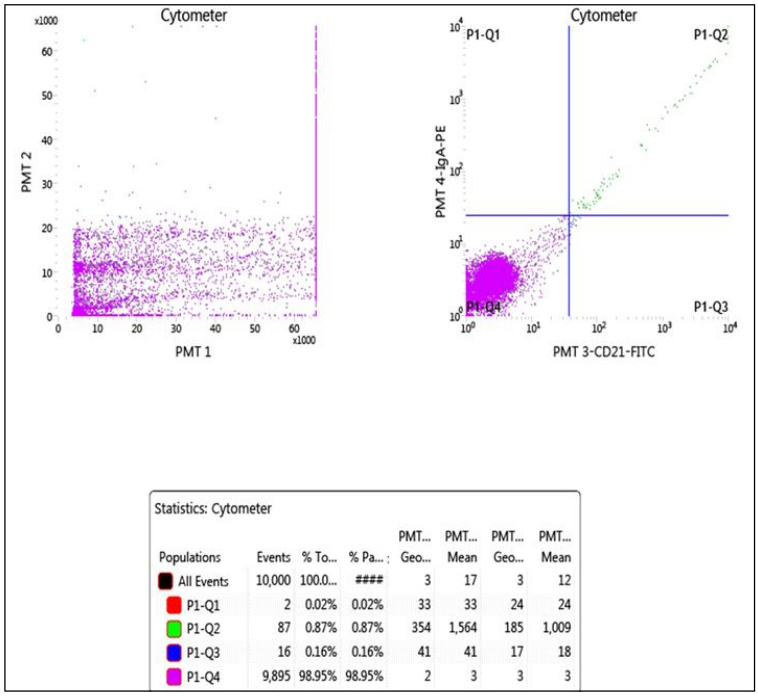

Representative result of the expression of IgA and CD21 on PBMCs**- lower range**

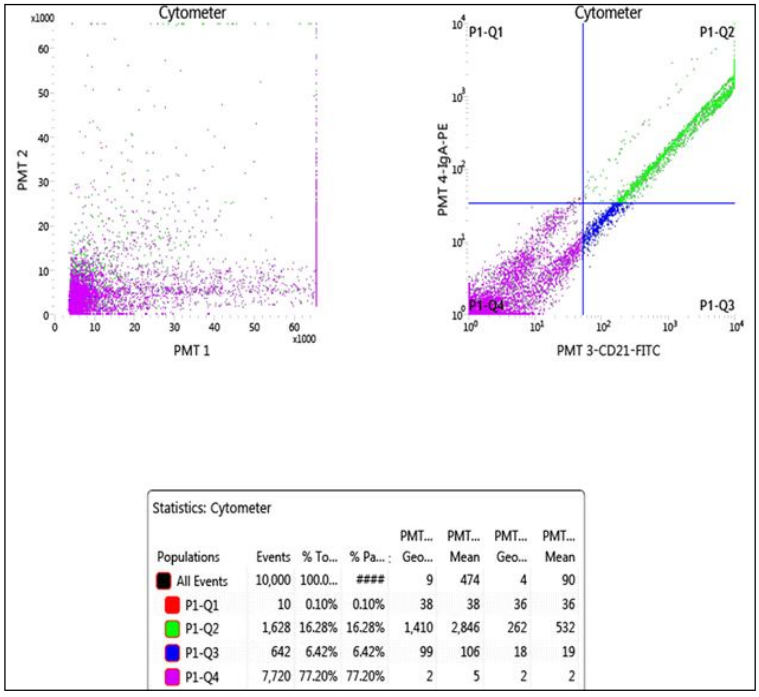

Representative result of the expression of IgA and CD21 on PBMCs**- higher range**

Fig 4: Flowcytometry— Expression of IgA and CD21 on PBMCs- IBD dogs.

Table 1: Mean±S.E values of haematological and serum parameters in dogs with IBD.

Parameters	Group I - Control (n = 10)	Group II - IBD (n = 33)	t value
Haemoglobin (g/dl)	13.13±0.36	10.35±0.44	3.392**
PCV (per cent)	37.66±1.74	31.22±1.11	2.872*
Total erythrocyte ($\times10^6$/cumm)	5.39±0.25	5.04±0.21	0.885^{NS}
Total leukocyte ($\times10^3$/cumm)	8.03±0.41	13.56±1.2	-2.564*
Neutrophils ($\times10^3$/cumm)	5.75±0.29	10.76±1.02	-2.63*
Lymphocytes($\times10^3$/cumm)	1.84±0.16	2.20± 0.20	-0.97 ^{NS}
Monocytes ($\times10^3$/cumm)	0.17±0.03	0.41±0.03	-3.75**
Eosinophils ($\times10^3$/cumm)	0.18±0.06	0.25±0.03	-1.12 ^{NS}
Serum alkaline phosphatase (IU/L)	86.40±6.70	243.64±29.62	-2.891*
Alanine aminotransferase (IU/L)	46.60±5.84	61.15±8.09	-0.960 ^{NS}
Total protein (g/dl)	6.68±0.13	6.60±0.14	0.300 ^{NS}
Albumin (g/dl)	2.4±0.14	2.29±0.09	0.778 ^{NS}
CRP (mg/dl)	2.76±0.38	24.39±2.48	-4.758**
Cobalamin (ng/L)	0661.94±38.55	408.86±37.58	3.522**
Folate (µg/L)	6.43±0.72	2.36±0.32	5.832**

**- Statistically highly significant (P<0.01); *- Statistically significant (P<0.05); NS- Statistically non significant (P>0.05).

levels of cobalamin and folate can allow for localization of the inflammation. Serum levels decreased together can indicate malabsorption and, thus, be a marker for inflammation while either hypocobalaminemia or hypofolatasemia are consistent with distal or proximal small intestinal disease respectively (Berghoff and Steiner, 2011). In our study eventhough the IBD dogs showed signs of colitis (haematochezia), the decrease in cobalamin and folate indicated the involvement of small intestine which was also evident in histopathology.

The proportion of IgA+ CD21+ PBMCs was significantly lower in dogs with IBD (median 4.59%, range 0.87-16.28%) compared to control animals (median 31.44 %, range 22.44-46.67%) (Fig 4) which was similar to Maeda *et al*. (2013). This may due to a failure of IgA class switching.

CIBDAI was correlated with CRP and cobalamin and was found that it had significant positive correlation with serum CRP and significant negative correlation with serum cobalamin. Jergens *et al*. (2003) stated that CRP was described as a marker of disease severity in dogs with chronic enteropathies, because serum CRP concentrations were indirectly correlated with CIBDAI and histologic scoring. He stated that as the severity of the disease increased decrease in the serum cobalamin values was observed. Mucosal disease in the ileum commonly reduces expression of the cobalamin + intrinsic factor complex receptor. This in turn, reduces the mucosal uptake of cobalamin in the ileum, leading to a reduced serum cobalamin concentration.

In the present study three dogs died and were observed to have diffuse IBD with very severe form of disease. Jergens *et al*. (2003) recorded the death of dogs having severe intestinal disease. Further these dogs in our study had elevated CRP, decreased cobalamin and folate. Jergens (2004) opined C-reactive protein has consistently been found to be the most useful disease activity marker for IBD in human patients. Allenspach *et al.* (2007) has shown that serum cobalamin also is very important for prognosis in dogs with chronic enteropathies and low serum cobalamin is also been correlated with a poor prognosis in dogs with chronic enteropathy. Allenspach (2013) opined that if serum concentration of cobalamin is below the reference interval, the risk for later euthanasia increases by a factor of 10. Batt (2009) suggested that decreased serum cobalamin can be indicative of distal small intestinal damage and when accompanied by low serum folate, is suggestive of diffuse and potentially relatively severe disease affecting the proximal and distal small intestine ones. Hence, from the present study it was concluded that CIBDAI, serum levels of CRP, cobalamin and folate could be used as prognostic indicator.

CONCLUSION

In summary, clinical signs associated with canine inflammatory bowel disease are primarily gastrointestinal symptom. CIBDAI supports a preliminary classification of the severity of inflammatory changes. Increased CIBDAI score, increased CRP, decreased cobalamin and folate may act as negative predictors in idiopathic IBD.

REFERENCES

Allenspach, K., Wieland, B., Grone, A. and Gaschen, F. (2007). Chronic enteropathies in dogs: Evaluation of risk factors for negative outcome. Journal of Veterinary Internal Medicine. 21: 700-708.

Allenspach, K. (2013). Diagnosis of small intestinal disorders in dogs and cats. Veterinary Clinics of North America: Small Animal Practice. 43: 1227-1240.

Arslan, H.H. (2017). Inflammatory bowel disease and current treatment options in dogs. American Journal of Animal and Veterinary Sciences. 12(3): 150-158.

Batt, R. (2009). Laboratory diagnosis of intestinal disease in dogs and cats. Veterinary Focus. 19: 10-19.

Berghoff, N. and Steiner, J.M. (2011). Laboratory tests for the diagnosis and management of chronic canine and feline enteropathies. Veterinary Clinics of North America: Small Animal Practice. 41: 311-328.

Dossin, O. and Lavoue R. (2011). Protein-losing enteropathies in dogs. Veterinary Clinics of North America: Small Animal Practice. 41: 399-418.

Garcìa-Sancho, M., Rodriguez-Franco, F., Sainz, A., Mancho C. and Rodriguez, A. (2007). Evaluation of clinical, macroscopic and histopathologic response to treatment in nonhypoproteinemic dogs with lymphocytic-plasmacytic enteritis. Journal of Veterinary Internal Medicine. 21: 11-17.

Hall, E.J. and German, A.J. (2010). Diseases of the Small Intestine. In: Textbook of Veterinary Medicine-Diseases of the Dog and the Cat, [Ettinger, S.J. and E.C. Feldman (eds)]. 7thed, Saunders, Philadelphia. pp: 1526-1572.

Heilmann, R.M., Berghoff, N., Suchodolski, J.S. and Steiner, J.M. (2018). Association of faecal calprotectin concentrations with disease severity, response to treatment and other biomarkers in dogs with chronic inflammatory enteropathies. Journal of Veterinary Internal Medicine. 32: 679-692.

Jergens, A.E., Schreiner, C.A., Frank, D.E., Niyo, Y., Ahrens, F.E., Eckersall, P.D., Benson, T.J. and Evans, R. (2003). A scoring index for disease activity in canine inflammatory bowel disease. Journal of Veterinary Internal Medicine. 17: 291-297.

Jergens, A.E. (2004). Clinical assessment of disease activity for canine inflammatory bowel disease. Journal of the American Animal Hospital Association, 40(6): 437-445.

Jergens, A.E., Crandell, J., Morrison, J.A., Deitz, K., Pressel, M., Ackermann, M., Suchodolski, J.S., Steiner, J.M. and Evans, R. (2010). Comparison of Oral Prednisone and Prednisone Combined with Metronidazole for Induction Therapy of Canine Inflammatory Bowel Disease: A Randomized-Controlled Trial. Journal of Veterinary VInternal Medicine. 24: 269-277.

Maeda, L., Ohno, N., Fujino, Y. and Tsujimoto, H. (2013). Decreased Immunoglobulin A concentrations in faeces, duodenum and peripheral blood mononuclear cells of dogs with inflammatory bowel disease. Journal of Veterinary Internal Medicine. 27: 47-55.

Roth-Walter, F., Berger, S. and Luckschander-Zeller, N. (2017). Inflammatory Bowel Disease in Humans, Pets and Horses. In: Comparative Medicine. [Jensen-Jarolim, E. (eds)]. Springer, Cham. pp: 47-69.

Ristic, M.E. and Stidworthy, M.F. (2002). Two cases of severe iron-deficiency anaemia due to inflammatory bowel disease in the dog. Journal of Small Animal Practice. 43: 80-83.

Volkmann, M., Steiner, J.M. and Fosgate, G.T. (2017). Chronic diarrhoea in dogs-retrospective study in 136 cases. Journal of Veterinary Internal Medicine. 31: 1043-1055.

Washabau, R., Day, M., Willard, M., Hall, E.J., Jergens, A.E., Mansell, J., Minami, T. and Bilzer, T.W. (2010). ACVIM Consensus statement: Endoscopic, biopsy and histopathologic guidelines for the evaluation of gastrointestinal inflammation in companion animals. Journal of Veterinary Internal Medicine. 24: 10-26.

Westermarck, E., Skrzypczak, T., Harmoinen, J., Steiner, J.M., Ruaux, C.G., Williams, D.A., Eerola, E., Sundback, P. and Rinkinen, M. (2005). Tylosin-responsive chronic diarrhoea in dogs. Journal of Veterinary Internal Medicine. 19(2): 177-186.