RESEARCH ARTICLE Indian Journal of Animal Research, Volume 57 Issue 11: 1502-1505 (November 2023)

Morphometrical Studies on the Exterior of the Heart of Pre-natal Non-descript Sheep

S.K. Sahu[1], U.K. Mishra[2], S. Sathapathy[2], S.M. Nanda[1]

10.18805/IJAR.B-4400

ABSTRACT

Background: Heart is the principal organ of circulatory system that pumps blood into the blood vessels and performs many vital functions. Its development before birth must be studied to safeguard the animal from the occurrence and consequences of various developmental anomalies. The detailed morphometry of different external parameters of heart especially in pre-natal sheep has not yet been reported.

Methods: The foeti of sheep were divided into three age groups *viz*. early prenatal (up to 50 days), mid prenatal (51-100 days) and late prenatal (101 to 150 days) with fifteen animals in each age group. The various external parameters were recorded by using digital weighing machine, graduated measuring cylinder, digital Vernier's calliper, non-stretchable nylon thread and graduated scale. The data recorded was statistically analysed by one way ANOVA with IBM SPSS 25.0 version software.

Result: It was revealed that the average width of heart at its base was 4.82±0.22 mm, 10.52±0.72 mm and 21.57±1.03 mm in early prenatal, mid prenatal and late prenatal stages respectively. The average dorso-ventral length of left ventricle of heart was measured as 4.82±0.14 mm, 12.07±1.16 mm and 25.58±0.88 mm in early prenatal, mid prenatal and late prenatal stages respectively. The average distance between the left longitudinal groove and cranial border of heart at base was measured as 2.93±0.11 mm, 6.38±0.39 mm and 9.78±0.41 mm in early prenatal, mid prenatal and late prenatal stages respectively. Similarly, the average distance between the right longitudinal groove and cranial border of heart at middle was measured as 1.96±0.09 mm, 5.01±0.34 mm and 8.31±0.50 mm in early prenatal, mid prenatal and late prenatal stages respectively. All these parameters recorded showed significant ($p \leq 0.01$) differences among the ages.

Key words: External morphometry, Heart, Pre-natal, Sheep.

INTRODUCTION

The circulatory system plays a vital role in smooth working of the body of the animal (Jaiswal *et al*., 2017a; Jaiswal *et al*., 2017b and Janqueira and Carneiro, 2005). Heart is the central organ of circulatory system that pumps blood into the blood vessels and performs many vital functions (Sathapathy *et al*., 2013 and Sathapathy *et al*., 2014). The faulty development of heart may result in ectopia cordis, dextrocardia, hypoplasia, *etc*. Very often, these developmental anomalies of the heart cause foetal death and thereby severe economic loss to the farmers. Due to close similarities in many of the systems between the animals and human being, the animals have always become a choice of interest for research purpose, which indirectly help the human being. The detailed morphometry of different external parameters of heart especially in pre-natal sheep has not yet been reported. Hence, the present study has been undertaken to elucidate age wise morphometrical development of heart in prenatal sheep.

MATERIALS AND METHODS

For this study, forty five foeti of either sex of non-descript sheep were collected from the local slaughter houses situated at Laxmisagar and Jadupur, Bhubaneswar during the period from July, 2020 to December, 2020. The adhering amniotic fluid from the body of the foeti was wiped by wet cotton. The crown rump length (CRL) for each foetus was measured in centimetres (cm) with the help of non-stretchable nylon thread and graduated scale. Further, the CRL was placed on the standard CRL-Gestation Age Curve to estimate the approximate age of the foeti in days (Noden and Lahunta, 1985). The collected sheep foeti were divided into three age groups *viz*. early prenatal (up to 50 days), mid prenatal (51-100 days) and late prenatal (101 to 150 days) with fifteen animals in each age group. This is a part of Doctoral research work, where 4 samples were taken in

[1]Department of Veterinary Anatomy and Histology, College of Veterinary Science and Animal Husbandry, Odisha University of Agriculture and Technology, Bhubaneswar-751 003, Odisha, India. [2]Department of Veterinary and Animal Husbandry Extension, College of Veterinary Science and Animal Husbandry, Odisha University of Agriculture and Technology, Bhubaneswar-751 003, Odisha, India.

Corresponding Author: S.K. Sahu, Department of Veterinary Anatomy and Histology, College of Veterinary Science and Animal Husbandry, Odisha University of Agriculture and Technology, Bhubaneswar-751 003, Odisha, India. Email: drsantoshsahu658@gmail.com

How to cite this article: Sahu, S.K., Mishra, U.K., Sathapathy, S. and Nanda, S.M. (2023). Morphometrical Studies on the Exterior of the Heart of Pre-natal Non-descript Sheep. Indian Journal of Animal Research. 57(11): 1502-1505. doi: 10.18805/IJAR.B-4400.

Submitted: 11-01-2021 **Accepted:** 18-02-2021 **Online:** 26-03-2021

each mentioned age group to record the data. The average weight of the hearts of foeti was taken in digital weighing balance and the average volume of the organs was measured in a graduated measuring cylinder by water displacement method (Dahariya *et al.*, 2020). Further, the various external parameters of the heart such as average width, length, circumference, dorso-ventral and cranio-caudal length of atria, dorso-ventral length of ventricles, cranio-caudal width of ventricles at the base, middle and apex of heart and distance between longitudinal grooves and borders of heart were measured by using digital Vernier's calliper. The recorded data were subjected to routine statistical analysis (Snedecor and Cochran, 1994) and one way ANOVA with IBM SPSS 25.0 version software.

RESULTS AND DISCUSSION

The gross morphological parameters were recorded in the hearts of non-descript sheep (Fig 1) in early prenatal, mid prenatal and late prenatal age groups. The average weight of the sheep foetus was measured as 3.33±0.30 g, 109.18±24.75 g and 946.00±100.08 g in early prenatal, mid prenatal and late prenatal stages respectively. Similarly, the average weight of the heart was measured as 0.07±0.01 g, 1.16±0.24 g and 8.40±0.81 g in early prenatal, mid prenatal and late prenatal stages respectively with significant ($p \leq 0.01$) differences between the mid prenatal and late prenatal stages. The present findings were in agreement with the reports of Gupta *et al*. (2018). The average volume of the heart was measured as 0.09±0.01 cc, 1.21±0.26 cc and 8.26±0.70 cc in early prenatal, mid prenatal and late prenatal stages respectively with significant ($p \leq 0.01$) differences between the mid prenatal and late prenatal stages. The present findings were in agreement with the reports of Gupta *et al*. (2018).

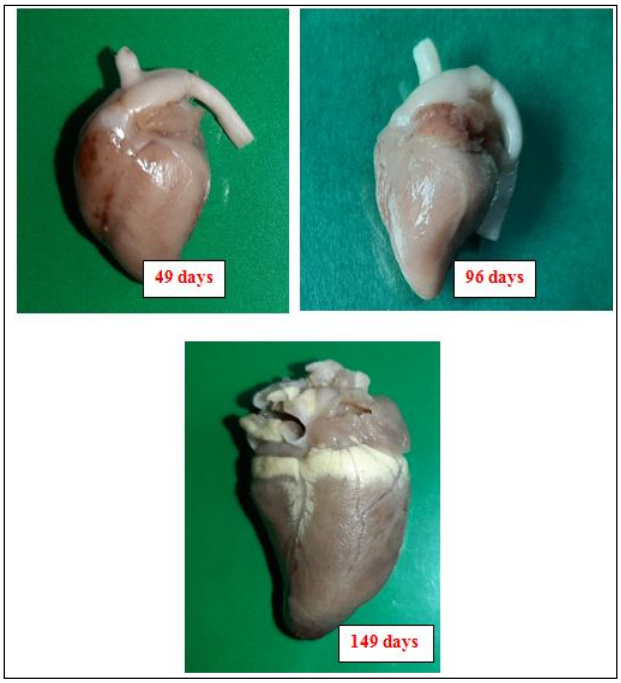

Fig 1: Photograph showing the external morphology of heart of non-descript sheep in early pre-natal (49 days), mid pre-natal (96 days) and late pre-natal (149 days) stages.

The average width of heart at base was measured as 4.82±0.22 mm, 10.52±0.72 mm and 21.57±1.03 mm in early prenatal, mid prenatal and late prenatal stages respectively with significant ($p \leq 0.01$) differences among the ages. Similarly, the average width of heart at the middle was measured as 4.64±0.20 mm, 8.91±0.54 mm and 18.00±1.17 mm in early prenatal, mid prenatal and late prenatal stages respectively with significant ($p \leq 0.01$) differences among the ages. Further, the average width of heart at apex was measured as 4.07±0.19 mm, 6.44±0.38 mm and 10.12±0.71 mm in early prenatal, mid prenatal and late prenatal stages respectively with significant ($p \leq 0.01$) differences among the ages. The present findings were in agreement with the reports of Gupta *et al*. (2018). The average length of heart was measured as 5.78±0.22 mm, 14.46±1.16 mm and 32.62±1.26 mm in early prenatal, mid prenatal and late prenatal stages respectively with significant ($p \leq 0.01$) differences among the ages. The present findings were in agreement with the reports of Gupta *et al*. (2018).

The average circumference of heart at base was measured as 14.51±0.45 mm, 31.78±2.18 mm and 64.02±2.04 mm in early prenatal, mid prenatal and late prenatal stages respectively with significant ($p \leq 0.01$) differences among the ages. Similarly, the average circumference of heart at middle was measured as 13.99±0.43 mm, 30.49±2.18 mm and 55.73±1.72 mm in early prenatal, mid prenatal and late prenatal stages respectively with significant ($p \leq 0.01$) differences among the ages. Further, the average circumference of heart at apex was measured as 12.60±0.34 mm, 28.42±2.21 mm and 21.81±0.87 mm in early prenatal, mid prenatal and late prenatal stages respectively with significant ($p \leq 0.01$) differences among the ages. The present findings were in agreement with the reports of Gupta *et al*. (2018).

The average dorso-ventral length of right atrium of heart was measured as 1.13±0.12 mm, 4.60±0.29 mm and 10.07±0.38 mm in early prenatal, mid prenatal and late prenatal stages respectively with significant ($p \leq 0.01$) differences among the ages. Similarly, the average cranio-caudal length of right atrium of heart was measured as 2.86±0.15 mm, 8.18±0.52 mm and 11.49±0.43 mm in early prenatal, mid prenatal and late prenatal stages respectively with significant ($p \leq 0.01$) differences among the ages. Further, the average dorso-ventral length of left atrium of heart was measured as 2.13±0.13 mm, 4.63±0.29 mm and 10.54±0.43 mm in early prenatal, mid prenatal and late prenatal stages respectively with significant ($p \leq 0.01$) differences among the ages. The average cranio-caudal length of left atrium of heart was measured as 2.83±0.11 mm, 8.22±0.51 mm and 12.33±0.38 mm in early prenatal, mid prenatal and late prenatal stages respectively with significant ($p \leq 0.01$) differences among the ages.

The average dorso-ventral length of right ventricle of heart was measured as 3.91±0.11 mm, 8.06±0.66 mm and

19.27±0.65 mm in early prenatal, mid prenatal and late prenatal stages respectively with significant (p≤0.01) differences among the ages. The average cranio-caudal width of right ventricle of heart at base was measured as 3.64±1.08 mm, 7.87±0.64 mm and 17.31±0.72 mm in early prenatal, mid prenatal and late prenatal stages respectively with significant (p≤0.01) differences among the ages. Similarly, the average cranio-caudal width of right ventricle of heart at middle was measured as 3.53±0.11mm, 6.87±0.62 mm and 14.95±0.64 mm in early prenatal, mid prenatal and late prenatal stages respectively with significant (p≤0.01) differences among the ages. Further, the average cranio-caudal width of right ventricle of heart at apex was measured as 2.35±0.09 mm, 5.78±0.64 mm and 8.71±0.41 mm in early prenatal, mid prenatal and late prenatal stages respectively with significant (p≤0.01) differences among the ages.

The average dorso-ventral length of left ventricle of heart was measured as 4.82±0.14 mm, 12.07±1.16 mm and 25.58±0.88 mm in early prenatal, mid prenatal and late prenatal stages respectively with significant (p≤0.01) differences among the ages. The average cranio-caudal width of left ventricle of heart at base was measured as 4.26±0.11 mm, 7.38±0.58 mm and 17.64±0.73 mm in early prenatal, mid prenatal and late prenatal stages respectively with significant (p≤0.01) differences among the ages. The average cranio-caudal width of left ventricle of heart at middle was measured as 4.03±0.13 mm, 6.92±0.51 mm and 15.08±0.63 mm in early prenatal, mid prenatal and late prenatal stages respectively with significant (p≤0.01) differences among the ages. Similarly, the average cranio-caudal width of left ventricle of heart at apex was measured as 2.75±0.11 mm, 5.94±0.50 mm and 8.79±0.41 mm in early prenatal, mid prenatal and late prenatal stages respectively with significant (p≤0.01) differences among the ages.

The average distance between the left longitudinal groove and cranial border of heart at base was measured as 2.93±0.11 mm, 6.38±0.39 mm and 9.78±0.41 mm in early prenatal, mid prenatal and late prenatal stages respectively with significant (p≤0.01) differences among the ages. Similarly, the average distance between the left longitudinal groove and cranial border of heart at middle was measured as 2.74±0.10 mm, 5.41±0.37 mm and 9.38±0.40 mm in early prenatal, mid prenatal and late prenatal stages respectively with significant (p≤0.01) differences among the ages. Further, the average distance between the left longitudinal groove and cranial border of heart at apex was measured as 2.04±0.12 mm, 4.46±0.38 mm and 5.92±0.43 mm in early prenatal, mid prenatal and late prenatal stages respectively with significant (p≤0.01) differences among the ages. The average distance between the left longitudinal groove and caudal border of heart at base was measured as 3.16±0.11 mm, 6.45±0.39 mm and 12.65±0.53 mm in early prenatal, mid prenatal and late prenatal stages respectively with significant (p≤0.01) differences among the ages.

The average distance between the left longitudinal groove and caudal border of heart at mid was measured as 3.18±0.09 mm, 5.49±0.36 mm and 11.02±0.44 mm in early prenatal, mid prenatal and late prenatal stages respectively with significant (p≤0.01) differences among the ages. Similarly, the average distance between the left longitudinal groove and caudal border of heart at apex was measured as 2.37±0.12 mm, 4.56±0.36 mm and 8.59±0.26 mm in early prenatal, mid prenatal and late prenatal stages respectively with significant (p≤0.01) differences among the ages. The average distance between the right longitudinal groove and cranial border of heart at base was measured as 2.15±0.11 mm, 5.65±0.33 mm and 11.10±0.65 mm in early prenatal, mid prenatal and late prenatal stages respectively with significant (p≤0.01) among the ages. Further, the average distance between the right longitudinal groove and cranial border of heart at middle was measured as 1.96±0.09 mm, 5.01±0.34 mm and 8.31±0.50 mm in early prenatal, mid prenatal and late prenatal stages respectively with significant (p≤0.01) differences among the ages. The average distance between the right longitudinal groove and cranial border of heart at apex was measured as 1.58±0.09 mm, 4.04±0.28 mm and 6.08±0.43 mm in early prenatal, mid prenatal and late prenatal stages respectively with significant (p≤0.01) differences among the ages.

The average distance between the right longitudinal groove and caudal border of heart at base was measured as 1.98±0.09 mm, 5.35±0.29 mm and 9.28±0.55 mm in early prenatal, mid prenatal and late prenatal stages respectively with significant (p≤0.01) differences among the ages. Similarly, the average distance between the right longitudinal groove and caudal border of heart at mid was measured as 1.72±0.11 mm, 4.71±0.31 mm and 8.31±0.43 mm in early prenatal, mid prenatal and late prenatal stages respectively with significant (p≤0.01) differences among the ages. Further, the average distance between the right longitudinal groove and caudal border of heart at apex was measured as 1.24±0.06 mm, 3.85±0.26 mm and 6.38±0.31 mm in early prenatal, mid prenatal and late prenatal stages respectively with significant (p≤0.01) differences among the ages.

CONCLUSION

The various external parameters of the heart recorded in this study showed significant variations (p≤0.01) among different ages in the pre-natal sheep. Further, the present study provided a detailed baseline data on the age wise morphometrical development of heart especially of external parameters in pre-natal sheep that could help in studying various congenital developmental anomalies in different animals.

ACKNOWLEDGEMENT

The authors are grateful to the Dean, CVSc. and A.H., OUAT, Bhubaneswar for providing necessary facilities and support

for the successful completion of this research work within time. The authors are grateful to Dr. S.M. Nanda, MVSc., Department of Veterinary and Animal Husbandry Extension, CVSc. and A.H., OUAT, Bhubaneswar for statistical analysis of the gross morphometrical data.

REFERENCES

Dahariya, N., Sathapathy, S., Mishra, U.K., Patra, R., Dehury, S., Joshi, S.K., Sahu, S.K. and Samal, L. (2020). Gross morphological and biometrical studies on the spleen in various chicken genotypes. Journal of Entomology and Zoology Studies. 8(5): 623-625.

Gupta, S.K., Pathak, A., Farooqui, M.M. and Prakash, A. (2018). Prenatal development of heart of goat (*Capra hircus*): Morphometric observations. Journal of Animal Research. 8(1): 155-162.

Jaiswal, S., Singh, I., Mahanta, D., Sathapathy, S., Mrigesh, M., Pandit, K. and Tamil selvan, S. (2017a). Gross and morphometrical studies on the heart of Uttara fowl. Journal of Entomology and Zoology Studies. 5(6): 2313-2318.

Jaiswal, S., Singh, I., Mahanta, D., Sathapathy, S., Mrigesh, M., Pandit, K. and Tamil selvan, S. (2017b). Histological, histomorphometrical, histochemical and ultrastructural studies on the heart of Uttara fowl. Journal of Entomology and Zoology Studies. 5(6): 2365-2370.

Janqueira, L.C. and Carneiro, J. (2005). Basic Histology Text and Atlas. (11th Edn.), The McGraw-Hill Companies. pp: 245.

Noden, D.M. and Lahunta, A.D. (1985). Embryology of Domestic Animals: Developmental Mechanisms and Malformations. Williams and Wilkins, Berlin, Germany. pp: 2.

Sathapathy, S., Dalvi, R.S., Joshi, S.K. and Singh, M.K. (2014). Biometry of the heart and its vessels in kids of local non-descript goats (*Capra hircus*). Pantnagar Journal of Research. 12(3): 416-418.

Sathapathy, S., Khandate, S.P., Dalvi, R.S., Charjan, R.Y. and Salankar, A.M. (2013). Biometry of the heart and its vessels in young and adult of local non-descript goats (*Capra hircus*). Indian Journal of Veterinary Anatomy. 25(2): 111-112.

Snedecor, G.W. and Cochran, W.G. (1994). In Statistical Methods" (8th Edn.), Oxford and IBH Publishing House. Calcutta, India.