RESEARCH ARTICLE Indian Journal of Animal Research, Volume 58 Issue 2: 271-275 (February 2024)

Efficacy of Silymarin and SAM in the Management of Hepatic Disorders in Dogs

K. Lakshmi[1], K. Padmaja[2]

10.18805/IJAR.B-4410

ABSTRACT

Background: Treatment of canine liver diseases is often supportive and enables combinations of drug therapy and dietary support. Many nutraceutical compounds that have anti-oxidant properties have been suggested as supplements in animals suffering with hepatic diseases especially silymarin and S-adenosyl methionine The current study was aimed to evaluate therapeutic efficacy of certain nutraceuticals in the management of hepatic disorders in dogs.

Methods: Dogs presented to Veterinary Hospital, Bhoiguda, Hyderabad with the clinical signs suggestive of hepatobiliary disorders were selected. Detailed history of the affected dogs was collected. Later, these cases were subjected for detailed clinical examination. While, apparently healthy dogs presented for general health checkup and vaccination with no clinical condition in the age group of 2-5 years were selected randomly as healthy control group for this study.

Result: The present investigation was under taken to study the therapeutic efficacy of certain nutraceuticals in the management of hepatic disorders in dogs. Based on history, clinical signs, haemato biochemistry and ultrasonography, 32 dogs were histologically confirmed as hepatic disorders which formed the largest group. These dogs were selected for therapeutic trial. Apart from the specific drugs, addition of nutraceuticals like Silymarin and S-adenosyl methionine therapy was effective in the treatment of hepatic disorders.

Key words: Dogs, Hepatic disorders, Neutraceuticals, Therapy.

INTRODUCTION

Liver plays a central role in a diverse array of processes including carbohydrate, lipid and protein metabolism; storage of vitamins, trace minerals, fat, glycogen and immune regulation (Cynthia, 2013). Hepatobiliary dysfunctions occur in a number of acute and chronic clinical conditions. Drug-induced hepatotoxicity, infectious diseases, congenital or neoplastic diseases, metabolic disorders, degenerative processes, vascular injury, auto-immune diseases and even blunt trauma may result in hepatobiliary dysfunctions (Kumar *et al*., 2013). Therapy of canine liver diseases enables combinations of drug therapy and dietary support. Hepatobiliary diseases in dogs can be managed with antibiotics, supportive therapy like fluid therapy, nutritional support, anti-oxidants like S-adenosyl methionine (SAMe). Nutritional therapy is provided for hepatic repair and regeneration and to prevent or manage complications of hepatic failure. Nutraceutical compounds especially Silymarin and S-adenosyl methionine containing anti-oxidant properties are suggested as dogs affected with hepatic diseases (Sanderson, 2013).

MATERIALS AND METHODS

The study was conducted on dogs of both genders, aged from 5 months to 14 years, presented to Veterinary Hospital, Bhoiguda, Hyderabad with the history and clinical signs suggestive of hepatobiliary disorders. However, dogs with hepatobiliary disorders due to infectious origin were excluded from the study. Each dog was subjected to detailed clinical, hemato-biochemical and abdominal ultrasonographic studies. Thirty two, dogs that were confirmed for hepatic disorders based on histopathologic changes in the liver tissue as described by Vanden Ingh *et al.,* (2006) were selected for therapeutic trial. Further, these 32 dogs were again divided into two sub groups, a and b with 16 dogs each and were subjected to the following therapeutic regimen with neutraceuticals. Subgroup I a dogs were treated with the Silymarin at the dose of 10 mg/kg orally for 30 days along with necessary supportive drugs and hepatic diet, while, I b dogs were treated with a combination of S-adenosyl methionine and Silymarin at the dose of 1 tablet bid orally for 30 days. The efficacy of treatment was judged based on the improvement in clinical signs, hemato-biochemical parameters to reach normal stage and ultrasonographic evaluation of liver in the respective sub-groups on day 0, 15 and 30.

[1]Department of Veterinary Medicine, College of Veterinary Science, Korutla-505 326, Jagityal, Telangana, India.

[2]Department of Veterinary Medicine, College of Veterinary Science, P.V. Narsimha Rao Telangana Veterinary University, Rajendranagar, Hyderabad-500 030, Telangana, India.

Corresponding Author: K. Lakshmi, Department of Veterinary Medicine, College of Veterinary Science, Korutla-505 326, Jagityal, Telangana, India. Email: drklakshmi1@gmail.com

How to cite this article: Lakshmi, K. and Padmaja, K. (2024). Efficacy of Silymarin and SAM in the Management of Hepatic Disorders in Dogs. Indian Journal of Animal Research. 58(2): 271-275. doi: 10.18805/ IJAR.B-4410.

Submitted: 23-01-2021 **Accepted:** 30-09-2021 **Online:** 27-10-2021

RESULTS AND DISCUSSION

The clinical manifestations in diffuse parenchymal disorders with ascites like abdominal pain, limb edema, vomition, ascites weight gain, respiratory distress, inappetance and anorexia, lethargy and anemia started disappearing early in I b with complete recovery in 5-20 days, while it took 6-22 days for the resolution of clinical signs in I a affected dogs (Table 1) and death was seen in three dogs after initiation of therapy and remaining 13 dogs of sub group I a showed improvement in clinical signs (Fig 1-4).

In the present study, there was a significant increase in the mean levels of hemoglobin, total erythrocyte count and non significant increase in the packed cell volume. While, a significant decrease in the total leucocyte count, neutrophils with no significant change with respect to lymphocytes, monocytes, eosinophils and basophils was observed in both the subgroups after the treatment. Though there was improvement in both the subgroups, the comparative means of hematological parameters of healthy, sub group I a and I b revealed that the treatment given to subgroup I b was more effective (Table 2). These findings were in accordance with Saravanan *et al.* (2014) and Bhadesiya *et al*. (2015), who observed improvement in the hematological parameters after therapy and may be due to the combined effects of hematinics and neutraceuticals.

S-adenosyl methionine (SAMe) is synthesized and degraded in the liver and methionine is actively transported into the liver and converted to SAMe by the enzyme methionine adenosyl transferase, which is impaired in the liver injury and thus SAMe becomes a conditionally essential nutrient. Administration of SAMe in cirrhosis and intrahepatic cholestasis replenishes hepatic GSH reserves, thereby improving their tolerance for free radical and re-perfusion type cell damage (Centre, 2004). Silymarin or Silibinin is a naturally occurring flavanoids extracted from milk thistle (*Silibum marianum*), has shown beneficial effects that includes anti oxidant effect, protective influence on membrane phospholipids, hepatic GSH, hepatocellular regeneration, suppression of fibrogenesis and promotion of fibrolysis (Centre, 2000).

Table 1: Number of days taken for resolution of clinical signs in diffuse parenchymal disorders with ascites affected dogs.

Clinical manifestations	Time taken for disappearance of clinical signs (days)			
	Sub group I a		Sub group I b	
	Range	Mean	Range	Mean
Inappetance and anorexia	10-16	13.0	8-12	10.0
Vomition	7-11	9.0	4-10	7.0
Ascites	6-14	10.0	4-12	8.0
Anemia	20-24	22.0	15-25	20.0
Abdominal pain	4-8	6.0	3-7	5.0
Weight gain	6-14	10.0	4-12	8.0
Lethargy	10-20	15.0	9-13	11.0
Limb edema	6-10	8.0	4-8	6.0
Respiratory distress	6-14	10.0	4-12	8.0



Fig 1: Distended abdomen on day 0 (I a).



Fig 2: Reduced distension of abdomen on day 30 (I a).



Fig 3: Distended abdomen on day 0 (I b).



Fig 4: Reduced distension of abdomen on day 30 (I b).

These findings are in concurrence with Chaudhary *et al.* (2008), who reported that fluid therapy, nutritional support, neutraceuticals, anti emetics, H_2 blockers, diuretics and anti-fibrinolytic drugs can be employed in the therapeutic management of hepatic disorders. Oral supplementation of nutraceuticals like S- adenosyl methionine and milk thistle along with antibiotics in the treatment of chronic hepatitis in dogs has been recommended by Shih *et al.* (2007) and Maddison (2016). Liver support in the form of supplementation with antioxidants like S-adenosyl methionine, milk thistle and vitamin E in dogs had a protective role particularly in inflammatory hepatopathies (Marks, 2012).

In the present study, there was a significant decrease in the mean serum levels of ALT, AST, ALP, GGT, globulin and a non-significant decrease in total bilirubin, direct bilirubin, cholesterol, BUN and creatinine. While, a significant increase

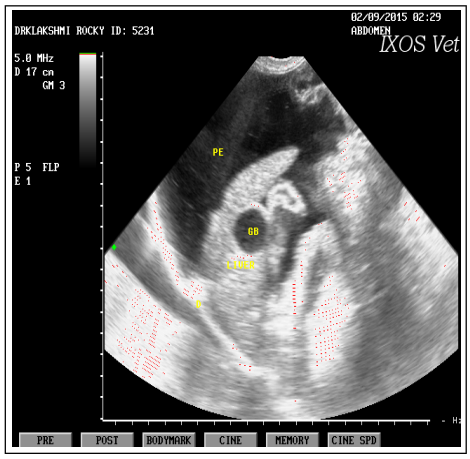

Fig 5: Ultrasonogram of I a - Hyperechoic hepatic parenchyma with peritoneal effusion and cholecystitis on day.

Table 2: Mean hematological findings in healthy and dogs of group Ia and Ib before and after therapy.

Parameter	Healthycontrol	Dogs affected with hepatic diseases			
		I a		I b	
		Before therapy	After therapy	Before therapy	After therapy
Hb (g/dl)	12.92^{c}±0.44	9.07±0.32	10.59^{a}±0.25	8.98±0.26	11.66^{b}±0.22
TEC (×10^{6}/µL)	7.19^{c}±0.23	4.80±0.20	5.91^{a}±0.19	4.46±0.19	6.44^{b}±0.15
TLC (×10^{3}/µL)	8.66^{a}±1.65	26.69±1.28	16.20^{c}±1.11	20.98±0.60	11.19^{b}±0.65
PCV (%)	41.73±1.34	32.44±0.94	36.31±0.75	31.65±0.82	40.36±0.38
Neutrophils (%)	58.98^{a}±2.70	77.54±2.04	63.46^{a}±1.32	82.83±2.20	69.50^{b}±2.33
Lymphocytes (%)	31.90±0.75	16.59±0.60	26.72±0.94	21.59±1.16	28.72±0.68
Monocytes (%)	2.18±0.29	2.66±0.31	2.68±0.27	1.81±0.25	2.63±0.24
Eosinophils (%)	2.50±0.18	1.97±0.31	1.25±0.99	1.93±0.16	1.79±0.15
Basophils (%)	0.48±0.24	0.54±0.12	0.50±0.11	0.46±0.51	0.45±0.11

Means with different alphabets as superscripts differ significantly (P<0.05).

Table 3: Mean of biochemical findings in healthy and dogs of group Ia and Ib before and after therapy.

Parameter	Healthycontrol	Dogs affected with hepatic diseases			
		I a		I b	
		Before therapy	After therapy	Before therapy	After therapy
ALT (U/L)	32.80^{a}±1.60	197.32±35.15	100.39^{c}±8.35	209.06±16.66	70.80^{b}±4.45
AST (U/L)	43.05^{a}±1.22	170.43±35.15	92.57^{c}±6.31	199.27±32.21	75.08^{b}±3.65
ALP (U/L)	59.62^{a}±2.08	271.66±26.62	96.56^{b}±7.99	297.98±25.81	81.17^{b}±4.73
GGT (U/L)	3.04^{a}±0.15	6.54±0.42	5.63^{c}±0.20	6.83±0.96	4.48^{b}±0.32
TB (mg/dl)	0.45±0.03	1.16±0.05	0.89±0.05	1.18±0.07	0.71±0.05
DB (mg/dl)	0.19±0.02	0.62±0.05	0.49±0.03	0.89±0.06	0.34±0.04
Total protein (g/dl)	6.22^{b}±0.03	4.73±0.15	5.76^{a}±0.10	4.81±0.14	6.17^{b}±0.06
Albumin (g/dl)	2.81^{a}±0.07	1.89±0.07	2.11^{b}±0.06	1.82±0.14	2.77^{b}±0.11
Globulin (g/dl)	3.41^{a}±0.07	3.81±0.16	3.73^{b}±0.08	3.99±0.16	3.68^{a}±0.11
Glucose (mg/dl)	108.24^{b}±1.87	93.36±2.28	106.39^{a}±2.90	88.36±1.39	107.69^{b}±1.98
Cholesterol (mg/dl)	166.89±2.28	219.33±21.10	178.01±12.18	238.73±28.19	170.86±13.92
CKMb (U/L)	25.29±0.61	24.88±0.54	26.11±0.94	25.29±0.61	25.45±0.52
BUN (mg/dl)	15.26±0.09	21.33±1.16	17.01±1.08	18.73±0.28	16.86±0.92
Creatinine (mg/dl)	1.08±0.07	1.43±0.16	1.27±0.04	1.81±0.02	1.12±0.02
Sodium (mEq/L)	142.16±0.38	136.81±1.21	141.16±0.59	132.74±2.06	140.15±0.47
Potassium (mEq/L)	4.05±0.04	3.51±0.12	3.95±0.056	3.60±0.12	4.03±0.03
Chloride (mEq/L)	103.12±0.35	97.11±1.40	102.87±0.46	98.63±0.98	102.71±0.38

Means with different alphabets as superscripts differ significantly (P<0.05).

in the mean levels of total protein, albumin, glucose and a non-significant increase in the mean serum levels of sodium, potassium and chloride along with no significant change in CKMb activity was observed in both the subgroups after the treatment. Though, there was improvement in both the subgroups, the comparative means of biochemical parameters of healthy, sub group I a and I b revealed that the treatment given to I b was more effective (Table 3). Decrease in the mean values of ALT, AST, ALP, GGT, globulins, total bilirubin, direct bilirubin, cholesterol, BUN and creatinine after treatment is in agreement with Saravanan *et al*. (2014) and Elhiblu *et al*. (2015). Increase in the mean values of serum electrolytes after treatment was probably due to the supplementation of ions through fluid therapy and normal appetite. These findings were in agreement with Ramprabhu *et al.* (2002).

Ultrasonography on the diffuse parenchymal disorders with ascites affected dogs of the therapeutic trial revealed

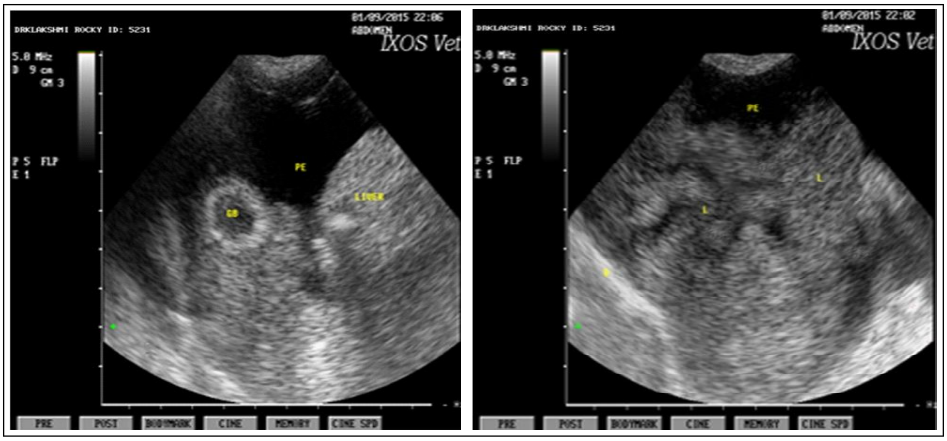

Fig 6: Ultrasonogramof I a - Reduced hyper echogenecity of hepatic parenchyma and peritoneal effusion on day 15 and 30.



Fig 7: Ultrasonogram of I b - Hyperechoic hepatic parenchyma with peritoneal effusion.

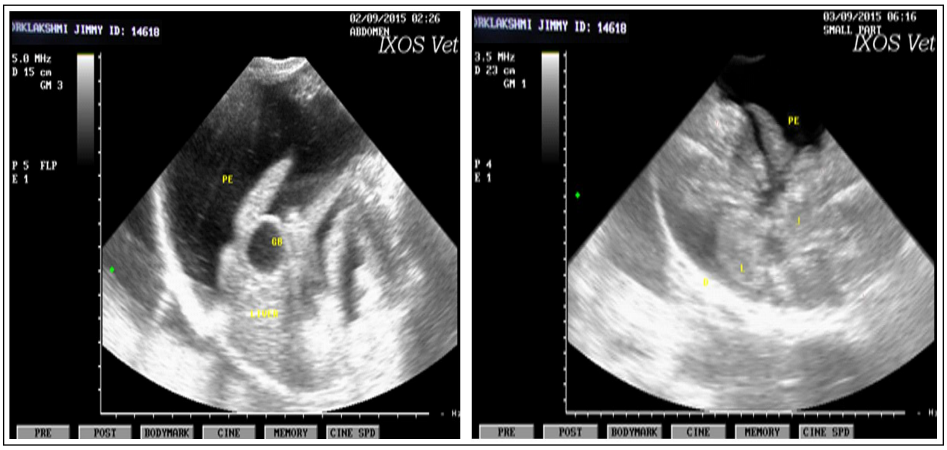

Fig 8: Ultrasonogram of I b - Reduced hyperechogenecity of hepatic parenchyma and peritoneal effusion on day 15 and 30.

Table 4: Ultrasonographic evaluation of liver in dogs affected with hepatic disease on different days.

USG parameters	I a			I b		
	Day 0	Day 15	Day 30	Day 0	Day 15	Day 30
Liver size	+	+	+	+	+	++
Echogenecity	+++	+++	++	+++	++	+
Irregular liver margins	+++	+++	+++	+++	+++	+++
Vascularity (Portal and hepatic veins)	+	+	++	+	++	++
Echotexture	+++	+++	+++	+++	+++	++
Ascites	+++	++	+	+++	+	+

+ : Mild, ++: Moderate, +++: Severe, - : Absent.

hyperchoic liver parenchyma with anechoic ascetic fluid in between the hepatic lobes or in the abdomen on day 0, which showed consistent decline in their severity towards day 15 of therapy and day 30 after therapy in both the I a and I b sub groups (Fig 5-8), although the effect of therapy was more pronounced in I b subgroup compared to I a subgroup (Table 4).

CONCLUSION

Nutraceuticals played an important role in the management of hepatic disorders in dogs. Improvement in the clinical signs, hemato-biochemical and ultrasonographic findings were seen in the dogs, at a faster rate with complete clinical recovery among sub group I b dogs and therapeutic efficacy was significant ($p<0.05$) on both day 15 and day 30, which could be attributed to the combination of S-adenosyl methionine and Silymarin.

Conflict of interset

All authors declared that there is no conflict of interest.

REFERENCES

Bhadesiya, C.M., Jani, R.G., Parikh, P.V., Pandey, A.M., Rao and Shai, A. (2015). Hemato biochemistry and imaging study on ascites with hepatic and cardiac involvement in a German shepherd pup. International Research Journal of Chemistry. 11: 14-22.

Centre, S.A. (2000). Balanced therapy for chronic liver disease. WALTHAM Focus. 10(4): 20-29.

Centre, S.A. (2004). Metabolic, antioxidant, nutraceutical, probiotic and herbal therapies relating to the management of hepatobiliary disorders. Veterinary Clinics of North America Small Animal Practice. 34: 67-172.

Chaudhary, P.S., Varshney, J.P. and Deshmukh, V.V. (2008). Application of ultrasonography, radiography and clinico biochemical profile in the diagnosis of hepatic disease and their clinical management. Intas Polivet. 9(11): 168-176.

Cynthia, R.W. (2013). Weight Loss and Cachexia. In: Text Book of Canine and Feline Gastroenterology, [Washabau, R.J. and Day M.J.], Chapter 24. Elsevier Publishers. pp: 174-176.

Elhiblu, M.A., Dua, K., Mohindroo, J., Mahajan, S.K., Sood, N.K., Dhaliwal, P.S. (2015). Clinico-haemato biochemical profile of dogs with liver cirrhosis. Veterinary World. 8(4): 487-491.

Kumar, M., Mondal, D.B., Saravanan, M. and Sharma, K. (2013). Therapeutic management of hepatobiliary dysfunction in canines. Intas Polivet. 14(1): 117-120.

Maddison, J.E. (2016). Diagnosis of Hepatobiliary Disease in Dogs and Cats. Proceedings of 15th World Small Animal Veterinary Association (WSAVA), 8th Federation of Small Animal Practitioners Associations of India (FSAPA) Continuing Education Programme on Companion Animal Practice. November 11th - 13th 2016 Chandigarh, India: 1-44.

Marks, S.L. (2012). Nutritional Management of Hepatobiliary Diseases. In: TB: Applied Veterinary Clinical Nutrition, [(ed) Fascetti, A.J. and Delaney, S.J.], Chapter 14, Wiley, Blackwell Publishers: 235-250.

Ramprabhu, R., Prathaban, S., Nambi, A.P. and Dhanpalan, P. (2002). Hemorrhagic gastroenteritis in dogs. A clinical profile. Indian Veterinary Journal. 79: 374-376.

Sanderson, S.L. (2013). Nutritional Strategies in Gastro Intestinal Diseases. In: Text Book of Canine and Feline Gasteroenterology. [Washabau, R.J. and Day, M.J. (eds)], Chapter: 32. Elsevier Publishers: 409-428.

Saravanan, M., Mondal, D.B., Sharma, K., Kumar, M., Vijayakumar, H. and Sasikala, V. (2014). Comprehensive study of hematobiochemical ascitic fluid analysis and ultrasonography in the diagnosis of ascites due to hepatobiliary disorders in dogs. Indian Journal of Animal Sciences. 84(5): 503-506.

Shih, J.L., Keating, J.H., Freeman, L.M. and Webster, C.R.L. (2007). Chronic hepatitis in labrador retrievers, clinical presentation and prognostic factors. Journal of Veterinary International Medicine. 21: 33-39.

Vanden Ingh, T.S.G.A.M., Vanwinkle, T., Cullen, J.M., Charles, J.A., Desmet, V.J. (2006). Morphological Classification of Parenchymal Disorders of Canine and Feline Liver. In: WSAVA Standards for Clinical and Histological Diagnosis of Canine and Feline Liver Disease. First edn (WSAVA Liver Standardization Group. ed.), Elsevier Ltd., Oxford: 85-101.