RESEARCH ARTICLE Indian Journal of Animal Research, Volume 58 Issue 5: 827-833 (May 2024)

Evaluation of β-Tricalcium Phosphate Biomaterial in Femur Fracture Repair in Dogs

D.K. Dwivedi[1], R.B. Kushwaha[1], M.S. Bhadwal[1], A.K. Gupta[1], J.S. Soodan[1], H.R. Bhardwaj[1] 10.18805/IJAR.B-4418

ABSTRACT

Background: Fracture repair is one of most common procedure carried out by veterinary clinicians. Fracture healing most of the time associated with delayed union, non-union and mal-uinon. Therefore, the objective of this study was to evaluate the clinical, haemato-biochemical and radiological outcome in patients after implantation of β-tricalcium phosphate as a bone graft substitute to promote the fracture healing.

Methods: Eight clinical cases brought to the clinics with femur fracture were divided into two groups *viz*. A and B, with four animals in each group. Femur fractures were stabilized with intramedullary pinning and β-TCP biomaterial and intramedullary pinning and β-TCP plus autologous bone marrow aspirate (BMA) composite in group A and B respectively. The efficacy of fixation was studied on the basis of clinical evaluation, haemato-biochemical and radiographical parameters on day 0 and on 7th, 15th, 30th, 45th and 60th post-operative day.

Result: Excellent weight bearing was noticed in group B. The overall functional outcome in group B was better in comparison to group A animals. Haematological parameters *viz*. haemoglobin, packed cell volume, total leukocyte count and differential leukocyte count did not differ significantly within and between the groups. The biochemical parameters *viz*. serum calcium increased significantly ($P<0.05$) on 7th and 15th post-operative day. A significant reduction in serum alkaline phosphatase level observed on successive post-operative days in both groups. Radiographs of fractures treated in both the groups showed good reduction and fracture fixation, early signs of fracture healing in group B than group A animals. The size of callus formation was more in group A than group B. No any graft related complications observed during the study period. The β-tricalcium phosphate facilitated fracture healing and early ambulation of affected limb.

Key words: Dog, Femur, Fracture, Intramedullary pinning, TCP.

INTRODUCTION

Fractures of long bones were common orthopaedic problem encountered in dogs (Aithal *et al*., 1999). Among long bones, incidence of femur fracture was higher (Kushwaha *et al*., 2011). Most of these fractures are immobilized by conventional fixation devices like IM Pin, Plating, Screws, cerclage wiring *etc*. Primary objective during fracture treatment is to achieve rigid immobilization of fractured fragments and complete functional recovery of the affected limb as earliest as possible. Since last few decades lot of development took place in fracture repair techniques like use ESF, ILN, Minimal invasive osteosynthesis *etc*. Despite the rapid development of fracture fixation techniques delayed union, maluinon or non-union are common complications associated with fracture healing. Segmental bone loss and non-union fractures of long bones are challenging problems for orthopaedic surgeons (Rao *et al*., 2001). To overcome these complications, research is now more emphasized on role of bone healing enhancers in fracture management. Bone graft, synthetic bone graft materials, composite bone grafts, bone marrow, BMP, TGFs, hydroxyapatite *etc*. were commonly used as bone healing enhancers (Devescovi *et al*., 2008). Bone was the second most frequently transplanted tissue after the blood transfusion in human medicine (Franch *et al*., 2006). Bone graft materials used in segmental bone defect, to enhance healing of fracture with fewer complications. Bone graft materials include Bone: Autograft, Allograft, Biomaterial: DBM, Collagen *etc*., Ceramics: TCP, HA, CPC *etc*. and Composite Grafts: β-TCP+BMA, BMP + Synthetic bone graft. Characteristics of an ideal bone graft material is based on: Osteoconduction, Osteoinduction, Osteogenesis and Osteointegration functions. The Autologous cancellous bone graft was considered as gold standard by which other graft materials were judged (Giannoudis *et al.,* 2005). It provides osteoconduction,

[1]Division of Veterinary Surgery and Radiology, Faculty of Veterinary Science and Animal Husbandary, Sher-e-Kashmir University of Agricultural Sciences and Technology, R.S. Pura, Jammu-181 102, UT of Jammu and Kashmir, India.

Corresponding Author: D.K. Dwivedi, Division of Veterinary Surgery and Radiology, Faculty of Veterinary Science and Animal Husbandary, Sher-e-Kashmir University of Agricultural Sciences and Technology, R.S. Pura, Jammu-181 102, UT of Jammu and Kashmir, India. Email: kumardinesh25@rediffmail.com

How to cite this article: Dwivedi, D.K., Kushwaha, R.B., Bhadwal, M.S., Gupta, A.K., Soodan, J.S. and Bhardwaj, H.R. (2024). Evaluation of β-Tricalcium Phosphate Biomaterial in Femur Fracture Repair in Dogs. Indian Journal of Animal Research. 58(5): 827-833. doi: 10.18805/IJAR.B-4418.

Submitted: 05-02-2021 **Accepted:** 31-05-2021 **Online:** 14-06-2021

osteoinduction and osteogenesis. The drawbacks are limited supply, donor site morbidity, expanded surgical time *etc*. Beta tricalcium phosphate [β-TCP or $Ca_3(PO_4)_2$] is a ceramics and similar to amorphous bone precursors. It had osteoconduction property and more porous than hydroxyapatite and other ceramic (Ozturk *et al*., 2006). Bone marrow contained osteoprogenitor stem cells and able to form bone when combined with other synthetic bone graft materials (Vertenten *et al*., 2010). When combined with osteoconductive scaffold like TCP, HA *etc*., provided a competitive alternative to autograft (Giannoudis *et al*., 2006). The use of these products in Veterinary Orthopaedics as substitute of cancellous bone graft is poorly reported in the literature. Role of these materials in fracture healing in clinical cases need to be evaluated. In view of above, the present study was planned with the objective to compare the efficacy of Beta tricalcium phosphate (β-TCP) with and without autologous bone marrow transplant in healing of femur fractures.

MATERIALS AND METHODS

Eight clinical cases presented to Division of Teaching Veterinary Clinical Complex, SKUAST-Jammu during the period 2014-17 with femur fracture were included in this study (Table 1).

After history taking, clinical examination, haemato-biochemical and radiographical examination, dogs were randomly divided into two groups *viz*. A and B. The animals in group A and B were treated with intramedullary pinning plus beta tricalcium phosphate and intramedullary pinning plus beta tricalcium phosphate plus autologous bone marrow aspirate respectively. In all the cases, open reduction internal fixation (ORIF) was done under Atropine sulphate (@0.044 mg/kg body weight intramuscular route), Xylazine hydrochloride (@2 mg /kg body weight intramuscular route) and Ketamine hydrochloride (@10 mg/kg body weight intramuscular route) anesthesia. Bone marrow (BMA) was collected from iliac crest. β-TCP (1-2 cc) was implanted at the fracture site directly under sterile condition (Fig 1). In all the cases normograde pinning was done through trochanteric fossa except in supracondylar fracture where arthrotomy of stifle joint performed for cross pinning. The post-operative treatment involved Robert Jones bandage application, broad spectrum antibiotic Ceftriaxone (@ 20 mg/kg body weight intravenous route), anti-inflammatory and analgesic (Meloxicam @ 0.2 mg/kg body weight intramuscular route), Serratiopeptidase 5-10 mg orally bid, Ranitidine 150 mg tab., ¼ to ½ tab. orally bid for 5 days alongwith oral supplementation of calcium. The efficacy of

Table 1: Details of cases included in the study.

Group	Breed	Sex	age	Body weight	Type of fracture	Treatment
A	Spitz	M	2.5 m	3.8	Long oblique	Intramedullary Pinning + Beta Tricalcium phosphate (IMP+β-TCP)
	GSD	M	5 m	11.0	Transverse	
	GSD	M	5.5 m	12.5	Transverse	
	Lab.	M	3 m	8.3	Short oblique	
B	ND	M	8 m	12.7	Supracondylar	Intramedullary Pinning + Beta tricalcium phosphate + Autologous bone marrow (IMP+β-TCP+BMA)
	ND	M	2 m	4.2	short oblique	
	ND	M	4 m	6.0	Pathological	
	ND	M	3 m	7.3	Transverse	

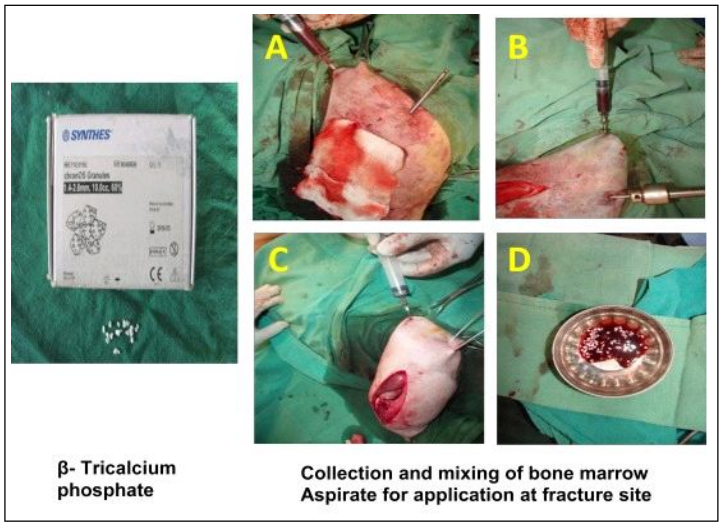

Fig 1: Sterile β-TCP and collection of autologous bone marrow aspirate.

treatment was evaluated on the basis of clinical examination including weight bearing, lameness and pain parameters, haemato-biochemical examination including complete blood count (CBC), serum calcium, serum phosphorus and alkaline phosphatase and lastly the radiographic examination in two orthogonal views. All the parameters were recorded on day 0 *i.e*. operative day or pre-operative day and then on 7th, 15th, 30th, 45th and 60th post-operative days. The degree of weight bearing on affected limb was recorded on a 0-4 scale where 0 means no weight bearing and 4 means maximum weight bearing. The degree of lameness in affected limb was also recorded on 0-4 scale again 0 indicates no any lameness and 4 for maximum lameness. The degree of pain on palpation of affected bone/limb was recorded on 0-4 scale, 0 for no pain and 4 for severe pain. The bio-chemical parameters were evaluated using the commercial kits. The obtained data were analyzed using SPSS programme 20.00 version.

RESULTS AND DISCUSSION

The mean±SE score values of weight bearing on affected limb was significantly lower on day of admission in both the groups. The weight bearing score significantly improved on all the successive post-operative day in both the groups. This may be attributed to application of beta tricalcium phosphate and bone marrow aspirate graft materials at fracture site that might have provided additional support alongwith enhancement of fracture healing rate. Further, the mean weight bearing score values varied non-significantly between group A and B. However, numerically, the weight bearing score was found better in group B animals than group A animals. This may also be attributed to less pain during walking in group B which led to early weight bearing. Tembhurne *et al*. (2010) reported that delay in weight bearing by dogs during fracture healing of femur could be due to the pain and presence of sepsis at trochanteric fossa. The mean±SE score value of lameness on day of admission in group A and B was 3.50±0.27 and 3.75±0.25, respectively. The degree of lameness score on day of admission was severe in both the groups. The mean lameness score in affected limb was significantly reduced on successive post-operative days in both the groups; however, the mean lameness score in the affected limb was significantly reduced and was found better in group B than group A animals. This may be attributed to rigid fixation as well as early reduction in swelling alongwith less post-operative complications in these animals. Ijaz *et al*. (2014) also observed prolonged period of lameness in animals with more post-operative complications during the treatment of femoral diaphyseal fracture in dogs using limited contact dynamic compression plate and dynamic compression plate. In both the groups, the mean±SE value of degree of lameness did not come to normal by the end of the study period, indicating that some degree of lameness was present in few cases of each group, probably due to presence of pin in medullary cavity eliciting pain while the dogs attempted to walk. The mean±SE score value of pain on palpation at fracture site was significantly higher on pre-operative day but significantly reduced during the successive post-operative days in both the groups. The initial severe pain could be attributed to initiation of fracture induced inflammatory process. The mean pain score was numerically found less in group B animals on 60th post-operative day during the present study. This may be due to slow healing of fractured bone in group A animals where simply intramedullary pinning was done and beta tricalcium phosphate was implanted at fracture site. Haematological parameters *viz*. haemoglobin, packed cell volume, total leukocyte count and differential leukocyte count did not differ significantly within and between the groups. The mean±SE values of calcium (mg/dl) in dogs of group A and group B was 9.93±1.71 and 9.21±0.75 respectively. The mean±SE values of calcium was significantly higher on 7th post-operative day in group A animals and a non-significant increase was observed in group B animals. Thereafter, the values fluctuated within normal physiological limits upto 60th post-operative day in both the groups. This initial increase in mean calcium value may be attributed to oral supplementation of calcium advised in all the cases in post-operative period. This may also the manifestation of osteoblastic activity at fracture site. Similar findings were also observed by Bush (1991) and Chaudhari *et al*. (2000). High levels of calcium at different post-operative intervals had also been reported by Hegade *et al.* (2007) and Rani *et al*. (2012). Contrary to this, Soliman and Hasan (1964) and Kumar *et al*. (1992) reported low level of serum calcium during early stages of fracture healing. However, several researchers had reported that there was no correlation between the fracture healing and serum calcium levels (Pandey and Udupa, 1981; Saikia *et al*., 1986 and Chandy, 2000). The mean±SE values of phosphorus (mg/dl) in dogs of group A and group B were 6.22±0.69 and 8.99±2.27, respectively. A non-significant ($P>0.05$) variation was observed in serum phosphorus levels in both the groups till the end of study. The mean±SE values of alkaline phosphatase (U/L) in group A and group B animals were 264.78±49.09 and 243.68±32.91, respectively, which were found higher than the normal reference range. The mean±SE values of alkaline phosphatase level were significantly ($P<0.05$) higher on day of admission and on 7th and 15th post-operative days in both the groups of animals. However, the value was significantly ($P<0.05$) reduced on 30th and successive post-operative days in both the groups. The higher initial values may be due to exuberant proliferation of fibrous tissue at fracture site following bone injury and proliferation of maturing osteogenic cells and active osteoblasts (Umashankar and Ranganath, 2008). The gradual but significant decrease in alkaline phosphatase level after 30th post-operative day may be due to the stabilization provided by the internal fixation device. This finding was in accordance with Singh *et al*. (1976), Chandy (2000), Julie (2005) and Manjunath (2010). The radiographic observations are shown in Fig 2, 3, 4 and 5. In the present study slight mal-alignment of fracture fragments in 2 cases in both the groups was observed, though repositioning was

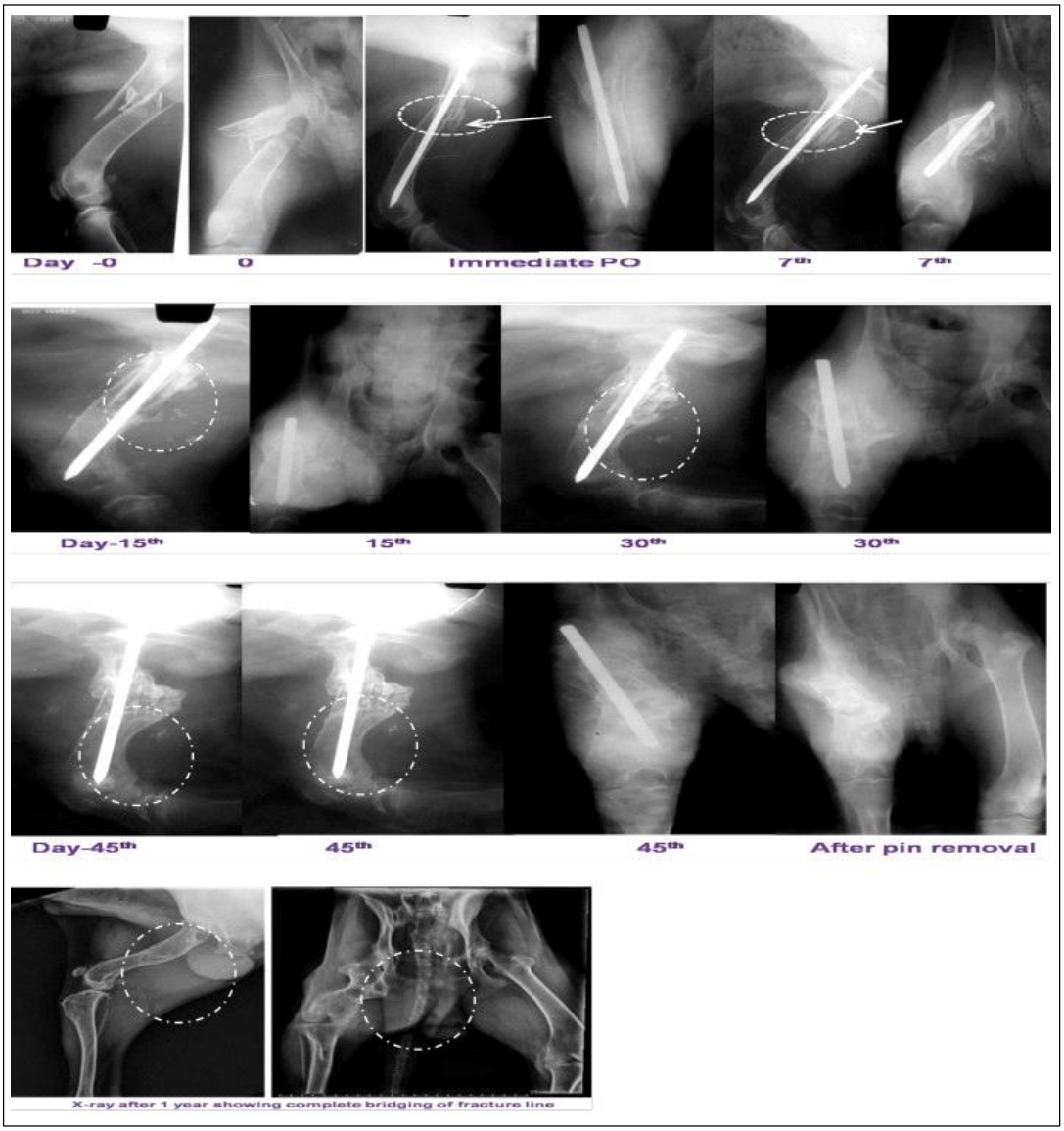

Fig 2: Pre operative and successive post-operative radiograph of group A animal. Immediate post-operative radiograph the β-TCP seen at fracture site. Moderate amount of callus formation seen at fracture site. After 1 year radiograph complete resorption of graft material and the bone remodelled to gain normal trabecular structure.



Fig 3: Pre-operative and successive post-operative radiograph of group A animal showing osseous tissue formation at fracture site and complete healing of fracture on 45th post-operative radiograph as fracture line becomes completely invisible.



Fig 4: Pre-operative and post-operative radiograph showing complete radiographic union of fracture 30th post-operative day as the fracture line becomes invisible in group B animal where β-TCP and bone marrow aspirate combination implanted at fracture site. Minimum amount of periosteal callus formation seen.

not carried out. This slight mal-alignment of fractured fragments was attributed to rotational forces acting on fractured bone. Fossum (2013), reported intramedullary pin could be used to stabilize femoral mid-diaphyseal fractures, providing excellent resistance to bending but not resisting rotational forces or axial loading. In both the groups the graft material appeared radiographically as radiopaque granular structure at fracture site because of its mineral component. The 7th post-operative day in both the groups revealed no evidenced of callus formation and fracture lines were clearly visible. The fracture fragments were in alignment as observed in immediate post-operative radiograph except in one case in group B animal that anatomic loss of reduction. Similar observations were reported by Binnington (1990) and Julie (2005). Disappearance of sharp end of fracture fragments were noticed in both the groups as also reported by Sirin *et al*. (2013). On 15th post-operative day, in both groups, mild callus formation with irregular periosteal reaction at the fracture site was seen and fracture line was clearly visible in group A animals. Fracture lines were not clearly visible in group B animals. In group B animals the fracture lines were partially bridged with white hazy structure that may be due to formation of feathery callus at fracture site. This may be attributed to the effect of composite graft materials that was applied at the fracture site in group B animals. Similar observations were recorded by Binnington (1990) and Julie (2005) indicative of progression of fracture healing. On 30th post-operative day in group A animals moderate amount of unorganised extra-cortical bridging callus formation was observed in 3 cases and in 1 case of stable fracture, almost complete healing of fractured bone was noticed. This might be again attributed to the osteoconductive potential of β-tricalcium phosphate. In group B animals 1 case with supracondylar fracture was almost healed with minimum amount of extra-cortical callus formation and in remaining cases fracture line was partially visible due to progressive fracture healing. Similar observations were noticed by Manjunath (2010). In both the groups the radiographic density of β-tricalcium phosphate was reduced that might be due to bio-resorption of the beta tricalcium phosphate. The 45th post-operative day radiograph showed good apposition of fracture fragments and fracture

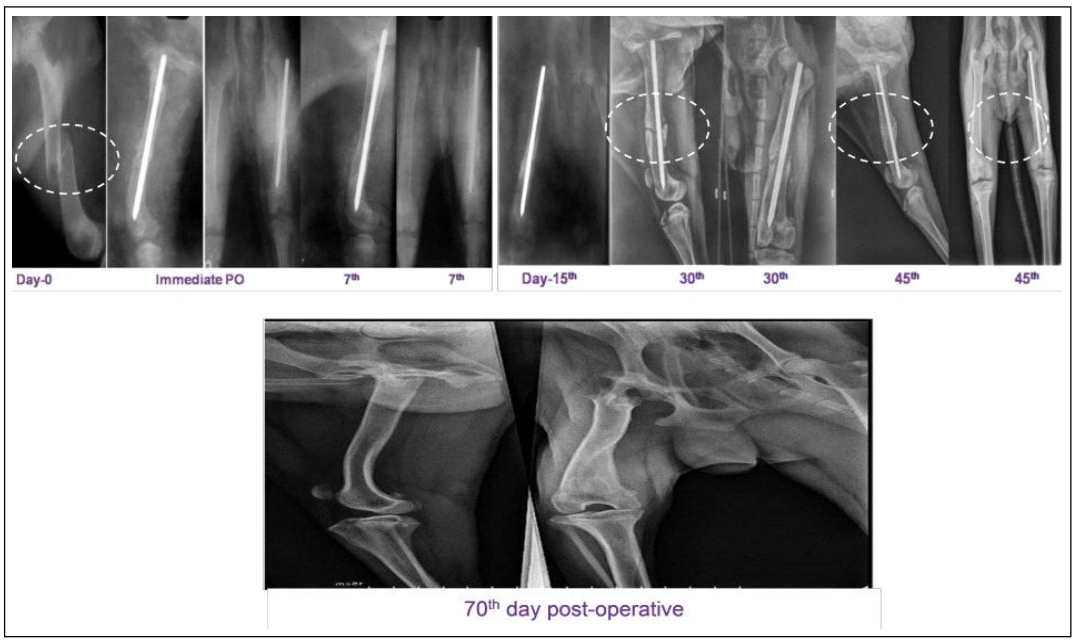

Fig 5: Pre-operative and successive post-operative radiograph showing complete fracture healing by 45th post-operative day with minimum amount of periosteal callus formation.

line was almost invisible in both the groups indicative of fracture healing. Similar observations were recorded by Julie (2005), Raghunath and Singh (2008). In 1 case of group A, animals the size of bridging callus was increased as compared to 30th post-operative radiograph. That might be correlated with the rigidity of fracture fixation. On 60th post-operative day radiograph fracture line was not visible and the cortices of both segments were in line in all the groups. In 1 case in group A bridging occurred by formation of exurbent callus. Parti *et al*. (2011) reported relatively larger sized callus during healing of osteopenic bones in comparison to normal bones fixed with intramedullary Steinmann pin. On the basis of aforesaid findings we may conclude that that the overall outcome of the treatment varied between very good to excellent functionally in both the groups of animals. The overall functional outcome in group B was better in comparison to group A animals. It is postulated that the graft materials applied at fracture site had hasten the healing process.The rate of fracture union was increased when β-TCP was implanted at fracture site. The use of β-TCP plus autologous bone marrow aspirate composite in treatment of femur fractures in dogs is safe and is more effective than β-TCP used alone.

Conflict of interest

All authors declare that they have no conflict of interest.

REFERENCES

Aithal, H.P., Singh, G. R. and Bisht, G. S. (1999). Fractures in dogs: A survey of 402 cases. Indian Journal of Veterinary Surgery. 20(1): 15-21.

Binnington, A.G. (1990). Bone Remodelling and Transplantation, Wittick W.G. (ed), Canine Orthopaedics, 2nd ed. Section III: Preparation, Priciples and Procedures for Surgery. Philadelphia: Lea and Febiger. pp: 166-189.

Bush, B.M. (1991). Interpretation of laboratory results for small animal clinician. Reprint 1998. Blackwell Science Ltd., USA. pp: 94-95.

Chandy, G. (2000). Clinical Evaluation of Stainless Steel and Acrylic External Skeletal Fixators as Adjuncts to Intramedullary Pinning for Fracture of Femur in Dogs. In: Thesis for master in Veterinary Surgery and Radiology Submitted to Post Graduate Faculty of Tamil Nadu Veterinary and Animal Sciences University, Chennai. pp 75.

Chaudhari, M.M., Ganesh, T.N., Archibald David, W.P. (2000). Management of compound tibial fracture using Ilizarov's circular external skeletal fixation in dogs. Clinical and radiological studies. Indian Journal of Veterinary Surgery. 21(1): 39-40.

Devescovi, V., Leonardi, E., Ciapetti, G. and Cenni, E. (2008). Growth factors in bone repair. Chirurgiadegliorgani di movimiento, 92(3): 16-18.

Fossum, T.W. (2013). Fundamentals of Orthopedic Surgery and Fracture Management. In: Small Animal Surgery. 4th edn. Mosby Elsevier, St. Louis, Missouri. pp. 991-999.

Franch, J., Diaz-Bertrana, C. and Lafuente, P. (2006). Beta tricalcium phosphate as a synthetic cancellous bone graft in veterinary orthopaedics: a retrospective study of 13 clinical cases. Veterinary Comparative Orthopaedics Traumatology, 19: 196-204.

Giannoudis, P. V., Dinopoulos, H. and Tsiridis, E. (2005). Bone graft substitutes: An update. Injury. International Journal Care Injured. 365: 520-527.

Heagade, Y., Dilimpkumar, D. and Usturge, S. (2007). Comparative evaluation of biochemical parameters during fracture healing in dogs. Karnataka Journal of Agriculture Science. 20(3): 694-695.

Ijaz, F., Buk, S.G., Khan, M.A., Ahmad, S.S. and Haider, B. (2014). Comparative efficacy of limited contact-dynamic compression plate and dynamic compression plate for repair of diaphyseal femoral fracture in dogs. Advances in Animal and Veterinary Sciences. 2(5): 296-301.

Julie, B. (2005). Acrylic external skeletal fixator for the treatment of long bone fractures in dogs. M.V.Sc thesis, Kerala Agricultural University, Mannuthy, Thrissur, Kerala, India.

Kumar, R., Gill, P.S., Singh, R., Sefia, M.S. and Rattan, P.J.S. (1992). Plasma electrolyte changes during fracture healing in dogs. Indian Veterinary Journal. 69: 476-477.

Kushwaha, R.B., Gupta, A.K., Bhadwal, M.S., Kumar, S. and Tripathi, A.K. (2011). Incidence of fracture and their management in animals: a clinical study of 77 cases. Indian Journal of Veterinary Surgery. 32(1): 54-56.

Manjunath, D.R. (2010). Comparison of “c-arm guided” and “aiming device” interlocking nailing of femoral fracture repair in dogs. M.V.Sc Thesis submitted to Karnataka Veterinary, Animal and Fisheries Sciences University, Bidar.

Ozturk, A., Yetkin, H., Memis, L., Cila, E., Bolukbasi, S. and Gemalmaz, C. (2006). Demineralised bone matrix and Hydroxyapatite/tricalcium phosphate mixture for bone healing in rats. International Orthopaedics. 30(3): 147-152.

Pandey, S.K. and Udupa, K.N. (1981). Effect of anabolic on certain metabolic responses in dogs. Indian Veterinary Journal. 58: 37-41.

Parti, M., Aithal, H.P., Kinjavdekar, P., Amarpal and Pawde, A.M. (2011). Management of femoral fractures using modified interlocking nailing in growing dogs with osteopenic bones. Intas Polivet. 12(1): 80-84

Raghunath, M and Singh, S. S. (2008). Intramedullary Interlocking Nailing for management of long bone diaphyseal fractures in dogs: A study of 17 clinical cases. Indian Journal Veterinary Surgery. 29: 106-109.

Rani, U., Rajendran, N. and Vairavasamy, K. (2012). Immobilization and treatment of femoral diaphyseal oblique fractures in dogs using double intramedullary pinning and cerclage wiring- A Study in Twelve patients. Intas Polivet. 13(II): 411-415.

Rao, T.M., Lakhshmipathi, G.V., Satry, T.P. and Ramakrishna, O. (2001). Biochemical changes following ulnar segmental defect repair with fibrillar collagen-hydroxyapatite and porous hydroxyapatite implants in canines. Indian J. Anim. Res. 35(2): 112-115.

Saikia, J., Singh, A.P., Chandna, I.S. and Chawla, S.K. (1986). Changes in certain blood and bone biochemical constituents during fracture healing in the bovine. Indian Journal of Animal Science. 56: 1-3.

Singh, H., Lovell, J.E., Schillar, A.G. and Kenner, G.H. (1976). Serum calcium, phosphorus and alkaline phosphatase level in dogs during repair of experimental ulnar defect. Indian Veterinary Journal. 53: 862-865.

Sirin, O.S., Kaya, U. and Olcay, B. (2013). Clinical and radiological outcome of locking compression plate system in dogs with diaphyseal fractures: 32 cases. Kafkas University Veterinary Fak. Derg. 19: A13-A18.

Soliman, F.A. and Hassan, S.Y.S. (1964). Serum calcium and phosphorous in rabbits during fracture healing with reference to parathyroid activity. Nature. 204: 693-694.

Tembhurne, R.D., Gahlod, B.M., Dhakate, M.S., Akhare, S.B., Upadhye, S.V. and Bawaskar, S.S. (2010). Management of femoral fracture with the use of horn peg in canine. Veterinary World. 3(1): 37-41.

Umashankar, S. and Ranganath, L. (2008). Osteomedullographic studies during fracture healing in dogs. Indian Veterinary Journal. 85: 382-84.

Vertenten, G., Gasthuys, F., Cornelissen, M., Schacht, E. and Vlaminck, L. (2010). Enhancing bone healing and regeneration: present and future perspective in veterinary orthopaedics. Veterinary Comparative Orthopaedics Traumatology. pp. 153-162.