RESEARCH ARTICLE Indian Journal of Animal Research, Volume 57 Issue 12: 1678-1685 (December 2023)

Evaluation of Autologous Bone Marrow Concentrate along with Hydroxyapatite-collagen for Management of Long Bone Fracture in Canines

Reshma Jain[1], B.P. Shukla[1], Supriya Shukla[1], Daljeet Chhabra[1], S.K. Karmore[1], Nidhi Shrivastava[1] **10.18805/IJAR.B-4519**

ABSTRACT

Background: Fractures are a major concern in Veterinary orthopedic surgery because they are often complicated into non unions. The present study was planned to evaluate the fracture healing by using hydroxyapatite-collagen (HAp-Col) as a bone graft substitute and autologous bone marrow concentrate, after the internal fixation by titanium elastic pin.

Method: The present work was conducted on 12 clinical cases of dogs having diaphyseal fracture of long bones. In group I (6 animals) fractures were immobilized by an internal fixation technique. In group II fracture was immobilized as in group I with use of autologous bone marrow concentrate along with Hydroxyapatite-collagen at the fracture site. The weight bearing and the progress of fracture healing were recorded.

Result: Study showed early weight bearing and no observable lameness in group II as compared to group I animals. Fracture union was earlier and with minimum periosteal callus formation in one animal, five animals at 45 days and 60 days respectively while in group I fracture healing was observed in one animal, two animals at 60 day and 90 days respectively. On basis of result, it is concluded that Hydroxyapatite-collagen composite can be used as along with autololegus bone marrow concentrate as alternative therapy to bone graft in clinical cases to enhance the fracture healing. The use of autogenous and allogenic bone graft having some advantages which is overcome by this present technique.

Key words: Autologous bone marrow, Fracture healing, Hydroxyapatite-collagen, Internal fixation, Radiographic union.

INTRODUCTION

Long bone fracture is the most common orthopaedic ailment encountered in routine canine practice. The goal of orthopedics and traumatology has been to return the patient to his pre-trauma state as quickly as possible. Internal fixation is preferred as associated with early immobilization and fast return to function. Bone healing success mainly depends on the presence of adequate mechanical stabilization and biological competence of the body, pro-osteogenic cells, scaffolds that allow bone growth (osteoconduction), growth factors (osteoinduction) and enough vascularization for an effective nutrient supply (Portal *et al*., 2012). Bone regeneration process may improve effectively and rapidly when stem cells are used. Stem cells are often employed with bone graft/ biomaterials/scaffolds and growth factors to accelerate bone healing at the fracture site (Iquanta *et al*., 2019).

The collagen-hydroxyapatite (HAp-col) composite is a synthetic bone graft has similar properties to the natural bone and has excellent osteoconductivity as a material for bone regeneration (Siswanto *et al*., 2020). The use of autologus bone marrow in fracture healing represents a promising method of application of tissue engineering in the orthopaedic field, which avoids many of the complications of the traditional bone grafting method commonly used so far (Sahu, 2018). Bone marrow contains osteoprogenitor stem cells which differentiate into chondroblasts and osteoblasts, cytokines and growth factors (Tseng *et al*., 2008). The transplantation of osteogenic cells in carrier system (Oryan *et al*., 2017) is an encouraging new approach to further enhance the process of bone reconstitution and remodeling (Perka *et al*., 2000). Biomechanical properties of titanium are often considered to be better than those of stainless steel with regard to biocompatibility, modulus of elasticity, osseointegration, corrosion resistance, and magnetic resonance imaging compatibility (Kitsugi *et al*., 1996).

Hence, the present study was planned to evaluate the efficacy of fracture healing using hydroxyapatite-collagen

[1]Department of Veterinary Surgery, College of Veterinary Science and Animal Husbandry, Nanaji Deshmukh Veterinary Science University, Mhow-453 441, Madhya Pradesh, India.

Corresponding Author: Reshma Jain, Department of Veterinary Surgery, College of Veterinary Science and Animal Husbandry, Nanaji Deshmukh Veterinary Science University, Mhow-453 441, Madhya Pradesh, India. Email: reshmavet@gmail.com

How to cite this article: Jain, R., Shukla, B.P., Shukla, S., Chhabra, D., Karmore, S.K. and Shrivastava, N. (2023). Evaluation of Autologous Bone Marrow Concentrate along with Hydroxyapatite-collagen for Management of Long Bone Fracture in Canines. Indian Journal of Animal Research. 57(12): 1678-1685. doi: 10.18805/IJAR.B-4519.

Submitted: 12-05-2021 **Accepted:** 15-09-2021 **Online:** 27-10-2021

(HAp-Col) as a bone graft substitute and autologus bone marrow, after the internal fixation by titanium elastic pin.

MATERIALS AND METHODS

Present study have been conducted in 12 clinical cases of dogs (above the 6 months of age) having the long bone fracture (femur, humerus and tibia), presented in Department of Veterinary Surgery and Radiology, VCC, Mhow. The study conducted from 2015 to June 2017. All the selected animals were randomly divided into two groups having six animals each. In group I (GI) fractures were immobilized by Internal fixation technique using appropriate size Titanium elastic intramedullary pin (Fig 1a). In group (GII), the stable internal fixation of fracture fragments was achieved as in GI and harvested autologous bone marrow concentrate along with Hydroxyapatite-collagenc (HAp-Col) granules was filled at the fracture gap (Fig 1b,c,d). The distribution of animals, bone involved and type of fracture were depicted in Table 1. A thorough clinical and radiological examination of the animals was performed to localize the fracture and to rule out any neurological deficit. Before planning of surgery health status of the animals was evaluated. All the animals were operated under general anesthesia in both the groups. Standard surgical approaches were made for femur, humerus and tibia fractures. After incision, the fractures ends were exposed, retrieved and immobilized by retrograde-normograde internal fixation technique using appropriate size of Titanium elastic pin in all the animals. In G II animals, 20-25 ml of bone marrow was harvested prior to the orthopedic procedure from iliac crests of same dog in a syringe having anticoagulant EDTA. The bone marrow was harvested using bone marrow needle (Fig 2a) and carefully layered on over equal volume of density gradient media (Hisep Fig 2b). After the centrifugation, the opaque buffy coat was collected which composed of mononuclear cells (lymphocyte, monocyte and mesenchymal stromal/stem cells) with platelets (Fig 3). This processed bone marrow concentrate was mixed with HAp-Col granules and used in G II animals, as described. A ready made pack of Hap-Col granules (bovine origin) having a particle size of 0.5 to 0.9 mm were used as bone graft substitute as per size of fracture gap. All surgical wounds were closed as per standard. Post operative management followed by dressing of the surgical wound, immobilization of limb with Robert Jones bandage, parentral administration of antibiotic for 7 days and analgesic for 4 to 5 days. Surgical wound was assessed for wound swelling, exudation and healing on the basis of gross examination.

Parameters of the study

The weight bearing and lameness was analyzed clinically in both the groups and scored on day 0, 7, 14, 21, 30 and

Table 1: Distribution of animals, Bone involved and type of fracture under treatment groups.

Group	Case no.	Bone affected	Orientation of fracture	Location of fracture
G I (n=6)	A1	Femur	Oblique with bone loss	Proximal
	A2	Femur	Transverse with bone loss	Distal third
	A3	Tibia	Transverse with bone loss	Mid shaft
	A4	Tibia	Transverse	Mid shaft
	A5	Femur	Transverse	Distal third
	A6	Femur	Transverse	Distal third
G II (n=6)	C1	Femur	Oblique	Mid shaft
	C2	Tibia	Oblique	Mid shaft
	C3	Femur	Transverse with bone loss	Distal third
	C4	Femur	Spiral with bone loss	Proximal third
	C5	Humerus	Spiral	Distal third
	C6	Femur	Oblique with bone loss	Distal third

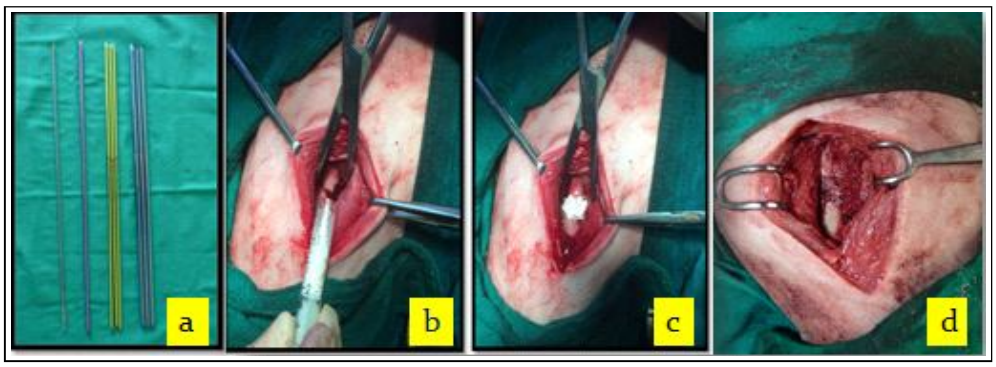

Fig 1: (a) Titanium Intramedullary Pin; (b and c) Use of Hydroxyapatite-collagen Granules at the fracture site; (d) use autologous bone marrow concentrate along with the granules at the fracture site.

60 as described by Cook *et al*. (1999) (Table 2). Post Radiographic examination (two orthogonal view) at 0 day post operative, 15th, 30th, 45th, 60th and 90th day to evaluate apposition, alignment of fracture fragment, callus formation, ossification, organization of callus, reaction of bone to implant if any and stability of implant. The data was analysed using complete randomized design (CRD) as per described by Snedecor and Cochran (1994).

RESULTS AND DISCUSSION

All surgical wounds were healed by first intention healing in 7 to 15 day post- operatively in all the animals. Surgical wound showed no exudation, swelling and pain on palpation except in one animal of both the groups. These two animals self mutilated the wound resulted slight exudation on 3rd and 5th day respectively. It was evident that titanium elastic nail alone and with HA-Col and autologous bone marrow was compatible to the animal's body without any adverse effect. Similarly, Preethi *et al*. (2021) stated that none of the cases showed any adverse tissue reaction to bone graft, thus confirming its complete biocompatibility.

On 0 day before the operation, all the animals were having non weight bearing lameness (score 05). In GI, score was 5.00±0.00 on 3rd day with significant gradual reduction post operative days with 2.16±0.60 at 60th day (Table 3, Fig 4). On 14th day, four animals out of six showed toe touching (score-04). On 30th day four animals showed moderate weight bearing with noticeable change in gait, scored-03. On 60th day, three animals (A2, A3, A4) scored 02, one animal (A6, A5, A1) scored 0, 01, 05 respectively. In GII, score was 4.66±0.21 on 3rd day with significant gradual reduction of 1.00 ±0.44 at 60th day (Table 3, Fig 4). Five animals showed early limb use with toe touching (score 04) on 3rd, 7th and 14th post operative days respectively. Two animals (C1, C2) scored 01 at 30th day. Two animals (C1, C2) scored 0 and 3 animals scored 01 and one animal (C6) scored 03 on 60th day. The C3 animals was having much bone loss hence healing and weight wearing is delayed in this animal.

In present study GII animals, showed early weight bearing and no observable lameness in comparison to GI animals, in spite of the fact, that few animals had spiral fractures and fractures with bone loss. These findings support

Table 2: Assessment of weight bearing and lameness score.

Weight bearing	Score
No observable lameness	0
Intermittent, mild weight bearing lameness with no change in the gait	1
Consistent, mild weight bearing lameness with little change in the gait	2
Moderate weight bearing with noticeable change in the gait	3
Severe weight bearing lameness, toe touching only	4
Non weight bearing	5

Table 3: Assessment of weight bearing and lameness score.

Days	3	7	14	21	30	60
Group I	$5.00^{a}\pm0.00$	$4.83^{ab}\pm0.16$	$4.00^{bc}\pm 0.25$	$3.83^{c}\pm 0.30$	$3.50^{c}\pm0.34$	$2.16^{d}\pm0.60$
Group II	$4.66^{a}\pm0.21$	$4.00^{b}\pm0.36$	$3.50^{bc}\pm 0.34$	$3.00^{bc}\pm0.36$	$2.00^{cd}\pm0.36$	$1.00^{d}\pm0.44$

^{abcd}values within groups with different superscript differ significantly ($p<0.05$).

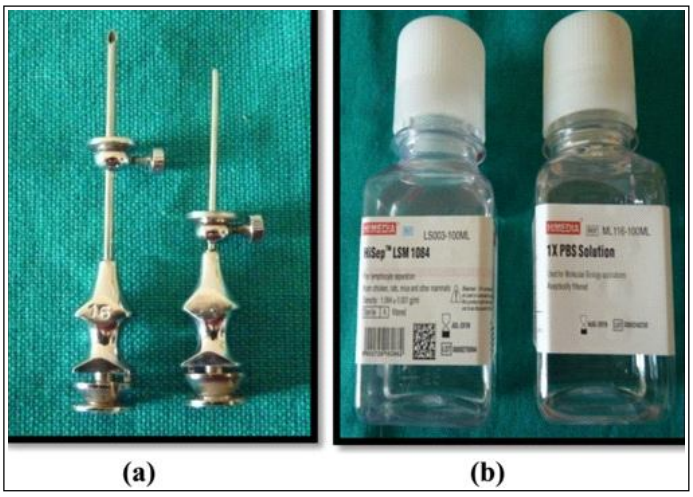

Fig 2: (a) Bone marrow biopsy needle of different sizes (b) Hisep and phosphate buffer solution (PBS).

radioghraphic finding also, which showed early callus formation. The improvement in limb use may be attributed to the use of HA-Col along with titanium nail which provide adequate stiffness, strain shielding and maintain the stability in load bearing bones (Wahl *et al*., 2006). Further use seeding of pluripotent cells trigger the patient's own regenerative mechanism (Raulo *et al*., 2012). Similarly, Rathod *et al*. (2014) also reported good functional recovery of limb after using autologus bone marrow concentrate in six dogs. Dwivedi *et al*. (2008) also observed better functional outcome in groups of animals where bone graft substitute was used.

Post Radiographic evaluation

Post surgery 0 day radiographs revealed proper opposition and alignment of fractured fragments with noticeable gap. The alignment was not perfect in two animals of group I (A1 and A5) and one animal (C6) of G II due to bone loss. In G II, interfragmentary gap was appreciated by granular opacity in most of the animals on immediate post surgery radioghaphs. This might be due to of the radiopaque granular structure of graft material at because of its mineral component. This was also in correlation with Tanaka *et al*. (2017) and Preethi *et al*. (2021).

Post operative radiographic examination (lateral and cranio-caudal view) in group I showed moderate periosteal reaction and reduction of inter fragmentary gap in four animals (A1, A2, A5 and A6) except in two animals (A3 and A4-Fig 5) from 15th to 30th day. More proliferative external callus was observed in two animals (A1 and A6-Fig 6) at 30th day. On 45th day, further reduction of fracture gap was observed in all animals. On 60th day obliteration of fracture line in two animals (A5 and A6) with moderate external callus in one animal (A5-Fig 7). Union on one side of cortex



Fig 3: Harvesting of autologous bone marrow concentrate.



i) on 3rd day (C1), ii) on 30th day (C2), iii) on 21st day (A4), iv) on 60th day (A5).

Fig 4: Weight bearing status of animals.



a) preoperative (0) day: fracture of proximal third of tibia, b) 0 day: Internal fixation by titanium pin, c) 15-30thday: moderate periosteal reaction with no change in inter fragmentary gap, d) 45th day: reduction of fracture gap, e) 60th day: union on one side of cortex, f) 90th day: a faint radiolucent line at fracture site on side of cortex.

Fig 5: Radiographs showing progress of fracture healing of A4 animal.

was observed in remaining four animals (A1, A2, A3 and A4) at 60th day. On 90th day complete fracture line was completely obliterated by external callus in one more animal (A2), while in the three animals (A1, A3 and A4) radiolucent line was visible and healing in progress.

In Group II postoperative day radiographs (lateral and cranio-caudal view) revealed mild periosteal reaction and progression of bridging callus with reduction of fracture gap in five animals, while in (C6), no periosteal reaction was noticed on 15th day. On 30th day, radioghraphs showed union of one aspect of cortex in two dogs (C2-Fig 8 and C5), further reduction of gap with callus formation in two animals (C1 and C4). In C3 animal union on cranial cortex was complete where as on other cortices progression of collar of callus was observed (Fig 9). In C6 animal presence of periosteal reaction was noticed with visible fracture gap.

On 45th day, there was complete consolidation of callus with thickening of cortex at fracture site in one dog (C2: Fig 8). On 60th day, complete obliteration of fracture line was revealed in two animals (C1 and C5). In C3 animal union was complete on cranial cortex, with faint radiolucent line on caudal cortex (lateral view) and size of callus was bigger (Fig 9). In C6 animal union of the over ridden part was observed however a spur of bone on caudal cortex was noticed. In C4 animal radiolucent space on one aspect of bone while union on other aspect of bone was observed. On 90th day, radiographs showed continuity of medullary cavity and remodeling in all five animals. Union was in progress in C6 animal with presence of radiolucent gap on one cortex.

Fracture union was earlier and with minimum periosteal callus formation in five animals in G II as compared to G I. This might be due to that bone marrow concentrate contains MSCs, osteoblast and osteoinductive growth factors such as bone morphogenic proteins (BMP), fibroblast growth factor (FGF) and transforming growth factor (TGF) which enhance the fracture healing (Knight and Hankenson, 2013). Further seeding of these elements on scaffolds, boost the

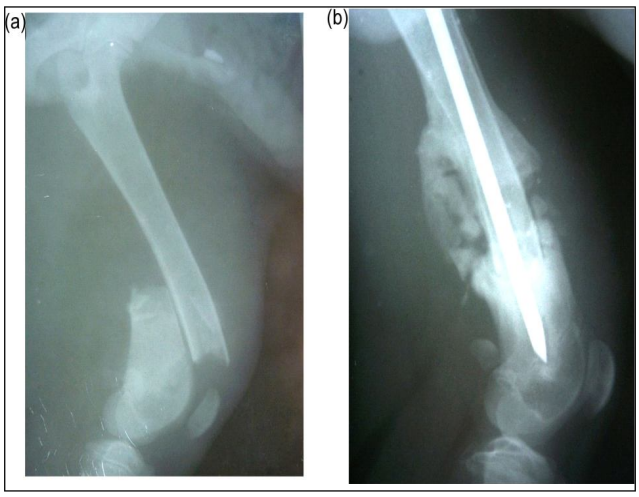

Fig 6: Proliferative periosteal external callus in A6 at 30th Day.

osteogenic/inductive potential, may also used as alternative for autogenous bone grafting (Knight and Hankenson, 2013; Jaiswal *et al.* (2021). This was in corroboration with the findings of Rathod *et al*. (2014) and Nnaji *et al*. (2017) who observed that autologous bone marrow aspirates treated groups exhibited a more matured osteiod seams in terms of callus proliferation and mineralization in transverse tibia fractures in Nigeria indigenous dogs. It is speculated that



a) preoperative (0) day: fracture of distal third of femur, b) 0 day: Internal fixation by titanium pin with slight overriding of fragments, c) 15-30th day: mild periosteal reaction, d) 45th day: reduction of fracture gap, e) 60th day: union of fracture fragments, f) 90th day: initiation of remodeling

Fig 7: Radiographs showing progress of fracture healing of A5 animal.

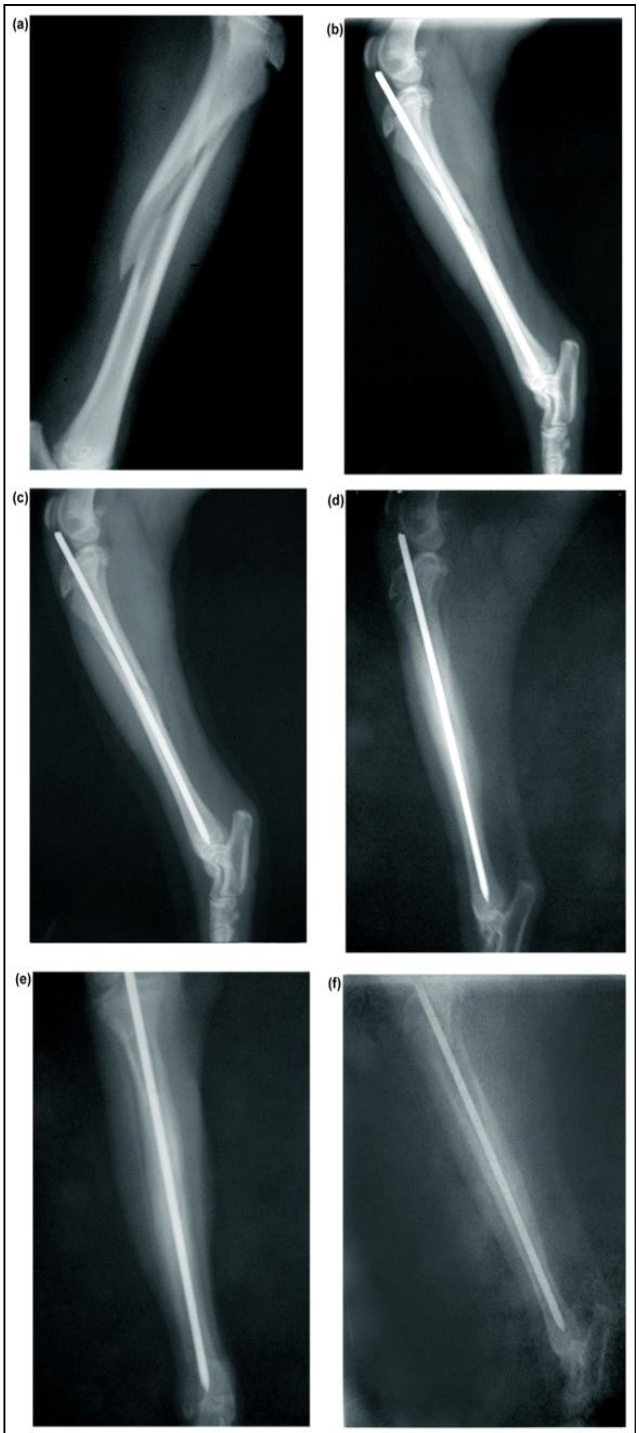

a) preoperative day, b) after internal fixation (0 day), c) at 15th day, d) at 30th day, e) at 45th day, f) at 60th day.

Fig 8: Radiographs showing progress of fracture healing of C2 dog.

bone marrow cells, most likely stem and progenitor cell, react vigorously and promote active bone formation around and inside the HAp-Col implant (Taniyama *et al*., 2015). The Histological examination of bone augmentation ability of HAp-Col composite in a rat calvaria defect model revealed that the entire area of the gap was filled with prominent newly formed bone intermingled with the HAp-Col (Ozava et al., 2018). In addition to bone conductivity HAp/Col might have released the calcium ion for bone formation and growth factor (Nishikawa *et al*., 2005).

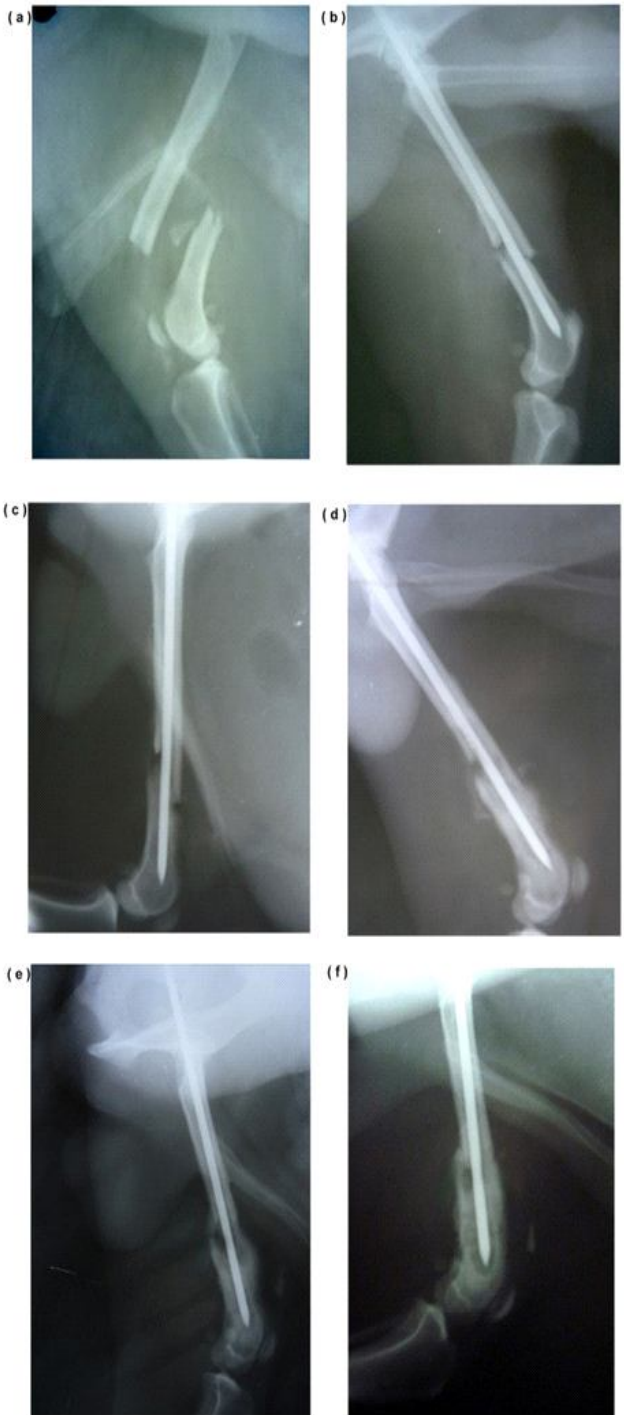

a) preoperative day, b) after internal fixation (0 day), c) at 15th day, d) at 30th day, e) at 45th day, f) at 60th day

Fig 9: Radiographs Showing progress of fracture healing of C3 dog.

In the present study ABMC was used, as it can bypass the time-consuming and difficult process of MSCs expansion, which must be expanded *in vitro* for several weeks to reach a sufficiently high number of cells for transplantation, which not only delays the treatment but also increases costs and contamination risk related to culture (Gali *et al*., 2016).

The case wise variation of fracture healing in the present study might be due to other contributing factors which also affect the bone regeneration. The factors such as age, weight, location, fractures gap, a shift that occurs in the bone, movement of the animal, post-operative immobilization, bandaging, post operative pain management, cooperation of veterinary patient and care by the pet owner are the factors which also affect the rate of healing in veterinary patient.

CONCLUSION

The early radiographic healing and encouraging weight bearing at different intervals in treated group explains logically that titanium elastic nail as implant with HAp-Col graft and autologous bone marrow was compatible to the animal's body without any adverse effect. The faster fracture healing is always a need in Veterinary patient, the present study advocated good alternative to full fill better outcome of orthopaedic surgery. Hence it is concluded that Hydroxyapatite-collagen composite with autolologus bone marrow concentrate hasten the fracture healing in comparison to intramedullary pin alone in fracture cases of dog. This technique improves the early limb use by the patient and satisfy the owner.

Conflict of interest

The authors declare that they have no conflict of interest.

REFERENCES

Cook, J.L., Tomlinson, J.L. and Reed, A.L. (1999). Fluroscopically guided closed reduction and internal fixation of fractures of lateral portion of the humeral condyle: Prospective clinical study of the technique and result in ten dogs. Veterinary Surgery. 25: 386-396.

Dwivedi, D.K., Kushwaha, R.B., Bhadwal, M.S., Gupta, A.K., Soodan, J.S. and Bhardwaj, H.R. (2008). Evaluation of b-tricalcium phosphate biomaterial in femur fracture repair in dogs. Indian Journal Animal Research. 1-7. doi: 10.18805/IJAR.B-4418.

Gali, R.S., Devireddy, S.K., Rao, N.M., Kumar, R.V.K., Kanubaddy, S.R., Dasari, M., Sowjanya, K. and Pathapati, R.M. (2016). Autogenous bone marrow aspirate coated synthetic hydroxyapatite for reconstructionof maxillo-mandibular osseous defects: A prospective study. Journal of Oral and Maxillofacial Surgery. 16: 1-8.

Iaquinta, M.R., Mazzoni, E., Bononi, I., Rotondo, J. Ch., Mazziotta, Ch. Montesi, M., Sprio, S., Tampieri, A., Tognon, M. and Martini, F. (2019). Adult stem cells for bone regeneration and repair. Frontier in Cell Developmental Biology. doi.org/10.3389/fcell.2019.00268.

Jaiswal, S., Jadon, N.S., Pandey, P., Bodh, D. and Kaushal, S. (2021). Histological study on the effects of allogenic bone marrow derived mesenchymal stem cells along with local insulin therapy on osteosynthesis in gap defects of radius in diabetic rabbit model. Indian Journal of Animal Research. 55(5): 542-549.

Kitsugi, T., Nakamura, T., Oka, M., Yan, W.Q., Goto, T., Shibuya, T., Kokubo, T. and Miyaji, S. (1996). Bone bonding behavior of titanium and its alloys when coated with titanium oxide (TiO2) and titanium silicate (Ti5Si3). Journal of Biomedical Material Research. 32: 149-156.

Knight, M.N. and Hankenson, K.D. (2013). Mesenchymal stem cells in bone regeneration. Advances in Wound Care. 2(6): 306-316.

Nnaji, T.O., Innocent, N., Ugwu, N. and Onyenekwe, C. (2017). Evaluation of single and multiple use of bone marrow aspirate in management of tibia fractures of Nigerian indigenous dogs. Journal of Applied Animal Research. 46(1): 828-834.

Nishikawa, T., Masuno, K., Tominaga, K., Koyama, K., Yamada, T., Takakuda, B.S., Kikuchi, M., Tanaka, J. and Tanaka, A. (2005). Bone repair analysis in a novel biodegradable hydroxyapatite/collagen composite implanted in bone. Implant Dentistry. 14: 3. doi: 10.1097/01.id.0000173628.00705.d0.

Oryan, A., Kamali, A., Moshiri, A. and Baghaban, E.M. (2017). Role of mesenchymal stem cells in bone regenerative medicine: what is the evidence. Cells Tissues Organs. 204: 59-83. doi: 10.1159/000469704.

Ozawa, Y., Kubota, T., Yamamoto, T., Tsukune, N., Koshi, R., Nishida, T., Asano, M. and Sato, S. (2018). Comparison of the bone augmentation ability of absorbable collagen sponge with that of hydroxyapatite/ collagen composite. Journal of Oral Science. 60(4): 514-518. doi: 10.2334/josnusd.17-0465.

Perka, C., Schultz, O., Spitzer, R., Linenhayn, K., Burmester, G. and Sittinger, M. (2000). Segmental bone repair by tissue-engineered periosteal cell transplantats with bioresorbable fleece and fibrin scaffold in rabbits. Biomaterials. 21: 1145-1153.

Portal-nunez, S., lozano, D. and Esbrit, P. (2012). Role of angiogenesis on bone formation. Histology and Histopathology Journal. 27: 559-566.

Preethi, K., Kumar, V.G., Raghavender, K.B.P., Kumar, P. D. and Lakshman, M. (2021). Use of Beta-tricalcium Phosphate Bone Graft with Collagen Membrane as Guided Bone Regeneration in Long Bone Fractures with Bone Loss in Dogs: A Clinical Study. Indian Journal of Animal Research. 55(2): 222-225.

Rathod, R., Vasanth, M.S., Nagaraja, B.N. and Patil, A.S. (2014). Femoral fracture repair using bone marrow cells in dogs. Indian Journal of Veterinary Surgery. 35(1): 71-72.

Raulo, B.C., Dash, C., Rath, S., Chakrabarty, S., Rautray, P., Sahoo, J. and Padhy, R.N. (2012). Use of bone marrow derived stem cell in a fracture non-union. Journal of Acute Disease. 1: 156-158.

Sahu, R.L. (2018). Percutaneous autologus bone marrow injection for delayed union and nonunion of long bone fracture after internal fixation. Revista Brasileira de Ortopedia. 53(6): 668-673.

Siswanto, S., Hikmawati, D., Kulsum, U., Rudyardjo, D.I., Apsari, R. and Aminatun, A. (2020). Biocompatibility and osteoconductivity of scaffold porous composite collagen-hydroxyapatite based coral for bone regeneration. Open Chemistry. 18(1) DOI: https://doi.org/10.1515/chem-2020-0080.

Snedecor, G. W. and Cochran, W.G. (1994). Stastistical Method, 8th Edn., The Iowa state University Press Publishing Co., U.S.A. pp: 312-317.

Tanaka, T., Komaki, H., Chazono, M., Kitasato, S., Kakuta, A., Akiyama, S. and Marumo, K. (2017). Basic research and clinical application of beta-tricalcium phosphate (β-TCP). Morphologie. 101(334): 164-172.

Taniyama, T., Masaoka, T. and Yamada, T. (2015). Repair of osteochondral defects in a rabbit model using a porous hydroxyapatite collagen composite impregnated with bone morphogenetic protein-2. Artificial Organs. 39: 529-535.

Tseng, S.S., Lee, M.A. and Reddi, A.H. (2008). Nonunions and the potential of stem cells in fracture-healing. Journal of Bone and Joint Surgery. 90: 92-98.

Wahl, Da. and Czernuszka, Jt. (2006). Collagen-hydroxyapatite composites for hard tissue repair. European Cells and Materials. 11: 43-56.

Wang, H., Tang, X., Li, W., Chen, J., Li, H., Yan, J., Yuan., X., Wu, H. and Liu, Ch. (2019). Enhanced osteogenesis of bone marrow stem cells cultured on Hydroxyapat- tite /collagen I scaffold in the presence of low-frequency magnetic field. Journal of Materials Science; Materials in Medicine. https://doi.org/10.1007/s10856-019-6289-8.