RESEARCH ARTICLE Indian Journal of Animal Research, Volume 58 Issue 6: 1017-1021 (June 2024)

Atrial Septal Defect (Secundum Type) in Dogs- A Study for 15 Years

K. Satish Kumar[1], V.V.V. Amruth Kumar[1]

10.18805/IJAR.B-4522

ABSTRACT

Background: Congenital anomalies in dogs are the defects present at birth and often lead to perinatal death if it involves any vital organ or system like cardiovascular system. Some dogs may remain asymptomatic or may have non cardiac manifestations and hence, undetected until later in life, so the percentage of dogs with congenital heart diseases that survive to adulthood can be rather high. Atrial septal defect (ASD) is an unusual congenital heart disease in dogs that is characterized by communication between the two atria due to a defect in the interatrial septum.

Methods: A thorough clinical examination followed by physical examination, thoracic radiography and 2d-echocardiography was performed to determine the septal defect. Doppler evaluation of ASD dogs was carried out to confirm the blood flow direction through the septal defect, which was managed medically.

Result: In the present study, ASD (secundum type) was diagnosed in 7dogs (7.5%) aged between 2y-6y. Boxer, German shepherd, Cocker spaniel, Daschund and Pomeranian were the breeds affected. Soft systolic murmur on left heart base and pulmonic valve area, low intensity heart sounds, distended jugular vein, jugular pulse and ascites were the significant findings on physical examination. Though few dogs (21%) were asymptomatic, exercise intolerance, dyspnoea, general weakness, cough and syncope were the presenting signs among other cases. Enlarged right heart, pleural effusion and pulmonary overcirculation were radiographic findings. 2d-echocardiographic evaluation determined the presence of the defect as a loss of echogenicity at the interatrial septum and presence of interatrial communication of varied size, enlargement of main pulmonary artery and thick atrio-ventricular valves but with normal left atrium:aorta base ratio, increased fractional shortening, systolic function and paradoxal septal motion. The colour flow Doppler study demonstrated a continuous flow with left-to-right shunt.

Key words: Atrial septal defect, Diagnosis, Dogs, Echocardiography.

INTRODUCTION

Congenital heart disease (CHD) is a morphologic defect of the heart or associated great vessels present at birth that are caused by alterations or arrests in particular phases of embryonic development of the fetal heart (MacDonald, 2006). Atrial septal defect (ASD) is one of the common congenital heart diseases (CHDs) in humans, but considered relatively rare in veterinary patients. However, advancement of modern diagnostic facilities such as 2d-echocardiography and doppler techniques is facilitating detection of these defects earlier in awake animals (Chetboul *et al.,* 2006a). Dogs may be presented asymptomatic or with signs of heart failure and are diagnosed for ASD alone (Chetboul *et al.,* 2006a) or the atrial septal anomaly may be associated with other congenital cardiac abnormalities like ventricular septal defect and tricuspid dysplasia (Guglielmini *et al.,* 2002). The present paper puts on record about clinical and diagnostic aspects of ASD in dogs.

MATERIALS AND METHODS

The study was carried out among the dogs of various breed and gender that were presented with the history and signs suggestive of heart failure and also those that were routinely referred for complete check up to cardiology ward, Veterinary Clinical Complex of CVSc., Rajendranagar during a period of 15 years (2006 to 2020). All these dogs were subjected for detailed clinical examination followed by physical examination. Chest auscultation was carried out in a sound proof environment, on specific points at left and right cardiac region. Thoracic plain radiography was performed on both the right lateral and ventro dorsal views. Further, 2d-echocardiography was performed using GE logiq Doppler machine and 6S cardiac probe to diagnose ASD in these dogs. Both short and long axis of cardiac chambers were evaluated to detect the septal anomaly on B-mode and whereas, dimensions of left ventricle was evaluated on M-mode echocardiography. Later Doppler evaluation of ASD dogs was also carried out to study the blood flow direction through the septal defect. These dogs were medically

[1]Department of Veterinary Medicine, College of Veterinary Science, PV Narsimha Rao Telangana Veterinary University, Rajendranagar-500 030, Hyderabad, Telangana, India.

Corresponding Author: K. Satish Kumar, Department of Veterinary Medicine, College of Veterinary Science, Rajendranagar-500 030, Telangana, India. Email: Drsatish.ksk@gmail.com

How to cite this article: Kumar, K.S. and Kumar, V.V.V.A. (2024). Atrial Septal Defect (Secundum Type) in Dogs-A Study for 15 Years. Indian Journal of Animal Research. 58(6): 1017-1021. doi: 10.18805/IJAR.B-4522.

Submitted: 14-05-2021 **Accepted:** 03-08-2021 **Online:** 23-08-2021

managed with angiotensin converting enzyme inhibitors, diuretics and positive ionotropic drugs and all the cases showed clinical improvement.

2 dimensional echocardiography was performed as right parasternal transthoracic echocardiograms in unsedated suspected dogs by placing them in right lateral recumbency. Access to the right side of the thorax was facilitated by using a table with a special cut-open to allow the transducer to be directed upward towards the site of maximal cardiac pulsation (Allworth *et al.,* 1995). Transducer is located parasternally between right third and sixth intercostal spaces between sternum and costochondral junction (Thomas *et al.,* 1994). M-mode recordings were taken at the high papillary level and the measurement of left ventricular dimension at end–diastole (LVEdD) and end-systole (LVEsD) was made intraluminally from the trailing edge of the septal wall image to the leading edge of the ventricular free wall. End–diastolic and end–systolic measurements of the thickness of the Inter Ventricular Septum (IVSd, IVSs) and left Ventricular Posterior Wall (LVPWd, LVPWs) were made using trailing edge (Allworth *et al.,* 1995). Further, colour flow Doppler was also done to assess the directional flow as per the technique suggested by Dominique and Marc-Andre (2008).

RESULTS AND DISCUSSION

Signalment and signs

A total of 1358 dogs of various breed and gender that were presented to cardiology ward of VCC of CVSc Rajendranagar were diagnosed for various acquired (93%) and congenital cardial diseases (7%), accounting for 1263 and 95 cases, respectively. Out of the total congenital diseases (95), ASD was diagnosed in 7 cases (7.5%). Congenital anomalies of the cardiovascular system are defects present at birth and often lead to perinatal death in dogs. However, in some cases, congenital heart diseases are asymptomatic and undetected until later in life, so the percentage of dogs with congenital heart diseases that survive to adulthood to breed can be rather high (Garncarz *et al.,* 2017 and Caivano *et al.,* 2018). These dogs were aged between 2y-6y and the majority of breeds include Boxer (43%) followed by German shepherd, Cocker spaniel, Daschund and Pomeranian. Boxer and Domestic shorthair was the most common canine and feline breeds affected (Chetboul *et al.,* 2006a). The main studies report different prevalence of congenital heart diseases (CHDs) in the affected breeds, depending on the popularity of the breed in a country in a given period of time (Ghirlanda *et al.,* 2014). Knowing the epidemiology of CHDs plays an important role in maintaining dog health and in preventing the diffusion of CHDs in the dog population (Garncarz *et al.*, 2017).

Auscultation of cardiac area revealed, soft systolic murmur on left heart base (78%) and pulmonic valve area (56%), low intensity heart sounds (48%) and whereas, physical examination determined distended jugular vein (32%), jugular pulse (24%) and ascites (29%). Most of the dogs (53%) were presented with the history and signs suggestive of heart failure and few (21%) were asymptomatic. The common clinical manifestation recorded among symptomatic cases include, reduced exercise tolerance (18.2%), dyspnoea (11.3%), general weakness (10.4%), jugular pulse (6.2%), cough (5.2%) and syncope (2.8%). According to the location of the defect within the interatrial septum, three types of ASD have been defined; primum ASD is located in the most apical portion of the atrial septum; secundum ASD involves the fossa ovalis region and third type that is present in the upper portion of the septum is sinus venosus ASD (Chetboul *et al.,* 2006a). Of all these types, secundum ASD is the most commonly seen septal defect among dogs (Guglielmini *et al.,* 2002; Chetboul *et al.,* 2006a; MacDonald, 2006). In dogs, most of the ASDs are secundum type and without clinical signs, but some are presented with certain common signs that included systolic murmur over the left heart base, exercise intolerance, dyspnoea, syncope and cough. Intensity of a systolic heart murmur over the left base is directly proportional to the size of the defect (Chetboul *et al.,* 2006a). Systolic murmur at the left heart base also helps to differentiate the type of the congenital heart disease, for that matter, a low intensity left heart base systolic murmur signifies an isolated ASD whereas a high intensity murmur suggests SAS, either isolated or associated with a concurrent CHD. The ASD is a common cause of left heart base systolic murmur among Boxers (Chetboul *et al.,* 2006b). A low intensity of heart beats, jugular pulse, tachypnea and ascites are some of the common manifestations among ASD dogs (Cavalcanti *et al.,* 2009).

Radiography

Radiographically, varied degrees of right ventricular/atrial enlargement, pleural effusion and prominence to the pulmonary vessels indicating pulmonary overcirculation were noticed on lateral and ventrodorsal views (Fig 1-2). The diagnosis of congenital heart disease in dogs is not only important for the sake of the affected pet, but also to prevent these defects in successive generations by eliminating these patients from the breeding pool (MacDonald, 2006). Survey

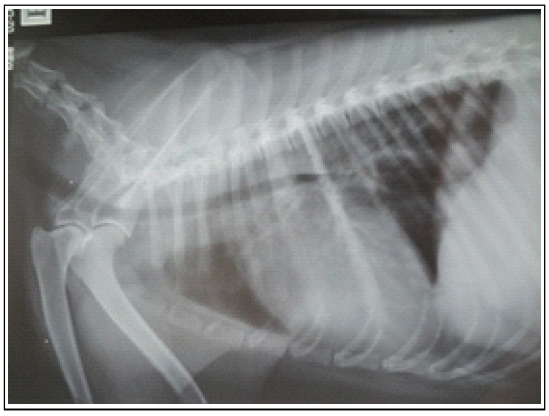

Fig 1: Right lateral view of thorax of a GSD (5 yr). Note the dilatation of right atrium and ventricle indicated by increased sternal contact.

thoracic radiography revealed pleural effusion and right atrium enlargement (Cavalcanti *et al.,* 2009).

Echocardiography

2d-echocardiography revealed gross dilatation of right atrium and right ventricle, as well as identification of the defect as a loss of echogenicity at the interatrial septum. The right parasternal B-mode examination revealed interatrial communication of varied size, enlargement of main pulmonary artery and discrete, thickened mitral and tricuspid valves but with normal left atrium:aorta base ratio (Fig 3-4). M-mode aspects of left ventricle lumen include, increased left ventricle lumen at end diastole with hyperkinetic interventricular septum (IVS), increased fractional shortening, systolic function and paradoxal septal motion (Fig 8). The echocardiography demonstrates interatrial communication and colour Doppler confirms a left-to-right shunt with a continuous flow on spectral Doppler echocardiography at the defect region. Dilated right atrium, right ventricle and main pulmonary artery, an increased systolic function associated with a high fractional shortening, thickened atrioventricular valve leaflets with mild to moderate regurgitation were the echocardiographic findings among ASD dogs (Cavalcanti *et al.,* 2009). ASD is considered relatively rare in veterinary medicine. Its prevalence has been reported to vary from 0.7 to 3.7% of all canine congenital cardiovascular anomalies (Guglielmini *et al.,* 2002). Echocardiographic and Doppler techniques offer a good view of the morphology of the myocardium and thus, facilitating earlier detection of ASD in asymptomatic awaken animals (Chetboul *et al.,* 2006a). Whereas, the colour flow Doppler study demonstrated the left-to-right shunt and a continuous flow was observed on spectral Doppler echocardiography (Fig 5 to 6) and regurgitation jet



Fig 2: Thoracic X-ray of a 6 yr old Pomeranian showing pleural effusion with increased sternal contact (dilated right heart).

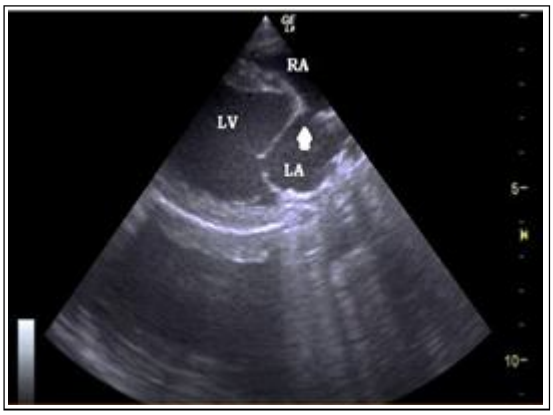

Fig 3: B-mode long axis echogram of 4.5 yr Daschund, showing smaller ASD (solid arrow).

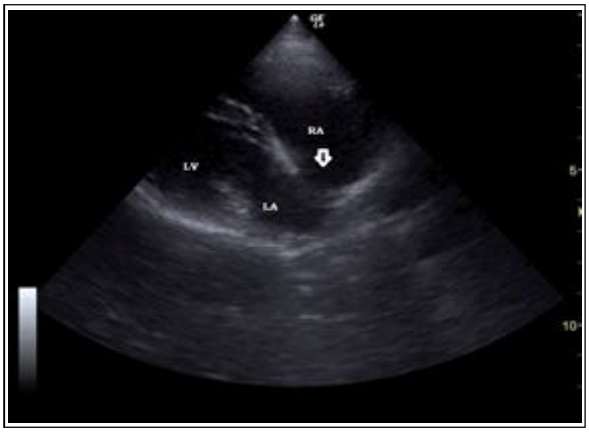

Fig 4: B-mode long axis echo tracing of GSD confirming a bigger ASD (solid arrow) with dilated right atriam (RA).



Fig 5: Colour flow Doppler image of a 4 yr Boxer showing left to right shunting with turbulence at the site of defect.



Fig 6: B-mode long axis echogram (A) depicting a bigger septal discontinuity (ASD). Continuous flow with left to right shunt is seen on color flow Doppler (B).

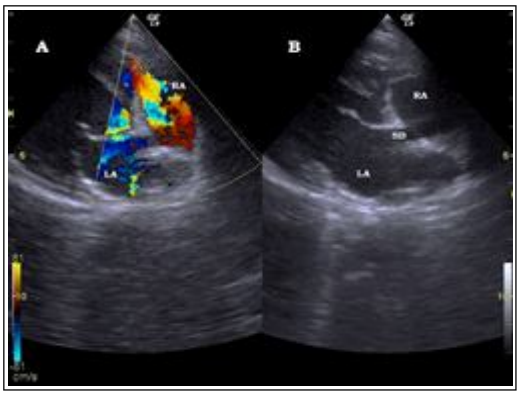

Fig 7: Colour flow Doppler image of a 2 yr Boxer (A) showing regurgitation in right atrium (RA), the septal defect (SD) can be noted in a B-mode image (B).

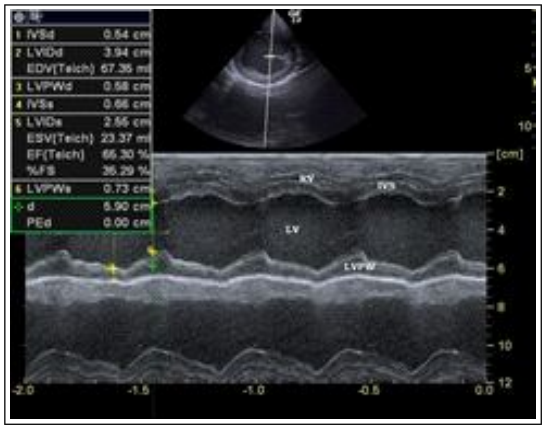

Fig 8: M-mode echo tracing of an ASD Pomeranian showing increased Fractional shortening: Right ventricle (RV), Interventricular septum (IVS), left ventricle lumen (LV) and Left ventricle free wall (LVPW).

at the tricuspid valve area (Fig 7). The echocardiography combined with color-flow Doppler mode was the method that is chosen to confirm ASD and to determine the severity of the shunt (Oliveira *et al.,* 2011). Isolated ASD usually result in a left-to-right shunting across the septal defect, because the left side heart chambers have a higher pressure than that of the right heart, thus the extra blood from the left atrium may cause a volume overload in right heart chambers, may lead to dilatation of right heart (Chetboul *et al.,* 2006b). Similarly, the abdominal ultrasound evaluation revealed anechoeic space with floating viscera, ascites and mild to moderate hepatomegaly with hepatic congestion. Right heart failure may further lead to ascites, pleural effusion, pulmonary overcirculation, paradoxal septal motion and enlargement of the main pulmonary artery (Oliveira *et al.,* 2011). Adult dogs with ASD may develop cardiac insufficiency in due course, secondary to myxomatous mitral valve degeneration (Cavalcanti *et al.,* 2011).

Medical management

Following institution of therapy with angiotensin converting enzyme inhibitor (ACEi), diuretics and calcium sensitizers, alleviation of signs were noticed from day 7-14 with an improvement in energy levels, physical activity and overall, well-being among the present symptomatic dogs. All the dogs survived a near normal life and the survival period ranged between 3 yr to 6 yr after the diagnosis and initiation of therapy. Treatment of small septal defects may not be necessary. Palliative treatment and medical management of septal defects of larger size and for those with heart failure signs include arterial vasodilation to reduce the severity of the shunt along with diuretics and angiotensin converting enzyme inhibitors. Positive inotropic drugs may be needed if there is myocardial failure, often as a result of severe aortic insufficiency (Cavalcanti *et al.,* 2011). Usually, the prognosis depends on the severity of the defect, the dogs with isolated and small-sized ASD is usually good (Guglielmini *et al.,* 2002).

CONCLUSION

ASD in dogs is relatively rare congenital heart disease that is diagnosed incidentally as majority of cases were asymptomatic or presented with non cardiac signs. The echocardiography helps to diagnose and the prognosis is usually fair to good if the defect is small and without any other congenital heart disease. However, the diagnosis of any congenital heart disease in dog population is also important to eliminate further breeding.

Conflict of interest

All authors declare that they have no conflict of interest.

REFERENCES

Allworth, S.M., Church, D.B., Maddison, J.E., Einstein, R., Brennar, P., Anssein, N.A. and Mathews, R. (1995). Effect of enalapril in dogs with pacing induced heart failure. American Journal of Veterinary Research. 56: 86-94.

Caivano, D., Dickson, D., Martin, M. and Rishniw, M. (2018). Murmur intensity in adult dogs with pulmonic and subaortic stenosis reflects disease severity. Journal of Small Animal Practice. 59: 161-166.

Cavalcanti, G.A.O., Tatibana, L.S., Pimenta, C.N., Val, A.P.C., Carneiro, R.A. and Araújo, R.B. (2009). Atrial Septal Defect in an Adult Dog. World Small Animal Veterinary Association World Congress Proceedings, UK, London.

Cavalcanti, G.A.O., Tatibana, L.S., Varaschin, M.S., Araújo, R.B. and Costa Val, A.P. (2011). Atrial septal defect in an elderly dog. Arquivo Brasileiro de Medicina Veterinária e Zootecnia (ABMVZ). 63(2): 503-507.

Chetboul, V., Charles, V., Nicolle, A., Sampedrano, C.C., Gouni, V., Pouchelon, J.L. and Tissier, R. (2006a). Retrospective study of 156 atrial septal defects in dogs and cats (2001-2005). Journal of Veterinary Medicine. Physiology, Pathology, Clinical Medicine. 53(4): 179-184.

Chetboul, V., Trolle, J.M., Nicolle, A., Sampedrano, C.C., Gouni, V., Laforge, H., Benalloul, T., Tissier, R. and Pouchelon, J.L. (2006b). Congenital heart diseases in the boxer dog: A retrospective study of 105 cases (1998-2005). Journal of Veterinary Medicine. Physiology, Pathology, Clinical Medicine. 53(7): 346-351.

Dominique Pennique and Marc-Andre d' Anjou. (2008). Atlas of Small Animal Ultrasonography, I edn. Blackwell Publishing, Australia.

Garncarz, M., Parzeniecka-Jaworska, M. and Szaluœ-Jordanow, O. (2017). Congenital heart defects in dogs: A retrospective study of 301 dogs. Medycyna Weterynaryjna. 73(10): 651-656.

Ghirlanda, S., Acerbi, A. and Herzog, H. (2014). Dog movie stars and dog breed popularity: A case study in media influence on choice. Public Library of Science (PLOS) One. 9: 1-5

Gugleilmini, C., Diana, A., Pietra, M. and Cipone, M. (2002). Atrial septal defect in five dogs. Journal of Small Animal Practice. 43(7): 317-322.

MacDonald, K.A. (2006). Congenital heart diseases of puppies and kittens. Veterinary Clinics North America Small Animal Practice. 36(3): 503-531.

Oliveira, P., Domenech, O., Silva, J., Vannini, S., Bussadori, R. and Bussadori, C. (2011). Retrospective review of congenital heart disease in 976 Dogs. Journal of Veterinary Internal Medicine. 25: 477-483.

Thomas, P.W., Gaber, C.E., Jacobs, G.J., Kaplan, P.M., Lombard, C.W., Moise, N.S. and Moses, B.L. (1994). Recommendations for standards in transthoracic two-dimensional echocardiography in the dog and cat. Veterinary Radiology and Ultrasound. 35: 173-178.