RESEARCH ARTICLE Indian Journal of Animal Research, Volume 58 Issue 6: 978-981 (June 2024)

Histochemical Studies on Post Natal Development of Gut Associated Lymphoid Tissue (GALT) of Intestine of Pati Duck (*Anas platyrhynchos domesticus*) of Assam

A. Deka[1], M. Talukdar[1], D.J. Talukdar[1]

10.18805/IJAR.B-4533

ABSTRACT

Background: The Pati duck constitutes a major indigenous duck variety in the state of Assam. The study of the gut associated lymphoid tissue (GALT) of Pati duck of Assam is of great value in regard to normal academic and bio-medical research aspects. It is also pre-requisite for correct diagnosis and evaluating the treatment of certain diseases like duck virus enteritis, duck cholera, aflatoxicosis, botulism *etc*, caused by different types of pathogens, food poisoning and food allergy.

Methods: The study was conducted on Pati duck of Assam in where 45 numbers of ducks were selected by irrespective of sex at different stages of development. The birds were divided into five groups depending on its age *viz.,* 1st week, 4th week, 16th week, 24th week and 42nd weeks old. The pieces of gut having lymphoid tissue or Peyer's patches were collected immediately after slaughter. Samples were made cryosections (-20°C) at 10 µm in thickness and were temporally stored at (-22°C). The histochemical staining was done after that.

Result: The acid phosphatase activity was weak in the lymphoid follicles of 1st and 4th week of age of Pati duck, while its activity was moderate in 16th, 24th and 42th week of age.The alkaline phosphatase activity was moderate reaction in the lymphoid follicles of 1st and 4th week of age of Pati duck, while its activity was intense in 16th, 24th and 42th week of age of duck. The lymphoid follicles of both Peyer's patches and solitary lymphoid nodules were showed moderate activity for adenosine tri-phosphatase activity in 1st and 4th week old Pati duck and strong activity in 16th, 24th and 42th week of age of Pati duck, respectively. The lymphoid nodules of intestine showed strong reaction for non-specific esterase activity in all the age groups of Pati duck.

Key words: GALT, Histochemical, Intestine, Pati duck, Postnatal.

INTRODUCTION

Now a day's poultry industry is the fastest growing industry in India. Duck is also one of the most important species in poultry industry and intensifying farming. Duck husbandry plays an important role in the socio-economic upliftment of the rural poor people of Assam. Theweird agro-climatic condition and having swampy and drenched areas existing in Assam provides a very congenial environment for rearing ducks (Deka *et al*., 2017). The popularity of duck is increasing in many areas of the world as ducks are one of the most versatile and useful of all domesticated animals and birds. India having 25.54 million of ducks (Population Division of the Department of Economic and Social Affairs of the United Nations Secretariat, 2014); out of that Assam possesses 8.4 million of ducks (Basic Animal Husbandry Statistics, 2014). As such Assam is one of the major duck rearing state in India. The Pati duck population constitutes a major indigenous duck variety in the state of Assam. The Annual egg production per Pati duck is 70-95 eggs, (Kalita *et al*., 2009). The study of the GALT of Pati duck of Assam is of great value in regard to normal academic and bio-medical research aspects. It is also pre-requisite for correct diagnosis and evaluating the treatment of certain diseases like duck virus enteritis, duck cholera, aflatoxicosis, botulism *etc*, caused by different types of pathogens, food poisoning and food allergy. The vaccination failure and failure to control the enteric disease is a cause of concern for poor farming community as it results in huge and irreparable economic loss. Since there is scanty of literature on histochemical studies of postnatal development of GALT of intestine of Pati duck at different stages of development being a local variety of Assam, hence the present study was designed to establish histo-chemical norms on, GALT of intestine at different stages of development of Pati duck of Assam.

[1]Department of Anatomy and Histology, College of Veterinary Science, Assam Agricultural University, Khanapara, Guwahati-781 022, Assam, India.

Corresponding Author: A. Deka, Department of Anatomy and Histology, College of Veterinary Science, Assam Agricultural University, Khanapara, Guwahati-781 022, Assam, India.
Email: dranilvet01@gmail.com

How to cite this article: Deka, A., Talukdar, M. and Talukdar, D.J. (2024). Histochemical Studies on Post Natal Development of Gut Associated Lymphoid Tissue (GALT) of Intestine of Pati Duck (*Anas platyrhynchos domesticus*) of Assam, Indian Journal of Animal Research. 58(6): 978-981. doi: 10.18805/IJAR.B-4533.

Submitted: 20-05-2021 **Accepted:** 13-09-2021 **Online:** 06-10-2021

MATERIALS AND METHODS

The study was conducted on Pati duck of Assam in 45 numbers of ducks were selected by irrespective of sex at different stages of development. The birds were divided into five groups depending on its age *viz.,* 1st week, 4th week, 16th week, 24th week and 42nd weeks old. The ducks were procured from Pathsala and nearby area of Barpeta district of Assam. The experiment was conducted in the Department of Anatomy and Histology, College of Veterinary Science, Assam Agricultural University, Khanapara, Guwahati for a period of five years and the ducks were slaughter according to the method of Gracy (1986). The plan of experiment was approved by Institutional Ethic committee. After slaughter, the birds were placed on a clean dissecting table, and skin and fascia were reflected carefully without disturbing the organs. The abdominal cavity of each experimental birds were exposed by making a ventro-median incision and then the abdominal muscle layers, peritoneum and air sacs of abdominal region were reflected properly. In duck, the lymphoid tissues were visible to the naked eyes but in other avian species, these lymphoid tissues were not visible in naked eye. Then, the pieces of gut having lymphoid tissue or Peyer's patches immediately collected. The samples were then preserved at liquid nitrogen (-196°C). Samples were made cryosections (-20°C) at 10µm in thickness and were temporally stored at (-22°C). The histochemical staining wasdone according to Gomori's alkaline phosphatase cobalt method and Gomori's method for acid phosphatase (Singh and Sulochana, 1978); Lead method for ATPase (Bancroft, 2008) and Gomori's method for non-specific esterase (Bancroft, 2008).

RESULTS AND DISCUSSION

The acid phosphates' activity was weak in the lymphoid follicles of intestine of 1 stand 4th week of age of Pati duck, while its activity was moderate in 16th, 24th and 42th week of age of duck (Fig 1, 2 and Table 1). Gedam *et al*. (2017) reported that acid phosphatase activity was weak in lymphoid follicle of 6th week old Kadaknath fowl on the other hand its intensity was more in 18th week of age. It might be due to different age groups and agro-climatic condition of the birds whereas Raju *et al*. (2012) observed that an intense enzyme activity was observed in the follicle associated epithelium and a dome area of ileal Peyer's patches. A strong activity in the inter follicular region and a mild activity of the enzyme in the capsule were observed in the ileal peyer's patches. A pattern of enzyme activity was noticed in the follicles.

The alkaline phosphatase activity was moderate reaction in the lymphoid follicles of intestine of 1st and 4th week of age of Pati duck, while its activity was intense in 16th, 24th and 42th week of age (Fig 3, 4 and Table 1). Gedam *et al*. (2017) revealed that the alkaline phosphatase activity was weak to moderate in lymphoid follicle and then increased from moderate to strong in lymphatic of 6th, 12th and 18th week old of Kadaknath fowl.

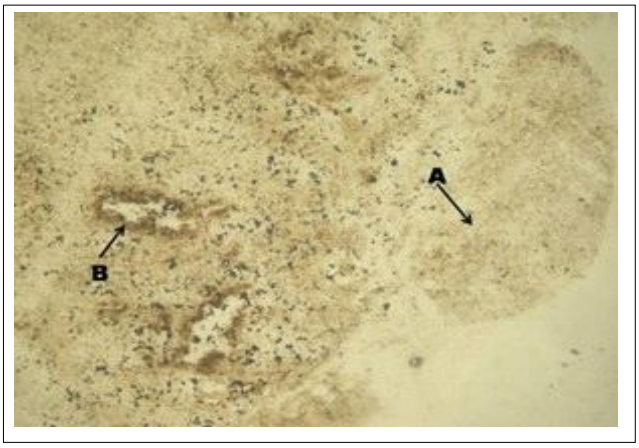

Fig 1: Photomicrograph showing the acid phosphatase activity in lymphatic nodule (a) and intestinal gland (b) on 4th week old Pati duck. gomori's, ×10.

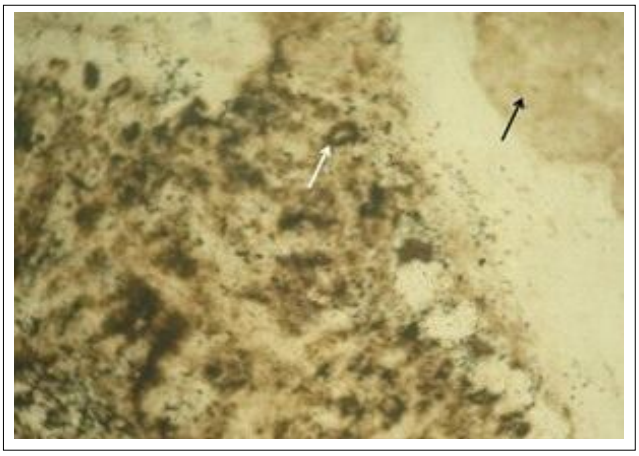

Fig 2: Photomicrograph showing the acid phosphatase activity in lymphatic nodule (black arrow) and intestinal gland (white arrow) on 24th week old Pati duck. gomori's, ×10.

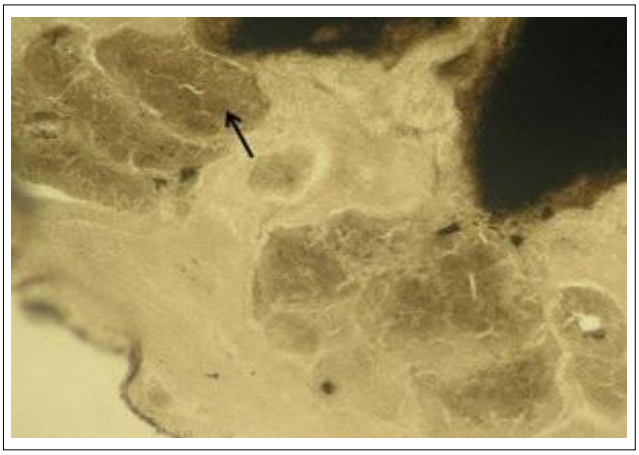

Fig 3: Photomicrograph showing the alkaline phosphatase activity in lymphatic nodule (black arrow) on 4th week old Pati duck. gomori's, ×10.

Representative samples from the small and large intestines of Pati duck were assessed for presence of ATPase. The lymphoid follicles of both Peyer's patches and solitary lymphoid nodules were showed moderate activity for adenosine tri-phosphatase activity in 1st week and 4th week old Pati duck and strong activity in 16th, 24th and 42th week of age, respectively (Fig 5, 6 and Table 1).

The lymphoid nodules of intestine showed strong reaction for non specific esterase activity in all the age groups of Pati duck (Fig 7 and Table 1). However, it could not be comparable due to paucity of literature.

Table 1: Histochemical characterization of lymphatic nodule (LN) of intestine of Pati duck.

Histoenzymes	Intestine				
	1st week	4th week	16th week	24th week	42nd week
	LN	LN	LN	LN	LN
Acid phosphatase	+	+	++	++	++
Alkaline phosphatase	++	++	++++	++++	++++
Adenosine tri phophatase	++	++	+++	+++	+++
Non specific esterase	+++	+++	+++	+++	+++

Gradation for intensity of histochemical reaction: - = Negative; + = Weak; ++ = Moderate; +++ = Strong; ++++ = Intense.

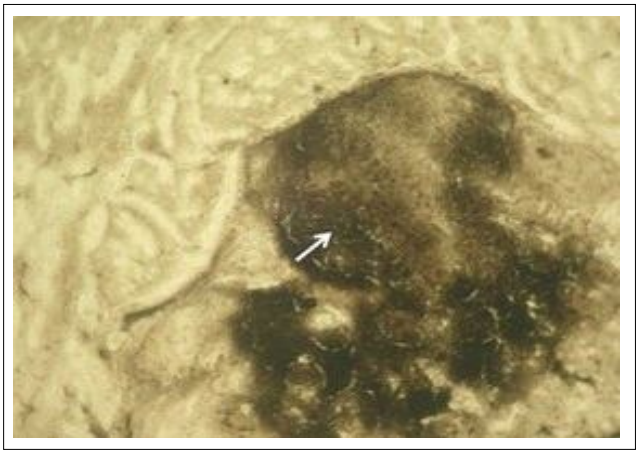

Fig 4: Photomicrograph showing the alkaline phosphatase activity in lymphatic nodule (black arrow) on 24th week old Pati duck. gomori's, ×10.

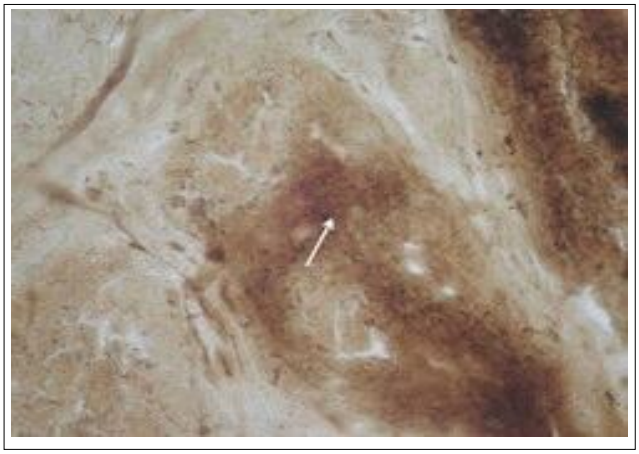

Fig 6: Photomicrograph showing the atpase activity in lymphatic nodule (white arrow) on 42th week old Pati duck. Lead method, ×10.



Fig 5: Photomicrograph showing the atpase activity in lymphatic nodule (black arrow) on 4th week old Pati duck. Lead method, ×10.

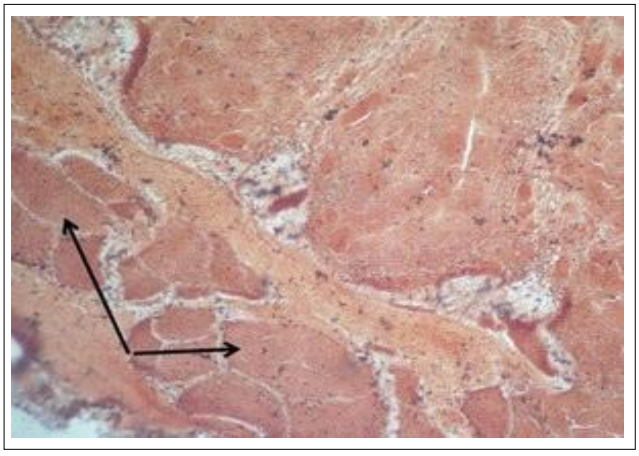

Fig 7: Photomicrograph showing the non specific esterase activity in lymphatic nodule (black arrow) on 42th week old Pati duck.1-naphthyl acetate method, ×10.

CONCLUSION

The acid phosphatase activity was weak in the lymphoid follicles of 1st and 4th week of age of Pati duck, while its activity was moderate in 16th, 24th and 42th week of age of duck. A strong activity in the inter follicular region and a mild activity of the enzyme in the capsule were observed in the ileal peyer's patches. A pattern of enzyme activity was noticed in the follicles. The alkaline phosphatase activity was moderate reaction in the lymphoid follicles of 1st and 4th week of age of Pati duck, while its activity was intense in 16th, 24th and 42th week of age. The lymphoid follicles of both Peyer's patches and solitary lymphoid nodules were showed moderate activity for adenosine tri-phosphatase activity in 1st week and 4th week old Pati duck and strong activity in 16th, 24th and 42th week of age, respectively. The lymphoid nodules of intestine showed strong reaction for non specific esterase activity in all the age groups of Pati duck.

Conflict of interest

All authors declare that they have no conflict of interest.

REFERENCES

Bancroft, J.D. (2008). In: Theory and Practices of Histological Technique. Churchill Livingstone, Elsevier Health Sciences. 6th Edn. pp. 267-272.

Deka, A., Sarma, K., Sarma, S., Goswami, J., Mahanta, J. and Talukdar, D. (2017). Comparative biochemical parameters studies on Pati and Chara-Chemballi ducks (*Anas platyrhynchos domesticus*) during their laying periods. International Journal of Livestock Research. 7(2): 110-114.

Gedam, D.P., Salankar, D.A., Nandeshwar, D.N., Mainde, D.U.P., Rama, D.T., Panda, D.R., Ravinkanth, D.V. and Mainda, D.U.P. (2017). Histochemical studies on intestinal lymphoid tissue in Kadaknath breed of poultry (*Gallus gallus domesticus*). International Journal of Science and Environment. 6(3): 2132-2136.

Gracy, J.F. (1986). In: Bleeding Method of Slaughtering-Slaughter. Meat Hygiene. 8th edn. pp. 144-145.

Kalita, N., Barua, N., Bhuyan, J. and Chidananda, B.L. (2009). Present status of duck farming in Assam. Proceeding of IV world waterfowl conference held at Thrissur, Kerala, India. pp. 359-363.

Raju, N.K.B., Ramesh, G., Basha, S.H., Ushakumary, S. and Kumar, R.S. (2012). Histochemical studies on the peyer's patches of sheep (*Ovis aries*). Global Journal of Medicine and Research. 12(6): 11-14.

Singh, U.B. and Sulochana, S. (1978). In: A Laboratory Manual of Histological and Histochemical Technique. Kothari Medical Publishing House, Bombay, 1st Edn. pp. 50-55.