RESEARCH ARTICLE Indian Journal of Animal Research, Volume 57 Issue 9: 1152-1156 (September 2023)

Gerontological Studies on the Micrometry of Liver of Bakerwali Goat

Lovish Sethi[1], Shalini Suri[1], Jasvinder Singh Sasan[1]

10.18805/IJAR.B-4555

ABSTRACT

Background: Goat husbandry has been playing an important role in the economy of our country with special reference to milk, meat, manure and hide production. Bakerwali goat constitutes about 50% of the total goat population of J and K. The liver is an extremely important organ in the body of mammals performing numerous functions. The liver is much heavier in young animals than older animals as it atrophies with age. The present study has been planned to record the micrometrical data about the liver of Bakerwali goat during different age groups.

Methods: Liver samples were collected from slaughter houses of Nagrota in and around Jammu city of UT of J and K during 2019-20. The samples were divided into young (below 1 year), adult (2-3 years) and senile (4 years and above) as per the dentition of the goats. Six samples from each age group were collected. The micrometrical observations were recorded on H and E stained sections with the help of an ocular micrometer duly calibrated with stage micrometer.

Result: The capsule showed maximum thickness in adults followed by the young and senile age group. The maximum thickness of the capsule was seen at upper part of main lobe (UPOML) in the liver of young and adult whereas, in the senile group, the maximum thickness was seen at middle part of main lobe (MPOML). The diameter of the central vein showed the highest values in adults, followed by young and senile probably due to increased liver functions in adult. The mean values of length of hepatocytes ranged between 13.50 to 22.50 µm in all regions of the liver of irrespective of age groups. The mean values showed higher values in adult and senile age groups. The nuclear diameter of the hepatocytes ranged between 9.00 to 13.50 µm with mean values varying between 9.72±0.58 to 10.05±0.50 µm in all the three age groups. The maximum number of portal triads per field was seen at ventral part of main lobe (VPOML) in the senile group whereas the minimum number was observed at MPOML in the young group. In general, several portal triads per field were highest in the senile group followed by adult and young.

Key words: Bakerwali goat, Gerontological studies, Liver, Micrometry.

INTRODUCTION

Goats are important livestock species in developing countries. It is sometimes referred to as “Poor Man’s Cow” in India and the ‘wet nurse’ of infants in Europe (Iqbal *et al.,* 2008). Goats are among the oldest domesticated species very useful to humans. Research on this species has been largely neglected, especially on its anatomy (Bhattarai, 2012). It is the most popular breed of rearing with the economically weaker population of India (Suman *et al.,* 2005). Goat husbandry has been playing an important role in the economy of our country with special reference to milk, meat, manure and hide production (Arora *et al.,* 2013). According to FAO (2010), goats provide 5,43,00 tons meat, 40,00,000 tons milk, 1,29,960 tons hide and 85,000 metric tons of manure per year in India. Thus, it contributes 2443.3 crores per annum to the national economy which is 3.5% of the total income from agriculture and 10.1% of the income incurred from the livestock sector (FAO, 2010).

Bakerwali goat is a specific breed of Jammu and Kashmir. It constitutes about 50% of the total goat population of UT of JandK (Gupta and Bakshi, 2009). ‘Bakerwali’ word is derived from the Hindi or Urdu Indic language terms, (Bakri or Bakara) meaning goat or sheep and wal meaning “one who takes care of”. Essentially, the name “Bakerwal” implies “high-altitude goatherds/shepherds”(Kapoor *et al.,* 1990).

[1]Division of Veterinary Anatomy, Faculty of Veterinary Sciences and Animal Husbandry, Sher-e-Kashmir University of Agricultural Sciences and Technology of Jammu, R.S. Pura-181 102, Jammu and Kashmir, India.

Corresponding Author: Singh Sasan, Division of Veterinary Anatomy, Faculty of Veterinary Sciences and Animal Husbandry, Sher-e-Kashmir University of Agricultural Sciences and Technology of Jammu, R.S. Pura-181 102, Jammu and Kashmir, India.
Email: jssasan216@gmail.com

How to cite this article: Sethi, L., Suri, S. and Sasan, J.S. (2023). Gerontological Studies on the Micrometry of Liver of Bakerwali Goat. Indian Journal of Animal Research. 57(9): 1152-1156. doi: 10.18805/IJAR.B-4555.

Submitted: 03-06-2021 **Accepted:** 09-11-2021 **Online:** 15-12-2021

The liver (hepar) is an extremely important organ in the body of mammals and vertebrates as it provides functions essential for life. It is the largest internal gland in the body, constituting 1-2% of total adult body weight (Frandson *et al*., 2009). The liver has numerous functions including the production of bile and protein, fat and carbohydrate metabolism. The size of the liver varies due to its role in metabolism. The liver is much heavier in young animals than older animals as it atrophies with age (Dyce *et al.,* 2010).

Micrometrical information about the liver of Bakerwali goat is meager. Hence, the present study was planned to record the micrometrical data about the liver of Bakerwali goats during different age groups.

MATERIALS AND METHODS

The present study was carried out in the Division of Veterinary Anatomy, F.V.Sc and A.H., SKUAST-Jammu.

Collection of samples

Liver samples of Bakerwali goats were collected from slaughter houses of Nagrota in and around Jammu city of UT of J&K. The samples were divided into three age groups *i.e.* young (below 1 year), adult (2-3 years) and senile (4 years and above) as per the dentition of the goats. Six samples from each age group were collected. Immediately after collection, the liver samples were brought to the laboratory in ice. The samples from each group were preserved in 10% neutral buffered formalin for histomorphometric studies. The micrometrical observations were recorded on Hematoxylin and Eosin stained sections with the help of an ocular micrometer duly calibrated with a stage micrometer. Different micrometrical observations were recorded at six levels *i.e.* upper part of the main lobe (UPOML), middle part of the main lobe (MPOML), ventral part of the main lobe (VPOML), caudate lobe (CL), at the level of the oesophageal notch (ON) and portal area (PA) in all three age groups. The following micrometrical observations were recorded:

1. Thickness of capsule of liver (µm) (Fig 1).
2. Diameter of the central vein (µm) (Fig 2).
3. Inter central vein distance (µm) (Fig 3).
4. Size of hepatocytes (Length) (µm) (Fig 4).
5. Nuclear diameter of the hepatocytes (µm) (Fig 4).
6. Number of liver lobules per field.
7. Number of portal triad per field.

All the recorded data were put to Standard Statistical procedures (Snedecor and Cochran, 2004) to find Students "t" test using the 11.0 version of SPSS software.

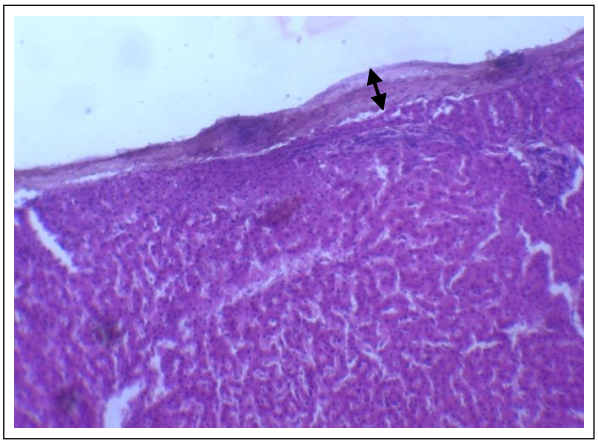

Fig 1: Photomicrograph of liver showing area of capsule of liver in adult Bakerwali goat used for micrometry, H&E, 10X.

RESULTS AND DISCUSSION

Thickness of capsule of liver (µm)

The micrometrical data regarding thickness of capsule of liver has been presented in Table 1a. The capsule showed maximum thickness in adults followed by the young and

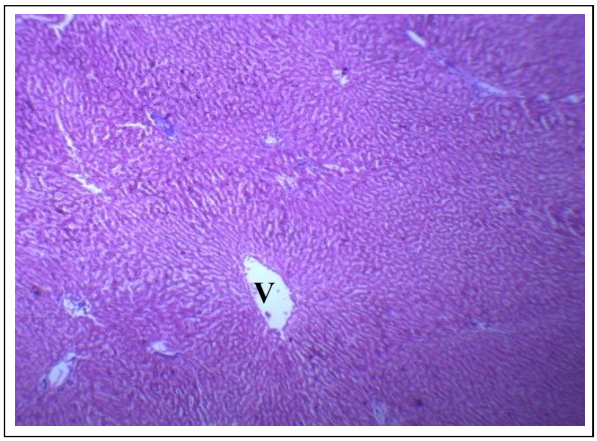

Fig 2: Photomicrograph of liver showing area used for micrometry of central vein (V), H&E, 10X.

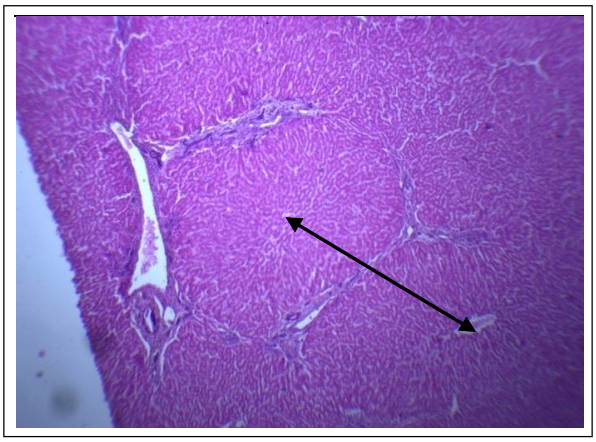

Fig 3: Photomicrograph of liver showing micrometry of inter-central vein distance, H&E, 4X.



Fig 4: Photomicrograph of liver showing micrometry of size of hepatocyte (H) and nuclear diameter (N), H&E, 100X.

senile age group. A similar pattern was observed at different levels *i.e.* VPOML, CL, ON and PA level (Table 1a). The maximum thickness of the capsule was seen at the upper part of main lobe (UPOML) in the liver of young and adults whereas in the senile group, the maximum thickness was seen at middle part of main lobe (MPOML). Choudhury and Singh (2020) recorded the average thickness of the capsule of liver of sheep during the prenatal period which comprised of Group 1 (0-50 days), Group 2 (51-100 days) and Group 3 (101-150 days) of gestation and Group 4 comprised of sheep below one year of age as 6.08±0.18 µm, 9.87±0.15 µm, 11.94±0.60 µm and 41.58±1.52 µm, respectively and suggested a progressive increase in the thickness of the capsule of liver with age. In the liver of an adult pig, the mean capsule thickness was 58.03±4.87 microns (Sasan *et al*., 2017).

Diameter of the central vein (µm) (Table 1a)

The mean diameter of the central vein at the level of UPOML was 109.74±14.86 µm, 120.85±16.43 µm and 91.68±7.25 µm in young, adult and senile, respectively. The mean diameter of the central vein at the level of MPOML was 109.46±16.00 µm, 118.96±6.31 µm and 105.86±12.66 µm in young, adult and senile, respectively. The same at the level of VPOML was 105.02±15.42 µm, 114.18±15.91 µm and 107.86±15.23 µm in young, adult and senile, respectively. At CL, the mean diameter was 105.75±24.05 µm, 113.91±21.89 µm and 108.35±15.42 µm in young, adult and senile, respectively. The mean diameter at the level of on was 103.97±20.36 µm, 115.86±25.14 µm and 103.58±16.13 µm in young, adult and senile, respectively. At the level of PA, the mean diameter was 103.92±25.20 µm, 114.69±28.32 µm and 104.69±13.99 µm in young, adult and senile, respectively. The diameter of the central vein showed highest values in adult, followed by young and senile probably due to increased liver functions in adult. Choudhury and Singh (2020) also reported that the average diameter of central vein of liver was 67.32±2.89 µm, 102.59±2.03 µm, 122.85±1.86 µm and 140.01±1.70 µm in Group 1 (0-50), Group 2 (51-100), Group 3 (101-150) days of gestation and Group 4 comprised of sheep below one year of age, respectively and suggested a progressive increase in diameter of the central vein of liver with age, statistically analysed a positive correlation between age and diameter of hepatocytes, as the age increases the diameter of the central vein also increases. In pigs, the diameter was 149.25±12.13 microns (Sasan *et al*., 2017).

Inter central vein distance (µm) (Table 1b)

The mean inter central vein distance at level of UPOML was 670.52±133.61 µm, 808.49±83.46 µm and 615.15±67.94 µm in young, adult and senile, respectively. The same at the level of MPOML was 683.45±86.23 µm, 780.71±101.54 µm and 619.82±89.52 µm in young, adult and senile, respectively. The mean inter central vein distance at the level of VPOML was 669.83±79.72 µm, 764.02±62.97 µm and 616.54±81.13 µm in young, adult and senile, respectively. The mean inter central vein distance at the level of CL was 684.87±109.78 µm, 784.84±110.81 µm and 620.15±111.69 µm in young, adult and senile, respectively. At the level of ON, the values for the young, adult and senile group were 669.57±124.45 µm, 720.95±81.97 µm and 617.91±69.92 µm, respectively. At the level of PA, the values were 657.11±114.36 µm, 758.50±102.38 µm and 610.56±62.05 µm in three age groups, respectively. Choudhury and Singh (2020) recorded the average inter central vein distance of liver as 140.41±3.99 µm, 264.38±10.83 µm, 295.00±19.62 µm and 402.12±36.44 µm in Group 1 (0-50), Group 2 (51-100), Group 3 (101-150) days of gestation and Group 4 comprised of sheep below one year of age, respectively and found a progressive increase in inter central vein distance of liver with age. Similar findings were made by Liman (1996) in the liver of sheep. He recorded the distance between the two adjacent central veins as 629.77±34.70 µm in the lambs, while 740.00±14.35 µm in adults. This increase was directly proportional to age.

Table 1a: Micrometrical parameters of different regions of liver of Bakerwali goat in different age groups.

Different lobes of liver	Thickness of capsule (µm)			Diameter of the central vein (µm)		
	Young	Adult	Senile	Young	Adult	Senile
UPOML	43.06±3.21	47.50±2.17[a]	38.89±2.37	109.74±14.86	120.85±16.43	94.46±8.29
	(33.34-66.68)	(33.34-50.01)	(33.34-50.01)	(50.01-216.71)	(50.01-216.71)	(50.01-133.36)
MPOML	42.01±4.10[a]	44.45±4.27	39.18±8.50[a]	109.46±16.00	118.96±6.31a	105.86±12.66[a]
	(33.34-66.68)	(33.34-66.68)	(33.34-56.68)	(50.01-200.05)	(50.01-213.36)	(83.35-200.05)
VPOML	43.06±3.22	47.23±4.95	38.12±1.87	105.02±15.42	114.18±15.91	107.86±15.23
	(16.67-66.68)	(33.34-83.35)	(33.34-50.01)	(66.68-206.72)	(50.01-250.05)	(83.35-250.05)
CL	41.05±4.33	41.91±4.10	37.51±2.17	105.75±24.05[a]	113.91±21.89	108.35±15.42
	(33.34-83.35)	(33.34-66.68)	(33.34-50.01)	(66.68-200.72)	(50.01-333.40)	(50.01-200.04)
At the level of ON	43.06±2.17	47.23±2.17	38.84±5.08	103.97±20.36	115.86±25.14	103.58±16.13
	(33.34-83.35)	(33.34-50.01)	(33.34-66.35)	(50.01-250.05)	(50.01-383.41)	(66.68-266.72)
PA	41.67±3.24	46.45±3.74	38.50±2.17	103.92±25.20	114.69±28.32	104.69±13.99[a]
	(33.34-66.68)	(33.34-66.68)	(33.34-50.01)	(66.68-366.74)	(50.01-333.40)	(66.68-200.04)

*Mean with different superscripts within the respective age group (young, adult and senile) in a row differ significantly (P≤0.05).

Table 1b: Micrometrical parameters of different regions of liver of Bakerwali goat in different age groups.

Different lobes	Inter central vein distance (µm)			Size of hepatocytes (Length) (µm)		
of liver	Young	Adult	Senile	Young	Adult	Senile
UPOML	670.52±133.61	808.49±83.46	615.15±67.94	16.12±0.86[a]	18.62±1.03[a]	17.02±1.10[a]
	(466.70-1700.34)	(466.72-1450.25)	(666.78-1333.60)	(13.50-22.50)	(13.50-22.50)	(13.50-22.50)
MPOML	683.45±86.23	780.71±101.54	619.82±89.52	16.12±0.86	18.12±0.86	17.60±0.84
	(433.38-1083.55)	(450.05-1333.60)	(450.05-1183.57)	(13.50-22.50)	(13.50-22.50)	(13.50-22.50)
VPOML	669.83±79.72[a]	764.02±62.97	616.54±81.13[a]	16.62±1.03	18.50±0.84	17.50±1.01
	(300.02-1000.20)	(383.39-1016.85)	(383.39-1233.58)	(13.50-22.50)	(13.50-22.50)	(13.50-22.50)
CL	684.87±109.78	784.84±110.81	620.15±111.69	16.50±0.84	18.00±1.10	17.62±1.03[a]
	(33.34-1133.56)	(166.70-1333.60)	(266.72-1566.98)	(13.50-22.50)	(13.50-22.50)	(13.50-22.50)
At the level of ON	669.57±124.45[a]	720.95±81.97	617.91±69.92[a]	17.60±1.10	18.50±1.01[a]	17.42±0.86
	(316.69-1667.00)	(200.04-1166.90)	(366.74-1250.25)	(13.50-22.50)	(13.50-22.50)	(13.50-22.50)
PA	657.11±114.36	758.50±102.38	610.56±62.05	16.50±1.01	18.62±1.03	17.62±1.03[a]
	(350.03-1233.64)	(333.40-1333.60)	(400.12-1216.95)	(13.50-22.50)	(13.50-22.50)	(13.50-22.50)

*Mean with different superscripts with in respective age group (young, adult and senile) in a row differ significantly (P≤0.05).

Table 1c: Micrometrical parameters of different regions of liver of Bakerwali goat in different age groups.

Different lobes	Nuclear diameter of the hepatocytes (µm)		
of liver	Young	Adult	Senile
UPOML	9.75±0.50	10.12±0.58	10.12±0.58
	(9.00-13.50)	(9.00-13.50)	(9.00-13.50)
MPOML	9.72±0.58	10.12±0.58	10.12±0.58
	(9.00-13.50)	(9.00-13.50)	(9.00-13.50)
VPOML	10.12±0.58	10.12±0.58	10.12±0.58
	(9.00-13.50)	(9.00-13.50)	(9.00-13.50)
CL	10.50±0.58	10.12±0.58	10.12±0.58
	(9.00-13.50)	(9.00-13.50)	(9.00-13.50)
At the level of ON	10.12±0.58	10.12±0.58	10.05±0.58
	(9.00-13.50)	(9.00-13.50)	(9.00-13.50)
PA	10.12±0.58	10.50±0.58	10.12±0.58
	(9.00-13.50)	(9.00-13.50)	(9.00-13.50)

*Mean with different superscripts with in respective age group (young, adult and senile) in a row differ significantly (P≤0.05).

Size of hepatocytes (Length) (µm)

The mean values of length of hepatocytes ranged between 13.50 to 22.50 µm in all regions of the liver of irrespective of age groups. The detailed values are given in Table 1b. The mean values showed higher values in adult and senile age groups. Aziz and Khatra (1985) in sheep reported that the diameter of hepatocytes was 16.08±0.30 µm and the ratio between nucleus and hepatocytes diameter was 1:2.1. Similar findings were reported by Khan and Prasad (1989) in black Bengal goat where diameter of hepatocytes was 16.30±0.40 µm and the ratio between hepatocytes and nuclei diameter was 1:2.49. Liman (1996) studied sheep liver during postnatal stages and reported that the cell size (long diameter) was 14.32±0.33 and 16.30±0.42 µm in young and adults, respectively. This increase was directly proportional to age. Modekar *et al.* (2003) in goats recorded the mean values of length of hepatocytes as 16.08±0.02 µm. Choudhury and Singh (2020) observed the average diameter of hepatocytes of the liver in Group 1(0-50), Group 2 (51-100), Group 3 (101-150) days of gestation and Group 4 comprised of sheep below one year of age was found to be 8.80±0.11 µm, 10.10±0.18 µm, 13.04±0.36 µm and 16.45±0.48 µm, respectively and suggested a progressive increase in diameter of hepatocytes of liver with age. The estimated diameter of hepatic cells in pig liver was 12.86±0.49 micron with a range from 9.25 to 14.80 micron (Sasan *et al.*, 2017).

Nuclear diameter of the hepatocytes (µm)

The nuclear diameter of the hepatocytes ranged between 9.00 to 13.50 µm with mean values varying between 9.72±0.58 to 10.05±0.50 µm in all the three age groups (Table 1c). Khan and Prasad (1989) in black Bengal goat observed that the diameter of the nucleus was 6.70±0.17 µm. Liman (1996) studied liver in sheep at postnatal stages and recorded the nuclear size (long diameter) as 6.92±0.19 and 6.70±0.17 µm in young and adult respectively. Modekar *et al.* (2003) in goats recorded the nuclear diameter of hepatocytes as 7.56±0.01 µm. Choudhury and Singh (2020) reported the average nuclear diameter of hepatocytes of the liver as 5.08±0.09 µm, 5.96±0.07 µm, 6.32±0.11 µm and 6.99±0.13 µm in Group 1(0-50), Group 2 (51-100), Group 3 (101-150) days of gestation and Group 4 comprised of sheep below one year of age, respectively. Their data suggested a progressive increase in the nuclear diameter of hepatocytes of the liver with age. The diameter of the nuclei of hepatic cells was 6.65±0.48 microns in pig (Sasan *et al.,* 2017).

Number of liver lobules per field (Table 1d)

The number of liver lobules per field of the liver was recorded in all three age groups at 40X. The mean number of liver lobules at the level of UPOML was 3.91±0.31, 4.58±0.33 and 5.25±0.50 in young, adult and senile, respectively. The mean number of liver lobules at the level of MPOML was 7.00±0.33, 8.60±0.38 and 12.58±0.48 in young, adult and senile, respectively. At the level of VPOML, the mean number

Table 1d: Micrometrical parameters of different regions of liver of Bakerwali goat in different age groups.

Different lobes	Number of liver lobules per field			Number of portal traids per field		
of liver	Young	Adult	Senile	Young	Adult	Senile
UPOML	3.91±0.31[a]	4.58±0.33[a]	5.25±0.50[a]	3.80±0.19	3.33±0.41	3.61±0.14
	(2.00-6.00)	(3.00-7.00)	(2.00-7.00)	(2.00-4.00)	(2.00-5.00)	(2.00-5.00)
MPOML	7.00±0.33[a]	8.60±0.38[a]	12.58±0.48[a]	3.03±0.14	3.08±0.38	4.91±0.25
	(3.00-8.00)	(4.00-10.00)	(10.00-15.00)	(2.00-4.00)	(2.00-6.00)	(3.00-6.00)
VPOML	5.75±0.50[a]	6.75±0.46[a]	9.08±0.35[a]	3.05±0.32	4.08±0.41[a]	4.96±0.29
	(5.00-10.00)	(4.00-10.00)	(5.00-12.00)	(2.00-4.00)	(3.00-6.00)	(2.00-6.00)
CL	4.33±0.24	5.33±0.30	6.08±1.37	3.58±0.48	4.33±0.41	4.58±0.22[a]
	(3.00-6.00)	(4.00-7.00)	(2.00-10.00)	(2.00-6.00)	(2.00-6.00)	(2.00-6.00)
At the level of ON	4.75±0.37	6.61±0.60	6.25±0.55[a]	3.66±0.56	4.90±0.36	4.83±0.16[a]
	(3.00-7.00)	(5.00-10.00)	(4.00-12.00)	(2.00-6.00)	(2.00-6.00)	(2.00-7.00)
PA	5.58±0.49	5.00±0.56	6.63±0.70[a]	3.68±0.37	3.80±0.29[a]	4.25±0.30[a]
	(4.00-8.00)	(3.00-9.00)	(3.00-10.00)	(2.00-5.00)	(3.00-6.00)	(2.00-6.00)

*Mean with different superscripts with in respective age group (young, adult and senile) in a row differ significantly (P≤0.05).

in young, adult and senile group was 5.75±0.50, 6.75±0.46 and 9.08±0.35, respectively. The mean number at the level of CL was 4.33±0.24, 5.33±0.30 and 6.08±1.37 in young, adult and senile, respectively. Liman (1996) reported the number of hepatocytes per unit area as 133.60±7.01 and 100.84±6.63 in lamb and adult liver of sheep, respectively. The number of hepatocytes reached the peak point on 1.5 month-old lambs and then arrived at adult levels in 8 month-old lambs by gradually decreasing.

Number of portal triads per field

The number of portal triads per field was recorded in all three age groups at 40X. The mean number of portal triad per field at level of UPOML was 3.80±0.19, 3.33±0.41 and 3.61±0.14 in young, adult and senile, respectively. The number of portal traids per field was also recorded at different levels *i.e*. MPOML, VPOML, CL, at levels of ON and PA level and mean values are given in (Table 1d). The maximum number of portal triads per field was seen at VPOML in the senile group (4.96±0.29) whereas the minimum number was observed at MPOML in the young group (3.03±0.14). In general, the number of portal triads per field was highest in the senile group followed by adult and young.

CONCLUSION

From the study, it can be concluded that most of the micrometrical parameters were highest in adults as compared to the young and senile group probably due to increased liver functions in adults. The number of liver lobules per field and number of portal triads per field were highest in the senile group as compared to the young and adult group.

REFERENCES

Arora, R., Bhojak, N. and Joshi, R. (2013). Comparative aspacts of goat and cow milk. International Journal of Engineering Science Invention. 2(1): 7-10.

Aziz, S.H. and Khatra, G.S. (1985). Quantitative histomorphology of liver lobule and gall bladder of sheep. Indian Journal of Animal Sciences. 55: 428-430.

Bhattarai, R.R. (2012). Importance of goat milk. J. Food Science and Technology Nepal. 7(1): 107-111.

Choudhury, A.R. and Singh, O. (2020). Micrometrical studies on the liver of sheep during prenatal and postnatal Development. Indian Journal of Veterinary Anatomy. 32(1): 65-66.

Dyce, K.M., Sack, W.O. and Wensing, C.J.G. (2010). The Text Book of Veterinary Anatomy, 4th Edn., W.B. Saunder's Company, Philadelphia. pp. 135-136.

FAOSTAT, (2010). http:/www.fao.org.

Frandson, R.D., Wilke, W.L. and Fails, A.D. (2009). Anatomy and Physiology of Farm Animals, 7th Edition.

Gupta, J.L. and Bakshi, S.B. (2009). Sheep Development in Temparate Region. Yak Book Publishers, Jammu. pp. 151-153.

Iqbal, A., Khan, B.B., Tariq, M. and Mirza, M.A. (2008). Goat-A potential dairy animal: Present and future prospects. Pakistan Journal Agricultural Sciences. 45(2): 227-230.

Kapoor, A.K., Rahna, H.K., Basu, D. and Kapoor, S. (1990). Ecology and Man in Himalayas. M.D. Publication, New Delhi. pp. 43-44.

Khan, M. and Prasad, J. (1989). Histology of the duct system of liver of black bengal goats. Indian Journal of Animal Sciences. 59: 945-948.

Liman, N. (1996). Quantitative histomorphology of liver growth in sheep at prenatal and postnatal Stages. Anatomia Histologia Embryologia. 25: 43-48.

Modekar, S.S., Bhosle, N.S. and Mamde, C.S. (2003). Morphological study of liver in Osmanabadi goat (*Capra hircus*). Indian Journal of Veterinary Anatomy. 15(1/2): 65-67.

Sasan, J.S., Sharma, A., Sarma, K., Suri, S. and Malik, M.R. (2017). A quantitative histological study of the liver of pig (*Sus Scrofa*). Indian Veterinary Journal. 94(03): 14-16.

Snedecor, G.W. and Cochran, W.G. (2004). Statistical Methods, 8th Edn. Oxford and IBH Pub. Co., Kolkata.

Suman, Gupta, A.N. and Jain, R.K. (2005). Histomorphology and histochemistry of respiratory bronchiole during postnatal development in goat. Haryana Veterinarian. 44: 55-59.