RESEARCH ARTICLE Indian Journal of Animal Research, Volume 57 Issue 5: 650-655 (May 2023)

Detection of Multiple Hepatic Peribiliary Cysts in Captive Lions (*Panthera leo*)

V. Manjunatha[1], M. Rout[2], N. Jaisingh[3], B.P. Shankar[1], K.S. Umashankar[3]

10.18805/IJAR.B-4671

ABSTRACT

Background: Hepatic lesions in non-domestic felids are poorly characterized. The present study reports multiple hepatic peribiliary cysts in 9 out of 32 lions (*Panthera leo*) at Bannerghatta Biological Park, Bengaluru.

Methods: The animals were presented for necropsy after the history of clinical signs of lethargy, anorexia, weakness, debilitated body conditions and all animals are in old age (between 15 to 25 years old). Systematic necropsy with gross and histopathological examination was carried out.

Result: Post-mortem examination grossly revealed multiple cysts in liver (varying in each case) with the cystic masses filled with clear fluid, sometimes mixed with bile. A diagnosis for the presence of spontaneous peribiliary cysts was made on the basis of gross and microscopic lesions. Histologically, the cysts were surrounded and composed of compact collagenous tissue. The inner cystic single layer resembled biliary mucosa and composed of columnar epithelial lining, while the submucosa was composed of connective tissue with loss of hepatic cord structure.

Key words: Histopathology, Lion, Liver, Peribiliary cysts.

INTRODUCTION

Peribiliary cysts, otherwise known as cystic dilatation of the peribiliary ducts are one of the most recent findings encountered in liver cystic abnormalities. Peribiliary cysts are characterized by multiple cysts along the portal radicle and result from the cystic dilatation of intrahepatic extramural peribiliary ducts around the large hepatic bile ducts (Seguchi *et al*., 2004). These peribiliary cysts have mostly been reported in advanced liver disease in humans (Fujioka *et al.,* 1997). Peribiliary cysts share a close similarity with hepatobiliary cystadenoma reported in cats, dogs, horses, sheep and pig (Adler and Wilson, 1995) and is characterized by the presence of multiple cystic masses of thin-walled cysts containing watery mucin-like fluids. The tumour is often raised above the liver capsular surface involving more than one lobe (Yu *et al*., 2007). The present study reports multiple hepatic peribiliary cysts in 9 out of 32 necropsied captive lions at the Rescue Centre of Bannerghatta Biological Park (BBP), Bengaluru, Karnataka over a period of 7 years during 2013-2020.

MATERIALS AND METHODS

Necropsy examination of 32 lions were conducted at the Rescue Centre at BBP, Bengaluru during 2013-2020. The lions were referred to the Zoo Hospital at BBP with historical signs of lethargy, anorexia, decubital ulcers, weakness and emaciated body condition (Fig 1) despite treatment with antibiotics and supportive fluid therapy. The carcasses were grossly examined and macroscopic abnormalities in the organs were observed and photographed. Appropriate hepatic tissues were collected and fixed in 10% neutral buffered formalin, processed and embedded in paraffin. Tissue sections were cut to 5 µm thickness and stained with hematoxylin and eosin (H&E) (Lee and Luna, 1968) for observation in light microscopy.

[1]Wild Animal Disease Diagnostic Laboratory, Institute of Animal Health and Veterinary Biologicals, Bannerghatta Biological Park, Bannerghatta-560 083, Bengaluru, Karnataka, India.
[2]ICAR-Directorate of Foot and Mouth Disease, IVRI Campus, Mukteswar-263 138, Nainital, Uttarakhand, India.
[3]Zoo Hospital, Bannerghatta Biological Park, Bannerghatta-560 083, Bengaluru, Karnataka, India.

Corresponding Author: V. Manjunatha, Wild Animal Disease Diagnostic Laboratory, Institute of Animal Health and Veterinary Biologicals, Bannerghatta Biological Park, Bannerghatta-560 083, Bengaluru, Karnataka, India. Email: manjuvet330@gmail.com

How to cite this article: Manjunatha, V., Rout, M., Jaisingh, N., Shankar, B.P. and Umashankar, K.S. (2023). Detection of Multiple Hepatic Peribiliary Cysts in Captive Lions (*Panthera leo*). Indian Journal of Animal Research. 57(5): 650-655. doi: 10.18805/IJAR.B-4671.

Submitted: 11-06-2021 **Accepted:** 20-05-2022 **Online:** 16-07-2022

RESULTS AND DISCUSSION

Multiple hepatic peribiliary cysts were observed in 9 out of 32 lions upon gross post-mortem examination with the cystic masses all over the liver parenchyma and bulging on the surface of liver lobes (Fig 2A and B). Macroscopically, the cysts were round to oval shaped with variable sizes. These were located not only beneath the serous membrane but also in the parenchyma. The liver cystic spaces with clear serous fluid were visible when the liver parenchyma was cut open (Fig 3A and B) and were located along the bile ducts around the hepatic hilus and in the large intra-hepatic



Fig 1: A 20 years old dead lion with decubital ulcers and emaciated body condition.

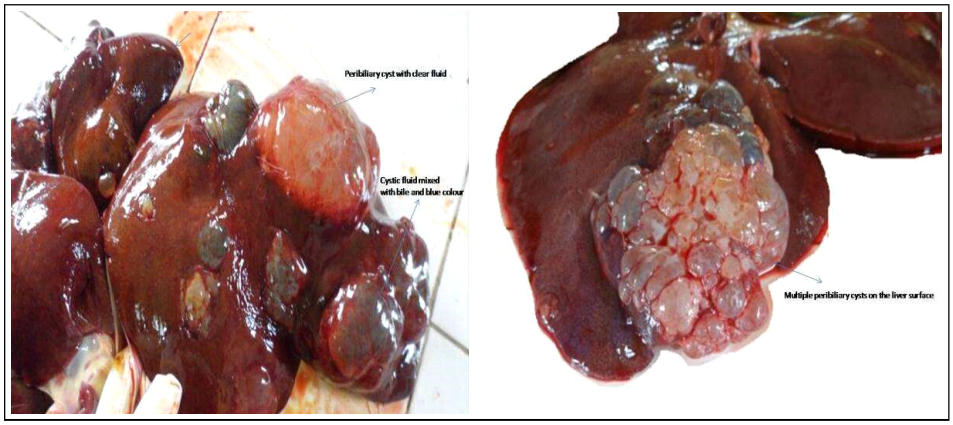

Fig 2: A and B: Multiple cysts in the liver parenchyma and bulging on the liver surface.

portal areas. In some cysts the fluid was mixed with bile appearing to be green in colour. Of course, there was no communication between the cysts and the lumen of the bile ducts. No other organs, including kidneys, spleen, heart, muscles and regional lymph nodes revealed obvious gross lesions.

Microscopically, the cysts were lined by a single layer of columnar epithelium surrounded by abundant connective fibrous tissue and mature collagen. The cysts were located in the portal area composed of artery, vein, and bile ducts (Fig 8). Cellular atypia, necrosis, inflammatory reactions were not observed. Liver parenchyma outside the cyst was unremarkable. The peribiliary cyst mucosa was covering the columnar epithelium (Fig 4 and 5). The multiple liver cysts in the present study were diagnosed as peribiliary cysts by histopathologic examination. Histologically, peribiliary cysts vary in size and are lined by a single layer of columnar epithelial cells and do not communicate with the lumen of bile ducts. The liver parenchyma contained many micro-cysts (empty spaces) all over the parenchyma especially around the liver triad (Fig 8, 9 and 10). Some authors reported cysts located within the connective tissue of the hepatic hilus and also within the larger portal tracts, whereas congenital cysts derived from bile ducts are found within parenchyma (Seguchi *et al.,* 2004). The cysts in the present case contained serous fluid, unlike those in the previous report (Webster and Summers, 1978) supporting that the cysts were derived from peribiliary glands. The present report notably provides evidence that peribiliary cysts known to occur in humans can also be found in non-domestic captive felid, such as in lions. Peribiliary cysts should be considered in the differential diagnosis of cystic hepatobiliary neoplasms in domestic animals. Bernard *et al.* (2015) have reported hepatic lesions in ninety captive, non-domestic felids including tigers, cougars, and lions confirming a significantly increased occurrence of biliary cystic lesions in lions compared with other non-domestic felids. There are records of three case reports of biliary cysts in lions (Yu *et al.,* 2007; Gerhauser *et al.,* 2009; Lucena *et al.,* 2011). In the present study, multiple micro-cysts were found around the portal triad surrounding the portal vein along with evident bile ducts hyperplasia (Fig 6 and 7), the small micro-cyst lined by single columnar epithelial cells and evidence of rupture and formed large cyst accumulating non-inflammatory fluid in the cystic spaces (Fig 9 and 10). Histopathologic features of hepatic peribiliary cysts have also been described in a young

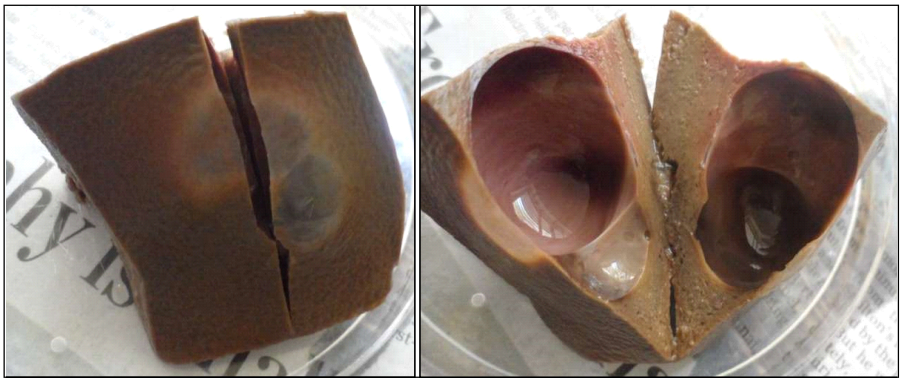

Fig 3: A and B: Cystic spaces in the liver incised with clear serous fluid inside.

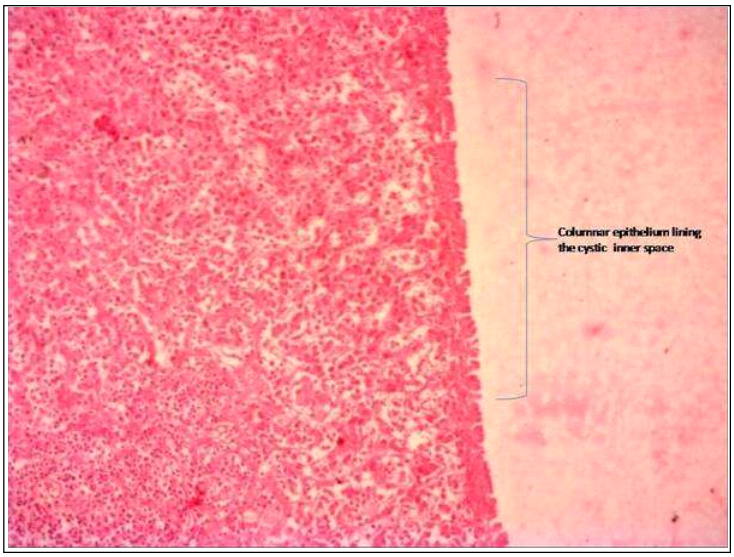

Fig 4: Cyst in the liver with columnar epithelium lining the cystic surface (Microscopic H&E 10X).

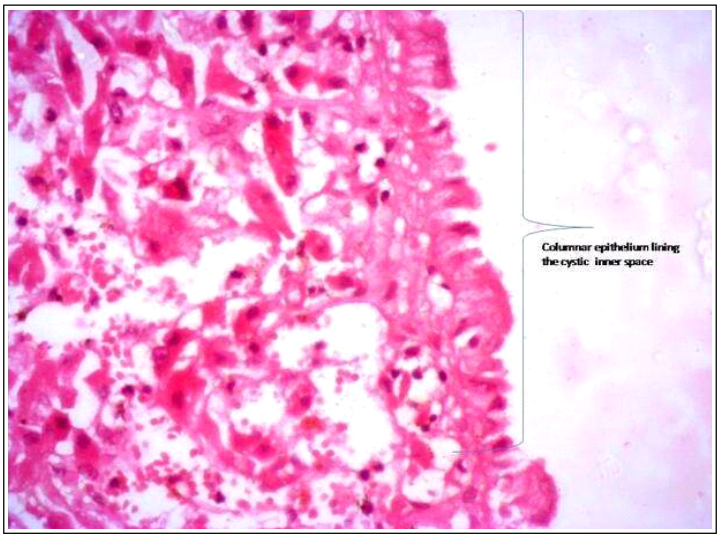

Fig 5: Cystic mucosa in the liver with columnar epithelium lining the cystic inner surface (Microscopic H&E 40X).

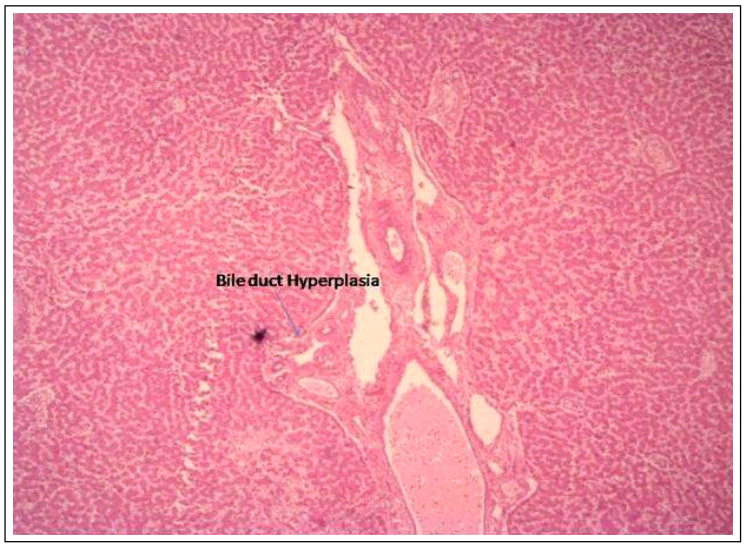

Fig 6: Cyst in the liver with bile duct hyperplasia around the portal triad (Microscopic H&E 10X).

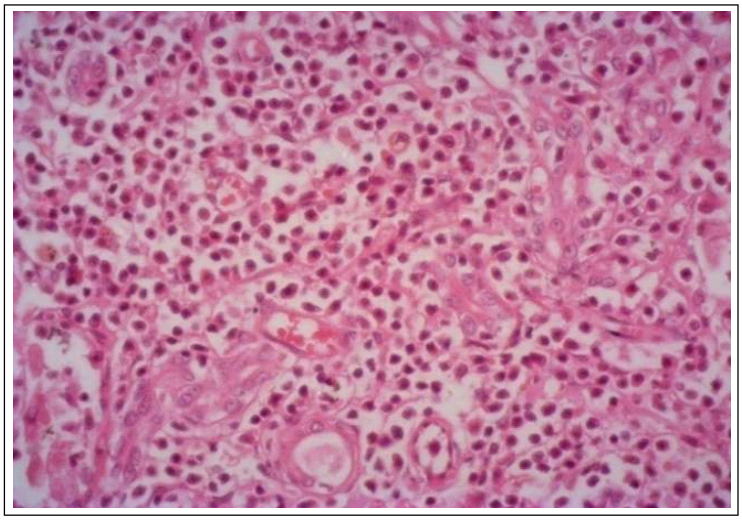

Fig 7: Cyst in the liver with bile duct hyperplasia around the portal triad (Microscopic H&E 40X).

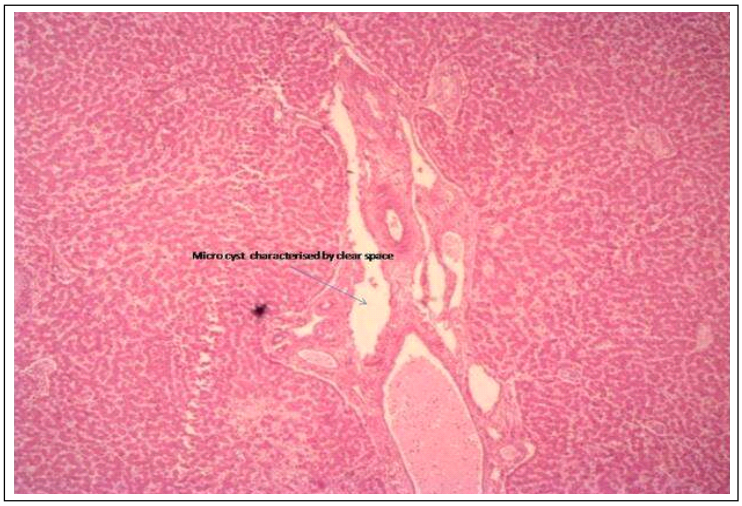

Fig 8: Micro-cystic spaces in the liver with bile duct hyperplasia around the portal triad (Microscopic H&E 4X).



Fig 9: Micro-cystic spaces in the liver with bile duct hyperplasia around the portal triad (Microscopic H&E 10X).

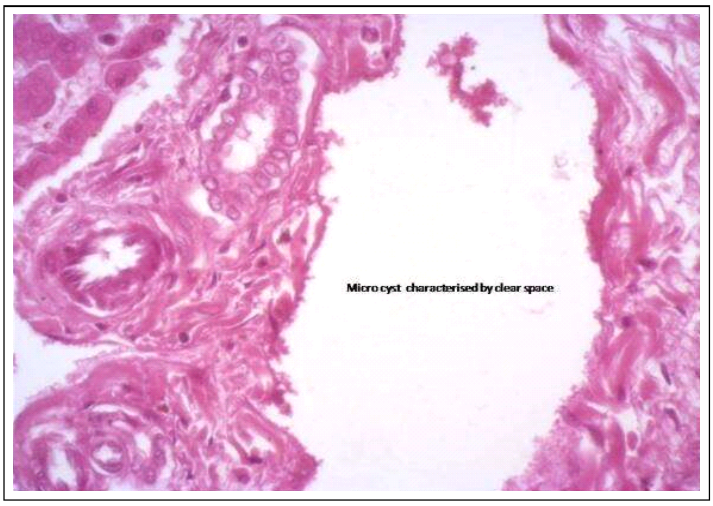

Fig 10: Micro-cystic space in the liver with bile duct hyperplasia around the portal triad (Microscopic H&E 40X).

slaughtered pig by Komine *et al.* (2007) that is the first case report of peribiliary cysts in an animal. The cysts were found to have been lined by a single layer of columnar epithelial cells.

The gross and histopathological findings in all 9 cases were suggestive towards diagnosis of peribiliary cysts also in agreement with the findings of Ishak *et al.* (1999) and Salvaggio *et al.* (2003). These peribiliary cysts were located in the connective tissue of hepatic hilus and also within the large intrahepatic portal tracts exhibiting abundant stromal component around the cysts. Biliary cystadenoma and peribiliary cysts reveal significant differences. Biliary cystadenoma has characteristic features of location of cysts in the parenchyma, mucin secreting epithelium, scant fibrous tissue and multiple layers of epithelial cells; whereas peribiliary cysts are mainly located in the portal area having non-mucin secreting epithelium, abundant fibrous tissue with a single layer of epithelial cells. Another neoplastic condition to be differentiated from peribiliary cysts is biliary adenofibroma, a morphological variant of biliary cystadenoma that is basically a solid lesion with microcysts not exceeding 2 mm (Salvaggio *et al.*, 2003). Peribiliary cysts differ from biliary adenofibroma by their gross appearance as a multilocular cystic mass with single cyst of variable size ranging from less than 10 mm to more than 38 mm (Nakanuma, 2001). Yu *et al.* (2007) also reported same case of peribiliary cyst in a 13-year-old male lion from Dae Jeon Zoo, Republic of Korea. The etiological factors behind peribiliary cysts are obscure. It is known that genetic background, chemical carcinogens such as nitrosamine, and hepatobiliary diseases may play a role in developing peribiliary cysts (Seguchi *et al.,* 2004). The disturbance of the portal venous flow has also been hypothesized to be a precipitating factor. It has further been postulated that periductal inflammation, fibrosis and portal venous

thrombosis could obliterate the necks of the peribiliary glands leading to the formation of retention cysts (Wanless *et al.,* 1987).

CONCLUSION

It could be concluded that multiple hepatic peribiliary cysts in the liver are mainly seen in lions of old age groups. The cysts are multiple with variable sizes. Thin walled cysts are filled with clear, straw colored fluid, while in few cases the fluid gets mixed with bile appearing green in color. The inner cyst wall is lined by single layer of columnar epithelium adjacent to bile ducts at the hepatic triad region. In some animals the entire liver parenchyma is replaced by cysts making the liver non functional that may lead to pathological liver condition and further complications. Further studies are required to know the cause and factors behind such peribiliary cystic liver condition in lions of old age groups, so that preventive measures can be taken.

ACKNOWLEDGEMENT

The authors thank the Assistant Director and staff of Zoo Hospital, Bannerghatta Biological Park for collecting the hosts and the Executive Director, Bannerghatta Biological Park, animal care-takers and supervisors for their support in the work.

Conflict of interest: None.

REFERENCES

Adler, R. and Wilson, D.W. (1995). Biliary cystadenoma of cats. Vet. Pathol. 32: 415-418.

Bernard, J.M., Newkirk, K.M., McRee, A.E., Whittemore, J.C. and Ramsay, E.C. (2015). Hepatic lesions in 90 captive nondomestic felids presented for autopsy. Vet. Pathol. 52(2): 369-376.

Fujioka, Y., Kawamura, N., Tanaka, S. *et al*. (1997). Multiple hilar cysts of the liver in patients with alcoholic cirrhosis: Report of three cases. J. Gastroenterol. Hepatol. 12: 137-143.

Gerhauser, I., Philipp, U., Distl, O., *et al*. (2009). Multiple cyst formation in the liver and kidneys of a lion (*Panthera leo*): A case of polycystic kidney disease? Eur. J. Wildl. Res. 55(4): 433-437.

Ishak, K.G., Goodman, Z.D. and Stocker, J.T. (1999). Tumors of the Liver and Intrahepatic Bile Ducts, 3rd Series, Armed Forces Institute of Pathology, Washington, DC. Pp. 57-59.

Komine, M., Kawasako, K., Akihara, Y., Shimoyama, Y., Okamoto, M., Matsuda, K., Hirayama, K. and Taniyama, H. (2007). Multiple hepatic peribiliary cysts in a young pig. Vet. Pathol. 44: 707-709.

Lee, G. and Luna, H.T. (1968). Manual of Histologic Staining Methods of the Armed Forces Institute of Pathology, 3rd edition, Mc Graw Hill Book Company, New York, Pp. 32-37.

Lucena, R.B., Fighera, R.A., Barros, C.S.L. (2011). Peribiliary cysts in an African lion. Pesq. Vet. Bras. 31(2): 165-168.

Nakanuma, Y. (2001). Peribiliary cysts, a hitherto poorly recognized disease [editorial]. J. Gastroenterol. Hepatol. 16: 1081-1083.

Salvaggio, A., Caracappa, S., Gurrera, A. and Magro, G. (2003). Hepatic biliary adenofibroma. Vet. Pathol. 40: 114-116.

Seguchi, T., Akiyama, Y., Itoh, H., *et al*. (2004) Multiple hepatic peribiliary cysts with cirrhosis. J. Gastroenterol. 39: 384-390.

Wanless, I.R., Zahradnik, J. and Heathcote, E.J. (1987). Hepatic cysts of periductal gland origin presenting as obstructive jaundice. Gastroenterol. 93: 894-898.

Webster, W.R. and Summers, P.M. (1978). Congenital polycystic kidney and liver syndrome in piglets. Aust. Vet. J. 54: 451.

Yu, C.H., Kim, K.T., Hwang, D.N., Young, Yhee, J., Moon, C.T., Hur, T.Y. and Sur, J.H. (2007). Peribiliary cysts associated with severe liver disease: A previously unrecognized tumor in a lion (*Panthera leo*): J. Vet. Diagn. Invest. 19: 709-712.