RESEARCH ARTICLE Indian Journal of Animal Research, Volume 57 Issue 5: 581-585 (May 2023)

Proliferating Cell Nuclear Antigen (PCNA) Localization in the Ovaries of Buffalo, Dog and Pig by Immunohistochemistry

Supriya Botlagunta[1], Deepa Pathipati[1], A.V.N. Siva Kumar[1]

10.18805/IJAR.B-4672

ABSTRACT

Background: It was expected from the previous studies that the immune histochemical staining for PCNA within follicular cells altered depending on the stage of follicular growth. Therefore, we aimed at determining the expression of proliferating cell nuclear antigen protein (PCNA) in the buffalo, dog and pig ovaries.

Methods: The localization of PCNA was demonstrated in formalin fixed, paraffin embedded tissue sections of buffalo, dog and pig ovaries using primary mouse monoclonal anti-PCNA antibody.

Result: Staining for PCNA was not observed in pregranulosa cells but observed in oocytes of primordial follicles. In primary to early secondary follicles, in oocytes and in few granulosa cells the positive staining was detected. The late secondary preantral follicles and actively growing small to large antral follicles showed strong PCNA labelling in the layers of granulosa and theca cells. PCNA staining was expressed in nuclei of oocytes in preantral and small antral follicles. The follicles demonstrating advanced atresia showed mild to no PCNA labelled granulosa and theca cells. The results of our study demonstrated that follicular growth and development in ovaries may be effectively monitored by determining the rate of granulosa cell proliferation of PCNA.

Key words: Buffalo ovary, Dog ovary, Follicular development, Immunohistochemistry, PCNA, Pig ovary.

INTRODUCTION

Proliferating cell nuclear antigen (PCNA) is a ring-shaped homotrimer that encircles the DNA (Boehm *et al*., 2016; Dieckman *et al*., 2012). It was a proven fact that PCNA is a marker for cellular proliferation (Strzalka and Ziemienowicz, 2011; Strzalka *et al*., 2015) and it orchestrated the events necessary for DNA synthesis, repair, damage avoidance, cell cycle control and cell survival (Prakash *et al*., 2005; Helleday *et al*., 2007; Mirkin and Mirkin, 2007; Stoimenov and Helleday, 2009; Sun *et al*., 2012; Yin *et al*., 2015). It is an ideal marker of cell proliferation in both non neoplastic and neoplastic cells. Because of its essential role in promoting proliferation, PCNA is an obvious target for cancer therapy (Wang, 2014).

PCNA was used to demonstrate the ovarian follicle counts in different laboratory and farm animal species (Muskhelishvili *et al*., 2002; Phoophitphong *et al*., 2012, Machado *et al*., 2018). Immunohistochemical localization of follicles and oocytes with proliferating cell nuclear antigen (PCNA) was reported in ovaries of rat (Oktay *et al*., 1995, Picut *et al*., 2008), mouse (Kerr *et al*., 2006), rabbit (Hutt *et al*., 2006), pig (Tomanek and Chronowska, 2006) and sheep (Patel *et al*., 2018). To our knowledge, there was no detailed study of proliferation process throughout the follicular development in buffalo and dog ovaries. Hence, the present study was undertaken with an objective of immunostaining of ovaries with PCNA in order to identify the distinct pattern of follicular cell proliferation in different follicular stages. The pattern of PCNA staining in the ovary was compared to previous studies in pig ovary.

[1]College of Veterinary Science, Sri Venkateswara Veterinary University, Tirupati-517 502, Andhra Pradesh, India.

Corresponding Author: Supriya Botlagunta, College of Veterinary Science, Sri Venkateswara Veterinary University, Tirupati-517 502, Andhra Pradesh, India. Email: supriyabotlagunta@gmail.com

How to cite this article: Botlagunta, S., Pathipati, D. and Siva Kumar, A.V.N. (2023). Proliferating Cell Nuclear Antigen (PCNA) Localization in the Ovaries of Buffalo, Dog and Pig By Immunohistochemistry. Indian Journal of Animal Research. 57(5): 581-585. doi: 10.18805/IJAR.B-4672.

Submitted: 11-06-2021 **Accepted:** 01-02-2022 **Online:** 12-04-2022

MATERIALS AND METHODS

The following immunohistochemistry work was conducted in the Department of Pathology, Padmavathi Medical College, SVIMS, Tirupati during 2018-19.

Sample collection and tissue handling

The ovaries of buffalo, pig was obtained from a local abattoir and those of dog were collected from the dogs underwent ovariohysterectomy as a part of animal birth control programme in Veterinary Clinical Complex, College of Veterinary Science, SVVU, Tirupati during 2021. The ovaries were transported to laboratory in a thermo-container filled with PBS at 37°C. Ovarian tissue was cut into small pieces and fixed in 10% neutral buffered formalin solution. After fixation, the specimens were dehydrated by ascending grades of ethyl alcohol, followed by clearing with xylene and they were embedded in paraffin (Merck, Germany). The pieces of ovarian tissue were serially sectioned at 5 µm with

the help of microtome (Leica RMZ 2125) and mounted on APES (Amino Propyl Triethoxy Silane) coated slides and incubated overnight at 37°C. These slides were subjected to the following immunohistochemistry protocol (Luna LG, 1968; Lynch, 1969).

Immunohistochemistry

Prior to PCNA localization, sections were deparaffinised by two changes of xylene 15 minutes each and rehydrated in decreasing concentrations of ethanol and PBS. The slides were kept in Tris EDTA buffer (pH-9.0) and subjected to heat induced epitope retrieval (HIER) treatment for 20 minutes at 100°C in a water bath to retrieve the antigenic sites and then cooled to the room temperature. The slides were kept in the distilled water for 5 minutes and in Tris buffer saline for 5 minutes. In order to block the endogenous peroxidase the slides were kept in the peroxidase block solution (3% hydrogen peroxide in methanol) for 10 minutes. Then slides were washed in Tris buffer saline for five minutes each in three changes. The power block solution using 1.5% bovine serum albumin (BSA) was poured on tissue section and kept for 30 minutes. Monoclonal mouse anti-PCNA (DAKO, Carpentaria, CA, USA: 1:200 dilution) was added on the sections and slides were kept at 4°C overnight. The next day, sections were washed in Tris buffer saline for five minutes each in three changes. The secondary antibody with horse radish peroxidase (HRP) was added and kept for 30 minutes at room temperature. Then sections were washed in Tris buffer saline for five minutes each in three changes. The binding of primary antibody was visualized using diaminobenzidine (DAB, Sigma, Germany) for 5-8 min. After washing with distilled water, sections were counterstained with Harris haematoxylin for 1 minute. The slides were washed in tap water for 5 minutes. For negative control, PBS was used instead of primary antibody. Then air dried and mounted with DPX. The PCNA labelling was

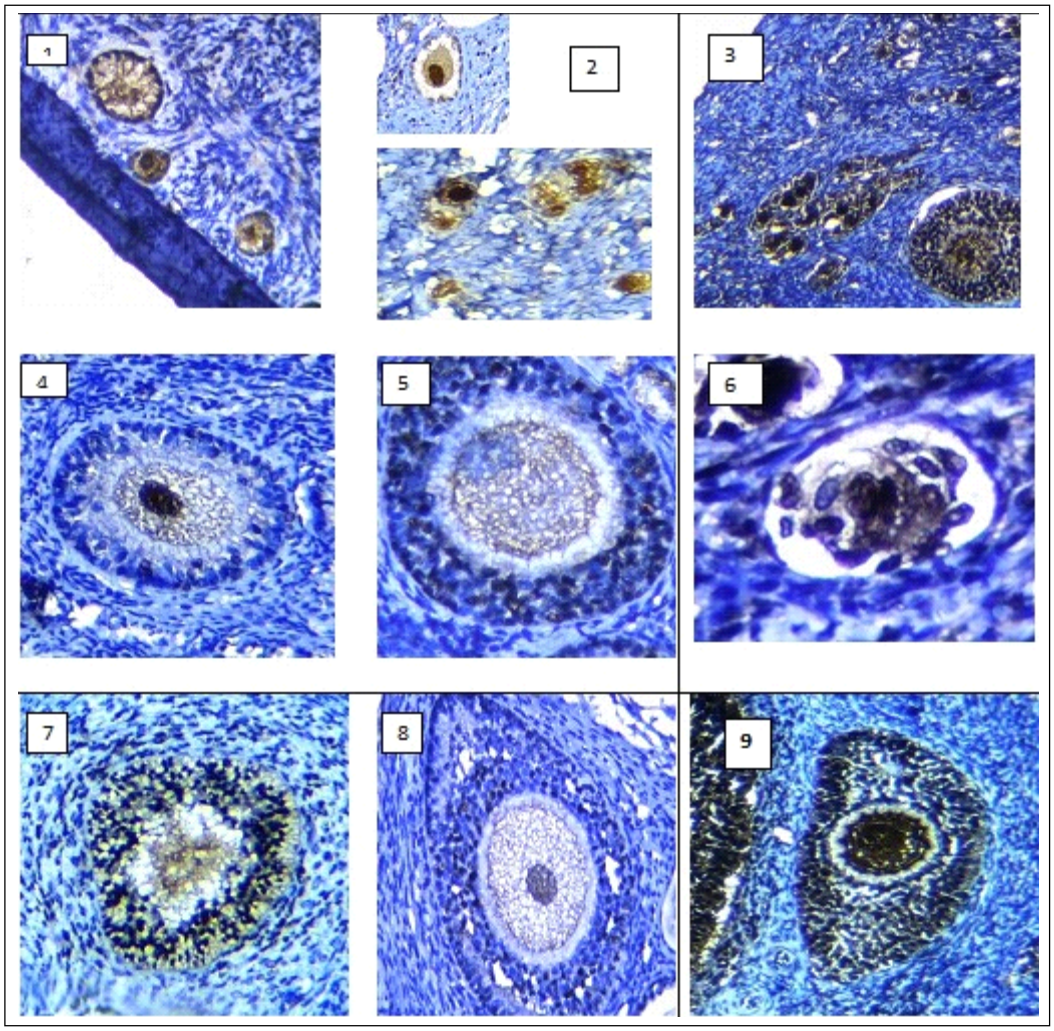

Fig 1-9: Different category of follicles with proliferating cell nuclear antigen (PCNA) immunohistochemical labelling (brown colour). 1- Primordial and primary follicles of buffalo, 2- Primordial and primary follicles of dog, 3- Cluster of primordial follicles of pig, 4- Early secondary follicles of dog, 5- Late secondary follicles of dog, 6- Secondary follicles of pig, 7,8,9- Early antral follicle of buffalo, dog and pig respectively.

examined using Leica DMLB microscope and the images were recorded by Leica DC 200 digital camera.

RESULTS AND DISCUSSION

Follicles were classified according to the stage of development, considering the shape, and layers of the granulosa cells (GC) as follows: primordial (oocyte surrounded by a flat pre granulosa cell layer), primary (one layer of cuboidal granulosa cells), secondary (two or more layers of cuboidal cells but without formation of vesicles), early antral (three or more layers of cuboidal granulosa cells and the presence of antrum) and large antral follicles (Da Silva-Buttkus *et al*., 2008). In the present study the intensity of reactivity was categorised as mild, moderate and strong.

The immunostaining with PCNA was multifactorial *i.e*., depending on the number of proliferating cells in the tissue sample, the concentration of primary antibodies, the pre-treatment of tissue with heat-induced epitope retrieval (HIER) technique, the type of fixative used (Muskhelishvili *et al*., 2005) and the time of fixation of the tissue (Takahashi *et al*., 1993).

The primordial follicles appeared as clusters in the connective tissue beneath the surface epithelium in case of pig, where as in most of the buffalo and dog ovaries they appeared mostly distributed in connective tissue as single follicles. The nucleus of ovum showed strong positive reactivity with PCNA (Fig 1, 2 and 3). Even though the ovum of primordial follicle was quiescent in diplotene stage of meiosis I (Byskov, 1982), it was possible that DNA polymerases were activated to repair potential damage to the genetic material in the oocytes selected to grow (Oktay *et al*., 1995).

The flat pregranulosa cells did not show immunoreactivity in all the three species under study (Fig 1, 2 and 3). These reports in pig were contrary with Phoophitphong *et al*. (2012) as they observed immunoreactivity in pregranulosa cells in addition to that of ovum. No immunostaining for PCNA in

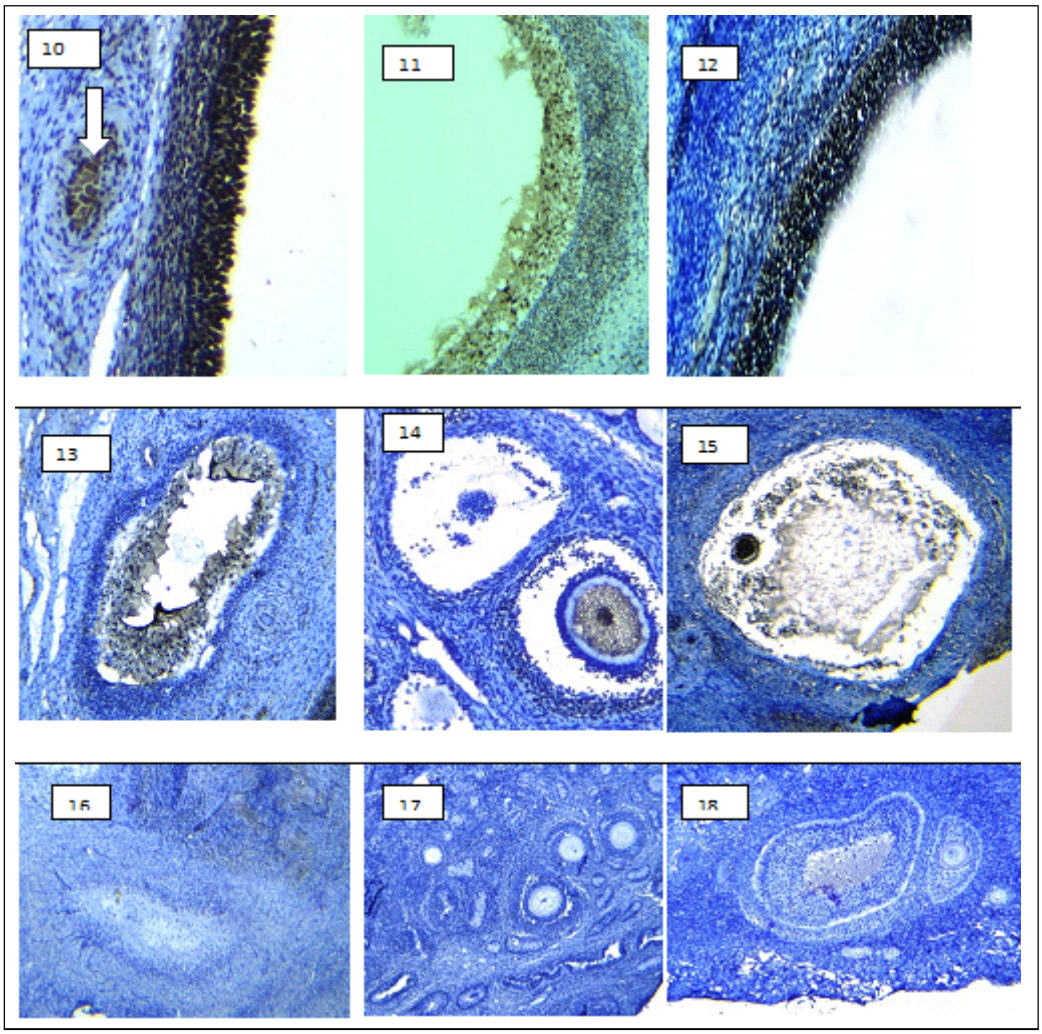

Fig 10-18: Different category of follicles with proliferating cell nuclear antigen (PCNA) immunohistochemical labelling (brown colour). 10- Wall of large antral follicle of buffalo showing granulosa and the theca layers with immunostained blood vessel (arrow), 11- Early atretic follicle of buffalo, 12- Wall of large antral follicle of pig, 13- Degenerating follicle of buffalo, 14- Degenerating follicles of dog, 15- Large degenerating follicle of pig, 16,17,18- Negative controls for buffalo, dog and pig respectively.

the primordial follicles (either in oocyte or in pregranulosa) was reported earlier in bovine (Wandji *et al*., 1996), baboon (Wandji *et al*., 1997) pig (Tomanek and Chronowska, 2006) and mouse (Rodrigues *et al*., 2009). Phoophitphong *et al*., (2012) standardised the technique for PCNA immunohistochemistry in pig ovaries by including antigen retrieval and using a dilution of 1:200 of mouse monoclonal anti-PCNA.

As the follicular development progresses the granulosa cells become cuboidal. The ovum of primary follicle in buffalo (Fig 1), dog (Fig 2) and pig showed strong immunorectivity. Only few cuboidal granulosa cells showed immunoreactivity in the primary and early secondary follicles in dog (Fig 2, 4, 5). One or two granulosa cells of the secondary follicles showed mild immunostaining in buffalo and pig (Fig 6).

The ovum of early antral follicles showed strong reactivity in all the species under study (Fig 7, 8, 9). All the granulosa cells of buffalo and pig showed moderate to strong reactivity (Fig 7, 9) whereas in dog few granulosa cells showed moderate immunoreactivity (Fig 8). The theca cells not showed immunostaining at this stage of follicular growth.

In antral follicles, the ovum showed moderate immunoreactivity in buffalo, dog and pig ovaries. The two different types of granulosa cells of large antral follicles displayed distinct patterns in that the cumulus granulosa cells were shown to divide more frequently than the mural granulosa cells (Hirshfield, 1986). Correspondingly, our studies with PCNA localization revealed more cumulus granulosa cells stained for PCNA as compared to the mural granulosa cells. The theca interna and its blood vessels showed moderate to strong immunostaining for PCNA in all the species under study (Fig 10, 12). These results were in accordance with previous studies that demonstrated a PCNA signal in different stages of follicular growth (Oktay *et al*., 1995; Tománek and Chronowska, 2006).

In degenerating follicles the granulosa and thecal cells were strongly immunoreactive in the initial stages of atresia. As the degeneration progress the immunostaining decreases and disappears (Fig 11, 13, 14 and 15). In all the species under study the intensity of PCNA immunostaining was negatively correlated to the stage of advance of atresia. We observed that the higher concentration of PCNA labelling in the healthy follicles than that of atretic follicles which is parallel to the findings of Feranil *et al*. (2004 and 2005). In the medulla the blood vessel wall was strongly stained by PCNA.

CONCLUSION

We observed that in all the species under study the PCNA immunostaining intensity decreased with the stage of advance of atresia and also higher concentration of PCNA labelling in the healthy follicles than that of atretic follicles.

ACKNOWLEDGEMENT

The authors thank S. Usha Nandini, Lab Technician, Department of Pathology, Padmavathi Medical College, SVIMS, Tirupati for her technical assistance during immunostaining procedure.

Conflict of interest

Authors certify that there is no conflict of interest with any financial organization regarding the material discussed in the manuscript.

REFERENCES

Boehm, E.M., Gildenberg, M.S. and Washington, M.T. (2016). The many roles of PCNA in eukaryotic DNA replication. The Enzymes. 39: 231-254.

Byskov, A.G. (1982). Primordial germ cells and regulation of meiosis. Reproduction in Mammals. 1: 1-16.

Da Silva Buttkus, P., Jayasooriya, G.S., Mora, J.M., Mobberley, M., Ryder, T.A., Baithun, M., Stark, J., Franks, S., Hardy, K. (2008). Effect of cell shape and packing density on granulosa cell proliferation and for mation of multiple layers during early follicle development in the ovary. Journal of Cell Science. 121: 3890-3900.

Dieckman, L.M., Freudenthal, B.D. and Washington, M.T. (2012). PCNA Structure and Function: Insights from Structures of PCNA Complexes and Post-translationally Modified PCNA. In The Eukaryotic Replisome: A Guide to Protein Structure and Function. 281-299.

Feranil, J.B., Isobe, N. and Nakao, T. (2004). Cell proliferation in the atretic follicles of buffalo and cattle ovary. Reproduction in Domestic Animals. 39: 405-409.

Feranil, J.B., Isobe, N. and Nakao, T. (2005). Apoptosis in the antral follicles of swamp buffalo and cattle ovary: TUNEL and caspase 3 histochemistry. Reproduction in Domestic Animals. 40: 111-116.

Helleday, T., Lo, J., van Gent, D.C. and Engelward, B.P. (2007). DNA double-strand break repair: From mechanistic understanding to cancer treatment. DNA Repair. 6: 923-935.

Hirshfield, A.N. (1986). Patterns of [3H] thymidine incorporation differ in immature rats and mature, cycling rats. Biology of Reproduction. 34: 229-235.

Hutt, K.J., McLaughlin, E.A. Holland, M.K. (2006). Primordial follicle activation and follicular development in the juvenile rabbit ovary. Cell Tissue and Research. 326: 809-822.

Kerr, J.B., Duckett, R., Myers, M., Britt, K.L. and Mladenovska, T. (2006). Quantification of healthy follicles in the neonatal and adult mouse ovary: Evidence for maintenance of primordial follicle supply. Reproduction. 132: 95-109.

Luna, L.G. (1968). Manual of Histologic Staining Methods of the Armed Forces Institute of Pathology, 3rd edition, New York.

Lynch, M.J. (1969). Medical Laboratory Technology and Clinical Pathology. W.B. Saunders Company, Philadelphia, London. Volume 1,

Machado, F.Z., Bergamo, L.Z., Bizarro-Silva, C., Morotti, F., Silva-Santos, K.C. and Seneda, M.M. (2018). Cell proliferation inovarian follicles from *Bos taurus* indicus females with different antral follicle count. Animal Reproduction. 14: 1307-1311.

Mirkin, E.V. and Mirkin, S.M. (2007). Replication fork stalling at natural impediments. Microbiolology and Molecular Biology Reviews. 71: 13-35.

Muskhelishvili, L., Freeman, L.D., Latendresse, J.R. and Bucci, T.J. (2002). An immuno-histochemical label to facilitate counting of ovarian follicles. Toxicologic Pathology. 30: 400-402.

Muskhelishvili, L., Wingard, S.K. and Latendresse, J.R. (2005). Proliferating cell nuclear antigen- A marker for ovarian follicle counts. Toxicologic Pathology. 33: 365-368.

Oktay, K., Schenken, R.S. and Nelson, J.F. (1995). Proliferating cell nuclear antigen marks the initiation of follicular growth in the rat. Biology of Reproduction. 53: 295-301.

Patel, H., Bhartiya, D. and Parte, S. (2018). Further characterization of adult sheep ovarian stem cells and their involvement in neo-oogenesis and follicle assembly. Journal of Ovarian Research. 11: 1-19.

Phoophitphong, D., Wangnaitham, S., Srisuwatanasagul, S. and Tummaruk, P. (2012). The use of proliferating cell nuclear antigen (PCNA) immuno-staining technique to determine number and type of follicles in the gilt ovary. Livestock Science. 150: 425-431.

Picut, C.A., Swanson, C.L., Scully, K.L., Roseman, V.C., Parker, R.F. and Remick, A.K. (2008). Ovarian follicle counts using proliferating cell nuclear antigen (PCNA) and semi-automated image analysis in rats. Toxicologic Pathology. 36: 674-679.

Prakash, S., Johnson, R.E. and Prakash, L. (2005). Eukaryotic translesion synthesis DNA polymerases: Specificity of structure and function. Annual Review of Biochemistry. 74: 317-353.

Rodrigues, P., Limback, D., McGinnis, L.K., Plancha, C.E. and Albertini, D.F. (2009). Multiple mechanisms of germ cell loss in the perinatal mouse ovary. Reproduction. 137: 709-720.

Stoimenov, I. and Helleday, T. (2009). PCNA on the crossroad of cancer. Biochemical Society Transactions. 37: 605-613.

Strzalka, W. and Ziemienowicz, A. (2011). Proliferating cell nuclear antigen (PCNA): A key factor in DNA replication and cell cycle regulation. Annals of Botany. 107: 1127-1140.

Strzalka, W.K., Aggarwal, C., Krzeszowiec, W., Jakubowska, A., Sztatelman, O. and Banas, A.K. (2015). Arabidopsis PCNAs form complexes with selected D-type cyclins. Frontiers in Plant Science. 6: 1-11.

Sun, Y.L., Zhang, J., Ping, Z.G., Wang, C.Q, Sun, Y.F., Chen, L., Li, X.Y, Li, C.J., Zhu, X.L., Liu, Z., Zhang, W. and Zhou, X. (2012). Relationship between apoptosis and proliferation in granulosa and teca cells of cystic follicles in sows. Reproduction in Domesticin Domestic Animals. 47: 601-608.

Takahashi, H., Oishi, Y., Oyaizu, T., Tsubura, A. and Moriiand Morii, S. (1993). Proliferating cell nuclear antigen (PCNA) immunohistochemistry: Influence of tissue fixation, processing and effects of antigen retrieval. Micron. 24: 385-388.

Tománek, M. and Chronowska, E. (2006). Immunohistochemical localization of proliferating cell nuclear antigen (PCNA) in the pig ovary. Folia Histochemica et Cytobiologica. 44: 269-274.

Wandji, S.A., Srsen, V., Nathanielsz, P.W., Eppig, J.J. and Fortune, J.E. (1997). Initiation of growth of baboon primordial follicles *in vitro*. Human Reproduction. 12: 1993-2001.

Wandji, S.A., Srsen, V., Voss, A.K., Eppig, J.J. and Fortune, J.E. (1996). Initiation *in vitro* of growth of bovine primordial follicles. Biology of Reproduction. 55: 942-948.

Wang, S.C. (2014). PCNA: A silent housekeeper or a potential therapeutic target? Trends in Pharmacological Sciences. 35: 178-1-86.

Yin, L., Xie, Y., Yin, S., Lv, X., Zhang, J., Gu, Z. and Liu, S. (2015). The S-nitrosylation status of PCNA localized in cytosol impacts the apoptotic pathway in a Parkinson's disease paradigm. PloS One. 10: e0117546.