RESEARCH ARTICLE Indian Journal of Animal Research, Volume 58 Issue 10: 1713-1717 (October 2024)

Histomorphological and Immunohistochemical Studies on Ovaries of Crossbred Dairy Cows with Ovarian Hypoplasia

V.R. Annie[1], K.M. Lucy[2]

10.18805/IJAR.B-4677

ABSTRACT

Background: Anatomical abnormalities of the ovaries can be responsible for a variety of reproductive problems, ranging from subfertility to sterility. The current study was aimed to evaluate the ovaries for histological variations and for the identification of Insulin-like Growth Factor Binding Protein- 2 (IGFBP-2) by Immunohistochemistry. IGFBP-2 was produced by ovarian tissues and was subjected to dynamic changes during follicle growth, differentiation and degeneration.

Methods: The study was conducted on the genitalia of 100 dairy cows/heifers collected from Meat Technology Unit, Mannuthy. Out of these 100 animals, three showed ovarian hypoplasia. Tissue samples from different regions were fixed in 10 per cent neutral buffered formalin. Standard procedures were adopted for histoarchitectural studies and samples were subjected to immunohistochemistry.

Result: Hypoplastic ovaries were appeared as small, wrinkled, flattened and elongated structures. Histologically, the ovary was not demarcated into a cortex and medulla distinctly. The ovaries were mostly devoid of ovarian follicles and corpora lutea. In partial hypoplastic ovaries, higher number of atretic follicles were noticed when compared with the normal ovary. Some of these atretic follicles showed a thickened zona pellucida. The granulosa cells surrounding the oocyte were degenerated. Tissue samples from the animals with ovarian hypoplasia showed a strong immunoreaction (for IGFBP-2) in the primordial and atretic follicles. The staining intensity and percentage of immunoreactive cells was comparatively higher than that of the control group. More number of IGFBP-2 blocked the positive effect of FSH and suppress steroidogenesis. The overall percentage of positive immunoreactive cells was more than 50 per cent with strongly positive staining intensity.

Key words: Dairy cows, Histomorphology, Immunohistochemistry, Ovarian hypoplasia.

INTRODUCTION

The productivity of cattle depends mainly on the functional status of the female reproductive tract. The functional ovary is essential for the production of healthy gametes and for hormone synthesis. Ovarian functions like follicular development, ovulation, corpus luteum (CL) formation, maintenance of pregnancy, *etc.* depend on the physiology of the ovary. Main cause of irregularity in these events involves structural abnormalities like ovarian hypoplasia and aplasia, follicular cyst, cystic corpora lutea, parovarian cysts, cystic bursa ovarica, periovaritis, adhesions, granulosa cell tumor, hemangioma, *etc* (Mohammed and Amin, 2016). Some of these anomalies occur in the foetus and can be inherited and is responsible for a variety of reproductive problems, ranging from subfertility to sterility. Ovarian hypoplasia is a condition of incomplete ovarian development where the ovary affected will be completely or partially inactive. Even though anatomical ovarian abnormalities are seen in only a small proportion of herds, these problems can interfere with breeding. Loss of two to three lactations due to poor reproductive efficiency causes great economic loss to the dairy farmers. Hence, the present work was undertaken to find out the incidence of ovarian hypoplasia in crossbred dairy cows and to study the histomorphology and immunohistochemistry of hypoplastic ovaries collected from the affected animals.

[1]Department of Veterinary Anatomy and Histology, College of Veterinary and Animal Sciences, Mannuthy, Thrissur-680 651, Kerala, India.

[2]Kerala Veterinary and Animal Sciences University, Pookode-673 576, Wayanad, Kerala, India.

Corresponding Author: V.R. Annie, Department of Veterinary Anatomy and Histology, College of Veterinary and Animal Sciences, Mannuthy, Thrissur-680 651, Kerala, India.
Email: annievraj@gmail.com

How to cite this article: Annie, V.R., Lucy, K.M. (2024). Histomorphological and Immunohistochemical Studies on Ovaries of Crossbred Dairy Cows with Ovarian Hypoplasia. Indian Journal of Animal Research. 58(10): 1713-1717. doi: 10.18805/IJAR.B-4677.

Submitted: 14-06-2021 **Accepted:** 23-08-2021 **Online:** 22-09-2021

MATERIALS AND METHODS

The present study was conducted on the female genitalia collected from 100 dairy cows/heifers from the Meat Technology Unit, Mannuthy during the period of 2018-2021. The animals brought for slaughter at Meat Technology Unit, Mannuthy were from herds of five different farms (University and Government Undertaking farms) in Kerala state. This included six animals culled on account of factors other than infertility with normal reproductive system (control group)

and the remaining animals with a known history of infertility. Out of 100 animals under study, three animals showed ovarian hypoplasia. This study was conducted in the Department of Veterinary Anatomy and Histology, College of Veterinary and Animal Sciences, Mannuthy, Thrissur, Kerala. After recording the gross features, tissue samples from different regions of the ovaries were fixed in 10 per cent neutral buffered formalin. Standard procedures were adopted for histoarchitectural studies. For the histological study Haematoxylin and Eosin (H&E), Masson's trichrome stain and Alcian blue stain were employed (Luna, 1968).

The ovarian tissue samples were also processed for immunohistochemical staining techniques. Standard procedure for immunohistochemistry was followed. The primary antibody was diluted at a ratio of 1: 50 and the tissue sections were incubated with this antibody for 24 h at 4°C in a humidified chamber. The stained section was graded for its staining intensity (SI) into four categories (0= no staining, 1= faintly, 2= moderately and 3= strongly positive) and for the calculation of approximate percentage of positively stained cells (PP) section was again categorized into four (0= no positive cells, 1= less than 10 per cent, 2= 10 to 50 per cent and 3= more than 50 per cent positive cells). Two immuno-reactive scores were calculated from the SI and the PP. The Immuno-Reactive Score I (IRS I) was calculated by summing SI and PP whereas the Immuno-Reactive Score II (IRS II) was calculated by multiplying SI and PP (Remmele *et al*., 1986).

RESULTS AND DISCUSSION

Morphology

Two cases of bilateral ovarian hypoplasia and one case of right unilateral ovarian hypoplasia were obtained during the study. Bilateral ovarian hypoplasia was found in animals of 22 months and 24 months of age. Ovaries appeared as pink-coloured, small, wrinkled, flattened and elongated structures without any follicles or CL (Fig 1). The first animal was found to be having complete bilateral ovarian hypoplasia. Measurements of the hypoplastic left ovary *viz*., length, width and thickness were recorded as 2.5 cm, 1.0 cm and 0.8 cm, respectively and that of the right ovary were 3.0 cm, 1.0 cm and 0.6 cm, respectively. The weight of the left and right ovaries was 2.5 g and 3.0 g, respectively. Kumar *et al*. (2014) categorized the ovarian hypoplasia into unilateral/bilateral/partial/complete and reported that animals with bilateral complete hypoplastic ovaries were sterile whereas, partial hypoplastic females were sub-fertile. The remaining tubular portion of the genital tract in these two animals were underdeveloped as reported by Gilmore (1949), Bhattacharya (1982) and Villagomez *et al*. (2009) in cattle.

Morphological examination of the ovaries of the second animal showed inactive, small, flat, streak-like left ovary without any cyclical structures. But the right ovary showed

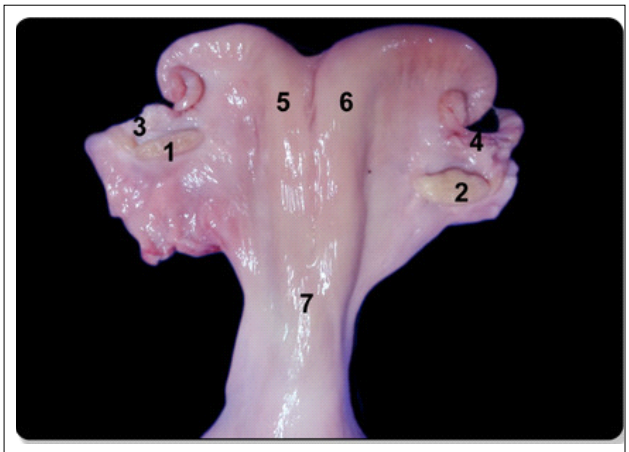

1. Left ovary, 2. Right ovary, 3. Left oviduct, 4. Right oviduct, 5. Left uterine horn, 6. Right uterine horn, 7. Body of uterus.

Fig 1: Genitalia of a heifer with complete bilateral ovarian hypoplasia.

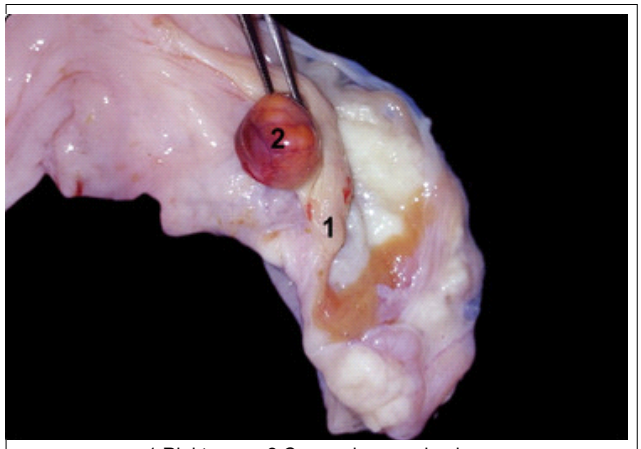

1.Right ovary 2.Corpus haemorrhagicum

Fig 2: Genitalia of a heifer with partial bilateral ovarian hypoplasia.

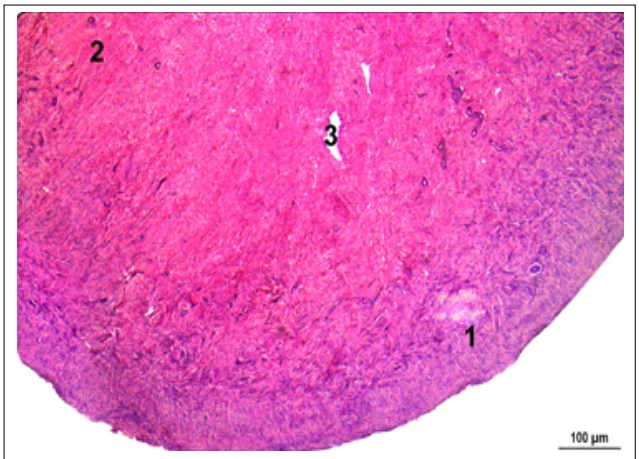

1. Cortex, 2. Medulla, 3. Venous sinus.

Fig 3: Section of ovary in a cow with complete bilateral ovarian hypoplasia. H&E × 100.

a single large corpus haemorrhagicum on the caudal end (Fig 2). No follicular structures could be located grossly. Thisanimal was considered as having bilateral partial ovarian hypoplasia. Measurements of the left ovary namely length, width and thickness were recorded as 3.5 cm, 1.0 cm and 0.5 cm, respectively and that of the right ovary were 4.5 cm, 2.5 cm and 0.8 cm, respectively. The weight of left and right ovaries was 3.0 g and 7.0 g, respectively.

In the case of right unilateral ovarian hypoplasia, the right ovary was elongated and irregularly triangular in shape. Measurements of the left ovary namely length, width and thickness were recorded as 2.0 cm, 1.5 cm and 1.5 cm, respectively and that of the hypoplastic right ovary were 2.0 cm, 1.0 cm and 1.0 cm, respectively. The weight of left and right ovaries was 4.0 g and 2.0 g, respectively. This agrees with the findings of Settergren (1997) and Akkoyunlu *et al*. (2014), who couldn't observe follicles/ CL in the affected ovary. The left ovary was also elongated and irregularly triangular in shape and appeared to be functionally active. (Mohammed and Amin, 2016) reported higher incidence of ovarian hypoplasia in the left ovary followed by right sided and bilateral ovarian hypoplasia. Roberts (1998) opined that ovarian hypoplasia was due to the mutation of single recessive autosomal gene with incomplete penetrance. These forms of infertility will cause reproductive inefficacy with heavy economic loss to the farmers.

Histology

Histologically the ovary of bilateral ovarian hypoplasia was not distinctly demarcated into a cortex and medulla. The ovaries were mostly devoid of ovarian follicles and CL (Fig 3) unlike in control animals. This is in accordance with the findings of Bhattacharya (1982) in goats and Venhoranta *et al*. (2013) in cattle. The large bundles of diffused collagenous connective tissue with numerous blood vessels were observed in ovary. In partial hypoplastic ovaries, the primordial follicles did not develop normally but underwent atresia (Fig 4). Some atretic follicles showed a thickened zona pellucida (Fig 5). The granulosa cells surrounding the oocyte were degenerated. Follicles beyond the primary follicle stage were rarely observed.

Histological examination of the fibrous right ovary of the unilateral ovarian hypoplasia condition revealed that the thick dense irregular connective tissue forming the tunica albuginea was diffused into the cortex unlike that of control animals (Fig 6). In the cortical region, numerous vessels were scattered along with a few ovarian follicles (Fig 7). Contrary to this, Venhoranta *et al*. (2013) did not observe any ovarian follicles or corpora lutea in the hypoplastic ovary in cattle. The inner medulla was composed of irregular loose connective tissue. The fibres were dispersed unevenly in the cortex and medulla as reported by Haque *et al*. (2016) black Bengal goat.

In the animal with right unilateral ovarian hypoplasia, the left ovary was clearly demarcated into cortex and

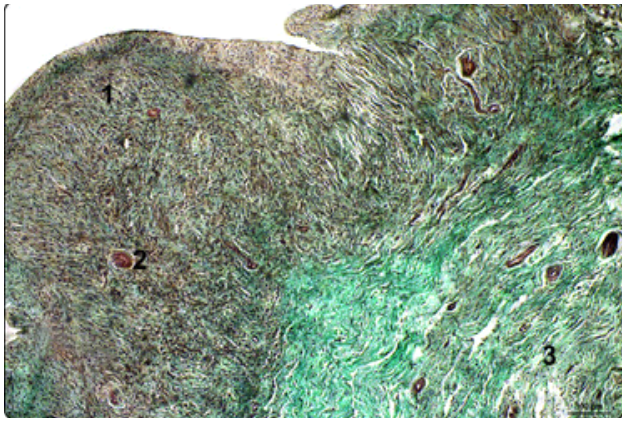

1. Cortex, 2. Atretic follicle, 3. Medulla.

Fig 4: Section of ovary in a cow with partial bilateral ovarian hypoplasia. Masson's trichrome method × 100.

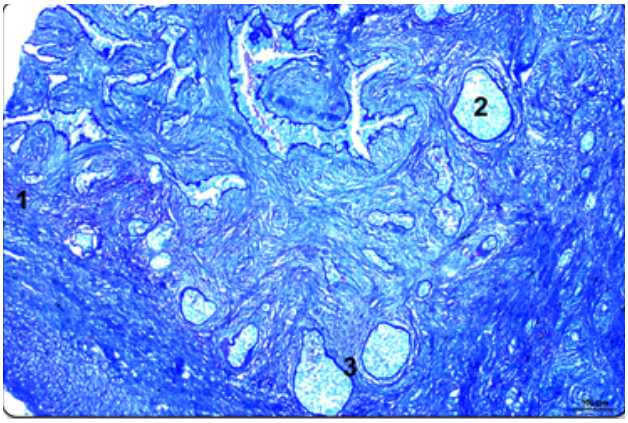

1. Cortex, 2. Atretic follicle, 3. Zona pellucida.

Fig 5: Section of ovary in a cow with partial bilateral ovarian hypoplasia showing atretic follicle. Alcian blue method × 100.

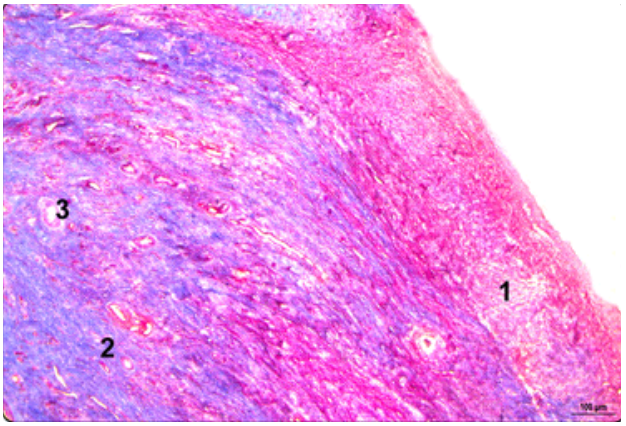

1. Tunica albuginea, 2. Cortex, 3. Primary follicles.

Fig 6: Section of right ovary in a cow with right ovarian hypoplasia. Masson's trichrome method × 100.

medulla, unlike in the case of right one (Fig 8). But, the follicular structures were comparatively less than the normal ovary. The primary follicles were located immediately beneath the germinal epithelium. The wall of the primary follicle was lined by a single layer of granulosa cells. Secondary and tertiary follicles were found in the deeper layers of cortex. The collagen fibres in the medulla were arranged more or less parallel to the surface.

Immunohistochemistry

Immunohistochemically, the hypoplastic ovarian tissue samples showed a strong immunoreaction to IGFBP-2 in the atretic follicles (Fig 9). Monget and Monniaux (1995) stated that intrafollicular concentration of IGFBP2 decreased from primordial to pre-ovulatory follicles. According to Voge *et al*. (2004), IGFBP had negative association with gonadotropin induced follicular growth. Thus, decrease in IGFBP expression led to rise in Insulin Like Growth Factor-1 leading to growth of dominant follicle.

The surface epithelium, endothelial lining of blood vessels and stromal cells also showed a strong positive immunolabelling (Fig 10). The staining intensity and percentage of immunoreactive cells was comparatively higher than that of the control group. The overall percentage of positive immunoreactive cells was more than 50 per cent with strongly positive staining intensity. IGFBP was produced by the primary follicles and was associated with antrum remodeling and the growth of healthy follicles. The positive effect of FSH on expression of aromatase was blocked by the addition of excess IGFBP-2 and also produce negative effect on steroidogenesis. Roberts and Echternkamp (2003) and Rodriguez *et al*. (2011) detected a two-fold increase in IGFBP-2 activity in the atretic follicles than the theca cells in bovine ovaries. Arraztoa *et al*. (2002) concluded that there was a remarkable interspecies difference in the expression patterns of IGFBP-2. In large domestic animals, it was expressed in granulosa cells and tended to decrease with follicular growth.

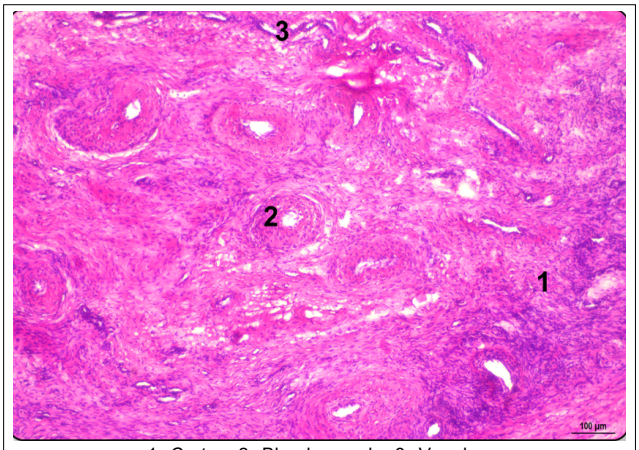

1. Cortex, 2. Blood vessels, 3. Venules.

Fig 7: Section of right ovary in a cow with right ovarian hypoplasia. H&E × 100.

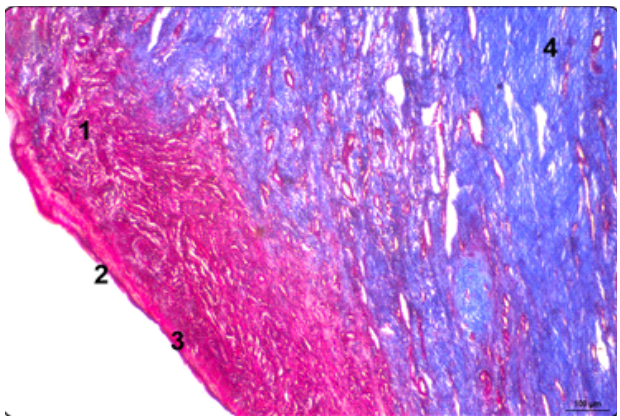

1. Cortex, 2. Germinal epithelium, 3. Tunica albuginea, 4. Medulla- collagen fibres.

Fig 8: Section of left ovary in a cow with right ovarian hypoplasia. Masson's trichrome method × 100.

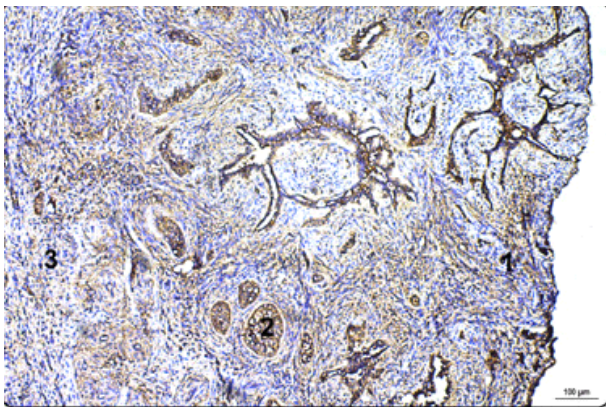

1. Cortex, 2. Atretic follicle, 3. Medulla.

Fig 9: Immunolabelling of IGFBP-2 of ovary in a cow with partial bilateral ovarian hypoplasia showing strong reaction in the atretic follicle. IHC × 100.

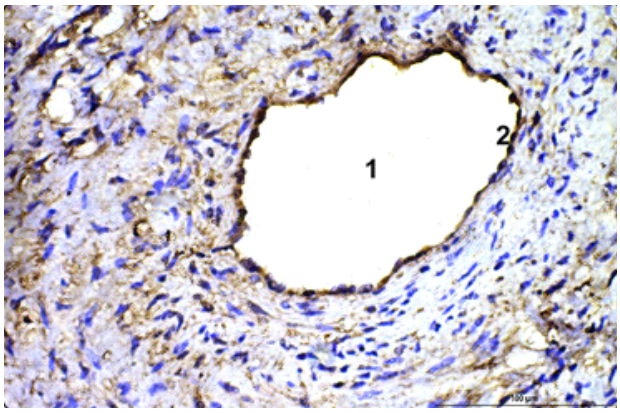

1. Blood vessel, 2. Endothelium.

Fig 10: Immunolabelling of IGFBP-2 of ovary in a cow with partial bilateral ovarian hypoplasia showing strong reaction in the endothelium. IHC × 400.

The values of Immuno-Reactive Score (IRS) 1 and 2 were scattered over a wide range of 1 to 9. Among the normal animals, 83.3 per cent of the ovary had IRS 1 of '3' and 16.7 per cent of the animals had IRS 1 of 4 whereas, in hypoplastic ovary, the animals obtained high score value of 6. The highest score for IRS 2 for the control group was '2', while the affected animals scored a value of 9. Similar reports are not available in domestic animals for comparison.

CONCLUSION

Among the group of 100 animals under study (six control animals and 94 animals with known history of infertility), three animals showed anatomical defects in the ovary. The surface of the ovaries were small, wrinkled, flattened and elongated without any follicles or CL. Bovine ovarian hypoplasia is difficult to diagnose as their small size hinders the transrectal palpation. Histological studies demonstrated that the ovary was not histologically demarcated into a cortex and medulla. Differential staining methods confirmed the presence of irregular bundles of collagen fibres with numerous blood vessels. Immunohistochemically, the hypoplastic ovary showed a strong immunoreaction to IGFBP-2 in the atretic follicles. The staining intensity and percentage of immunoreactive cells were comparatively higher than that of the control group. Their histological derangement affects the functional property of the ovary thereby affecting the gamete production which may considerably influence fertility of the affected animals.

Conflict of interest

All authors declare that they have no conflict of interest.

REFERENCES

Akkoyunlu, G., Tepekoy, F., Bebiş, A. and Uysal, F. (2014). Bilateral total ovarian hypoplasia in a Holstein Friesian heifer. Acta Histochemica. 116: 1519-1521.

Arraztoa, J.A., Monget, P., Bondy, C. and Zhou, J. (2002). Expression patterns of insulin-like growth factor-binding proteins 1, 2, 3, 5 and 6 in the mid-cycle monkey ovary. Journal of Clinical Endocrinology and Metabolism. 87: 5220-5228.

Bhattacharya, M. (1982). Histomorphological and histochemical studies on the hypothalamic-hypophyseal gonadal axis in goat during reproductive cycle. *Ph.D. thesis,* Punjab Agricultural University, Ludhiana. 257p.

Gilmore, L.O. (1949). The inheritance of functional causes of reproductive inefficiency: A review. Journal of Dairy Science. 32: 71-91.

Haque, Z., Haque, A. and Quasem, M. (2016). Morphologic and morphometric analysis of the ovary of black bengal goat (*Capra hircus*). International Journal of Morphology. 34: 13-16.

Kumar, P.R., Singh, S.K., Kharche, S.D., Govindaraju, C.S., Behera, B.K., Shukla, S.N., Kumar, H. and Agarwal, S.K. (2014). Anestrus in cattle and buffalo: Indian perspective. Advances in Animal and Veterinary Sciences. 2: 124-138.

Luna, L.G. (1968). Manual of Histological Staining Methods of the Armed Forces Institute of Pathology. 3rd Ed. Mc Graw Hill Book Company, New York. 258 p.

Mohammed, M.O. and Amin, F.A. (2016). A pathological study of ovarian abnormalities in slaughtered non-pregnant cows in sulaimani province. Journal of Zankoy Sulaimani. 18: 311-321.

Monget, P. and Monniaux, D. (1995). Growth factors and the control of folliculogenesis. Journal of Reproduction and Fertility. 49: 321-334.

Remmele, W., Hildebrand, U., Hienz, H.A., Klein, P.J., Vierbuchen, M., Behnken, L.J., Heicke, B. and Scheidt, E. (1986). Comparative histological, histochemical, immuno histochemical and biochemical studies on oestrogen receptors, lectin receptors and Barr bodies in human breast cancer. Virchows Archiv. 409: 127-147.

Roberts, A.J. and Echternkamp, S.E. (2003). Insulin-like growth factor binding proteins in granulosa and thecal cells from bovine ovarian follicles at different stages of development. Journal of Animal Science. 81: 2826-2839.

Roberts, S.J. (1998). Veterinary Obstetrics and Genital Diseases. 2nd Ed. CBS Publication and Distributors, India. 776p.

Rodriguez, F.M., Salvetti, N.R., Panzani, C.G., Barbeito, C.G., Ortega, H.H. and Rey, F. (2011). Influence of insulin-like growth factor binding proteins-2 and-3 in the pathogenesis of cystic ovarian disease in cattle. Animal Reproduction Science. 128: 1-10.

Settergren, I. (1997). Ovarian hypoplasia in heifers due to germ cell weakness. Theriogenology. 47: 531-539.

Venhoranta, H., Pausch, H., Wysocki, M., Szczerbal, I., Hanninen, R., Taponen, J., Uimari, P., Flisikowski, K., Lohi, H., Fries, R. and Switonski, M. (2013). Ectopic KIT copy number variation underlies impaired migration of primordial germ cells associated with gonadal hypoplasia in cattle (*Bos taurus*). Plos One [online]. 8 (9). Available: https://journals.plos.org/plosone/article?id=10.1371/journal.pone. 0075 659 [12 Nov. 2019].

Villagomez, D.A.F., Parma, P., Radi, O., Di Meo, G., Pinton, A., Iannuzzi, L. and King, W.A. (2009). Classical and molecular cytogenetics of disorders of sex development in domestic animals. Cytogenetic and Genome Research. 126: 110-131.

Voge, J.L., Santiago, C.A.T., Aad, P.Y., Goad, D.W., Malayer, J.R. and Spicer, L.J. (2004). Quantification of insulin-like growth factor binding protein mRNA using real-time PCR in bovine granulosa and theca cells: Effect of estradiol, insulin and gonadotropins. Domestic Animal Endocrinology. 26: 241-258.