RESEARCH ARTICLE Indian Journal of Animal Research, Volume 59 Issue 2: 337-343 (February 2025)

Gross, Histomorphological and Scanning Electronic Microscopic Studies on Gut Associated Lymphoid Tissue of Intestine of Pati Duck (*Anas platyrhynchos domesticus*) of Assam

A. Deka[1], M. Talukdar[1], D.J. Talukdar[1], K. Sarma[1]

10.18805/IJAR.B-4731

ABSTRACT

Background: The study on Gut Associated Lymphoid Tissue (GALT) of Pati duck of Assam is of great value in regard to normal academic and bio-medical research aspects. The aim of the study was to evaluate the gross, histomorphological and scanning electronic microscopic examination of gut-associated lymphoid tissue of the intestine of Pati duck at different age group.

Methods: For this study, forty five Pati ducks were divided into five groups depending on its age *viz.,* 1st week, 4th week, 16th week, 24th week and 42nd weeks old. The pieces of gut having lymphoid tissue or Peyer's patches were collected immediately after slaughter. These samples were fixed in 10% neutral buffered formalin solution and were processed as per the standard technique of procedure (Luna, 1968). The paraffin blocks were sectioned in Shandon Finesse microtome at 5 µm thickness and the sections were stained with Mayer's Haematoxylin and Eosin staining technique for Cellular details, Van Gieson's method for collagen fibres, Gomori's method for reticular fibres, Hart's method for elastic fibres and Bielchowsky's method for axis cylinder and dendrites as per the method of Luna (1968).

Result: Gut-associated lymphoid tissue was found in the duodenum, jejunum, ileum, caecum and the terminal part of the rectum in all the age group of Pati duck. The lymphoid compartment of the gut-associated lymphoid tissue in duck included a follicular structure, dome, follicle associated epithelia and interfollicular area. Lamina propria of jejunum was heavily infiltrated with diffuse lymphatic tissue in the 16th, 24th and 42nd week of age of Pati duck. The scattered and diffuse lymphatic infiltration occurred in all age groups. The lamina propria of the colorectum revealed an extensive network of reticular fibre with diffused lymphatic tissue in all the age group of duck. In Scanning Electron Microscope, the lumen of the jejunum was covered by finger-like villi with numerous opening of goblet cells. The lymphoid follicle of Lamina propria contains numerous lymphocytes along with connective tissue fibres.

Key words: Gut associated lymphoid tissue, Histomorphology, Intestine, Pati duck, Scanning electron microscopy.

INTRODUCTION

The gut-associated lymphoid tissue (GALT) that is associated with the intestinal tract is well developed in poultry which plays an important role in the defence mechanism, by secreting IgA. The complex organization pattern of GALT needs to be explored to have a comprehensive understanding of the local immune system working at the gut mucosal level and the relation between innate and specific immune system. The ileum contains lymphoid tissue in the form of nodules within the mucosa as part of mucosa-associated lymphoid tissue known as Peyer's patches (PPs) which serve as an important site for monitoring inflammatory and immunologic responses of the host against enteric pathogens (Forchielli and Walker, 2005). The associated cellular repertoire of the PPs includes macrophages, dendritic cells, plasma cells and B- and T-lymphocytes (Yamanaka *et al.,* 2001). The number, structure, size and distribution of Payer's patches vary according to species (Liebler *et al*., 1988). This may potentiate the strategies to minimize the immunization cost and disease control protocol in the poultry industry. Thorough knowledge of the morphology and morphometry of GALT is very essential in elucidating its role in disease pathogenesis and gut immunology. The study of the GALT of Pati duck of Assam is of great value regarding normal academic and biomedical research aspects. Pati is the indigenous duck breed of Assam, India (Fig 1) and constitutes about 85.6% of the total duck population in Assam (Islam *et al*., 2002) which are reared for meat, egg and ritual sacrifices, in the backyard production system in rural areas of Assam. Since there is scanty literature on gross, histological and scanning electron microscopic studies of postnatal development of

[1]Department of Anatomy and Histology, College of Veterinary Science, Assam Agricultural University, Khanapara, Guwahati-781 022, Assam, India.

Corresponding Author: A. Deka, Department of Anatomy and Histology, College of Veterinary Science, Assam Agricultural University, Khanapara, Guwahati-781 022, Assam, India.
Email: dranilvet01@gmail.com

How to cite this article: Deka, A., Talukdar, M., Talukdar, D.J., Sarma, K. (2025). Gross, Histomorphological and Scanning Electronic Microscopic Studies on Gut Associated Lymphoid Tissue of Intestine of Pati Duck (*Anas platyrhynchos domesticus*) of Assam. Indian Journal of Animal Research. 59(2): 337-343. doi: 10.18805/IJAR.B-4731.

Submitted: 19-07-2021 **Accepted:** 04-10-2021 **Online:** 09-12-2021

GALT of the intestine of Pati duck at different stages of development, hence the present study was designed to establish various norms on Gut Associated Lymphoid Tissue (GALT) of intestine at different stages of development of Pati duck of Assam.

MATERIALS AND METHODS

In the study, forty-five Pati duck were randomly divided into five groups according to the age *viz.*, 1st week, 4th week, 16th week, 24th week and 42nd week of age. The experiment was duly approved by the Institutional Animal Ethics committee. Ducks were sacrificed according to the method of Gracy (1986). The research was carried out in the Department of Anatomy and Histology, College of Veterinary Science, Assam Agricultural University, Khanapara, Guwahati, Assam for a period of five years.

For gross anatomical studies, the location and relative topographic position of the GALT of the intestine were observed *in-situ* of each age group of birds. Two knots were put, one at the proximal end of the duodenum and the other at the rectum to avoid leakage of ingesta. Thereafter, the intestines were carefully separated from the abdominal cavity. Gradually the mesenteric attachments were removed and the intestines were made straighten. After that, it was opened longitudinally from the duodenum to the rectum. Then, the intestinal content from the mucosal surface was removed by gentle rinsing with cold running water for few minutes. Thereafter, the intestine was fixed in 1 per cent acetic acid for 6 hours and immediately stained in 0.5 per cent methylene blue for 3 to 5 minutes. After that, length, breadth, location and number of Peyer's patches of the small intestine were recorded.

For histological studies, the different parts of the intestinal samples were fixed in 10% neutral buffered formalin solution and were processed as per the standard technique (Luna, 1968). The paraffin blocks were sectioned in Shandon Finesse microtome at 5 µm thickness and the sections were stained with Mayer's Haematoxylin and Eosin staining technique for cellular details, Van Gieson's method for collagen fibres, Gomori's method for reticular fibres, Hart's method for elastic fibres and Bielchowsky's method for axis cylinder and dendrites. Different parameters of histo-morphometry were recorded on Hematoxylin and Eosin stained section using the standard method of micrometry using Nikon E 200 camera mounted microscope.

For scanning electron microscopy (SEM), the tissue samples were processed as per the standard technique of Parsons *et al.* (1991). The samples were fixed in 2.5 per cent glutaraldehyde in 0.1 M phosphate buffer (PBS) (pH 7.2) for 24 h at 4°C and post fixed in two per cent aqueous osmium tetroxide for four hours. Then, dehydrated in series of ascending grades of alcohol and dried to critical point drying with CPD unit. The processed samples were mounted over the stubs with double-sided carbon conductivity tape and a thin layer of gold coat on the samples were done by using an automated sputter-coater (Model- JEOL JFC-1600) for three minutes and scanned under scanning electron Microscope (SEM-Model: JMS-35CF) at required magnifications as per the standard procedures (Bozzola and Russel, 1998) at North Eastern Hill University, Shillong, Meghalaya, India.

The data collected from the study were subjected to statistical analysis using a suitable formula for meaningful and accurate comparison and interpretation as per Snedecor and Cochran (1994).

RESULTS AND DISCUSSION

Gross studies on Peyer's patches of Intestine of Pati duck

Gut-associated lymphoid tissue was found in the duodenum, jejunum, ileum, caecum and the terminal part of the rectum. Thick bands of distinct Peyer's patches were extended around the circumferences of the lumen of jejunum and ileum except at the mesenteric attachment (Fig 1). The four number of Peyer's patches were found in all the age group

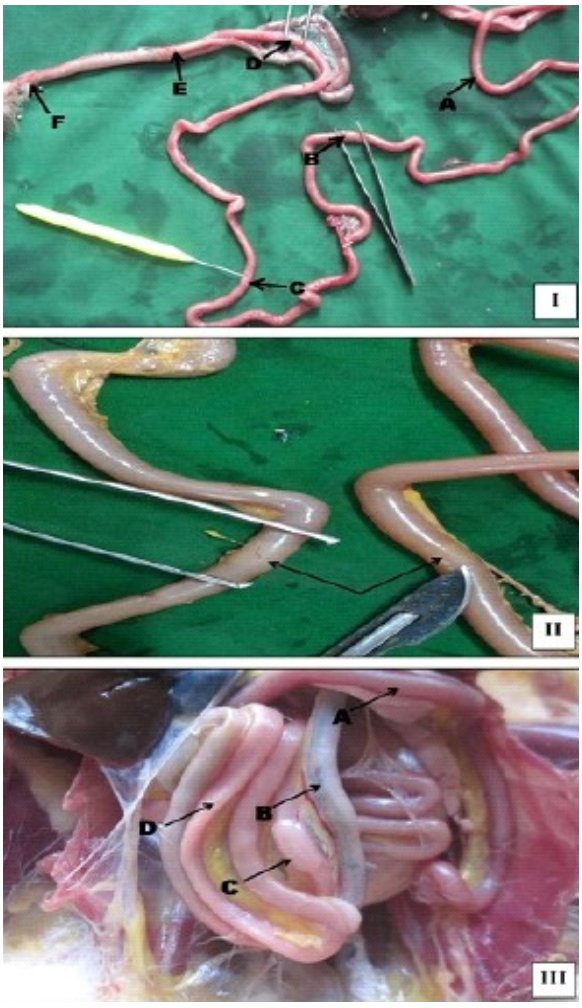

The duodenum (A), caecum (B), ileal Peyer's patches (C) and jejunum (D) of 42nd week old Pati duck.

Fig 1: Thick bands of distinct Peyer's patches of the different age group of Pati duck.

of Pati duck. The ileocaecal junction showed the aggregation of lymphatic nodules. The average value of length, breadth of Jejunal Peyer's patches and ileal Peyer's patches are depicted in Fig 2. The study showed that the average value of length and breadth of Jejunal Peyer's patches and ileal Peyer's patches were significantly (P<0.05) increased from the 1st week to the 42nd week. The length of Jejunal Peyer's patches was ranged from 4.24±0.42 to 8.67±0.99 mm and breadth from 2.67±0.15 to 5.36±0.21 mm from 1st week to 42nd week. Similarly, the length of ileal Peyer's patches was ranged from 4.02± 0.15 to 10.74±0.01 mm and breadth from 2.07±0.14 to 7.24±0.03 mm from 1st week to 42nd week age of pati duck.

Gut-associated lymphoid tissue was found in the duodenum, jejunum, ileum, caecum and the terminal part of the rectum which were in consonances with the findings of Gedam *et al.* (2016) in Khaki Campbell duck. The significantly (P<0.05) increased of length and breadth

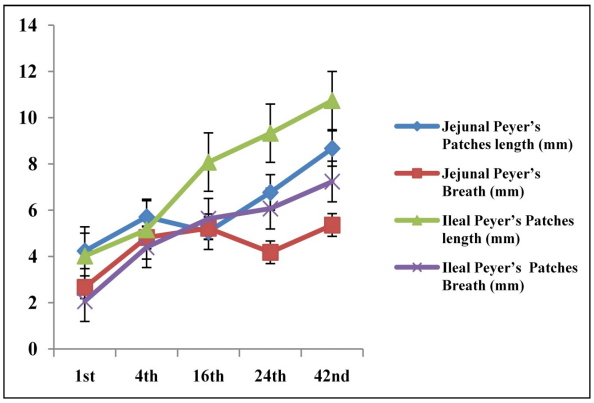

Fig 2: Length and breadth of Peyer's patches of jejunum and ileum of pati duck at different age group

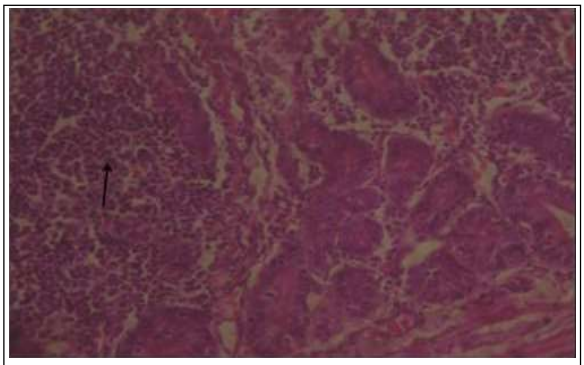

H & E, X40.

Fig 3: The diffuse lymphatic tissue (black arrow) in lamina propria of duodenum of 16th week old pati duck.

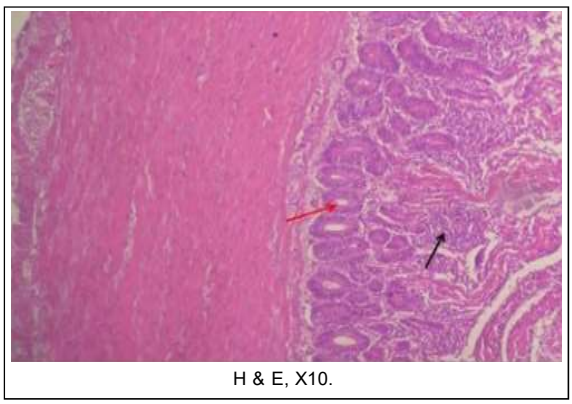

H & E, X10.

Fig 4: The lymphatic nodule (black arrow) and crypts of lieberkuhn (red arrow) of doude-num of 42th week old pati duck.

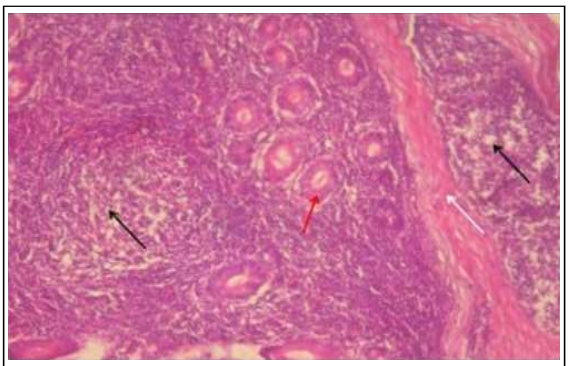

H & E, X10.

Fig 5: The lymphatic nodule (black arrow), crypts of lieberkuhn (red arrow) and tunica muscu-laris (white arrow) of jejunum on 16th week old pati duck.

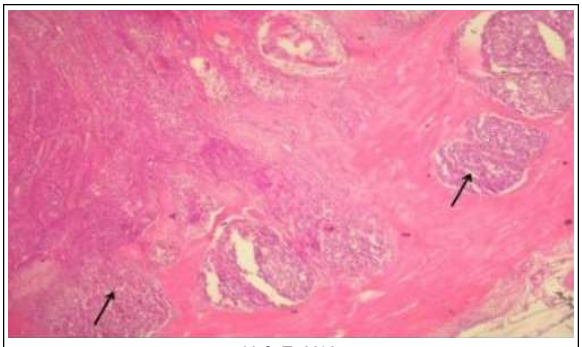

H & E, X10.

Fig 6: The lymphatic nodule (black arrow) of jejunum on 4th week old pati duck.

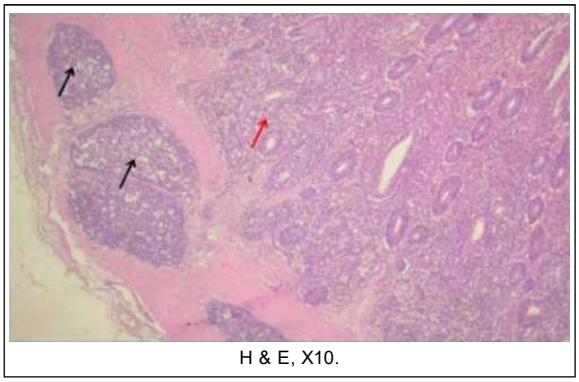

H & E, X10.

Fig 7: The showing the lymphatic nodule (black arrow) of tunica muscularis and lamina propria (red arrow) of jejunum on 24th week old pati duck.

of Jejunal Peyer's patches and ileal Peyer's patches from the 1st week to the 42nd week of pati duck. Similar findings were reported by McGarry and Bourns (1980) in the adult mallard duck.

Histo-morphological studies on Peyer's patches of Intestine of Pati duck

Histologically, Peyer's patches and solitary lymphoid nodules were distributed in the duodenum,jejunum, ileum,caecum and colo-rectum of the intestine in all the age group of Pati ducks. The lymphoid compartment of the gut-associated lymphoid tissue in the duck included a follicular structure, dome, follicle associated epithelia and inter-follicular area (Fig 3). Some lymphatic nodules were also observed in the duodenum of the 24th week and 42nd week old Pati duck (Fig 4). The follicles were present in the non-villus area. The intraepithelial lymphocytes were found in the epithelium. The identity of lymphocytes was observed as individual cells or as small clusters. Lamina propria of jejunum was heavily infiltrated with diffuse lymphatic tissue in 16th week, 24th week and 42nd week of age of Pati duck (Fig 5). The scattered and diffuse lymphatic infiltration occurred in all age groups of the duck.

Lymphoid follicles of jejunal Peyer's patches remained cluster within the tunica muscularis layer and separated from each other by a narrow interfollicular area (Fig 6, 7). The lymphoid follicle contained abundant nerve fibres. The interfollicular area contained collagen, few elastic and nerve fibres (Fig 8).

The lymphocytes were highly concentrated in lamina propria and were loosely scattered in the epithelium (Fig 9). The ileum contained a cluster of lymphoid follicles within the tunica muscularis layer and separated from each other by a narrow interfollicular area (Fig 10). The interfollicular area contained collagen, little elastic, reticular and nerve fibres (Fig 11). The ileocaecal junction showed the aggregation of lymphoid follicles in all the age groups (Fig 12). The solitary lymphatic nodules were observed in lamina propria and tunica submucosa of the caecum (Fig 13). The aggregated lymphatic nodules in the caecum were covered by a few elastic, collagen and reticular fibres (Fig 14). The inter nodular connective tissue consisted of collagen, few elastic, reticular and nerve fibres (Fig 15). There was less infiltration of lymphatic tissue in the colorectum as compared to the other part of the intestine. The Intraepithelial lymphocytes were not recorded. The solitary lymphatic nodules were observed in the lamina propria as well as tunica muscularis of the rectum but there was no aggregation of nodules (Fig 16, 17). The mean diameter of lymphocytes of the duodenum, jejunum,

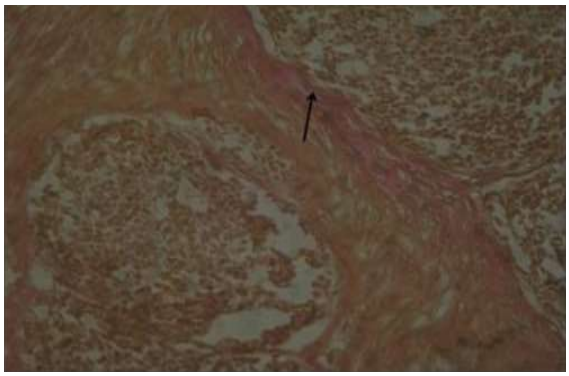

Van Gieson' X40.

Fig 8: The collagen fiber of ileum of 16th week old pati duck.

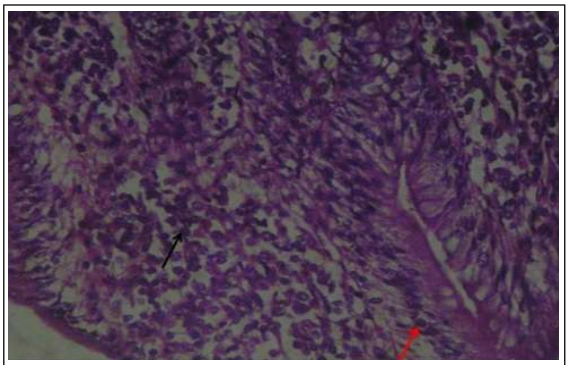

H & E, X40.

Fig 9: The lymphatic of lamina propria and epithelium of ileum of 24th week old pati duck.

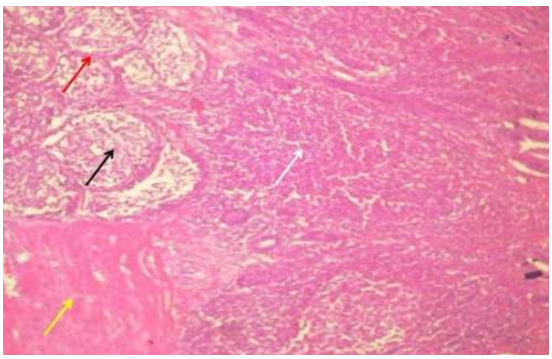

H & E, X40.

Fig 10: The lymphatic of nodule (black arrow), inter- follicular area (red arrow), tunica muscularis (yellow arrow) and lymphatic nodule (white arrow) of ileum of 24th week old Pati duck.

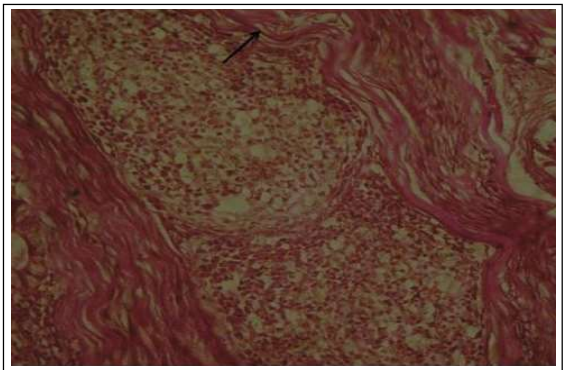

Hart's method, X40.

Fig 11: The elastic fibers of ileum of 24th week old Pati duck.

ileum, caecum and colorectum was significantly (P<0.01) higher from 1st week to 42nd week of age. The mean diameter of lymphocytes of the duodenum, jejunum, ileum, caecum and colorectum was ranged from 3.41±0.07 µm to 5.12±0.17µm, 3.11±0.16 to 5.13±0.14, 3.03±0.23 to 5.07±0.14, 3.43±0.10 to 5.22±0.20 and 3.26±0.10 to 5.08±0.16 respectively from 1st week to 42nd week. The mean diameter of a lymphatic nodule of the duodenum, jejunum, ileum, caecum and colorectum was significantly (P<0.01) higher from 1st week to 42nd week of age. The mean diameter of a lymphatic nodule of the jejunum, ileum, caecum and colorectum was ranged from 64.96±0.59 µm to 191.81±0.85 µm, 64.59±0.72 to 189.10±0.80, 65.30±0.73 to 192.17±1.03 and 63.83±1.11 to 188.20±0.84 respectively from 1st week to 42nd week.

Histologically, Peyer's patches and solitary lymphoid nodules were distributed in the important strategic areas of the intestine in all the age group of Pati ducks.

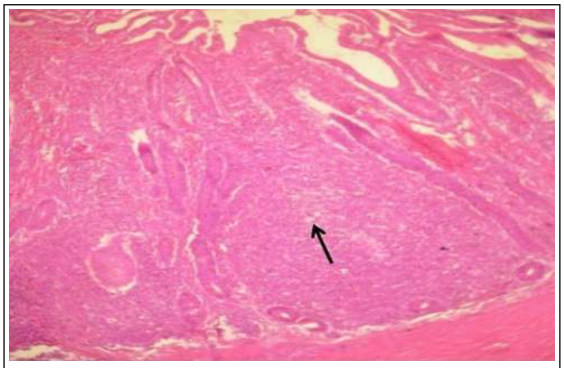

H & E, X10.

Fig 12: The lymphatic nodule (black arrow) of caecum of 24th week old Pati duck.

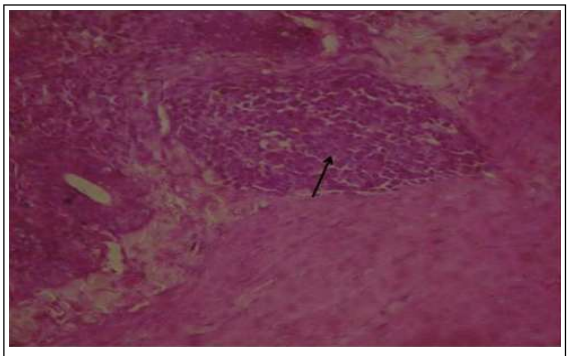

H & E, X40.

Fig 13: The lymphatic nodule (black arrow) of caecum of 4th week old Pati duck.

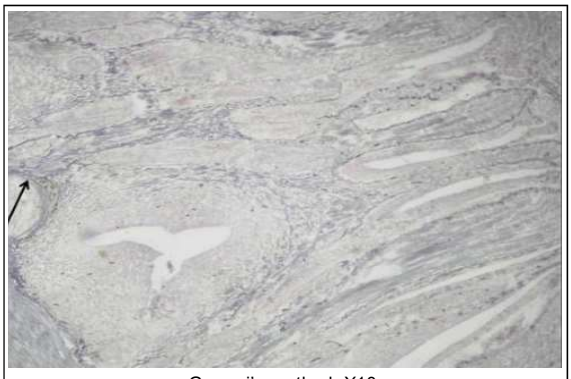

Gomori's method, X10.

Fig 14: The reicular fibers of caecum of 4th week old Pati duck.



Gomori's method, X10.

Fig 15: The nerve fibers of caecum of 4th week old Pati duck.

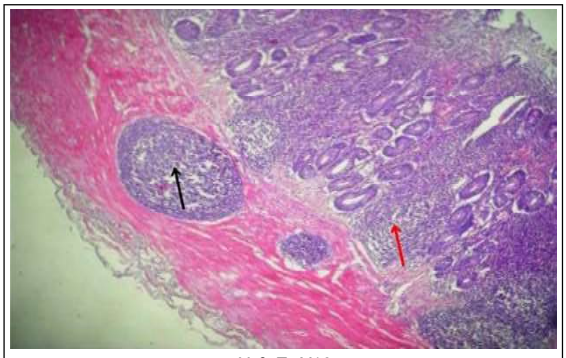

H & E, X10.

Fig 16: The lymphatic nodule (black and red arrow) of rectum of 24th week old Pati duck.

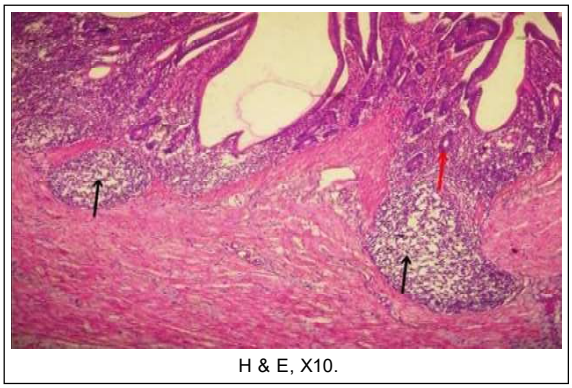

H & E, X10.

Fig 17: The lymphatic nodule (black arrow) and crypts of lieberkuhn (red arrow) of rectum of Pati duck.



A. The intestinal gland (black arrow), lymphoid follicle (red arrow) and connective tissue fibers (white arrow) of ileum Bar=20 µm, 1.25KX.
B. The intestinal gland (black arrow), lymphoid follicle (red arrow) and connective tissue fibers (white arrow) of ileum Bar=20 µm, 1.25KX.
C. The intestinal gland (black arrow) and lymphocytes (red arrow) of ileum Bar=20 µm,1.15KX.

Fig 18: Scanning electron microphotograph.

The lymphoid compartment of the gut-associated lymphoid tissue in the duck included a follicular structure, dome, follicle associated epithelia and inter-follicular area. These findings were corroborated with the findings of Gedam *et al.* (2016) in Khaki Campbell duck. The lamina propria of the duodenum was made up of loose connective tissue and was infiltrated with diffuse lymphatic tissue. These finding was total agreement with the findings of Hodges (1974) in fowl and Khaleel and Atiea (2017) in Indigenous duck of Iraq. The identity of lymphocytes was observed as individual cells or as small clusters. These findings were in accordance with the findings of Gedam (2017) in Kadaknath fowl and Rahman *et al*. (2003) in deshi chicken. The scattered and diffuse lymphatic infiltration occurred in all age groups of Pati duck. Similar finding were also observed in desi chicken (Rahman *et al*. 2003), domestic birds (Aughey and Frye, 2001) and Khaki Campbell duck (Gedam *et al*. 2016). Lymphoid follicles of jejunal Peyer's patches remained cluster within the tunica muscularis layer and separated from each other by a narrow interfollicular area in a mallard duck (McGarry and Bourns, 1980) which was also observed in Pati duck. The ileum contained a cluster of lymphoid follicles within the tunica muscularis layer and separated from each other by a narrow interfollicular area. Similar findings were observed in duck (Barman *et al.,* 1998) and domestic birds (Aughey and Frye, 2001).The solitary lymphatic nodules were observed in lamina propria and tunica submucosa of caecum which was also found in broiler chicken (Akter *et al*., 2006). The mean diameter of lymphocytes of the duodenum, jejunum, ileum, caecum and colorectum was significantly ($P<0.01$) higher from 1st week to 42nd week of age. Contrary to the present findings, Gedam (2017) opined that the average diameter of lymphocytes of the duodenum, jejunum, ileum, caecum and colorectum was significantly ($P<0.01$) reduced from 6th week to 18th week of Kadaknath fowl. This might be due to species variation and the different age of the birds.

Scanning electronic microscopic studies on Peryer's patches of intestine of pati duck

In Scanning Electron Microscope, the lumen of the jejunum was covered by finger-like villi. These villi contained numerous opening of goblet cells (Fig 18 A). Lamina propria of the jejunum contained intestinal gland along with lymphoid follicle (Fig 18 B) and that of ileum contained lymphoid follicle (Fig 18 C). This lymphoid follicle contained numerous lymphocytes along with connective tissue fibres. The lymphoid follicle of tunica muscularis was surrounded by a thin capsule (Fig 18 D), which contained numerous lymphocytes along with connective tissue fibres where lymphocytes were attached (Fig 18 E) as seen in domestic fowl and Turkey (Burns and Maxwell, 1986) by SEM. High endothelial venules were found among the lymphocytes and intestinal gland (Fig 18 F).

Conclusion

Thorough knowledge of the morphology and morphometry of GALT is very essential in elucidating its role in disease pathogenesis and gut immunology. Poultry Peyer's patches are often difficult to observe grossly, So, with the help of light microscope and scanning electron microscope, it is easy to understand the anatomical structure of Peyer's patches of Pati duck. This study will help to utilize the Pati duck for a breeding programme as well as help physiologist, pathologist and poultry scientists for effective disease control regime.

Acknowledgement

The authors are grateful to the Dean, College of Veterinary Science, Assam Agricultural University, Khanapara, Assam, India for providing the required facilities to conduct this experiment.

Conflict of interest

All authors decalre that they have no conflict of interest.

References

Akter, S.H., Khan, M.Z.I., Jahan, M.R., Karim, M.R. and Islam, M.R. (2006). Histomorphological study of the lymphoid tissues of broiler chickens. Bangladesh Journal of Veterinary Medicine. 4(2): 87-92.

Aughey, E. and Frye, F.L. (2001). Comparative Veterinary Histology with Clinical Correlates. Manson Publishing Ltd., London NW 117DL, UK.134.

Barman, N.N., Goswami, S., Mukit, A. and Islam, S. (1998). Gut associated lymphoid tissues of duck: Distribution and histology. Indian Journal of Animal Sciences. 68(1): 14-16.

Bozzola, J. and Russell, L. (1998). In: Electron Microscopy: Principles and Techniques for Biologists. First Edition. Jones and Bartlett, Boston. pp. 670.

Burns, R.B. and Maxwell, M.H. (1986). Ultrastructure of Peyer's patches in the domestic fowl and Turkey. Journal of Anatomy. 147: 235-243.

Forchielli , M.L. and Walker, W.A. (2005). The role of gut-associated lymphoid tissues and mucosal defence. British Journal of Nutrition. 93(1): S41-8.

Gedam, D.P., Salankar D.A., Nandeshwar, D.N., Mainde, D.U.P., Rama, D.T., Panda, D.R., Ravikanth, D.V. and Bansode, D.S. (2017). Micrometrical studies of lymphocytes and lymphatic nodules of the intestine in the Kadaknath breed of poultry (*Gallus gallusdomesticus*). International Journal of Environmental Science and Technology. 6(3): 2137-2141.

Gedam, P.M., Nandeshwar, N.C., Salankar, A.M., Kawareti, P.K., Dalvi, R.S. and Mainde U.P. (2016). Histomorphological studies on gut associated lymphoid tissue of Khaki Campbell breed of duck (*Anas platyrhynchos*). International Journal of Environmental Science and Technology. 5(4): 2415-2419.

Gracy, J.F. (1986). Bleeding Method of Slaughtering-Slaughter. Meat Hygiene. 8th edn. 144-145.

Hodges, R.D. (1974). The Histology of Fowl. Academic Press Inc. (London) Ltd. 80-213.

Islam, R., Mahanta, J.D., Barua, N. and Zaman, G. (2002). Duck farming in North-Eastern India (Assam). World's Poultry Journal. 58: 567-572.

Khaleel, I.M. and Atiea, G.D. (2017). Morphological and histochemical study of small intestine in Indigenous ducks (*Anas platyrhynchos*). Journal of Agriculture and Veterinary Science. 10(7): 19-27.

Liebler, E.M., Pohlenz, F. and Cheville, N. (1988). Gut-associated lymphoid tissue in the large intestine of calves. Veterinary Pathology. 25: 509-515.

Luna, L.G. (1968). Manuals of Histological Staining Methods of Armed Forces Institute of Pathology, Mc Graw Hill Book Co., London. 3rd Edn. pp. 79-207.

McGarry, R.C. and Bourns, T.K.R. (1980). Annular bands of lymphoid tissue in the intestine of the mallard duck (*Anas platyrhynchos*). Journal of Morphology. 163(1): 1-8.

Parsons, K.R. Bland, A.P. and Hall, G.A. (1991). Follicle associated epithelium of the gut-associated lymphoid tissue of cattle. Veterinary Pathology. 28(1): 22-29.

Rahman, M.L., Islam, M.R., Masuduzzaman, M. and Khan, M.Z.I. (2003). Lymphoid tissues in the digestive tract of deshi chicken (*Gallus domesticus*) in Bangladesh. Pakistan Journal of Biological Science. 6(13): 1145-1150.

Snedecor, G.W. and Cochran, W.G. (1994). In: Statistical Methods. 8th edn. Oxford and IBH. Pub. Cp. New Delhi.

Yamanaka, T.A., Straumfors, H., Morton, O., Fausa, P., Brandtzaeg, I. and Farstad, M. (2001). Cell pockets of human Peyer's patches are specialized extensions of germinal centers. European Journal of Immunology. 31: 107-117.