RESEARCH ARTICLE Indian Journal of Animal Research, Volume 59 Issue 2: 267-273 (February 2025)

Bronchoscopic Evaluation of Eosinophilic Bronchopneumopathy in Dogs

Amrinder Singh Kansla[1], S. Kavitha[1], M. Sandhya Bhavani[2], D. Chandrasekaran[3], S. Vairamuthu[4], N. Pazanivel[5]

10.18805/IJAR.B-4736

ABSTRACT

Background: Eosinophilic bronchopneumopathy (EPB) is an emerging canine lower respiratory disease characterized by eosinophilic infiltration of lungs and bronchial mucosa that has traditionally been refer to as pulmonary infiltrates with eosinophilia (PIE). Since the diagnosis of this disease is of great challenge to the veterinarians and currently very limited work have been carried out and recorded in veterinary literature the present study was planned and conducted to document clinical and bronchoscopic changes in dogs with Eosinophilic bronchopneumopathy and to assess bronchoalveolar lavage fluid analysis in the diagnosis of Eosinophilic bronchopneumopathy in dogs

Methods: Present study consisted of eight apparently healthy dogs and eight clinical cases. The parameters included in this study were clinical examination, BALF microbiological culture, BALF antibiogram, bronchoscopy and BALF cytology.

Result: Eosinophilic bronchopneumopathy (EBP) was recorded in eight dogs. In BALF cytology based on eosinophilic scoring, mild to moderate form of eosinophilic infiltration was observed in six dogs. Severe eosinophilia was observed in two cases. No micro-organisms were observed on cytology of EBP dogs. The most predominant bronchoscopic findings were the presence of muco-purulent secretions and mild to moderate thickening of bronchial mucosa in EBP dogs. BALF analysis is found to be the gold standard test in the confirmation of EBP in dogs. Bacterial and fungal culture was performed on all 24 BALF samples collected. The most frequently isolated bacterial species were *Staphylococcus* sp. (66 per cent) followed by *Streptococcus* sp. (25 per cent) one *E. coli* (4 per cent) and one sample showing growth of *Klebseilla* sp. (4 per cent). In the study, the antibiogram pattern of BALF showed high sensitivity for Enrofloxacin.

Key words: Broncho alveolar lavage fluid, Eosinophilic broncho pneumopathy.

INTRODUCTION

Eosinophilic broncho pneumopathy (EPB) is an emerging canine lower respiratory disease characterized by eosinophilic infiltration of lungs and bronchial mucosa that has traditionally been refer to as pulmonary infiltrates with eosinophilia (PIE). PIE is described in humans and dogs and includes a range of different diseases that vary in presentation from mild to severe, transient to chronic and self-limiting, sometimes fatal. The diseases are all considered to be manifestations of immunologic hypersensitivity (Clercx and Peeters, 2007).

According to several authors (Hawkins *et al.,* 1995, Brownlie, 1990 and Clercx and Peeters, 2007), the predominant sign of EBP is persistent and chronic cough for more than two months, productive or on productive and shows positive response when given the corticosteroid therapy. Clercx and Peeters (2007) suggested that airway sampling is considered utmost necessary for the confirmation or diagnosis of EBP through cytologic assessment and exclusion of infection. This can be done by collecting the sample from tracheal wash or bronchoscopy. The bronchoscopy so far is considered important by many researchers as one of the best and advanced techniques in the diagnosis and treatment of respiratory disorders of canines.

[1]Department of Veterinary Clinical Medicine, Madras Veterinary College, Chennai-600 007, Tamil Nadu, India.
[2]Department of Clinics, Madras Veterinary College, Tamil Nadu Veterinary and Animal Sciences University, Chennai-600 007, Tamil Nadu, India.
[3]Veterinary College and Research Institute, Tamil Nadu Veterinary and Animal Sciences University, Udumalpet-642 205, Tamil Nadu, India.
[4]Department of Centarlised Clinical Laboratory, Madras Veterinary College, Tamil Nadu Veterinary and Animal Sciences University, Chennai-600 007, Tamil Nadu, India.
[5]Department of Veterinary Pathology, Madras Veterinary College, Tamil Nadu Veterinary and Animal Sciences University, Chennai-600 007, Tamil Nadu, India.

Corresponding Author: Amrinder Singh Kansla, Department of Veterinary Clinical Medicine, Madras Veterinary College, Chennai-600 007, Tamil Nadu, India. Email: honeysinghny0088@gmail.com

How to cite this article: Kansla, A.S., Kavitha, S., Bhavani, M.S., Chandrasekaran, D., Vairamuthu, S. and Pazanivel, N. (2025). Bronchoscopic Evaluation of Eosinophilic Bronchopneumopathy in Dogs. Indian Journal of Animal Research. 59(2): 267-273. doi: 10.18805/IJAR.B-4736.

Submitted: 24-07-2021 **Accepted:** 25-03-2022 **Online:** 31-05-2022

Chronic cough associated with infections of the lower respiratory tract is a most common sign in canine practice.

The cause of infection may be due to primary or secondary pathogenic bacteria (Vieson *et al.,* 2012). The opportunistic secondary infections are induced by a range of factors, such as viral or parasitic infection, inflammation, environment and surroundings of the animal, season trauma, aspiration, neoplasia, anomalies, systemic immunodeficiency or any other cause of impaired local defence mechanisms.

Identification and therapy of the specific cause is necessary in the management of chronic cough. Bronchoscopy is a minimally invasive technique utilised in veterinary medicine to sample the lower generation bronchi and alveolar spaces. BALF is helpful in isolation of causative bacteria. The aim of this study was to identify bacterial species involved in the canine lower respiratory tract as determined by findings in BAL fluid and the susceptibility patterns of isolated bacteria.

Since the diagnosis of this disease is of great challenge to the veterinarians and currently very limited work have been carried out and recorded in veterinary literature, the present study was planned and conducted to document clinical and bronchoscopic changes in dogs with Eosinophilic broncho pneumopathy and to assess bronchoalveolar lavage fluid analysis in the diagnosis of Eosinophilic broncho pneumopathy in dogs.

MATERIALS AND METHODS

Twenty-four dogs brought to Madras Veterinary College Teaching Hospital, Chennai, during the year 2018-2019 with a history of chronic cough were selected. Dogs were included in the study group if they displayed one or more of the following clinical signs: nasal discharge, coughing, dyspnoea or abnormal findings on auscultation of the lungs. The dogs under study were subjected to detailed clinical examination, physical examination and bronchoscopic study. The bronchoscopic scores (presence of material and mucosal changes) were depicted in the Table 3.

For bronchoscopic examination of the respiratory tract and sampling, a bronchovideoscope (OLYMPUS BF TYPE 1T150) was used under general anaesthesia. The dogs were premedicated with atropine at 0.04 mg/kg body weight and xylazine hydrochloride at 1 mg/kg body weight IM. Anaesthesia was induced and maintained using ketamine at 10 mg/kg weight IV and diazepam at 0.5 mg/kg weight IV according to the produced anaesthetic effect. 2 ml/kg sterile isotonic saline solution (0.9 per cent sodium chloride) was delivered to the selected lung lobe to a point at which it becomes wedged in the narrow lumen through the working channel followed by immediate gentle suction for sampling. Recovered BAL fluid was collected in a sterile tube and immediately processed for microbiological examination (Fig 1). The collected BALF was subjected to cytospin at 3000 rpm for 7 mins and smears were prepared from pelletal cells and stained with Leishman-Giemsa stain.

The BALF samples collected were cultured for bacterial and fungal isolation and identification so as to know the prevalence of microorganisms causing chronic cough and its epidemiology in dogs. For bacterial isolation and identification, the samples were cultivated on blood agar. Cultures were incubated aerobically were incubated at 37°C under aerobic conditions and examined after 24 and 48 hours. Bacterial colonies were then identified based on colony morphologic characters, Gram's stain and various biochemical tests (Quinn *et al.,*1994). For further confirmation of the isolated colonies, the colonies were also inoculated in specific or selective media like Edward's medium, Mannitol salt agar, Eosin methylene blue agar *etc*. (Table 1).

For the fungal culture, the swabs were inoculated to Sabouraud's Dextrose agar and the Dermatophyte test medium. The plates were incubated at 25° and 37°C for 4 weeks. The fungal growth was identified based on colonial appearance and microscopic appearance by Gram's stain and Lactophenol staining of Tape impression smears as per (Smith *et al.,* 1998). *In vitro* antibiotics used in this study was mentioned in Table 2.

Table 1: Bacterial isolates from culture of BALF.

Bacterial isolates	No of dogs
Staphylococcus sp.	16
Streptococcus sp.	6
E. coli	1
Klebsiella	1

Table 2: Antibiotic susceptibility pattern of bacterial isolates from culture of BALF.

Antibiotics	Sensitive (No. of animals)	Intermediate (No. of animals)	Resistant (No. of animals)
Amoxycillin	2	21	1
Azithromycin	8	16	0
Cephotaxime	1	22	1
Enrofloxacin	21	0	3
Amikacin	19	5	0
Tetracycline	4	9	11

Table 3: Bronchoscopic scoring of EBP dogs.

Presence of material	Score	Per cent (No. of animals)
No material	0	-
Presence of mucus or mucopurulent material	1	100 (8/8)
Presence of abundant yellow green mucopurulent material	2	-
Mucosal changes		
No changes in mucosa	0	-
Congestion and hyperemia	1	100(8/8)
Mild thickening of mucosa	2	37.5 (3/8)
Severe thickening and irregular aspect	3	62.55/8)
Polypoid aspect	4	-

Results and Discussion

Out of 31,233 dogs presented to Madras Veterinary College Teaching Hospital during the study period of two semesters, forty-seven dogs were presented with the history of chronic cough along with respiratory distress. Based on clinical examination and other diagnostic techniques, 17 out of 47 cases were found not fit for bronchoscopy and in 6 cases there was no consent given by the owner. and excluded from the study because of other disease conditions. In the remaining 24 cases, endoscopy was performed. Based on bronchoalveolar lavage fluid cytology eosinophilic broncho pneumopathy was evident in eight among 24 cases (33%) with chronic bronchitis (Fig 1).

In the present study, Eosinophilic broncho pneumopathy (EBP) was diagnosed in eight out of 24 cases presented with cough associated with chronic bronchitis. In the remaining 16 cases, neutrophilic infiltration was predominant which could be associated with bacterial infection (Fig 1). Similar diagnosis of EBP in 23 and 25 dogs were reported by Clercx *et al.* (2000) and Rajamäki *et al.* (2002) in their study.

The low incidence of EBP recorded in this study may not represent actual disease prevalence. The reasons behind may be unlike bacterial pneumonia, EBP is not often associated with lethargy, anorexia and fever which are commonly recognised by the pet owners for presentation to the hospital as well as poor owner consent for bronchoscopy procedure.

Seventeen cases which had chronic cough were excluded from the present study based on theunderlying etiology and this concurred with Rozanki (2014) who opined that chronic cough in dogs may be caused by infectious diseases, lung hookworm, pleural effusion, interstitial lung disease and congestive heart failure.

Bronchoscopic findings of normal healthy dogs (group I) revealed prominent tracheal rings, pinkish mucosa (Fig 2 and 3) showing no growth (nodules or polypoid), absence of mucus secretions and smooth lining of bronchial mucosa (Fig 4). The above findings concurred with Nagarajan (1995) and Hawkins *et al.,* (1995).

The predominant changes observed in all EBP dogs were, presence of mucus to mucopurulent material (Score 1) (Table 3) and presence of congestion and hyperemia (Score1). Mild to moderate thickening of bronchial mucosa was a common finding of EBP dogs (Table 3, Fig 4 to 12).

Similarly, Clercx *et al.* (2000) recorded presence of abundant green-yellow mucus and muco-purulent material, severe thickening with irregularity of mucosa to polypoid growth in bronchioles. Other changes reported were exaggerated airway closure during expiration. Rajamäki *et al.* (2002) also recorded presence of severe hyperemia and nodular changes in dogs with EBP. However, no polypoid growth was seen in EBP dogs though severe eosinophilic infiltration was recorded in two dogs.

The bronchoscopic findings in EBP dogs were given different scores as in Table 4. In all the cases with EBP, score 1 suggestive of presence of mucus or mucopurulent material was noticed (Fig 5, 6 and 7). In addition, congestion and hyperaemia of score one was noticed in all the cases with EBP (Fig 8 and 9). Mild thickening of mucosa (Fig 10)

Table 4: Eosinophilic Scoring of BALF Cytology of EBP Dogs.

Percent of eosinophils by counting the cells (n=100)	Score	Per cent (No. of animals)
No eosinophils	0	-
1-20% eosinophils	1	37.5(3/8)
20-50% eosinophils	2	37.5(3/8)
more than 50% eosinophils	3	25 (2/8)



Fig 1: BALF samples.



Fig 2: ABST of BALF showing susceptibility pattern.

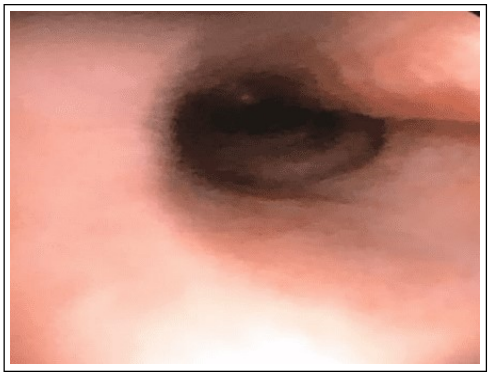

Fig 3: Normal tracheal mucosa.

marked as Score two was observed in three out of eight cases and severe thickening with score 3 was observed in five out of eight cases (62.5 per cent) (Fig 11 and 12). No polypoid growth was observed in our study. The median score calculated for bronchoscopic findings was three.

BALF cytology of normal healthy dogs showed predominantly macrophagic infiltration and epithelial cells (Fig 13 and 14). BALF cytology of EBP dog showed Score one with 1-20 per cent eosinophilic cells in 3/8 cases (Fig 15). Score two, suggestive of 20-50 per cent eosinophils were observed in 3/8 cases (Fig 16) and Score three with severe infiltration of eosinophils was observed in 2/8 cases (Fig 17). Other cells observed were few respiratory cells. No bacterial cells were observed in the cytology of all EBP dogs. In this study, in remaining 16 cases, no eosinophilic infiltration was observed, instead severe neutrophilic infiltration was recorded.

The BALF cytology of normal control dogs in this study showed predominantly macrophages and respiratory epithelial cells. This was in accordance with Hawkins *et al.* (1990). In the present study, out of 24 dogs BALF cytology showed positive for eosinophilic infiltration in eight cases. Based on eosinophilic scoring, mild to moderate form of eosinophilic infiltration was observed in six dogs (Fig 15 and 16). Severe eosinophilia was observed in two cases (Fig 17). No micro-organisms were observed on cytology of EBP dogs. Other cells identified were few epithelial cells and macrophages. The above findings were in accordance with Rajamäki *et al.* (2002) and Clercx *et al*. (2007).

Suspected and known cause of the pulmonary hypersensitivity in humans and animals include fungi, moulds, dust, bacteria and parasites. Further the inciting cause of eosinophilic cases remains unknown in most cases and EBP is considered an idiopathic disease. Clercx and Peeters (2007) also recorded house dust, human dander, *Dirofilarial* spp., mixed feathers, moulds, pollen of grasses, trees and weeds and mixed insects as suspected allergens that cause hypersensitivity in EBP dogs. The confirmation EBP in dogs is mainly based on demonstration of eosinophilic infiltration in BALF cytology and cannot be diagnosed with routine diagnostic work up hence the disease is less reported in practice.

BALF cytology of remaining 16 cases in this study showed severe neutrophilic infiltration with bacteria suggestive of bacterial cause of bronchitis. This was in agreement with Johnson *et al.* (2013) who demonstrated that BALF cytology showing > 8 per cent neutrophils were classified as suppurative and if neutrophil contains intracellular bacteria, the samples are categorized as septic. Bacterial and fungal culture was performed on all 24 BALF samples collected. Bacteria isolated from culture-positive samples included *Staphylococcus* sp., *Streptococcus* sp., *Escherichia coli* and *Klebsiella pneumonia.* The most frequently isolated bacterial species were *Staphylococcus* sp. (16/24, 66 per cent) followed by *Streptococcus* sp. (6/24, 25 per cent) one *E. coli* (1/24, 4 per cent) and one sample of each *Klebseilla* sp. (1/24, 4 per cent) (Table 1).



Fig 4: Normal bronchial mucosa.

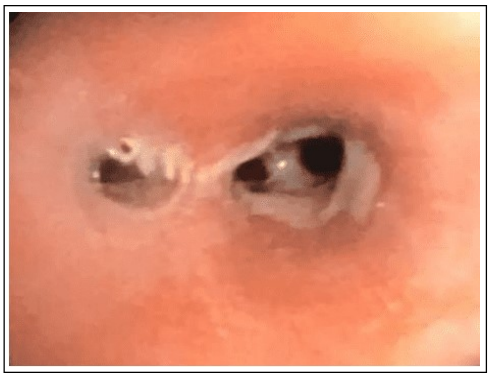

Fig 5: Mucus plugs in bronchioles.



Fig 6: Mucus strands at the bronchioles.

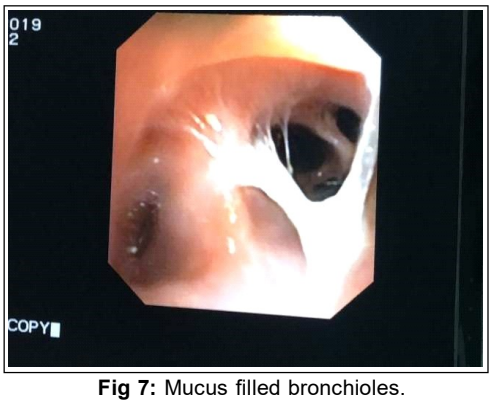

Fig 7: Mucus filled bronchioles.

The results were in accordance to earlier work carried out by Adaszek *et al*. (2009) who demonstrated that *Staphylococcus* sp., *E. coli* and *Klebseilla* sp. were the commonly isolated bacteria in canine respiratory infections. Similar findings were also demonstrated earlier by Ayodhya *et al.* (2013) and Rheinwald *et al*. (2014). None of the samples showed growth when incubated for fungal isolation and identification.

In the present study, microbiological culture of the BALF samples of EBP dogs showed no growth for fungi. The bacteria isolated from BALF were *Staphylococcus* sp., *Streptococcus* sp., *E. coli* and *Klebsiella* sp. Several authors isolated bacteria from BALF of dogs with lower respiratory tract infection. The commonly identified bacteria were *Staphylococcus* sp., *Streptoccous* sp, *Pseudomonas* sp., *Klebsiella* sp., *E. coli* and *Bordotella* sp. (Clercx *et al.,* 2000, Peeters *et al*., 2000, Johnson *et al.,* 2013 and Lappin *et al*., 2017). The present study findings concurred with the observations of above authors. The culture of bronchopulmonary secretion may give positive results even in in the absence of any true infection. The quantitative culture of BAL fluid is needed to distinguish between airway colonization and true infection. A value of 1.7×10^3 CFU/ml of BAL fluid is considered as diagnostic threshold of lower respiratory infection (Peeters *et al*., 2000).

In the study, the antibiogram pattern of BALF showed high sensitivity for Enrofloxacin. This was in accordance with Johnson *et al.* (2013) who studied antimicrobial

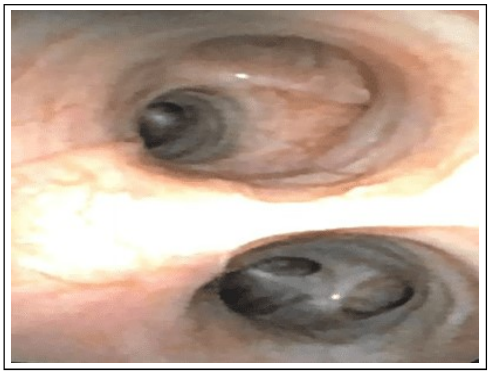

Fig 8: Hyperemic bronchial mucosa with mucus.

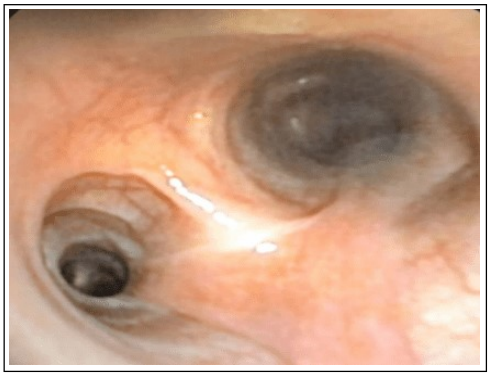

Fig 9: Mild hyperemia of bronchial wall.

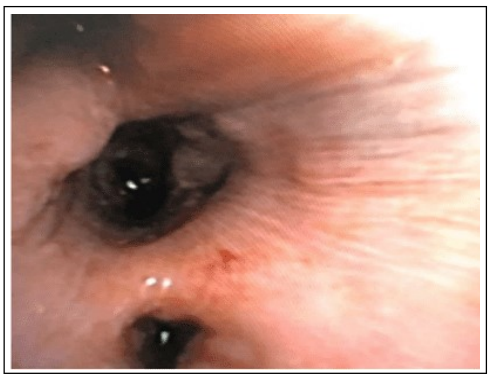

Fig 10: Moderate thickening of bronchial mucosa.



Fig 11: Severe hypermia of bronchial wall.

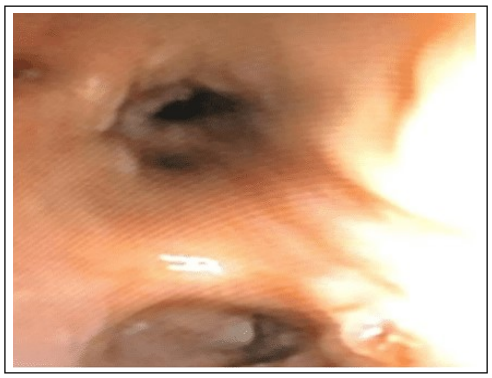

Fig 12: Severe thickening of bronchial mucosa with irregular aspects.

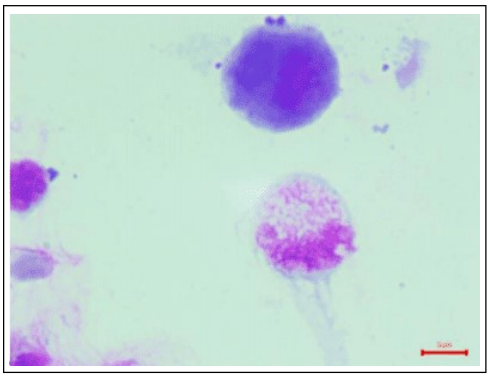

Fig 13: BALF cytology of normal healthy dog showing macrophage (LG stain 1000×).

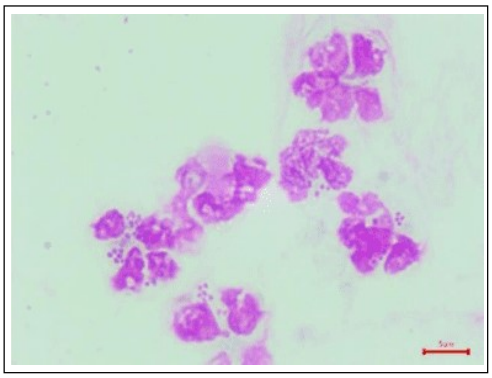

Fig 14: BALF cytology showing neutrophilic infiltration of non EBP dogs (LG stain 1000 ×).

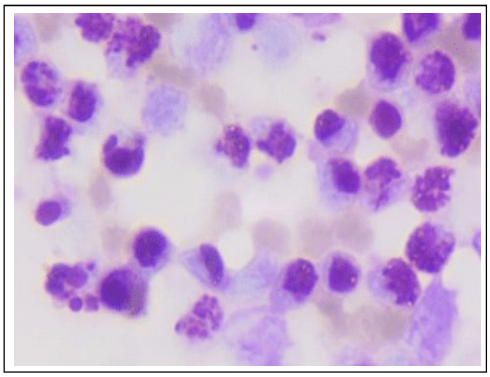

Fig 15: Mild eosinophilic infiltration of EBP (LG stain 1000 ×).

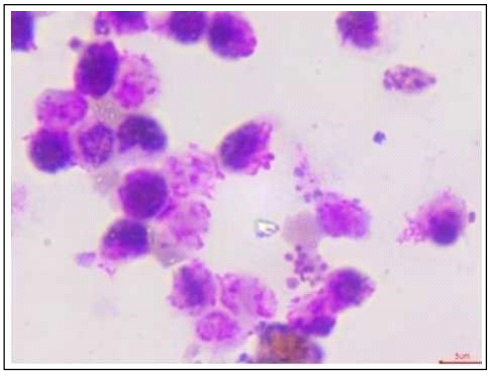

Fig 16: Moderate eosinophilic infiltration of EBP (LG stain 1000 ×).

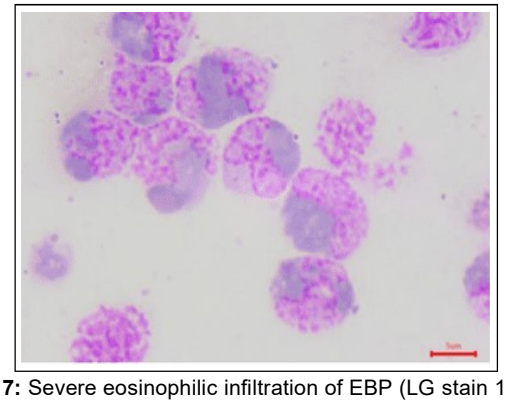

Fig 17: Severe eosinophilic infiltration of EBP (LG stain 1000 ×).

susceptibility of common bacterial isolates of dogs with lower respiratory tract disease. Clercx and Peeters (2007) suggested that pulmonary bacterial infection is uncommon in the dogs with EBP, but it should be promptly recognised and treated before initiating therapy with glucocorticoids.

Antibiotic susceptibilities of the most commonly isolated bacteria are displayed in Table 2 and Fig 2. Enrofloxacin showed the best susceptibility pattern followed by Amikacin which also yielded good susceptibility. Similar susceptibility pattern of Enrofloxacin was observed by Rheinwald *et al*. (2014) in his study.

If a broad antibiotic coverage is indicated in a severely sick dog with a suspected lower respiratory tract infection and airway sampling for culture and susceptibility testing is not possible or results are pending, the use of a combination of antibiotic agents is recommended (Lee-Fowler and Reinero, 2012 and Lappin *et al.,* 2017). Based on the present study, enrofloxacin can be recommended as a first-line treatment in patients suspected for chronic cough and lower respiratory tract infections.

Conclusion

BALF analysis is found to be the gold standard test in the confirmation of EBP in dogs. The most predominant bronchoscopic findings were the presence of muco-purulent secretions and mild to moderate thickening of bronchial mucosa in EBP dogs. The most frequently isolated bacterial species were *Staphylococcus* sp. and the antibiogram pattern of BALF showed high sensitivity for Enrofloxacin, therefore it can be recommended as a first-line treatment in patients suspected for chronic cough and lower respiratory tract infections.

Conflict of interest

All authors decalre that they have no conflict of interest.

References

Adaszek, L., Gorna, M., Zietek, J., Kutrzuba, J. and Winiarczyk, S. (2009). Bacterial nosocomial infections in dogs and cats. Zycie Weterynaryjne. 84: 805-808.

Ayodhya, S., Rao, D.S.T., ReddyY.N., Sundar, N.S. and Kumar, V.G. (2013). Isolation and characterization of bacteria from canine respiratory diseases in and around Hyderabad city, Andhra Pradesh, India. Veterinary World. 7: 601-604.

Brownlie, S.E., (1990). A retrospective study of diagnosis in 109 cases of canine lower respiratory disease. J. Small Anim. Pract. 31(8): 371-376.

Clercx, C., Peeters, D., Snaps, F., Hansen, P., McEntee, K., Detilleux, J., Henroteaux, M. and Day, M.J. (2000). Eosinophilic bronchopneumopathy in dogs. J. Vet. Intern. Med. 14(3): 282-291.

Clercx, C. and Peeters, D. (2007). Canine eosinophilic bronchopne umopathy. Vet. Clin. of North Am. Small Anim. Pract. 37(5): 917-935.

Hawkins, E.C., DeNicola, D.B. and Kuehn, N.F. (1990). Bronchoalveolar lavage in the evaluation of pulmonary disease in the dog and cat: State of the art. J. Vet. Intern. Med. 4(5): 267-274.

Hawkins, E.C., DeNicola, D.B. and Plier, M.L. (1995). Cytological analysis of bronchoalveolar lavage fluid in the diagnosis of spontaneous respiratory tract disease in dogs: A retrospective study. J. Vet. Intern. Med. 9(6): 386-392.

Johnson, L.R., Queen, E., Vernau, W., Sykes, J. and Byrne, B.A. (2013). Microbiologic and cytologic assessment of bronchoalveolar lavage fluid from dogs with lower respiratory tract infection: 105 cases (2001-2011). J. Vet. Intern. Med. 27(2): 259-267.

Lappin, M.R., Blondeau, J., Boothe, D., Breitschwerdt, E.B., Guardabassi, L., Lloyd, D.H., Papich, M.G., Rankin, S.C., Sykes, J.E., Turnidge, J. and Weese, J.S. (2017). Antimicrobial use guidelines for treatment of respiratory tract disease in dogs and cats: Antimicrobial guidelines working group of the International Society for Companion Animal Infectious Diseases. J. Vet. Intern. Med. 31: 279-294.

Lee-Fowler, T. and Reinero, C. (2012). Bacterial Respiratory Infections. In: Infectious Diseases of the Dog and Cat. 4th edn. Ed C.E. Greene. Saunders. pp: 936-950.

Nagarajan, B. (1995). Bronchoscopic Studies in Respiratory Disease of Dogs (Doctoral dissertation) MadrasVeterinary College.

Peeters, D.E., McKiernan, B.C., Weisiger, R.M., Schaeffer, D.J. and Clercx, C. (2000). Quantitative bacterial cultures and cytological examination of bronchoalveolar lavage specimens in dogs. J. Vet. Intern. Med. 14(5): 534-541.

Quinn, P.J., Carter, M.E., Markey, B.K. and Carter, G.R.(1994). Clinical Veterinary Microbiology, Wolfe Publishing, London. 358p.

Rajamäki, M., Järvinen, A.K., Sorsa, T. and Maisi, P. (2002). Clinical findings, bronchoalveolar lavage fluid cytology and matrix metalloproteinase-2 and-9 in canine pulmonary eosinophilia. Vet. J. 163(2): 168-181.

Rheinwald, M., Hartmann,K., Hähner,M., Wolf, G., Straubinger, R.K. and Schulz, B. (2014). Antibiotic susceptibility of bacterial isolates from 502 dogs with respiratory signs. Vet. Rec. 8: 56-61.

Rozanski, E. (2014). Canine chronic bronchitis. Vet.y Clin. Small Anim. 44(1): 107-116.

Smith, A.K., Hungerford, L.L. and Campbell, C.L. (1998). Veterinary Mycology Laboratory Manual. 1st edn. Iowa State University Press. Ames, Iowa. 46p.

Vieson, M. D., Piñeyro, P. and Leroith, T. (2012). A review of the pathology and treatment of canine respiratory infections. Veterinary Medicine. 3: 25-39.