RESEARCH ARTICLE Indian Journal of Animal Research, Volume 58 Issue 10: 1733-1742 (October 2024)

# Histological Studies on Ageing Changes in the Retina of Buffaloes (*Bubalus bubalis*)

A. Prasanth Babu[1], P. Jagapathi Ramayya[2], Y. Nagamalleswari[1], Makkena Sreenu[3], K. Lakshmi Kavitha[4]

10.18805/IJAR.B-4738

## ABSTRACT

**Background:** Affections of eye are commonly encountered in all the species of animals. The age-related changes of the retina primarily cause loss of visual acuity as well as reduction of the visual field. Hence, the current study was carried out to establish basic data related to ageing changes in the retina of buffaloes.

**Methods:** The study was conducted on 63 eye balls of locally available buffaloes of different breeds. These buffaloes were categorized into 3 groups *i.e*., group I (1-5 yrs), group II (6-10 yrs) and group III (11 yrs and above). The eyeballs were isolated and fixed with Davidson's fluid. The paraffin sections were subjected for routine histological study.

**Result:** The thickness of retinal pigment epithelium was increased from group I to III buffaloes from 6.06±0.18 to 8.44±0.32 and the quantity of melanin pigment was decreased with advancement of age. Rod and cone cells of the photoreceptor layer were tightly packed in young age, loosely arranged in old animals. The mean thickness (µm) of photoreceptors and outer nuclear layers together was decreased from 64.22±1.84 to 58.72±2.1 with age advancement. The displacement of nuclei from outer nuclear layer into outer plexiform layer was significantly decreased in old animals. The outer limiting membrane was continuous and uninterrupted throughout the life. The thickness of outer plexiform layer was increased with advancement of age from 8.78±0.58 to 10±0.51 due to enhancement of synaptic fibers density. As age advances the number and density of horizontal, bipolar and amacrine cells were decreased and also the mean thickness (µm) of this layer was decreased from 30.83±1.48 to 22.56±0.62 in the inner nuclear layer. The thickness of inner plexiform layer was increased from 42.44±2.23 to 45.39±0.81 with advancement of age due to increased cystoids spaces and thickening of retinal blood vessels. In ganglionic cell layer, the number of α-ganglion cells were more than the β-ganglion cells, their common number were decreased approximately from 16-20 cells/sq.mm to 7-10 cells/sq.mm, whereas the average size was increased from 4.72±0.49 to 15.83±0.83 with advancement of age. In aged buffaloes nerve fiber layer showed corpora amylacea and thickened blood vessels. The inner limiting membrane became thick and uninterrupted in old buffaloes. The total thickness (µm) of retina in group I, II and III buffaloes were 235.5±7.25, 184.33±3.64 and 201.05±5.15 respectively.

**Key words:** Ageing changes, Buffaloes, Histology, Retina.

## INTRODUCTION

The buffalo holds an important role in Indian rural economy and contributing about 60% of total milk production in the country. Buffaloes are preferred over cattle in India because of their distinctive qualities such as better feed conversion efficiency, more resistance to diseases and higher milk fat percentage than in cows (Bandhopadhyay *et al*., 2003). Affections of eye were commonly encountered in all the species of animals. If these were not treated in time, the vision may be hampered, which may impair the physical ability of animals leading to economic loss to the animal owners. The age related changes of the retina in animals primarily cause a loss of visual acuity and impairment of colour discrimination as well as reduction of the visual field. Impairment of visual functions in aged animals has long been considered the consequence of opacity of the dioptic media (Cavallotti *et al*., 2001). Hence, the present study was carried out to establish basic data pertaining to ageing changes in eyes of buffaloes.

## MATERIALS AND METHODS

The present study was conducted on 63 eye balls of buffaloes at Department of Veterinary Anatomy, College of Veterinary Science, Proddatur. The eye balls were collected from the buffaloes from the slaughter houses in and around Proddatur town of Andhra Pradesh irrespective of breed and sex. The age of the buffaloes was estimated by their

[1]Department of Veterinary Anatomy, College of Veterinary Science, Proddatur-516 360, Andhra Pradesh, India.
[2]Department of Veterinary Anatomy, College of Veterinary Science, Tirupati-517 502, Andhara Pradesh, India.
[3]Department of Veterinary Surgery and Radiology, NTR College of Veterinary Science, Gannavaram-521 102, Andhra Pradesh, India.
[4]Department of Microbiology, NTR College of Veterinary Science, Gannavaram-521 102, Andhra Pradesh, India.

**Corresponding Author:** A. Prasanth Babu, Department of Veterinary Anatomy, College of Veterinary Science, Proddatur-516 360, Andhra Pradesh, India. Email: prasanthankem@gmail.com

**How to cite this article:** Babu, A.P., Ramayya, P.J., Nagamalleswari, Y., Sreenu, M. and Kavitha, K.L. (2024). Histological Studies on Ageing Changes in the Retina of Buffaloes (*Bubalus bubalis*). Indian Journal of Animal Research. 58(10): 1733-1742. doi: 10.18805/IJAR.B-4738.

**Submitted:** 28-07-2021 **Accepted:** 08-02-2022 **Online:** 06-04-2022

dentition (Saini *et al.* 1982). These buffaloes were categorized into 3 groups based on their age *i.e.*, group I (1 to 5 yrs), group II (6 to 10 yrs) and group III (11 yrs and above) buffaloes. The eye balls were separated from the orbital cavity immediately after slaughter and Davidson's fixative fluid injected into the anterior and posterior chambers of eye balls for initial fixation. Then the samples were kept in the same fixative for 72 hours (Latendresse *et al.,* 2009). After complete fixation the retinal samples were collected for histological studies (Luna, 1968). The paraffin sections were subjected to Hematoxylin and Eosin staining for routine histological study and Van Geison's stain for histological study. Immunohistochemical studies were carried out by using anti PAX 6 antibody to identify the ageing changes in the retinal pigment epithelium (Raviv *et al.,* 2014). Further, the micrometry was also done to study the thickness of the different layers of retina. These observations were subjected to statistical analysis (Snedecor and Cochran, 1994) by using SPSS software.

## RESULTS AND DISCUSSION

Histologically, retina of buffaloes showed the following layers without inwards (i) Retinal pigment epithelium (ii) Photoreceptor layer (iii) Outer limiting membrane (iv) Outer nuclear layer (v) Outer plexiform layer (vi) Inner nuclear layer (vii) Inner plexiform layer (viii) Ganglion cell layer (ix) Nerve fiber layer and (x) Inner limiting membrane (Fig 1).

### Retinal pigment epithelium

In buffaloes the pigmented epithelium was cuboidal type and basally adherent to the Bruch's membrane and apically to the photoreceptors with long projections. The cytoplasm of RPE consisted of large quantity of melanin pigment in the non tapetal portion than in the tapetal portion. The RPE cells were cuboidal in group I and gradually elongated in group III buffaloes (Fig 2a, 2b and 2c). These findings were in accordance with Friedmann *et al.* (1968) in normal young human. Further, they stated that the typical RPE cells were hexagonal, mononucleated and approximately 3% of the cells of all age groups were binucleated. But in the present study the binucleated cells were not found in any age groups of buffaloes.

Melanin pigment in RPE cells was decreased from group I to III, which was supported qualitatively by immunohistological study with PAX6 antibody reaction also (Fig 3a, 3b and 3c). Drusen was not found in in the eyes of buffaloes as buffaloes obtain natural antioxidants *i.e.* Vitamin-E and Vitamin-A abundantly from their regular feed *i.e.* green grasses. This may lead to inhibit the peroxidase damage of outer segments of photoreceptors and prevents the abnormal accumulation of lipofuscin which concurrently maintain the melanin pigment balance in RPE. Dilley and Mc Connell (1970) also mentioned that the α-tocopherol act as antioxidant and play an important role in controlling the membrane metabolism and structure of outer segment stacks of lipoprotein lamellae from peroxidation damage in animals.

The mean thickness (µm) of retinal pigment epithelium of group I, II and III was 6.06±0.18, 6.67±0.23 and 8.44±0.32 respectively (Table 1 and Fig 4). There was a significant increase in thickness of retinal pigment epithelium in group III buffaloes as compared to group I and II. It may be due to the elongation of RPE cells and accumulation of fragmented discs and metabolites of photoreceptors. Similarly, Dellmann and Eurell (2006) stated that function of RPE includes transport of nutrients and metabolites from the capillaries of choroid to the rods and cones, phagocytosis, lysosomal degeneration and recycling of the shredded outer segments of photoreceptors.

### Photoreceptors and outer nuclear layer

The photoreceptors cells were tightly packed with less intercellular spaces in group I, whereas in the group II and III intercellular spaces were (Fig 5a, 5b and 5c). The nuclei of photoreceptors from the outer nuclear layer neither displaced to outer segments of photoreceptors nor outer plexiform layers in group I buffaloes. Whereas in group II and III the nuclei of photoreceptors were extended into outer plexiform layer. Similarly Gartner and Henkind (1981) noted displacement of photoreceptor nuclei into the outer plexiform layer in old age people.

In the present study number of rods was more compared to the cones in all age groups, but the number of cones was progressively increased and the rods were decreased from

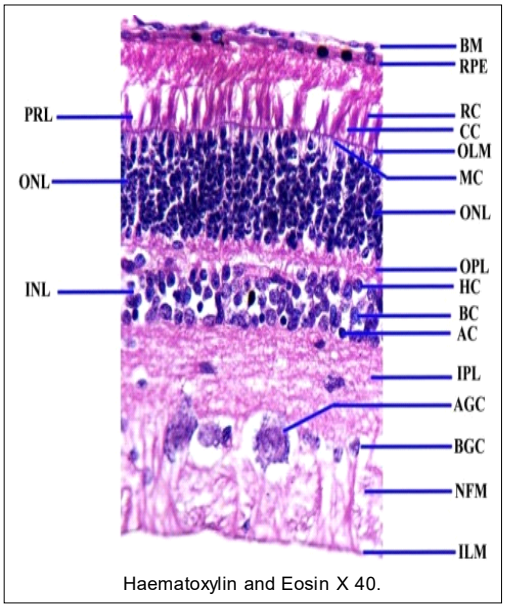


**Fig 1:** Photomicrograph of retina of buffaloes showing Bruch's membrane (BM), Retinal pigment epithelium (RPE), Photoreceptor layer (PRL), Rod cells (RC), Cone cells (CC), Outer limiting membrane (OLM), Muller cells (MC), Outer nuclear layer (ONL), Outer plexiform layer (OPL), Inner nuclear layer (INL), Horizontal cells (HC), Bipolar cells (BC), Amacrine cells (AC), Inner plexiform ayer (IPL), α- Ganglion cells (AGC), β-Ganglion cells (BGC), Nerve fiber layer (NFL) and Inner limiting membrane (ILM).

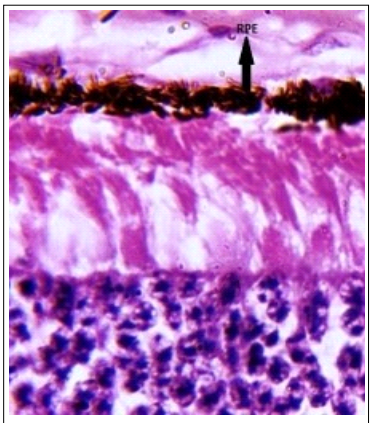

Haematoxylin and eosin X 1000.

**Fig 2a:** Photomicrograph of retinal pigment epithelium (RPE) of group I buffaloes showing cuboidal cells with tightly packed melanin pigment.

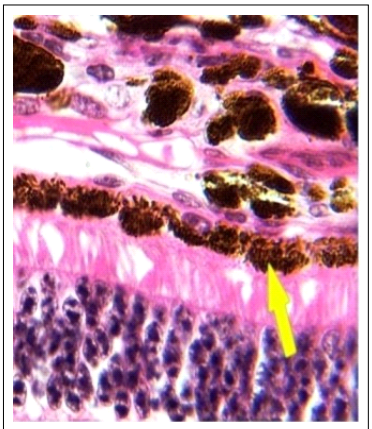
Haematoxylin and Eosin X 1000.

**Fig 2b:** Photomicrograph of retinal pigment epithelium (Arrow) of group II buffaloes showing cuboidal epithelium with moderate melanin pigment.

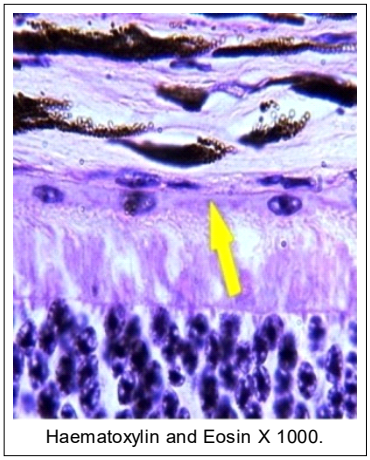
Haematoxylin and Eosin X 1000.

**Fig 2c:** Photomicrograph of retinal pigment epithelium (Arrow) of group III buffaloes showing cuboidal epithelium with less melanin pigment.

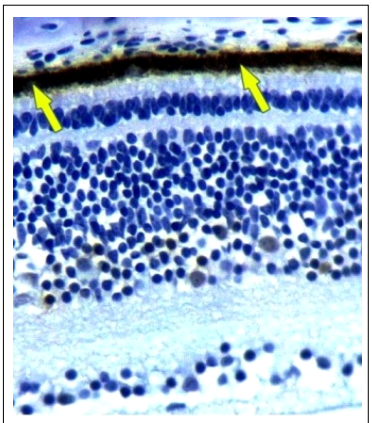
X100.

**Fig 3a:** Photomicrograph of retina of group I buffaloes showing strong immune positive reaction for PAX6 in Retinal Pigment Epithelium (Arrow).

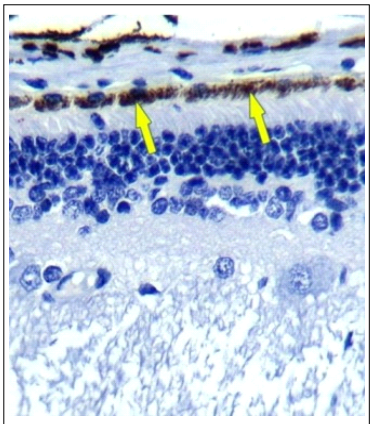
X100.

**Fig 3b:** Photomicrograph of retina of group II buffaloes showing mild to moderate immune positive reaction for PAX6 in Retinal Pigment Epithelium (Arrow).

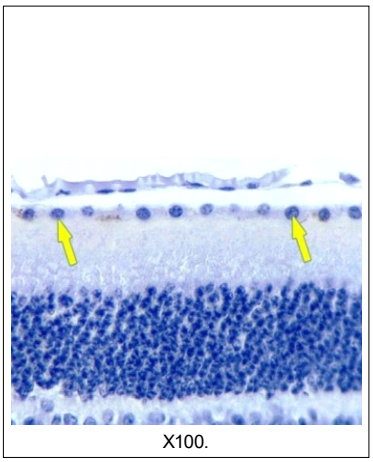
X100.

**Fig 3c:** Photomicrograph of retina of group III buffaloes showing no immune positive reaction for PAX6 in Retinal Pigment Epithelium (Arrow).

**Table 1:** Mean thickness (µm) of different layers of retina in buffaloes of different age groups.

| Retina | Group I | Group II | Group III |
|---|---|---|---|
| Retinal pigment epithelium | 6.06±0.18$^{b}$ | 6.67±0.23$^{b}$ | 8.44±0.32$^{a}$ |
| Photoreceptor and Outer nuclear layer | 64.22±1.84$^{a}$ | 49.17±1.63$^{c}$ | 58.72±2.1$^{b}$ |
| Outer plexiform layer | 8.78±0.58$^{ab}$ | 8.28±0.33$^{b}$ | 10±0.51$^{a}$ |
| Inner nuclear layer | 30.83±1.48$^{a}$ | 24.55±0.71$^{b}$ | 22.56±0.62$^{b}$ |
| Inner plexiform layer | 42.44±2.23$^{a}$ | 32.56±0.95$^{b}$ | 45.39±0.81$^{a}$ |
| Ganglion cell+Nerve fiber layer+Inner limiting membrane | 83.17±2.08$^{a}$ | 63.11±1.83$^{b}$ | 55.94±2.2$^{c}$ |
| Total thickness | 235.5±7.25$^{a}$ | 184.33±3.64$^{c}$ | 201.05±5.15$^{b}$ |

Mean values with different superscripts in rows differ significantly (P<0.05 and 0.01).
One way ANOVA, SE-Standard error.

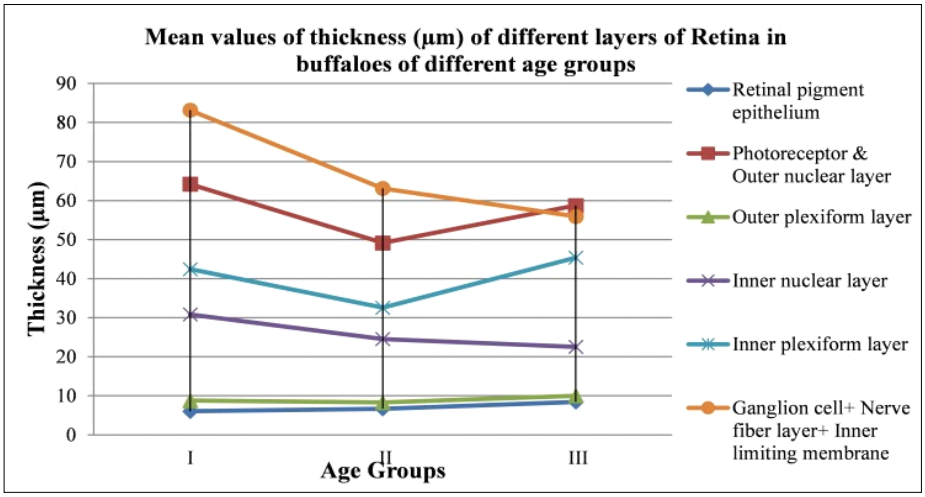


**Fig 4:** Mean total thickness (µm) of retina in buffaloes of different age groups.

group I to group III buffaloes (Fig 5a, 5b and 5c). Similar findings were also reported by Curcio and Drucker, (1993) and Gao and Hollyfield (1992) in human retina. These findings suggested that the rods appear to be more affected by ageing than cones both in buffalo and human. The mean thickness (µm) of photoreceptors and outer nuclear layers of retina of group I, II and III was 64.22±1.84, 49.17±1.63 and 58.72±2.1 respectively (Table 1 and Fig 4). It indicated that the mean thickness (µm) of photoreceptors and outer nuclear layers of retina of group I to III was significantly decreased due to the decreased number of rods and their nuclei with advancement of age in buffaloes. These findings suggested that the declining of sensitivity of the peripheral field of vision with ageing than that of the central field in buffaloes, which may be resulted due to the functional vulnerability of rods with ageing in animals. Marshall *et al.* (1998) observed the morphological distortions in rod outer segments and their diameter was increased from 2.5 µm to 3.5 µm in all areas of retina in human.

### Outer limiting membrane

The outer limiting membrane was formed by joining of adjacent photoreceptors and Muller cells processes. This membrane separated the inner segments of rods and cones from the outer nuclear layer. These findings were in accordance with the Dellmann and Eurell (2006) in other domestic animals. The outer limiting membrane was apparent, continuous and unbroken throughout the life in all age groups of buffaloes.

### Outer plexiform layer

This layer was formed by dendritic and axonic terminals of horizontal and bipolar cells along with displaced nuclei of horizontal cells in buffaloes. Similar findings were also noticed by Dellmann and Eurell (2006) in domestic animals.

The mean thickness (µm) of outer plexiform layer of retina was 8.78±0.58, 8.28±0.33 and 10±0.51 in group I, II and III buffaloes respectively (Table 1 and Fig 4). These findings suggested that the outer plexiform layer thickness was increased with advancement of age in buffaloes. This might be due to that increased number of synaptic fibers between photoreceptors and cells of inner nuclear layer with advancement of age.

### Inner nuclear layer

The inner nuclear layer consisted of four types of cells *viz.*, horizontal, bipolar, amacrine and Muller cells. The horizontal cells were located in the outer zone of the nuclear layer and they had round or oval nucleus and more perinuclear cytoplasm. Whereas, Gallego and Laufer *(*1982) reported two types of horizontal cells *i.e.*, H1 cell with a short axon and an axon less H2 cells in most of the vertebrate retinae.

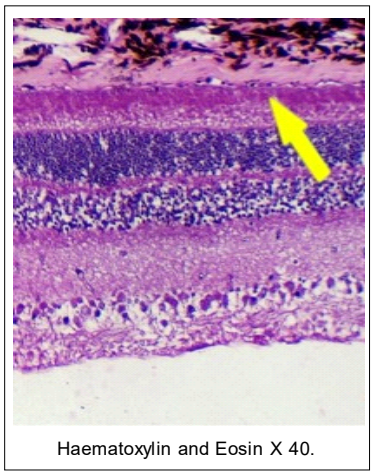

Haematoxylin and Eosin X 40.

**Fig 5a:** Photomicrograph of photoreceptor layer (Arrow) of group I buffaloes showing more number of tightly packed rod cells than cone cells with less intercellular space.

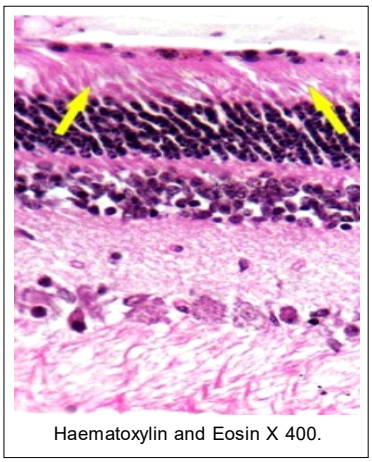

Haematoxylin and Eosin X 400.

**Fig 5b:** Photomicrograph of photoreceptor layer (Arrow) of group II buffaloes showing increased intercellular spaces and loosely arranged rod and cone cells.

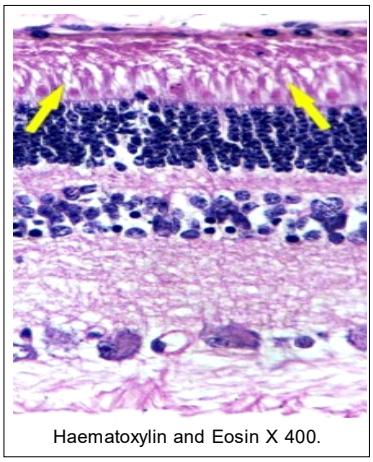

Haematoxylin and Eosin X 400.

**Fig 5c.** Photomicrograph of photoreceptor layer (Arrow) of group III buffaloes showing increased intercellular spaces and loosely arranged rod and cone cells.

But in the present study such differentiation was not observed in horizontal cells of retina of buffaloes. The bipolar cells were characterized by large, round nuclei and long processes and they were placed in the center of the inner nuclear layer. The amacrine cells were predominate in the inner portion of the inner nuclear layer and their nuclei were generally characterized by deep invaginations. The Muller or radial glial cells were fibrous astrocytes characterized by a homogenous oval nuclei and a dark cytoplasm located in the outer portion of the inner nuclear layer. The density of the nuclei of these three cells in inner nuclear layer was decreased with advancement of age *i.e.* from group I to group III animals (Fig 6a, 6b and 6c). The mean thickness (µm) of inner nuclear layer was 30.83±1.48 in group I, 24.55±0.71 in group II and 22.56±0.62 in group III buffaloes (Table 1 and Fig 4). The above findings suggested that in retina the density of nuclei of different cells decreased gradually with advancement of age in inner nuclear layer. No supporting literature is available pertaining to above findings in domestic animals.

**Inner plexiform layer**

In buffaloes, the inner plexiform layer was a synaptic layer comprised of predominately the axons of amacrine and bipolar cells and dendrites of ganglion cells in buffaloes. These observations were coincided with the findings of Dellmann and Eurell (2006) in domestic animals. In young animals between 1 to 2 years this layer was comprised of many displacing amacrine cells and few ganglion cells, but sparse in old buffaloes. Both connective tissue and nerve fibers were densely arranged in group I but were sparse in group II to III, this may be due to increased cystoid spaces as age advances (Fig 7a, 7b and 7c).

The mean thickness (µm) of inner plexiform layer of retina was 42.44±2.23, 32.56±0.95 and 45.39±0.81 in group I, II and III, respectively (Table 1 and Fig 4). The present observations revealed that the thickness of inner plexiform layer was increased in buffaloes in group III. Similar findings were also noticed by Folberg (1996) and O' Malley and Allen (1967) in human retina. This degeneration was thought to be due to choroidal vascular insufficiency as opined by O'Malley and Allen (1967) in human beings.

**Ganglion cell, nerve fiber layer and inner limiting membrane**

Two types of ganglion cells were reported *i.e.* α- and β-ganglion cells in the retina of buffaloes. The α-ganglion cells were large and characterized by large nuclei and less amount of cytoplasm. Whereas, the α-ganglion cells were small and consisted of small nuclei and comparatively abundant cytoplasm (Fig 7a, 7b and 7c). Similarly, Bloom and Fawcett (1970) and Kelly *et al.* (1971) also found two types of ganglion cells *i.e.* midget ganglion cells and diffuse ganglion cells. Germain *et al.* (2010) identified 30 types of ganglion cells based upon their morphological differences and Boycott and Wassle, (1974) found three different types *viz.*, α, β and γ ganglion cells in human retina on the basis

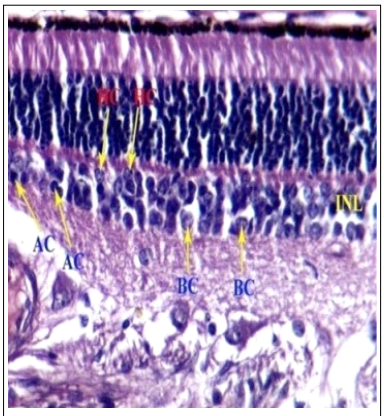


Haematoxylin and Eosin X 400.

**Fig 6a:** Photomicrograph of retina of group I buffaloes showing densely arranged Horizontal cells (HC), Bipolar cells (BC) and Amacrine cells (AC) in the Inner Nuclear Layer (INL).

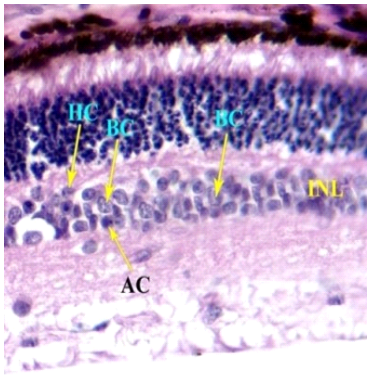


Haematoxylin and Eosin X 100.

**Fig 6b:** Photomicrograph of retina of group II buffaloes showing less densely arranged Horizontal cells (HC), Bipolar cells (BC) and Amacrine cells (AC) in the Inner Nuclear Layer (INL).

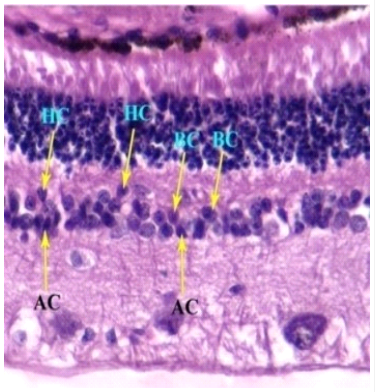


Haematoxylin and Eosin X 100.

**Fig 6c:** Photomicrograph of retina of group III buffaloes showing less densely arranged Horizontal cells (HC), Bipolar cells (BC) and Amacrine cells (AC).

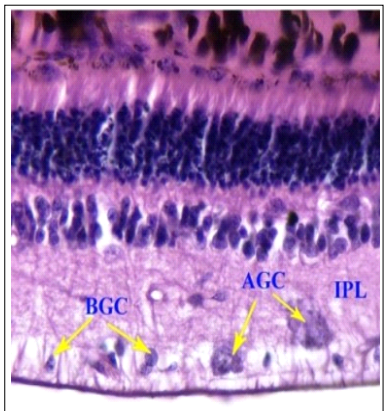


Haematoxylin and Eosin X 100.

**Fig 7a:** Photomicrograph of retina of group I buffaloes showing Inner Plexiform Layer (IPL), α-Ganglion cells (AGC) and β- Ganglion cells (BGC) in the ganglion cell layer.

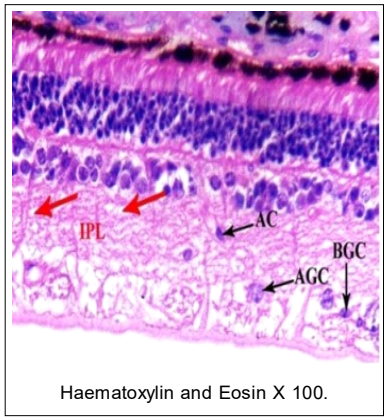


Haematoxylin and Eosin X 100.

**Fig 7b:** Photomicrograph of retina of group II buffaloes showing less displaced Amacrine cells (AC) and more cystoids spaces (Arrow) in the Inner Plexiform Layer (IPL). Relatively more α- Ganglion cells (AGC) and α-Ganglion cells (BGC) in ganglion cell layer.

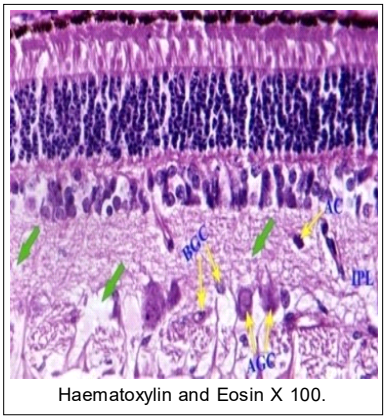


Haematoxylin and Eosin X 100.

**Fig 7c:** Photomicrograph of retina of group III buffaloes showing less displaced Amacrine cells (AC) and more Cystoids spaces (Arrow) in the Inner Plexiform Layer (IPL). Relatively more α- Ganglion cells (AGC) and α-Ganglion cells (BGC) in ganglion cell layer.

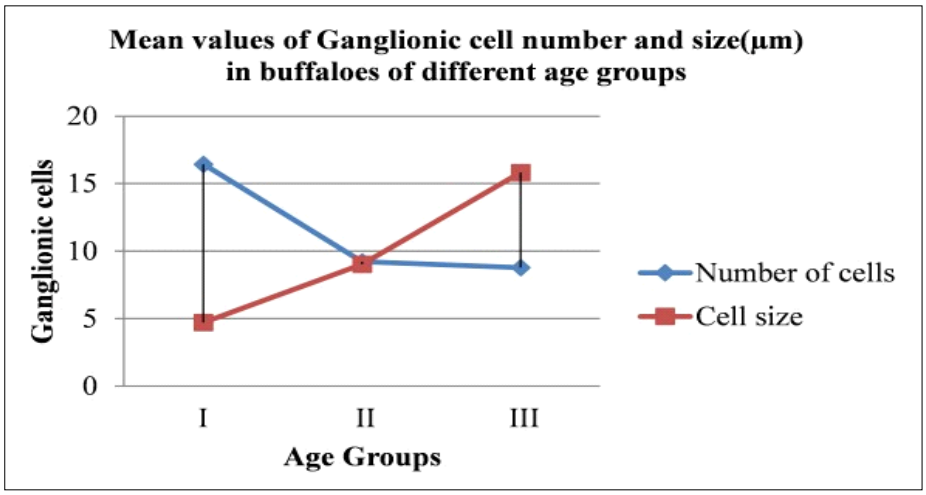


**Fig 8:** Mean number of ganglion cells of retina in buffaloes of different age groups.

**Table 2:** Mean values of number of ganglion cells and size of retina in buffaloes of different age groups.

| Ganglion cells | Group I | Group II | Group III |
|---|---|---|---|
| Number of cells | 16.44 ±1.03[a] | 9.22±0.45[b] | 8.78±0.45[b] |
| Cell size | 11.81±1.22[c] | 22.56±1.03[b] | 39.58±2.08[a] |

Mean values with different superscripts in rows differ significantly (P<0.05 and 0.01). One way ANOVA, SE-Standard error.

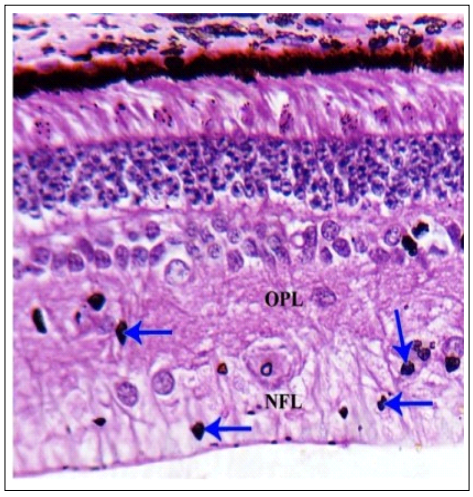


**Fig 9:** Photomicrograph of retina of group III buffaloes showing stained bodies corpora amylacea (Arrow) between the fibers of outer plexiform layer (OPL) and nerve fiber layer (NFL). haematoxylin and eosin X 100.

of dendritic fields. The β-ganglion cells were predominant when compared with α- ganglion cells in group I, whereas with advancement of age the α- anglion cell population was relatively more in group II and III. These findings were in agreement with the findings of Boycott and Wässle (1974) in cats.

Few melanin granules were also reported in ganglion cells. Similarly, Dellmann and Eurell (2006) have noted melanopsin photopigment in ganglion cells of rodents and primates. The number of ganglion cells were decreased from group I to group III. Their number was approximately 16-20 cells/sq.mm in group I and 7-10 cells/sq.mm in group III animals (Table 2 and Fig 8). Similarly, Gao and Hollyfield (1992), Curcio and Drucker (1993) and Grunwald *et al.* (1993) reported 16-20% decrease in average ganglion cell population in human from young to adults. In buffaloes the size of the both α- and the β-ganglion cells was increased from group I to III. The average size of the ganglion cell was 4.72±0.49 in group I, 9.03±0.41 in group II and 15.83±0.83 in group III (Table 2 and Fig 8). This indicated that the size of the ganglion cells was increased but their number was decreased with advancement of age. Cavallotti *et al.* (2001) and Cavallotti *et al.* (2004) also reported that there was an increase in size of the ganglion cells with advancement of age in rat and in human respectively.

In buffaloes the nerve fiber layer consisted of the unmyelinated axons of ganglion cells, they were surrounded by Muller cell processes and occasionally by astrocytes. The stained bodies called corpora amylacea were also present in the retina of aged buffaloes between the fibers (Fig 9). Similarly, Avendano *et al.* (1980) and Woodford and T'so (1980) also noted corpora amylacea in the pericapillary retinal nerve fiber layer, optic disc and optic nerve. Furthermore, these bodies represent the degenerated nerve cells and their organelles in ageing changes of retina of human.

Numerous blood vessels were noted in the inner plexiform and nerve fiber layers of retina in buffaloes. These blood vessels became wide and thickened due to the accumulation of fibrous tissue from group I to group III (Fig 10). It is in conformity with the findings of Folberg (1996) in human. Cogan (1963), Kuwabara and Coagan (1965) and Ramirez *et al.* (2001) reported arteriosclerotic changes in retinal blood vessels with ageing in human, The inner limiting membrane was loose and interrupted in group I and became thick and uninterrupted in most of the aged

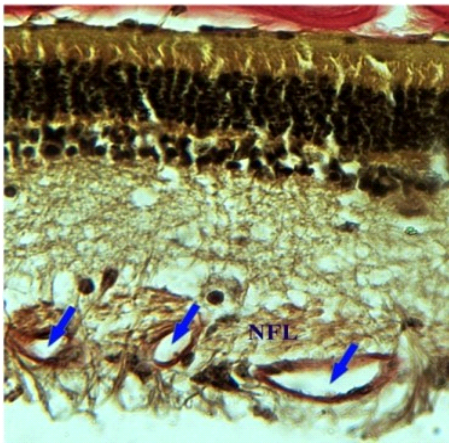


Van gieson's X 100.

**Fig 10:** Photomicrograph of retina of group III buffaloes showing thick and wide blood vessels (Arrow) in the nerve fiber layer (NFL).

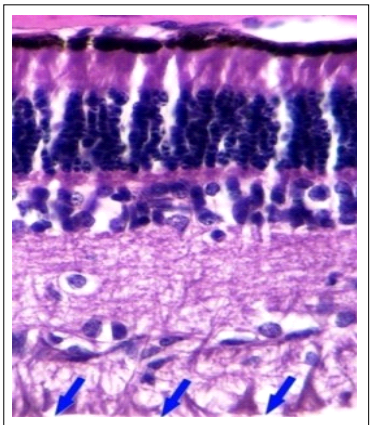

Haematoxylin and eosin X 100.

**Fig 11a:** Photomicrograph of retina of group I buffaloes showing loose and interrupted Inner limiting membrane (Arrow).

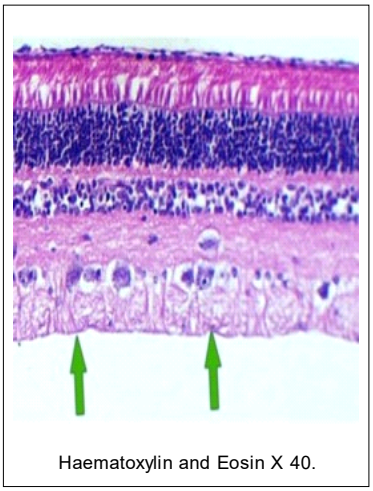

Haematoxylin and Eosin X 40.

**Fig 11b:** Photomicrograph of retina of group II buffaloes showing thick and uninterrupted Inner Limiting Membrane (Arrow).

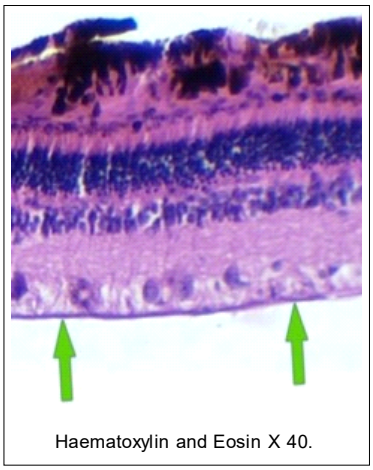

Haematoxylin and Eosin X 40.

**Fig 11c:** Photomicrograph of retina of group III buffaloes showing thick and uninterrupted Inner Limiting Membrane (Arrow).

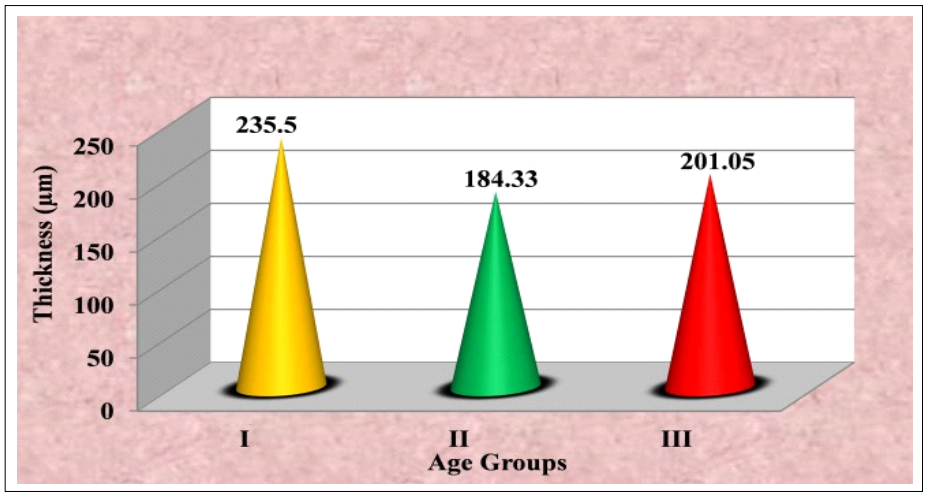


**Fig 12:** Mean size (µm) of ganglion cells in of retina in buffaloes of different age groups.

buffaloes (Fig 11a, 11b and 11c). Similarly, Dellmann and Eurell (2006) also noted continuous layer of inner limiting membrane in domestic animals

In the present study the total thickness (µm) of retina in group I, II and III buffaloes were 235.5±7.25, 184.33±3.64 and 201.05±5.15 respectively (Table 1 and Fig 12). Similar findings were also reported by Cavallotti *et al.* (2001) in rat and Cavallotti *et al.* (2004) in human retina. The above values indicated that there was a decrease in the thickness of retina from group I to group II animals. But the total thickness of retina is slightly increased in group III.

## CONCLUSION

In the present study the thickness of retinal pigment epithelium (RPE) was increased, whereas, the quantity of melanin pigment was decreased with advancement of age. The rod and cone cells were tightly packed in young age and loosely arranged in old animals. The cones cells were more than the rod cells in aged buffaloes. The nuclei of photo receptors were displaced into outer plexiform layer in old animals. The outer limiting membrane was continuous throughout the life. The thickness of outer plexiform layer was increased with advancement of age. The number and density of cells in the inner nuclear layer were decreased in old buffaloes. The inner plexiform layer of group III buffaloes showed increased number of cystoids spaces and thickening of retinal blood vessels between the synaptic fibers of inner nuclear layer cells. Two different ganglionic cells were present in the retina of buffaloes *i.e* $\alpha$ and $\beta$ type ganglionic cells and the number of $\beta$ ganglion cells increased with advancement of age. The corpora amylacea and thickened blood vessels were observed in the nerve fiber layer of retina of old buffaloes. The inner limiting membrane was loose and interrupted in young animals whereas, thick and uninterrupted in old buffaloes.

### Conflict of interest

All authors declare that they have no conflict of interest.

## REFERENCES


Avendano, J., Rodrigues, M.M. and Hackett, J.J. (1980). Corpora amylacea of the optic nerve and retina: A form of neuronal degeneration. Investigative Ophthalmology and Visual Science. 19: 550-555.

Bandyopadhyay, A.K., Ray, P.R and Ghatak, P.K. (2003). Effective Utilization of Buffalo Milk for Manufacturing Dairy Products. 4th Asian Buffalo Congress Lead Papers. 191.

Bloom, W. and Fawcett, D.W. (1970). The Eye. In A Text book of Histology. 9th ed. W.B. Saunders Company, Philadelphia, London, Toronto. pp: 776-811.

Boycott, B.B. and Wässle, H. (1974). The morphological types of ganglion cells of the domestic cat's retina. Journal of Physiology. 240: 397-419.

Cavallotti, C., Artico, M., Pescosolido, N and Feher, J. (2001). Age-related Changes inhuman retina. Japanese Journal of Ophthalmology. 45: 68-75.

Cavallotti, C., Artico, M., Pescosolido, N. and Feher, J. (2004). Age-related Changes in rat retina. Canadian Journal of Ophthalmology. 39: 61-68.

Cogan, D.G. (1963). Development and senescence of the human retinal vasculature. Doyne memorial lecture. Transactions of Ophthalmological Society United kingdom. 83: 465-491.

Curcio, C.A. and Drucker, D.N. (1993). Retinal ganglion cells in Alzheimer's disease and ageing. Annals of Neurology. 33(3): 248-257.

Dellmann, H. and Eurell, J.A. (2006). Eye and Ear. In: Textbook of Veterinary Histology. 6th edn. Lea and Febiger. Philadelphia. pp: 423-456.

Dilley, R.A. and Mc Connell, G.D. (1970). Alpha-tocopherol in the Retinal Outer Segment of Bovine Eyes. Journal of Membrane Biology. 2: 317-323.

Folberg, R. (1996). The Eye. Atlas and Textbook. 4th ed. Philadelphia, PA: W.B. Saunders, Co. pp: 1-37.

Friedman, E., Mark, O.M., Ts'o, M.B. and Boston, B.S. (1968). The Retinal Pigment Epithelium II. Histologic Changes Associated With Age. Archieves of Ophthalmology. 79: 315-320.

Gallego, A.H. and Laufer, M. (1982). The tetrapoda retina. In the S-potential. NewYork. pp: 9-29.

Gao, H. and Hollyfield, J.G. (1992). Ageing of the human retina Differential loss of neurons and retinal pigment epithelial cells. Investigative Ophthalmology and Visual Science. 33(1): 1-17.

Gartner, S. and Henkind, P. (1981). Ageing and degeneration of the human macula. 1. Outernuclear layer and photoreceptors. British Journal of Ophthalmology. 65: 23-28.

Germain, F., Pérez-Rico, C., Vicente, J. and de la Villa, P. (2010). Functional histology of the retina. Microscopy: Science, Technology, Applications and Education. pp: 914-925.

Grunwald, J.E., Piltz, J. and Patel, N. (1993). Effect of aging on retinal macular microcirculation: Ablue field simulation study. Investigative Ophthalmology and Visual Science. 34: 3609-3613.

Kelly, E.D., Wood, L.R. and Enders, A.C. (1971). Bailey's Textbook of Microscopic Anatomy. 8th edn. Williams and Wilkins, Baltimore. In the Organ of Special Senses: The Eye. pp. 822-865.

Kuwabara, T. and Coagan, D.G. (1965). Retinal vascular patterns; VII. Acellular change. Investigative Ophthalmology and Visual Science. 4: 1049-1064.

Latendresse, J.R., Warbrittion, R.A., Jonassen, H. and Creasy, M.D. (2009). Fixation of testes and eyes using a modified Davidson fluid: Comparison with Bouin's fluid and conventional Davidson's fluid. Toxicologic Pathology. 30: 524-533.

Luna, L.G. (1968). Manual of Histological Staining Methods of Armed Forces Institute of Pathology. 3rd Edn. McGraw Hill Book Co, NewYork. pp: 153-173.

Marshall, J., Hussain, A.A. and Starita, C. (1998). The retinal pigment epithelium: Function and disease. New York: Oxford University Press. pp. 669-692.

O' Malley, P.F. and Allen, R.A. (1967). Peripheral cystoid degeneration of the retina: Incidence and distribution in 1,000 autopsy eyes. Archieves of Ophthalmology. 77: 769-776.

Ramirez, J.M., Ramirez, A.I., Salazar, J.J., de Hoz, R. and Trivino, A. (2001). Changes of astrocytes in retinal ageing and age-related macular degeneration. Experimental Eye Research. 73(5): 601-615.

Raviv, S., Bharti, K., Rencus-Lazar, S., Cohen-Tayar, Y., Schyr, R., *et al.* (2014). PAX6 Regulates Melanogenesis in the Retinal Pigmented Epithelium through Feed-Forward Regulatory Interactions with MITF. PLOS Genetics. 10(5): 1-15.

Saini, A., Gill, R.S. and Gill, S.S. (1982). Dentition and ageing in Murrah buffaloes. Indian Journal of Dairy Science. 35(3): 257-262.

Snedecor, G.W. and Cochran, W.G. (1994). Statistical Methods. 6th edn. Oxford and IBH Publishing Co, Bombay.

Woodford, B. and T'so, M.O. (1980). An ultrastructure study of the corpora amylacea of the optic nerve head and retina. American Journal of Opthalmology. 90:492-502.