RESEARCH ARTICLE Indian Journal of Animal Research, Volume 57 Issue 7: 908-914 (July 2023)

Pathology and Molecular Characterization of Porcine Sapelovirus in Indian Pigs

Shailesh Kumar Patel[1], Mamta Pathak[1], Alok Singh[1], Aditya Agrawal[2], Jigyasa Rana[3], G. Saikumar[1]

10.18805/IJAR.B-4739

ABSTRACT

Background: The porcine sapelovirus (PSV) is a small, non-enveloped, single-stranded, positive-sense, RNA virus of the family Picornaviridae. The PSV infections in pigs have been found associated with diarrhoea, polioencephalomyelitis, pneumonia and reproductive disorders with a high morbidity rate. Despite of its economical importance very few studies are available on the pathology of PSV. The present study was conducted with the aim to investigate the PSV infection and associated pathology in Indian pigs.

Methods: Tissue samples along with intestinal content were collected from a total of 78 necropsied cases for histopathological examination and molecular investigation during April 2019 to August 2020. The amplification of 5′ UTR region of PSV was carried out *via* RT-PCR and confirmed by sequencing. The Genetic characterization of Indian isolate of the PSV was done on the basis of viral 5′ UTR gene.

Result: A total of eight out of 78 cases were found positive for the PSV. Catarrhal and haemorrhagic enteritis, thickening and clouding of brain meninges along with congestion of brain and pneumonia was observed as common gross lesions. Microscopic lesions included perivascular cuffing, focal gliosis, neuronophagia, congestion of meningeal and cerebral vessels, interstitial pneumonia, inflammatory changes in the intestinal mucosa and sloughing of villi. The genetic characterization revealed maximum identity of 96.89% with PSV-1 strain PSV-46-V (LC508233) and PSV-1 strain PSV-26-B (LC508232) of Zambia. This study reported the pathological and molecular investigation of PSV from Indian pigs. Further explorative surveillance along with experimental studies in suitable animal model and cell lines are highly warranted for better understanding of PSV pathology in Indian pigs.

Key words: Pathology, Pigs, Porcine sapelovirus, PSV.

INTRODUCTION

Pigs form an important component of the Indian livestock sector. According to the 20th livestock census of India the estimated number of pigs is 9.06 million which comprises 1.69% of the total livestock population (http://dahd.nic.in). Moreover, the pig population is declined by a significant value of 12.03% over previous census which is a serious matter of concern. Pig farming has great potential to ensure economic and nutritional security for the weaker sections of the Indian population. In contrast to this, the profitability of pig farming may be drastically reduced due to occurrence of various infectious and nutritional diseases. The wide range of microbes involved in various enteric and neurological diseases of the pigs pose a great threat to the pig industry. Porcine sapelovirus is among the important pathogens which can cause diarrhoea and nervous disorders responsible for causing significant losses to the pig farmers.

The porcine sapelovirus (PSV) is a non-enveloped, spherical virus of about 30 nm in diameter. The genome of PSV is a linear, non-segmented, single-stranded, positive-sense RNA with a length of 7.5-8.3 kb nucleotides (Lan *et al.*, 2011; Schock *et al.*, 2014). The PSV has been detected in Spain (Buitrago *et al.*, 2010), China (Lan *et al.*, 2011), Brazil (Donin *et al.*, 2014), United Kingdom (Schock *et al.*, 2014), South Korea (Kim *et al.*, 2016; Bak *et al.*, 2016), United States (Chen *et al.*, 2016; Arruda *et al.*, 2017) and India (Ray *et al.*, 2018). In addition, the PSV was isolated from severely diarrhoeic pigs in Korea (Chen *et al.*, 2012). Recently in 2018 for the first time the PSV was reported from the faeces of pigs in India (Ray *et al.*, 2018).

However, the PSV infections are often reported to be subclinical (Sozzi *et al.*, 2010) but the PSV can cause illness with a wide range of symptoms, including polio-encephalomyelitis, diarrhoea, mild to severe pneumonia and reproductive disorders (Lan *et al.*, 2011; Schock *et al.*, 2014; Ray *et al.*, 2018; Kumari *et al.*, 2018). Moreover, the term

[1]Division of Pathology, ICAR-Indian Veterinary Research Institute, Bareilly, Izatnagar-243 122, Uttar Pradesh, India.
[2]Division of Animal Biochemistry, ICAR-Indian Veterinary Research Institute, Bareilly, Izatnagar-243 122, Uttar Pradesh, India.
[3]Department of Veterinary Anatomy, Faculty of Veterinary and Animal Sciences, Rajeev Gandhi South Campus, Banaras Hindu University, Barkachha, Mirzapur-231 001, Uttar Pradesh, India.

Corresponding Author: Shailesh Kumar Patel, Division of Pathology, ICAR-Indian Veterinary Research Institute, Bareilly, Izatnagar-243 122, Uttar Pradesh, India.
Email: shaileshpatel624@gmail.com

How to cite this article: Patel, S.K., Pathak, M., Singh, A., Agrawal, A., Rana, J. and Saikumar, G. (2023). Pathology and Molecular Characterization of Porcine Sapelovirus in Indian Pigs. Indian Journal of Animal Research. 57(7): 908-914. doi: 10.18805/IJAR.B-4739.

Submitted: 28-07-2021 **Accepted:** 18-10-2021 **Online:** 30-10-2021

SMEDI syndrome (Stillbirth, Mummified fetus, Embryonic Death and Infertility) was also adapted to describe the wide range of fertility disorders caused by the PSV (Dunne *et al.*, 1965). Additionally, gastroenteritis and respiratory distress may also be seen in the PSV induced polioencephalomyelitis (Lan *et al.*, 2011).

In PSV infection the lesions were mainly concentrated in the intestines, brain and lungs (Lan *et al.*, 2011). A study including eight PSV positive samples (16%) out of 49 necropsied animals described presence of froathy exudate in trachea, congestion of the lungs, thickening of intestinal mucosa, corrugation of ileum, thickening and clouding of meninges and congestion in brain as major lesions of the PSV. In addition, the study reported microscopic lesions such as engorgement of cerebral and meningeal vessels, infiltration of mononuclear cells in the meninges, gliosis, neuronophagia, mild to moderate perivascular cuffing, congestion and edema of the brain, interstitial pneumonia, vascular congestion of mucosa and submucosa along with mononuclear cells infiltration with increased number of plasma cells in lamina propria (Kumari *et al.*, 2019).

The PSV is ubiquitous and distributed globally in swine population. A wide range of illness is reported to be associated with this group of viruses like encephalomyelitis, respiratory distress, diarrhoea, reproductive disorders and dermal lesions. In this context, diseases with such type of symptoms are frequently seen in the Indian pig population. But, the information about the porcine sapelovirus in Indian pigs, their association with other diseases and their other characteristics is meager. Despite of this, only preliminary work is done on the pathology of PSV in India and a thorough investigation is utmost necessary to establish the pathology of this important pathogen in local pig herds. This study was conducted for pathological and molecular characterization of PSV infection in Indian pigs.

MATERIALS AND METHODS

Collection of samples

The present study included the tissue samples and intestinal content collected from 78 naturally died pigs presented for the necropsy to the post-mortem facility, Division of Pathology, ICAR-IVRI, Izatnagar, Bareilly during April 2019 to August 2020. The study included carcasses of different age groups and either sex with or without the history of diarrhoea. All the carcasses were subjected to detailed necropsy examination and the gross findings were recorded carefully. Tissue samples from lung, liver, spleen, kidney, heart, brain, intestines, tonsil, spleen and lymph nodes were collected in 10% neutral buffered formalin and ice for histopathological examination and molecular investigation respectively.

Histopathological examination

For histopathological processing, the thin pieces of formalin fixed tissue samples were washed overnight under running tap water followed by dehydration through ascending grades of alcohol. After dehydration, clearing was done with acetone and benzene followed by embedding in paraffin wax blocks by automatic tissue processor. The 4-5 µm thick paraffin embedded tissue sections were trimmed by microtome and stained with routine haematoxylin and eosin stain using standard protocol (Bancroft and Gamble, 2008). The stained sections were examined microscopically; the histopathological lesions were carefully recorded and photographed digitally (Olympus BX41, USA).

Molecular examination

Total RNA extraction from tissue samples

The total RNA was extracted from tissue samples using commercial TRIzol® Reagent (Life technologies) which is a modified and improved version of RNA extraction employing guanidium isothiocyanate and phenol as the monophasic solution (Chomcynski and Sacchi, 1987). For extraction of total RNA from the tissue samples approximately 100 mg of tissue samples was homogenized properly on ice with 500 µl of TRIzol® reagent. There after, the suspension was used for RNA isolation using manufacturer's standard protocol. All extracted RNA samples were subjected for quantification by NanoVue plus (Thermo Fisher Scientific, USA) and the purity of RNA was also checked by A260/230 and A260/280 ratio.

First strand cDNA (complementary DNA) synthesis

First strand cDNA from the extracted RNA was synthesized by random priming using the genetically modified Moloney Murine Leukemia Virus Reverse Transcriptase (M-MLVRT) (RevertAid First Strand cDNA Synthesis Kit, Thermo Scientific) in a standard reaction volume of 20 µl. Briefly, 1 µg of RNA (volume varies according to the concentration) and 1 µl of random primer (100 picomole/µl) were added in a sterile nuclease free PCR tube on ice and nuclease free water was added to make the final volume of 12 µl. The mixture was mixed gently and centrifuged briefly followed by incubation at 70°C for 5 min. After incubation the mixture was subjected to quick chilling on ice. To this, 4 µl of 5X Reaction buffer, 2 µl of 10 mM dNTP mix (Thermo Scientific), 1 µl of RiboLock RNase Inhibitor (Thermo Scientific) and 1 µl of RevertAid Reverse Transcriptase was added and incubated at 25°C for 10 min followed by 42°C for 60 min. The reaction was stopped by inactivating the enzyme by heating at 70°C for 5 min. The synthesized cDNA was stored after proper labeling at -20°C till further use.

Polymerase chain reaction (PCR) amplification

The amplification of 5′ UTR region of PSV was carried out *via* RT-PCR using the primer pair PEV 8 g: 5′-ATGGCAGTA GCGTGGCGAGCTAT-3′ and PEV 8 h: 5′-GTAATGCCAAGA GCATGCGCCA-3′ (Zell *et al.*, 2000). All the samples were also screened for porcine teschovirus (PTV), porcine kobuvirus (PKV) and enterovirus G (EV-G) using specific primers. PCR reaction (12 µl) was carried out in 0.2 ml PCR tubes containing 6.0 µl of DreamTaq™ Green PCR Master Mix (2X), 0.5 µl of PEV 8 g primer (10 pmol/µl), 0.5 µl of PEV

8 h primer (10 pmol/µl), 2.0 µl of cDNA (100 ng/µl) and 3.0 µl of nuclease-free water by using a thermocycler (S1000™ Thermal Cycler, BIO-RAD Laboratories India). The PCR was carried out with an initial denaturation of 95°C for 3 minutes; 45 cycles of 95°C for 30 seconds (denaturation), 45°C for 20 seconds (annealing) and 68°C for 30 seconds (extension) and a final extension at 68°C for 7 minutes. The visualization of amplified PCR products was done by agarose gel (1.5% w/v) electrophoresis after staining with 0.5 µg/ml ethidium bromide at 90 V for 60 min under UV transilluminator (Geldoc, USA).

Sequencing of RT-PCR amplicons

The identities of the amplified PCR products was confirmed by direct sequencing of purified DNA using specific primer used for amplification at DNA sequencing facility of Eurofins, Banglore. The sequencing data generated was received as the coloured electropherograms and text files which was analysed and processed further for GeneBank submissions and phylogenetic analysis.

Phylogenetic analysis

The phylogenetic analysis based on 5′ UTR was performed to establish the genotypes of the sequenced virus strains. Thereafter, sequences of various isolates corresponding to other genotypes from different countries were retrieved from GenBank and used as input sequences along with the sequence of isolates found in this study for multiple sequence alignment. The sequence alignment was carried out using ClustalW programme of MEGA v.6 software followed by construction of a phylogenetic tree (Tamura *et al.*, 2013). The Neighbor-joining (NJ) was applied as the statistical method and the reliability of the constructed tree was determined by bootstrap replicates of 1000.

RESULTS AND DISCUSSION

A total of eight out of 78 necropsied animals were found positive for PSV on RT-PCR screening. In RT-PCR, specific amplicons of 211 bp were obtained from PSV positive samples whereas all the tested samples were found negative for PTV and PKV (Fig 1). The RT-PCR positive cases of PSV were further confirmed by sequencing and one processed sequence was submitted to the GeneBank (Accession no. MW018695). All the PSV positive cases were less than 20 days of age suggesting the prevalence of the virus in early aged (less than 1 month) piglets (Table 1). A total of five out of eight positive cases were presented with the history of diarrhoea suggesting the PSV as a causal agent of diarrhoea. The intestinal tissue of three animals was found positive for PSV whereas all spleen, lymph nodes, brain, lungs, spinal cord, kidney and tonsil tissue samples were found negative for the PSV indicating no or minimal viral load in these tissues. However, intestinal content of one necropsied animals was found positive for PSV and four necropsied animals was found positive for PSV and EV-G both indicating the co-infection of more than one enteric picornaviruses. In this study, pathological and molecular characterization was done on the basis of cases positive for PSV only to rule out the involvement of other porcine enteric picornaviruses such as PTV, PKV and EV-G in the pathology. Details of necropsied animals positive for porcine sapelovirus are described in Table 1.

Gross lesions of PSV

The lesions observed in the PSV positive cases were concentrated on gastrointestinal tract, respiratory system and nervous system. The consistent lesions observed in the gastrointestinal tract were congestion of intestinal mucosa and mesenteric lymph nodes, catarrhal enteritis, thickening of intestinal mucosal folds resulting into the formation of corrugations especially in the ileum and mottling along with discoloration of the liver. On necropsy lungs

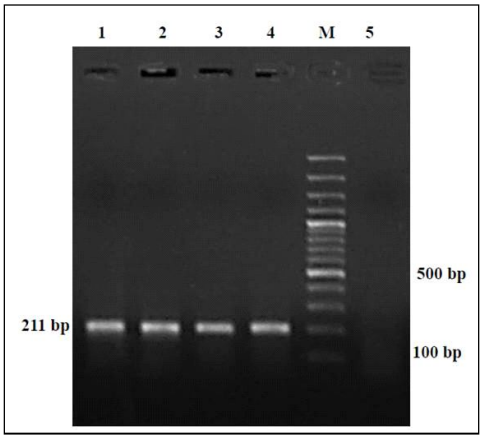

Fig 1: Ethidium bromide stained 1.5% agarose gel showing 211 bp amplicons of PSV: Lane 1-4: Positive sample, Lane M: Marker (100 bp) and Lane 5: Negative test control.

Table 1: Details of necropsied animals positive for porcine sapelovirus by PCR.

Necropsy no.	Breed	Age (Days)	Sex	Type of sample	Virus identified
80 A/19	CB	10	M	Intestine	PSV
106 A/19	CB	17	M	Intestine	PSV
358 A/19	CB	16	M	Intestine	PSV
420 A/19	CB	18	F	Intestinal content	PSV
345 A/19	CB	9	M	Intestinal content	PSV, EV-G
356 A/19	CB	9	F	Intestinal content	PSV, EV-G
357 A/19	CB	14	F	Intestinal content	PSV, EV-G
186 A/20	CB	7	M	Intestinal content	PSV, EV-G

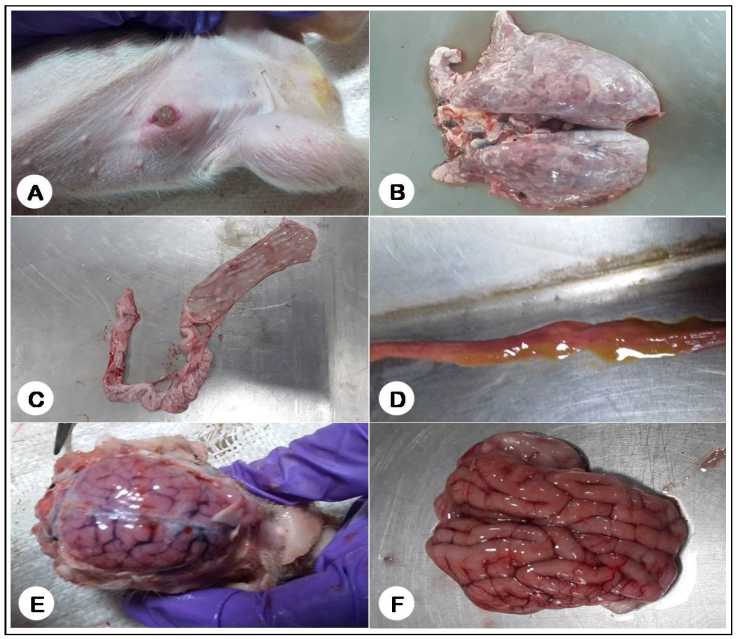

Fig 2: Gross lesions of PSV affected animals.

A: Ruptured vesicle in the ventral surface of abdomen; B: Non-collapsible pneumonic lungs with thickened and inflammed pleura; C: Thickened and slightly corrugated mucosa of ileum; D: Congestion of jejunal mucosa and presence of greenish yellow diarrhoeic content; E: Clouding of meninges along with congestion of meningeal vessels; F: Mild congestion of cerebral blood vessels.

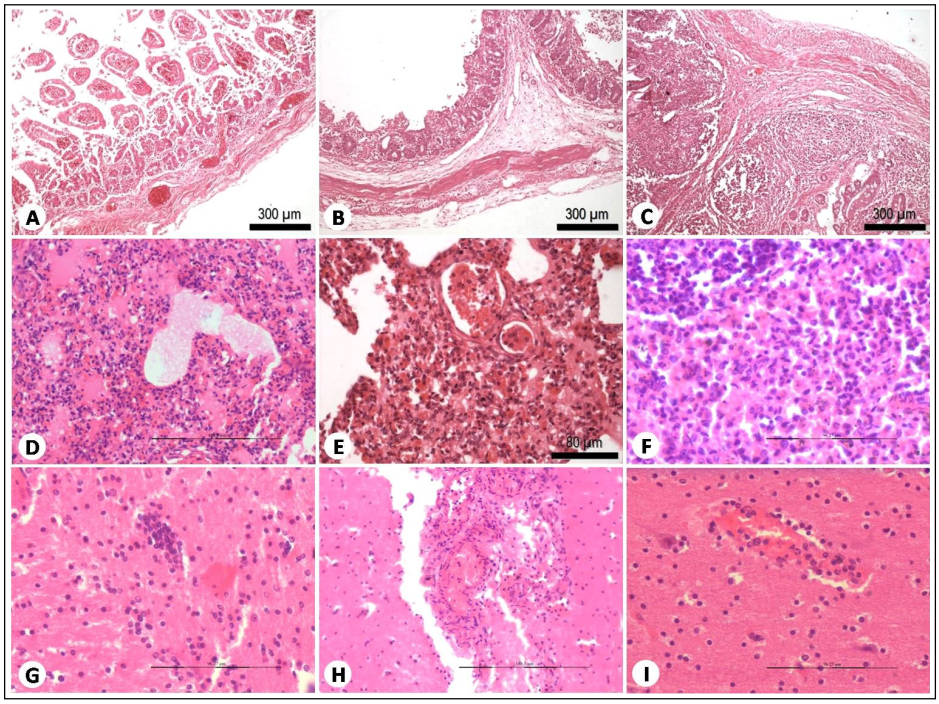

Fig 3: Microscopic lesions of PSV affected animals.

A: Severe degeneration of villi and engorgement of submucosal vessels. Duodenum. H&E, 100X; B: Complete loss of villous structure and hyperplasia of goblet cells. Jejunum. H&E, 100X; C: Mild lymphoid depletion of payer's patches along with infiltration of mononuclear cells in the submucosa. Ileum. H&E, 100X; D: Severe interstitial pneumonia, accumulation of oedema fluid, hamorrhages and infiltration of mononuclear cells in the inter-alveolar septa. Lungs. H&E, 200X; E: Severe vascular engorgement and infiltration of mononuclear cells in the inter-alveolar septa. Lungs. H&E, 400X; F: Moderate degree of lymphoid depletion in mesenteric lymph node. Lymph node. H&E, 400X; G: Gliosis along with increased cellularity in cerebrum. Brain. H&E, 400X; H: Severe infiltration of mononuclear cells in the meninges along with meningeal congestion. Brain. H&E, 200X; I: Moderate degree of perivascular cuffing and congestion of blood vessel. Brain. H&E, 400X.

revealed mild to severe degree of interstitial pneumonia and congestion. Frothy exudate was observed in the trachea of infected piglets. Pleural thickening was also observed in few cases. Lesions observed in the brain include thickening and clouding of the meninges, mild to severe congestion of blood vessels of meninges and brain. Moreover, vesicular lesions on the ventral abdomen, coronets and ears were also observed (Fig 2). In few cases, cyanosis was also observed as less common lesion of the PSV infection. Similar gross lesions have been reported in other studies involving PSV in China (Lan *et al*., 2011) and India (Kumari *et al*., 2019).

Histopathology

The major histopathological lesions in the gastrointestinal tract include severe desquamation of villous epithelium mainly in duodenum, jejunum and ileum. In addition, engorgement of mucosal blood vessels, goblet cell hyperplasia and infiltration of mononuclear cells was also observed. Payer's patches of the ileum showed mild to moderate depletion of lymphoid cells. Moreover, eosinophilic infiltration, mild vascular congestion and depletion of lymphoid cells in the follicles of cortical region were observed in mesenteric lymph nodes. The CNS lesions include congestion of meningeal and parenchymal blood vessels along with perivascular cuffing. In addition, neuronal degeneration, satellitosis along with neuronophagia was also observed in infected piglets. Swelling of endothelial cells of brain capillaries along with severe degree of congestion was observed as a common finding in PSV infection. The lesions in the lungs consist of mild to severe degree of pneumonia which includes interstitial pneumonia, bronchopneumonia or combination of both. In this context, congestion of pulmonary vessels, haemorrhages, pulmonary oedema and infiltration of mononuclear cells in inter-alveolar septa leading to thickening of the septa was observed as common finding in PSV infection (Fig 3). Similar finding were reported in a study from India in which engorgement of cerebral and meningeal vessels, infiltration of mononuclear cells in the meninges, gliosis, neuronophagia, perivascular cuffing, interstitial pneumonia and oedema of lungs, mononuclear cells infiltration in lamina propria of intestine and vascular congestion of mucosa and submucosa was observed (Kumari *et al*., 2019).

The role of PSV particularly as a causal agent of diarrhoea, has been unclear as the entero-like viruses were frequently been isolated from the faecal samples of healthy

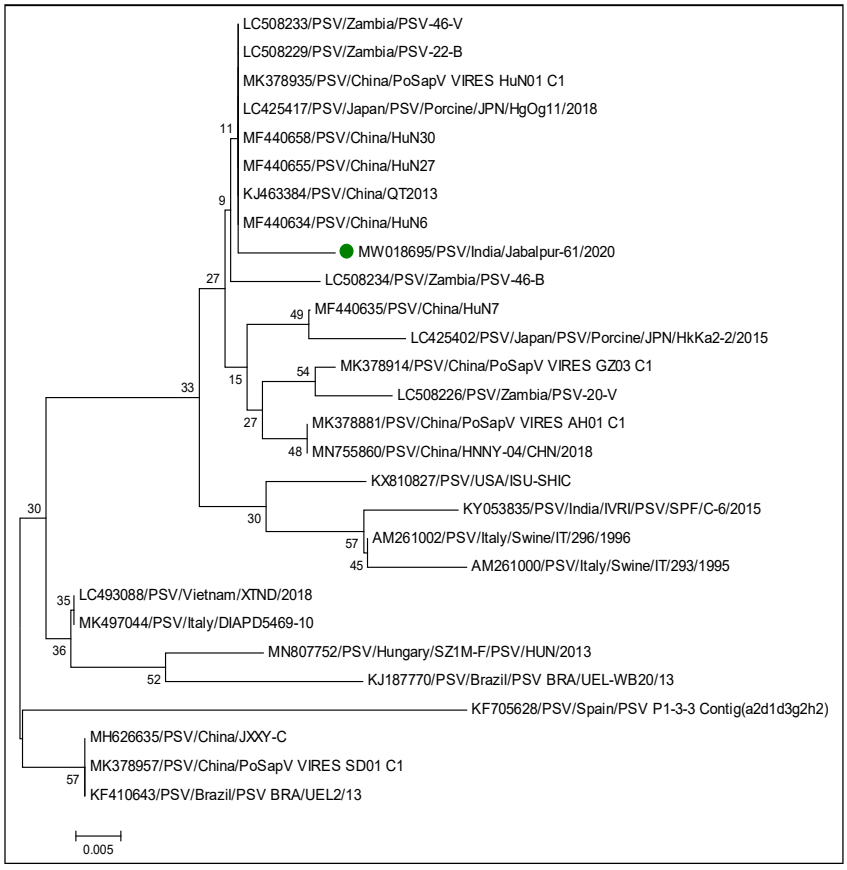

Fig 4: Phylogenetic tree of the Indian isolates of PSV (PSV/India/Jabalpur-61/2020; Accession no. MW018695) with reference sequences based on 5′ UTR region of PSV genome using the Neighbor-Joining method. The percentage of replicate trees in which the associated taxa clustered together in the bootstrap test (1000 replicates) is shown next to the branches.

piglets (Lamont and Betts, 1960; Buitrago *et al.*, 2010; Cano-Gomez *et al.*, 2013). Although, PSV infections are frequently asymptomatic but they have also been found associated with diarrhoea, polioencephalomyelitis, pneumonia and reproductive disorders (Huang *et al.*, 1980; Honda *et al.*, 1990; Knowles, 2006; Lan *et al.*, 2011; Schock *et al.*, 2014). Our study was found in accordance with the above mentioned studies and further studies in this direction may provide better insights of PSV pathology to the global researchers.

Molecular characterization of PSV

The PSV sequence obtained in the study was named as PSV/India/Jabalpur-61/2020 (Accession no. MW018695). On BLAST analysis the sequence showed maximum identity of 96.89% with PSV-1 strain PSV-46-V (LC508233) and PSV-1 strain PSV-26-B (LC508232) of Zambia. For phylogenetic analysis the PSV isolates of the present study was analysed along with 27 sequences retrieved from NCBI database after construction of phylogenetic tree. The phylogenetic analysis revealed that the isolate of this study clustered with and was closely related to PSV strain HuN6, QT2013, HuN27, HuN30 and PoSapV VIRES HuN01 C1 of China, JPN/HgOg11/2018 of Japan and PSV-46-V and PSV-22-B of Zambia (Fig 4).

CONCLUSION AND FUTURE PROSPECTS

The present pathological and molecular investigation of PSV in naturally infected piglets concluded that PSV primarily infects gastro-intestinal tract, nervous system and lungs. The virus mainly affects young piglets of less than one month of age and may found associated with large outbreaks of diarrhoea and nervous disorders. The major pathological findings include mild to severe encephalitis, interstitial pneumonia and severe catarrhal and haemorrhagic enteritis. The PSV is circulating widely among the Indian pigs and more studies targeting this pathogen are highly warranted to minimize the economic losses attributed to PSV. Staining of tissue antigen could not be done in this study due to the unavailability of specific antibodies which may be attempted in future studies. As very limited information is available on the pathology of PSV this study will definitely add to the understanding of PSV infection in Indian pigs. However, further studies in suitable animal model and cell lines are utmost necessary for better insights of the pathology and pathogenesis of the PSV in Indian pigs.

ACKNOWLEDGEMENT

The authors are thankful to the Director and Joint Director (Research) of the Institute (ICAR-Indian Veterinary Research Institute, Bareilly) for providing the funds (Institute funded project) and facilities to carry out this work.

Conflict of interest

The authors declare that they have no conflict of interest.

REFERENCES

Arruda, P.H., Arruda, B.L., Schwartz, K.J., Vannucci, F., Resende, T., Rovira, A., Sundberg, P., Nietfeld, J. and Hause, B.M. (2017). Detection of a novel sapelovirus in central nervous tissue of pigs with polioencephalomyelitis in the USA. Transboundary and Emerging Diseases. 64(2): 311-315.

Bak, G.Y., Kang, M.I., Son, K.Y., Park, J.G., Kim, D.S., Seo, J.Y., Kim, J.Y., Alfajaro, M.M., Soliman, M., Baek, Y.B., Cho, E.H., Kwon, J., Choi, J.S., Park, S.I. and Cho, K.O. (2016). Occurrence and molecular characterization of Sapelovirus A in diarrhea and non-diarrhea feces of different age group pigs in one Korean pig farm. Journal of Veterinary Medical Science. 78(12): 1911-1914.

Bancroft, J.D. and Gamble, M. (2008). Theory and Practice of Histopathological Techniques. 6th Ed., Churchill Livingstone, Elsevier, Philadelphia. pp 657.

Buitrago, D., Cano-Gómez, C., Agüero, M, Fernandez-Pacheco, P., Gómez-Tejedor, C. and Jiménez-Clavero, M.A. (2010). A survey of porcine picornaviruses and adenoviruses in fecal samples in Spain. Journal of Veterinary Diagnostic Investigation. 22: 763-766.

Cano-Gómez, C., García-Casado, M.A., Soriguer, R., Palero, F. and Jiménez-Clavero, M.A. (2013). Teschoviruses and sapeloviruses in faecal samples from wild boar in Spain. Veterinary Microbiology. 165: 115-122.

Chen, J., Chen, F., Zhou, Q., Li, W., Song, Y., Pan, Y., Zhang, X., Xue, C., Bi, Y. and Cao, Y. (2012). Complete genome sequence of a novel porcine sapelovirus strain YC2011 isolated from piglets with diarrhea. Journal of Virology. 86: 10898.

Chen, Q., Zheng, Y., Guo, B., Zhang, J., Yoon, K.J., Harmon, K.M., Main, R.G. and Li, G. (2016). Complete genome sequence of porcine sapelovirus strain USA/IA33375/2015 identified in the United States. Genome Announcement. 4(5): e01055-16.

Chomczynski, P. and Sacchi, N. (1987). Single-step method of RNA isolation by acid guanidinium thiocyanate-phenol-choloroform extraction. Analytical Biochemistry. 162(1): 156-159.

Donin, D.G, de ArrudaLeme, R., Alfieri, A.F., Alberton, G.C. and Alfieri, A.A. (2014). First report of porcine teschovirus (PTV), porcine sapelovirus (PSV) and enterovirus G (EV-G) in pig herds of Brazil. Tropical Animal Health and Production. 46(3): 523-528.

Dunne, H.W., Gobble, J.L., Hokanson, J.F., Kradel, D.C. and Bubash, G.R. (1965). Porcine reproductive failure associated with a newly identified 'SMEDI' group of picornavirus. American Journal of Veterinary Research. 26: 1284-1297.

Honda, E., Hattori, I., Oohara, Y., Taniguchi, T., Ariyama, K.I., Kimata, A., Nagamine, N. and Kumagai, T. (1990). Sero- and CPE-types of porcine enteroviruses isolated from healthy and diarrheal pigs: Possible association of CPE type II with diarrhea. Japanese Journal of Veterinary Science. 52(1): 85-90.

Huang, J., Gentry, R.F. and Zarkower, A. (1980). Experimental infection of pregnant sows with porcine enteroviruses. American Journal of Veterinary Research. 41(4): 469-473.

Kim, D.S., Kang, M.I., Son, K.Y., Bak, G.Y., Park, J.G., Hosmillo, M., Seo, J.Y., Kim, J.Y., Alfajaro, M. M., Soliman, M. and Baek, Y. B. (2016). Pathogenesis of Korean sapelovirus a in piglets and chicks. Journal of General Virology. 97(10): 2566-2574.

Knowles, N.J. (2006). Porcine Enteric Picornaviruses in Diseases of Swine, Wiley-Blackwell, Oxford, UK. 9: 337-345.

Kumari, S., Ray, P.K., Singh, R., Desingu, P.A., Varshney, R. and Saikumar, G. (2019). Pathological and molecular investigation of porcine sapelovirus infection in naturally affected Indian pigs. Microbial Pathogenesis. 127: 320-325.

Kumari, S., Singh, R. and Saikumar, G. (2018). Epidemiological study of porcine sapelovirus infection in pigs at Bareilly area of Uttar Pradesh, India. Biological Rhythm Research. 14: 1-11.

Lamont, P.H. and Betts, A.O. (1960). Studies on enteroviruses in pigs-IV: The isolation in tissue culture of a possible enteric cytopathogenic swine orphan (ECSO) virus (V13) from the faeces of a pig. Research in Veterinary Science. 1: 152-159.

Lan, D., Ji, W., Yang, S., Cui, L., Yang, Z., Yuan, C. and Hua, X. (2011). Isolation and characterization of the first Chinese porcine sapelovirus strain. Archives of Virology. 156: 1567-1579.

Ray, P.K., Desingu, P.A., Kumari, S., John, J.K., Sethi, M., Sharma, G.K., Pattnaik, B., Singh, R.K. and Saikumar, G. (2018). Porcine sapelovirus among diarrhoeic piglets in India. Transboundary and Emerging Diseases. 65(1): 261-263.

Schock, A., Gurrala, R, Fuller, H., Foyle, L., Dauber, M., Martelli, F., Scholes, S., Roberts, L., Steinbach, F. and Dastjerdi, A. (2014). Investigation into an outbreak of encephalomyelitis caused by a neuroinvasive porcine sapelovirus in the United Kingdom. Veterinary Microbiology. 172(3-4): 381-389.

Sozzi, E., Barbieri, I., Lavazza, A., Lelli, D., Moreno, A., Canelli, E., Bugnetti, M. and Cordioli, P. (2010). Molecular characterization and phylogenetic analysis of VP1 of porcine enteric picornaviruses isolates in Italy. Transboundary and Emerging Diseases. 57: 434-442.

Tamura, K., Stecher, G., Peterson, D., Filipski, A. and Kumar, S. (2013). MEGA6: Molecular evolutionary genetics analysis version 6.0. Molecular Biology and Evolution. 30(12): 2725-2729.

Zell, R., Krumbholz, A., Henke, A., Birch-Hirschfeld, E., Stelzner, A., Doherty, M., Hoey, E., Dauber, M., Prager, D. and Wurm, R. (2000). Detection of porcine enteroviruses by nRT-PCR: Differentiation of CPE groups I-III with specific primer sets. Journal of Virological Methods. 88: 205-218.