RESEARCH ARTICLE Indian Journal of Animal Research, Volume 59 Issue 5: 845-851 (May 2025)

Lower Urinary Tract Diseases (LUTD) in Geriatric Dogs

K. Satish Kumar[1], J. Jyothi[2], G. Ambica[3], P. Nagaraj[2]

10.18805/IJAR.B-4744

ABSTRACT

Background: The clinical manifestations of lower urinary tract diseases (LUTD) are common but non-specific to any particular disease among geriatric dogs. Diagnosis and confirmation of the specific lower urinary tract disease is a biggest challenge for a successful treatment plan.

Methods: Geriatric dogs that were presented with signs suggestive of lower urinary tract diseases were subjected for detailed clinical examination followed by complete urinalysis, culture and microscopic examination of the urine sample that was collected by ultrasound guided cystocentesis. Abdomen radiography and ultrasonography was also performed to confirm the specific LUT disease. Fine needle aspiration of prostate was also carried out in few selected cases.

Result: A total of 52 geriatric dogs were diagnosed for various lower urinary tract diseases such as cystitis, cystic calculi, prostate infection, transitional cell carcinoma and both calculi with cystitis. Stranguria, dysuria, malodorous urine, blood-tinged urine, oliguria, urinary incontinence and anuria were few common signs recorded. Apart from RBCs, WBCs and other cellular debris, various types of crystals were also detected on microscopic evaluation of the urine sample. Struvite or triple phosphate crystals (coffin-lid shape) were of predominant, followed by calcium oxalate dihydrate (octahedron or envelope shape), calcium oxalate monohydrate (picket fence shape) and ammonium urate or biurate (irregular shape). Most commonly calculi were retrieved from bladder and in few male dogs from urethra. In addition to cystic calculi, transitional cell carcinoma was also recorded among few cases that were reported with hematuria. Enlarged prostate and abscess were common abnormalities of prostate among geriatric dogs.

Key words: FNAC, Geriatric dogs lower urinary tract diseases, Ultrasonography, Urinalysis.

INTRODUCTION

Unlike veterinary medicine, great advances have been made in human geriatric medicine over the past 20 years, wherein it improved our knowledge on many diseases of the elderly and so their treatment and management (Davies, 1996). In veterinary practice clients ignore their pets when they show preliminary signs *viz*., polyuria or polydipsia in the belief that such signs are common with advancing age (Davies, 1996). Urinary incontinence and/or inappropriate urination is commonly reported in elderly dogs and cats and is a major reason for euthanasia. Dogs suffer from various urinary tract disorders leading to malfunctioning of organs followed by critical medical emergency or death of the animal (Mukherjee *et al*., 2014). Lower urinary tract disease (LUTD) includes various diseases that affect the bladder, urethra and prostate are usually seen in 2 to 3% of senior dogs and are presented with hematuria, pollakuria, urinary incontinence or stranguria (Bartges and Kirk, 2012). However, none of these signs is indicative of a specific disease, such as bacterial urinary tract infection, urolithiasis, micturition disorders or prostate diseases. The present study is aimed to understand the specific causes of LUTD in geriatric dogs that allows diagnostic and therapeutic efforts to be directed toward identification, removal and management.

MATERIALS AND METHODS

Geriatric dogs (aged more than 8 years) that were presented to Veterinary Clinical Complex (VCC), College of Veterinary Science, Rajendranagar, PVNR Telangana Veterinary University, Hyderabad with the history and signs suggestive of lower urinary tract (LUT) infections during Sep 2019 to May 2021 were selected for the study. All these dogs were subjected for detailed clinical examination followed by urinalysis, radiography and abdomen ultrasonography to diagnose the specific LUT disease. Urine was collected either by bladder expression or ultrasound guided cystocentesis (Kurien *et al*., 2004) or by catheterisation, for complete urinalysis. Sample was later proces.sed through centrifuge at 2,000 rpm for 5 minutes until a moderately cohesive button is produced at the bottom of the tube. The supernatant is decanted and a volume of

[1]Department of Veterinary Medicine, College of Veterinary Science, Rajendranagar, P.V. Narasimha Rao Telangana Veterinary University, Hyderabad-500 030, Telangana, India.
[2]Department of Veterinary Clinical Complex, College of Veterinary Science, Rajendranagar-500 031, Telangana, India.
[3]Department of Veterinary Medicine, College of Veterinary Science, Rajendranagar-500 031, Telangana, India.

Corresponding Author: K. Satish Kumar, Department of Veterinary Medicine, College of Veterinary Science, Rajendranagar, P.V. Narasimha Rao Telangana Veterinary University, Hyderabad-500 030, Telangana, India. Email: drsatish.ksk@gmail.com

How to cite this article: Kumar, K.S., Jyothi, J., Ambica, G. and Nagaraj, P. (2025). Lower Urinary Tract Diseases (LUTD) in Geriatric Dogs. Indian Journal of Animal Research. 59(5): 845-851. doi: 10.18805/IJAR.B-4744.

Submitted: 03-08-2021 **Accepted:** 01-02-2022 **Online:** 28-03-2022

0.2 to 0.5 ml is left inside the tube. The sediment is re-suspended in the remaining supernatant by flicking the bottom of the tube several times. A drop of re-suspended sediment is poured onto a glass slide and cover slip was placed. It was then examined by light microscope under both low-power and high-power field (Kesson *et al*., 1978). Both lateral and ventro-dorsal radiographs were taken. Later, abdomen ultrasonography was carried out using Ixos Vet and Mindray Z5 ultrasound machine with linear L4-8 and C5-8 micro convex probes. Ultrasound guided fine needle aspiration of prostate was also carried out in few selected cases.

Results and Discussion

Out of a total 576 geriatric (aged above 8 years) dogs of various breed and gender that were presented to VCC, CVSc, Rajendranagar, 81 were showing the signs suggestive of renal diseases and of which 52 cases were diagnosed for various lower urinary tract disorders *viz*., cystitis (22), cystic calculi (13), prostate infection (8), transitional cell carcinoma (5) and both calculi with cystitis (4). Almost all the dogs that were diagnosed for cystitis were showing similar manifestations such as increased frequency of urination but in little quantity, stranguria, malodorous urine and blood-tinged urine (6 dogs). Dysuria, oliguria, urinary incontinence and anuria (2 dogs) were additional signs recorded among cystic calculi patients. Whereas, hematuria with dysuria and stranguria were the significant signs among dogs with prostate infection and transitional cell carcinoma (TCC). Mukherjee *et al.* (2014) reported lower prevalence rate of lower urinary tract infections (LUTI) comprising high prevalence of urolithiasis followed by cystitis. Jeong-Seong Mok (2002) stated urinary calculi occurred more often in males than females and stated that canine urolithiasis can occur from one year until 12 years but the most prevalent age was 3 years. Hesse, (1990) reported incidence of urolithiasis in first year of life and its increase up to six years of age than decline from age of eight years in dogs. Urolithiasis and transitional cell carcinoma (TCC) of urinary bladder were found to be the common surgical affections of lower urinary tract and cystitis was found to be the nonsurgical affection in dogs (Sarma and Dutta, 2014). The male dogs between age group of 7 to 9 years were found to be more vulnerable for lower urinary tract affections (Parmar *et al*., 2020). Clinical signs of lower urinary tract disease in dogs are characteristic but non-specific for infection. Bacterial cystitis was defined as significant bacteriuria on quantitative bacterial culture in dogs with compatible clinical signs of urinary tract disease (Sorensen *et al*., 2019). Regardless of underlying cause, LUTD is characterized by dysuria, pollakiuria, stranguria, hematuria and periuria (urination in inappropriate places). Diagnostic evaluation of dogs with recurrent or persistent lower urinary tract signs should include a urinalysis, culture and diagnostic imaging, hematology and serum chemistry (Sorensen *et al*., 2019). If the urolith is removed, urolith analysis is imperative to proper management of the patient (Sarma and Dutta, 2014).

Urinalysis is an important element of evaluating patients with signs of lower urinary tract disease. The use of voided urine specimens for bacteriological culture in dogs is discouraged because contamination from external genitalia could lead to misinterpretation of laboratory results (Sorensen *et al*., 2016 and Srikanth *et al*., 2017). Cloudy, turbid urine, that was dark yellow to blood tinged were the physical features of the urine sample. Microscopically epithelial cells, pus cells, RBCs, WBCs along with moderate (15 per hpf) to many (22 per hpf) crystals of various types, few coccobacilli, casts and debris along with occasional spermatozoa were common findings. Squamous epithelial cells, though normally seen in less numbers, increased number of transitional epithelial cells may present in the urine sediment with infection, mechanical trauma (urolithiasis) or neoplasia of the urinary tract (Chew *et al*., 2011). Various cellular components observed in the present study are in accordance with (Carolyn and Nicole, 2012). Microbial culture of sterile urine samples revealed *E.coli, Staphylococcus, Pseudomonas* and mixed infection bacterial colonies when cultured on specific media. Further, ABST revealed maximum sensitivity towards enrofloxacin followed by amoxicillin, ceftriaxone and amikacin, respectively. Presence of blood cells and epithelial cells in the urine samples might be due to inflammation of urinary tract and the presence of a greater number of these cells may suggest bacterial urinary tract infection (Rajan, 2007; Burgess and DeRegis, 2019). Bacterial urinary tract infections (UTIs) have been associated with urogenital disease such as cystitis, nephritis, metritis and prostatitis in dogs (Wooley and Blue, 1976; Burgess and DeRegis, 2019). The findings of the present study are in agreement with (Westropp *et al*., 2012. Srikanth *et al*., 2017) who reported that *E. coli, Proteus, Staphylococci, Streptococci, Enterococus, Pseudomonas* were the common pathogens associated with urinary tract infections in senior dogs. Whereas, Ulrika *et al.* (2014) reported that the *Escherichia coli* was the most frequently isolated pathogen (68%) followed by *Staphylococci* (11%) in most of the canine urinary tract infections. *Staphylococcus aureus* and *Proteus mirabilis* were also found to be among the most common infecting bacteria in UTI cases in dogs (Gatoria *et al*., 2006, Byron, 2019). Female dogs are more often affected than male dogs and majority of canine UTIs are caused by a single bacterial species and *E. coli* is singularly most prevalent in canine UTIs (Ling *et al*., 2001).

Among the various crystals, triple phosphate or struvite were more predominant, followed by calcium oxalate dihydrate, calcium oxalate monohydrate and ammonium urate or biurate. The triple phosphate or struvite crystals were colourless, three to six sided prisms with oblique ends “coffin-lid”. Calcium oxalate dihydrate crystals appeared as colourless squares whose corners were

connected by intersecting lines with characteristic shape of octahedron or envelope (Fig 1) and whereas, calcium oxalate monohydrate crystal varied in size with two dimensional spindle, oval and various forms like “picket fence” and “dumbbell” and “hemp seed” shape (Fig 2). The most common site of predilection of calculi were urinary bladder/urethra in males and only urinary bladder in females. The major mineral component of calculi in urinary bladder was struvite followed by urate and that in urethra and multiple locations was calcium oxalate (Fig 3 and 4). Urinary calculi are a result of the crystalisation from inorganic and organic components of urine. In spite of the fact that they are normally present, the process of their diagnostics is still not fully established (Ryall, 2011). Urolithiasis in the present study was evaluated in dogs beyond 8 years and was more common in lower urinary tract (Gleaton *et al*., 2001) of males. Over saturation of urine with calcium oxalate leads to precipitation of crystals and formation of urinary calculi, inspite of certain inhibitors like magnesium that can withhold the process of super saturation (Kumar and Srikanth, 2021). However, this process of initiation of calculi formation can be ascribed to the presence of citric acid and some ions (Ryall, 2011). Super saturation is followed by formation of a solid crystal phase (nucleation) that permit further deposition and aggregation of crystals (Finlayson and Reid, 1978). Proteins, lytic enzymes and other organic matrix present in normal urine also cause dissolution and degradation of the urinary crystals, which gives irregular shapes of calcium oxide monohydrate and dehydrate crystals and decrease crystals chance for deposition on the renal tissue, for instance osteopontin is incriminated in crystals erosion and the appearance of cracked surfaces (Thurgood *et al*., 2010). Further, other substances secreted by the kidneys like undifferentiated proteins and glycosaminoglycans inhibit retention of crystals and nucleation by reducing the ability of attachment of calcium oxide monohydrate to renal epithelial cell membranes (Grover *et al*., 2010). Various types of crystals identified during microscopic examination of urine were formed by precipitation of solutes, specifically inorganic salts, organic compounds or iatrogenic compounds. Crystals are more likely to form in concentrated urine



Fig 1: Various types of crystals identified in the geriatric dog urine- struvite crystals (*coffin lid), c*alcium oxalate dihydrate (*envelope).*



Fig 3: A big struvite of 4 × 6 cm retrieved from urinary bladder of a geriatric dog.

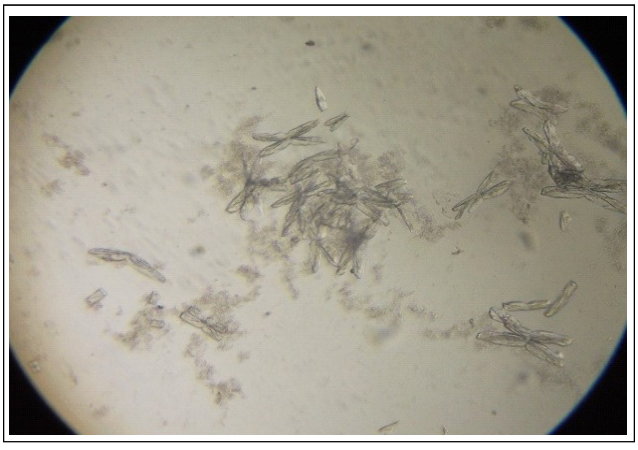

Fig 2: Calcium oxalate monohydrate crystal with typical hemp seed shape.



Fig 4: A urate calculi of 1.5 cm retrieved from bladder of geriatric dogs with LUTD.

samples. Canine lower urinary tract disease (LUTD) signs are seen in 2 to 3% of dogs per year, with urinary tract infections and uroliths being the most common (Bartges and Kirk, 2012). Among the various uroliths, struvites (magnesium, ammonium, phosphate) and calcium oxalates make up 90+% of uroliths seen in dogs (Bartges and Kirk, 2012).

Selected cases of LUT diseases that were presented with urinary incontinence or anuria when subjected for radiography, revealed extremely distended urinary bladder, few with soft tissue radio density or radiopaque structures within the bladder and or urethra. While abdomen ultrasonography revealed fully distended bladder with hyperechoeic crystals floating in anechoeic media (urine), thickened urinary bladder wall with uneven margins and with hyperechoeic layers (Fig 5) and hyperechoeic bladder contents suggesting cellular debris and sludge (Fig 6) different size and shaped hyperechoeic structures with anechoeic shadow with in the bladder lumen and in few hyperechoeic crystals were also detected in the urethra (Fig 7 and 8). In few dogs that were presented with hematuria also revealed mixed soft tissue echogenic structures with irregular borders within the bladder lumen (Fig 9) that were confirmed as transitional cell tumour. Ultrasonographic examination of lower abdomen among 8 patients revealed distended, irregularly shaped prostate gland with multiple heterogenous, anechoeic foci and hyperechoeic or mixed echogenic texture (Fig 10). Multiple anechoeic foci present in the gland parenchyma suggests cysts and whereas, presence of irregular fluid filled anechoeic spaces is indicative of abscess, later confirmed by fine needle aspiration. Presence of hypoechoeic peripheral prostatic tissue with parenchymal heterogenicity might be suggestive of benign prostatic hyperplasia. Ultrasound guided fine needle aspiration was done using a sterile syringe and the sample from 5 cases revealed *E. coli* and *Pseudomonas spp* on culture.

The second most commonly diagnosed LUT tumour in senior dogs is prostatic carcinoma. The median age at diagnosis is 10 years and it occurs more commonly in

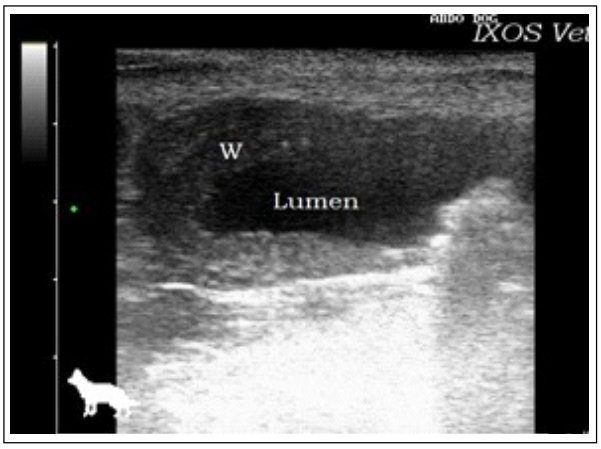

Fig 5: B mode ultrasonogram showing hyperechoeic thick urinary bladder wall (w) with abnormal contour.

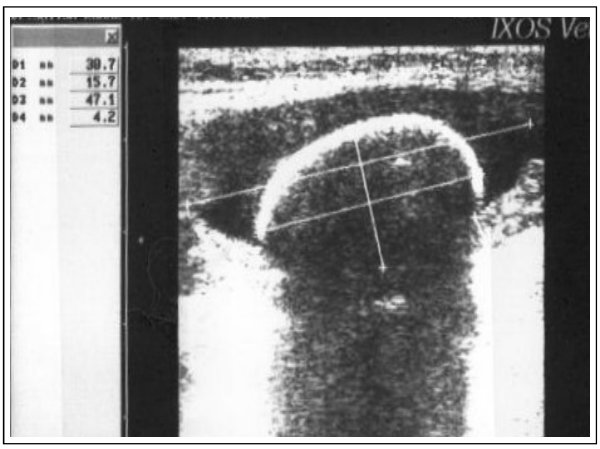

Fig 7: Ultrasonographic image of urinary bladder showing huge hyperecoeic calculi with anechoeic shadow and thick bladder wall.

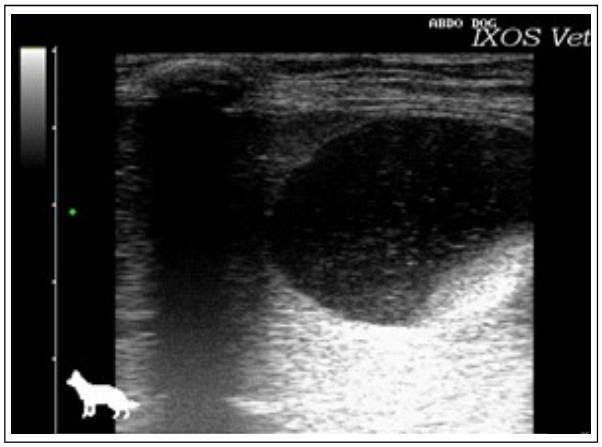

Fig 6: B mode ultrasonogram depicting full bladder with anechoeic media (urine) mixed with hyperechoeic crystals and sludge.

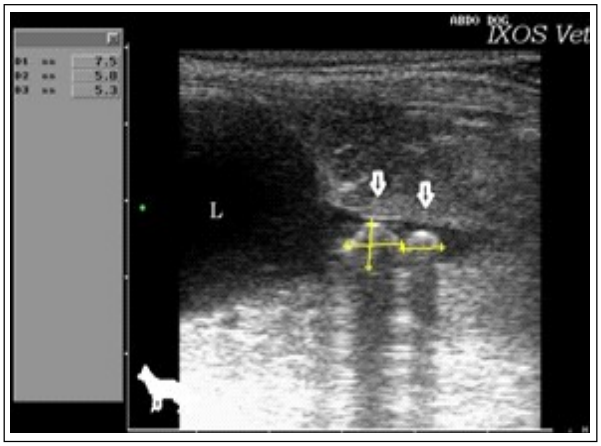

Fig 8: Ultrasonographic image of bladder with two hyperechoeic calculi (arrow) with anechoeic shadow lodged in the neck of the bladder.

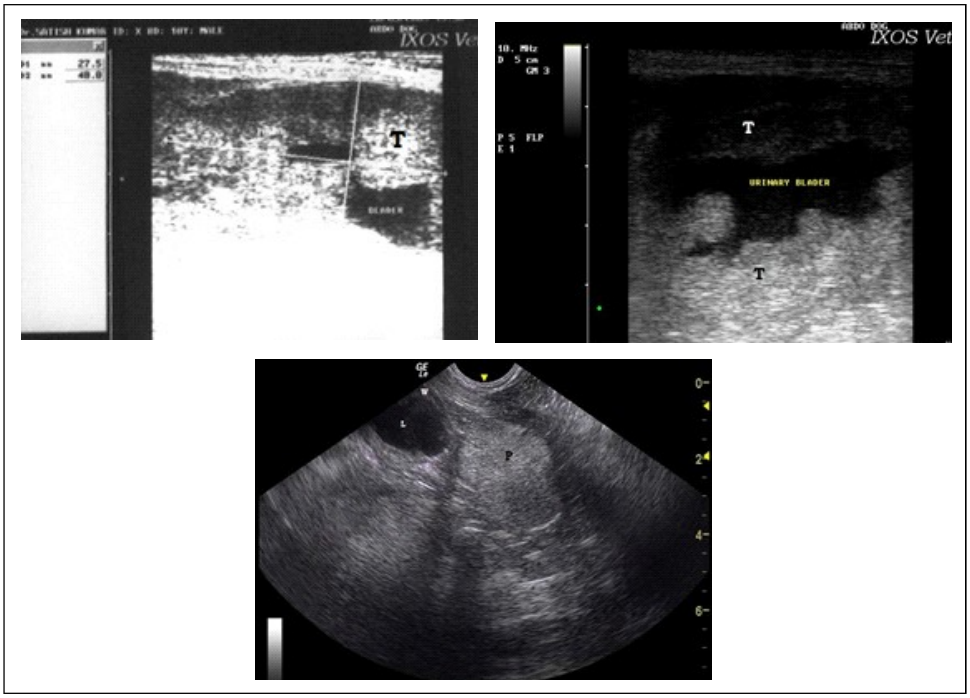

Fig 9: B mode ultrasonographic images whowing isoechoeic soft tissue like growith extended into and occupying almost entire bladder (T) - *transitional cell carcinoma.*

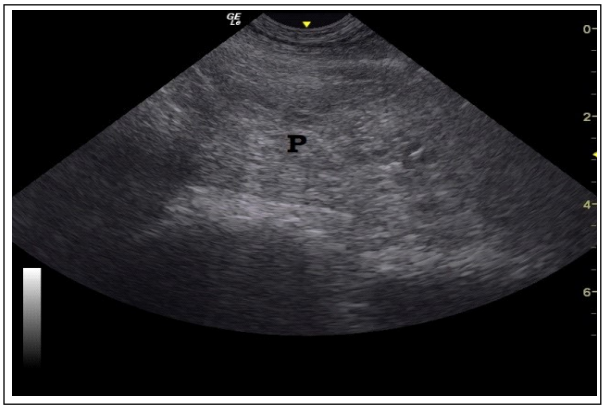

Fig 10: Ultrasonographic images showing (left) enlarged hyperechoeic pro.state gland (P) and thickened bladder wall (W); (right) extensively enlarged prostate gland (P) with anechoeic spaces of varied size.

neutered males compared to intact males (Bradbury *et al.* 2009. Withrow and Vail. 2007). Tumours of the bladder and urethra account for 0.5-1.0% of canine neoplasia. The majority of these tumours are transitional cell carcinoma (TCC). The median age at diagnosis for TCC is 12 years. The bladder tumour antigen test and more recently BRAF testing, can be helpful screening tools for TCC, but definitive diagnosis through a combination of imaging, cytology and cystoscopy is recommended (Burgess and DeRegis, 2019; Withrow and Vail, 2007).

Prostate diseases are most commonly noticed in dogs over 8 years primarily in intact males, but neutered dogs may also have prostatic tumours and infections (Wilson, 2011 and Bradbury *et al*., 2009). Prostatic diseases such as, prostatic hyperplasia, cyst, abscess and neoplasia account for 10% of intact male dogs (Levy *et al*., 2014) and may lead to different clinical manifestations ranging from infertility to septicaemia (Smith, 2008). The clinical signs of prostatic diseases usually depend on type and severity, though prostatic abscesses usually arise as the immune system attempts to isolate, or wall off, an area of infection and from chronic infections of the prostate gland, mostly by *E. coli* (Satish, 2020). The abscess can be single or multiple and can be small or very large, wherein, a large abscess probably develop from paraprostatic cysts and may become large enough to put pressure on other internal organs. When the enlargement of abscess reaches to a point where putting pressure on the colon and decreasing its functional diameter, affected dog will strain while defecating resulting in tenesmus and formation of ribbon-like appearance to the stools (Johnston *et al*., 2001). On the other hand, there will be dysuria or stranguria, if the enlarged abscess places pressure on the urethra (Levy *et al*., 2014 and Bradbury *et al*., 2009). Intermittent preputial bloody discharge without urination and haematuria mostly towards the end of urination are the common signs of associated urinary system abnormalities (Maurey, 2007). The cysts and abscess are common in an enlarged prostate, wherein, prostatic abscess is rare and is often a complication of an infected cyst or severe prostatitis. Bacterial prostatitis represents only one third of prostatitis (Levy *et al*., 2006).

CONCLUSION

In the present study the manifestations associated with LUTD are common and are the primary signs of an ageing dog, which are usually ignored by the client or pet owner. Diagnosis and treatment of the same is a big challenge for a vet as they did not specify any underlying LUTD along with comorbidities among geriatric patients. The approach to these cases requires not only diagnosis and treatment of the primary cause of the LUT signs, but also attention to the underlying diseases that may have predisposed the patient.

Conflict of interest

All authors declare that they have no conflict of interest.

REFERENCES

Bartges, J. and Kirk, C. (2012). Nutritional Management of Lower Urinary Tract Disease. In: Applied Veterinary Clinical Nutrition, [Fascetti. A.J. and Delaney, S.J. (eds.)], Wiley-Blackwell, West Sussex, UK. 269-272.

Bradbury, C.A., Westropp, J.L. and Pollard, R.E. (2009). Relationship between prostatomegaly, prostatic mineralization and cytologic diagnosis. Veterinary Radiology and Ultrasound. 50: 167-171.

Burgess, K.E. and DeRegis, C.J. (2019). Urologic oncology. Veterinary Clinics of Small Animal. 49: 311-323.

Byron, J.K. (2019) Urinary tract infection. Veterinary Clinics of Small Animal. 49: 211-221.

Carolyn, A.S. and Nicole, M.W. (2012). Routine Urinalysis. In: Text Book of Veterinary Urine Analysis. Wiley Blackwell Publishers edited by John Willy and Sons, Inc. pp. 82-120.

Chew, D.J., DiBartola, S.P. and Schenck, P.A. (2011). Canine and Feline Nephrology and Urology, Second Edition, Elsevier Saunders, St. Louis MO. 272-305.

Davies, M. (1996). Canine and Feline Geriatrics. Blackwell Scientific Publications, Library of Veterinary Practice, Oxford. pp. 87-102.

Finlayson, B. and Reid, F. (1978). The expectation of free and fixed particlesin urinary stone disease. Investigations in Urology. 15: 442-448.

Gatoria, I.S., Saini, N.S. and Rai, T.S. (2006). Comparison of three techniques for the diagnosis of urinary tract infections in dogs with urolithiasis. Journal of Small Animal Practice. 47: 727-732.

Gleaton, H.K., Bartges, J.W. and Laflamme, D.P. (2001). Influence of diet on urinary pH, urine and serum biochemical variables and blood-ionized calcium concentrations in healthy dogs. Veterinary Therapeutic Journal. 2: 61-69.

Grover, P.K., Thurgood, L.A., Wang, T. and Ryall, R.L. (2010). The effects of intracrystalline and surface-bound proteins on the attachment of calcium oxalate monohydrate crystals to renal cells in undiluted human urine. British Journal of Urology International. 105: 708-715.

Hesse, A. (1990). Canine urolithiasis: Epidemiology and analysis of urinary calculi. Journal of Small Animal Practice. 31: 599-604.

Jeong-Seong, M. (2002). Urolithiasis in dogs: Comparison of breed, gender, anatomic location, urinalysis and mineral composition of calculus (30) cases. Journal of Veterinary Clinics. 19(2): 272-275.

Johnston, S.D., Root, K.M.V. and Olson, P.N.S. (2001). Canine and Feline Theriogenology. WB Saunders Company, Philadelphia. 355.

Kesson, A.M., Talbott, J.M. and Gyory, A.Z. (1978). Microscopic examination of urine. The Lancet. pp. 809-812.

Kumar, K.S. and Srikanth, K. (2021). Scanning electron microscopic structure and composition of urinary calculi of geriatric dogs. International Journal of Veterinary Science and Animal Husbandry. 7(1): 081-087.

Kurien, B.T., Nancy, E., Everds, E. and Scofield, R.H. (2004). Experimental animal urine collection: A review. Laboratory Animals. 38: 68-75.

Levy, X., Maurey, C., Fontaine, E. and Fontbonne, A. (2006). Comparative Evaluation of Five Different Techniques to Diagnose Prostatic Infection in the Dog. In: Proceeding of the 5th EVSSAR Meeting. 319-328.

Levy, X., Nizanski, W., Heimendahl, A.V. and Mimouni, P. (2014). Diagnosis of common prostatic conditions in dogs an update. Reproduction of Domestic Animals. (49): 50-57.

Ling, G.V., Norris, C.R., Franti, C.E., Eisele, P.H., Johnson, D.L. and Ruby, A.L. (2001). Interrelations of organism prevalence, specimen collection method and host age, sex and breed among 8, 354 canine urinary tract infections (1969-1995). Journal of Veterinary Internal Medicine. 15: 341-347.

Maurey-Guenec, C. (2007). Approche cliniquedes affections prostatiques. Pratique Veterinary Compendium Animal. 38: 7-8.

Mukherjee, P., Chakrabarti, A., Har, T., Batabyal, K. and Das, B. (2014). Study of haematological profiles of dogs infected with pathogenic aerobes. Exploratory Animal and Medical Research. 4(1): 81-85.

Parmar, J.J., Parikh, P.V., Shah, A.I. and Dabhi, P.B. (2020). Retrospective analysis of lower urinary tract disorders in dogs, study of five years. Indian Journal of Animal Research. 55(8): 941-945. doi: 10.18805/ijar.B-4146.

Rajan, R., Chand, N. and Dhaliwal (2007). Diagnosis and the rapeutic management of urinary tract infections in dogs. Indian Veterinary Journal. 84: 507-508.

Ryall, R.L. (2011). The Possible Roles of Inhibitors, Promoters and Macromolecules in the Formation of Calcium Kidney Stones. In: Urinary Tract Stone Disease. 4th ed. London: Springer. p. 31.

Sarma, B.K. and Dutta, B. (2014). Urinary system disorders in canine among the clinical cases. Indian Journal of Veterinary Research. 23(2): 25-27.

Satish, K.K. (2020) Diagnosis of prostate gland diseases in dogs. Journal of Entomology and Zoology Studies. 8(4): 682-684.

Smith, J. (2008). Canine prostatic disease: Are view of anatomy, pathology, diagnosis and treatment. Theriogenology. 70: 375-383.

Sorensen, T.M., Holmslykke, M., Nordlund, M., Siersma, V., Jessen, LR. (2019). Pre-test probability of urinary tract infection in dogs with clinical signs of lower urinary tract disease. Veterinary Journal. 247: 65-70.

Sorensen, T.M., Jensen, A.B., Damborg, P., Bjornvad, C.R., Guardabassi, L., Jessen, L.R. (2016). Evaluation of different sampling methods and criteria for diagnosing canine urinary tract infection by quantitative bacterial culture. Veterinary Journal. 216: 168-73.

Srikanth, K., Satish, K.K. and Nagaraj, P. (2017). Cultural studies of urine from cystitis dogs. The Pharma Innovation Journal. 6(8): 247-250.

Thurgood, L.A., Cook, A.F., Sorensen, E.S. and Ryall, R.L. (2010). Face-specificincorporation of osteopontin into urinary and inorganic calciumoxalate monohydrate and dihydrate crystals. Urology Research. 38: 357-376.

Ulrika, W., Bodil, S.H., Ann, N., Ulrika, G. and Björn, B. (2014). Characterisation of bacterial growth and antimicrobial susceptibility patterns in canine urinary tract infections. British Medical Council Veterinary Research. 2: 53-62.

Westropp, J.L., Sykes, J.E., Irom, S., Daniels, J.B., Smith, A. and Keil, D. (2012) Evaluation of the efficacy and safety of high dose short duration enrofloxacin treatment regimen for uncomplicated urinary tract Infections in dogs. Journal of Veterinary Internal Medicine. 26: 506-512.

Wilson, J.D. (2011). The critical role of androgensin prostate development. Endocrinology Metabolism Clinics of North America. 40: 577-590.

Withrow, S.J. and Vail, D.M. (2007). Small Animal Clinical Oncology. 4th ed. St. Louis MO: Saunders Elsevier. pp 223-275.

Wooley, R.E. and Blue, J.L. (1976). Bacterial isolations from canine and feline urine. Modern Veterinary Practice. 57: 535-538.