RESEARCH ARTICLE Indian Journal of Animal Research, Volume 59 Issue 5: 859-863 (May 2025)

Importance of Right Pulmonary Artery Distensibility Index in the Diagnosis and Management of Pulmonary Arterial Hypertension Secondary to Canine Dilated Cardiomyopathy

K. Basava Reddy[1], C. Ansar Kamran[1], P.T. Ramesh[1], H.A. Upendra[1], Suguna Rao[2], V. Mahesh[3]

10.18805/IJAR.B-4766

ABSTRACT

Background: The measurement of tricuspid regurgitant velocity is the commonly used non-invasive method for the diagnosis of pulmonary hypertension in dogs. It is anticipated that M-mode echocardiographic measurement of right pulmonary artery distensibility (RPAD) index is simple and provides accurate means for the diagnosis of pulmonary arterial hypertension when tricuspid regurgitant velocity is absent. Hence this study was undertaken to evaluate the importance of RPAD index in the diagnosis and management of pulmonary arterial hypertension secondary to dilated cardiomyopathy.

Methods: In the present study, a total of 165 dogs were subjected to echocardiography for diagnosis of pulmonary hypertension secondary to dilated cardiomyopathy. The maximum and minimum internal diameter of the right pulmonary artery during systole and diastole were quantified respectively to determine the right pulmonary artery distensibility (RPAD) index in right parasternal short axis M-mode echocardiogram. The M-mode morphology of right pulmonary artery (anterior dicrotic notch) also recorded.

Result: Out of 165 dogs ten dogs had pulmonary arterial hypertension with dilated cardiomyopathy. Dogs with pulmonary hypertension showed a significant decrease in the mean right pulmonary artery distensibility index values and Acceleration time/Ejection time (AT/ET) ratio, while the mean tricuspid regurgitant systolic pressure gradient (TRPG) were significantly elevated when compared to the respective control group. The significant difference was observed in the mean values of tricuspid regurgitant systolic pressure gradient and RPAD index before and after the treatment.

Key words: Dilated Cardiomyopathy, Dogs, Pimobendan, Pulmonary hypertension, RPAD index.

INTRODUCTION

Pulmonary hypertension (PH) is most commonly diagnosed in its advanced stage only due to its nonspecific clinical signs exhibited in dogs. It is classified as primary and secondary; primary PH being idiopathic and uncommon in dogs. The secondary PH develops in dogs with chronic bronchitis, congenital cardiac shunts, degenerative mitral valve disease and left sided congestive heart failure (Chetboul, 2015). The dogs with PH may exhibit clinical signs like exercise intolerance, cough, dyspnea, inappetence, ascites and syncope (Kellihan and Stepien, 2010). Right heart catheterization (invasive method) is the gold standard test for measurement of pulmonary arterial pressure in dogs and human beings. The echocardiographic measurement of systolic pulmonary arterial pressure is the commonly used non-invasive method in dogs for diagnosis of PH. While in the absence of tricuspid regurgitation (TR) jet or pulmonic regurgitant flow, the diagnosis mainly relies on clinical signs, thoracic radiography and pulsed-wave Doppler derived indirect methods such as acceleration time (AT), Acceleration time/Ejection time (AT/ET), notching at deceleration phase of pulmonic flow, right ventricular Tie index and main pulmonary artery/ ascending aorta (MPa/Ao) ratio (Venco *et al.,* 2014). In the absence of any one of the above indirect parameters due to technical limitations, the diagnosis would be inconclusive. However, the measurement of right pulmonary artery distensibility (RPAD) index provide useful complementary information especially when tricuspid regurgitation (TR) jet is absent or inconsistent (Visser *et al*., 2016). The phosphodiesterase

[1]Department of Veterinary Medicine, Veterinary College, Hebbal, Karnataka Veterinary, Animal and Fisheries Sciences University, Bengaluru-560 024, Karnataka, India.

[2]Department of Veterinary Pathology, Veterinary College, Karnataka Veterinary, Animal and Fisheries Sciences University, Bengaluru-560 024, Karnataka, India.

[3]Department of Veterinary Surgery and Radiology, Veterinary College, Karnataka Veterinary, Animal and Fisheries Sciences University, Bengaluru-560 024, Karnataka, India.

Corresponding Author: K. Basava Reddy, Department of Veterinary Medicine, Veterinary College, Hebbal, Karnataka Veterinary, Animal and Fisheries Sciences University, Bengaluru-560 024, Karnataka, India. Email: drbasava2k10@gmail.com

How to cite this article: Basava Reddy, K., Ansar Kamran, C., Ramesh, P.T., Upendra, H.A., Rao, S. and Mahesh, V. (2025). Importance of Right Pulmonary Artery Distensibility Index in the Diagnosis and Management of Pulmonary Arterial Hypertension Secondary to Canine Dilated Cardiomyopathy. Indian Journal of Animal Research. 59(5): 859-863. doi: 10.18805/IJAR.B-4766.

Submitted: 02-09-2021 **Accepted:** 02-03-2022 **Online:** 23-04-2022

3 inhibitors like Pimobendan may provide added benefit to cardiac failure dogs with PH as it enhances adrenergic relaxation in the pulmonary arteries and also produce calcium sensitization effect in myocardium (Stepien, 2009). It is anticipated that M-mode echocardiographic measurement of right pulmonary artery distensibility (RPAD) index is simple and provides accurate means for the diagnosis of pulmonary arterial hypertension when TR is absent in dogs. Hence this study was undertaken to evaluate the importance of right pulmonary artery distensibility index in the diagnosis and management of pulmonary arterial hypertension secondary to dilated cardiomyopathy in dogs.

MATERIALS AND METHODS

The study was carried out among the dogs (n= 165) presented to the Department of Veterinary Medicine, Veterinary College, Hebbal, Bangalore from December 2019 to July 2021 with clinical signs suggestive of cardiac insufficiency were screened for the Dilated Cardiomyopathy (DCM) with pulmonary hypertension using the specially designed cardiology data sheet. Dogs with clinical signs like dyspnea, cough, exercise intolerance, cardiac cachexia, ascites, limb oedema and murmur on auscultation were screened for the study. A total of ten apparently healthy dogs brought for routine checkup and vaccination were randomly selected to collect reference values of the parameters under study. They were subjected to detailed clinical examination, physical examination and special examination including electrocardiography, radiography and echocardiography. The ECG was recorded in right lateral recumbency as per the standard bipolar limb lead system described by Tilley and Smith (2008) using GE Healthcare-MAC-400 portable ECG machine. Standard transthoracic echocardiography was performed using Esoate Mylab eight Vet ultrasound system with 1 MHz to 5 MHz transducer depending on the size of the animal. Furthermore, dogs were subjected to two dimensional, M mode, colour flow doppler, pulse wave and continuous wave doppler echocardiography as described by Boon (2011) to diagnose the DCM with pulmonary hypertension. None of the animals were given sedation or tranquilization while performing echocardiography. The dogs that had fractional shortening below twenty five per cent, ejection fraction below fifty per cent with left atrial enlargement and the peak tricuspid regurgitation (TR) velocity greater than 2.8 m/s with absence of pulmonic stenosis were selected for the study. The apical four chamber view was obtained for each dog to optimize the alignment of the tricuspid regurgitant jet and the doppler cursor. The modified Bernoulli equation was applied to calculate the right ventricle-to-right atrium systolic pressure gradient across the tricuspid valve. The maximum and minimum internal diameter of the right pulmonary artery during systole and diastole were quantified respectively to determine the right pulmonary artery distensibility (RPAD) index in right parasternal short axis M-mode echocardiogram as per standard techniques described by Venco *et al.* (2014). Other indirect echocardiographic parameters included were main pulmonary artery and ascending aorta ratio (MPa/Ao), Systolic time intervals such as acceleration time and acceleration time/ejection time (AT/ET). The M-mode morphology of right pulmonary artery (anterior dicrotic notch) artery also recorded.

The normal reference range for the RPAD index was obtained from control group (apparently healthy dogs) and used for comparison of the RPAD index values obtained from dogs with pulmonary hypertension secondary to DCM. The DCM dogs with pulmonary hypertension were treated with tab: Pimobendan @ 0.25 mg/ kg b.wt, bid, PO, tab: Enalapril @ 0.5 mg/ kg b.wt, bid, PO and tab: Furosemide @ 2 mg/ kg b.wt, bid, PO for a period of four weeks. Clinical signs, electrocardiography and echocardiography were recorded before and after the treatment. In the present study, two sample t-test and paired t-test were done to compare the means values of the parameters obtained from the control (apparently healthy) dogs and the dogs with pulmonary hypertension before and after treatment respectively. Anterior dicrotic notch of the right pulmonary artery was tested and percentage analysis was calculated.

RESULTS AND DISCUSSION

In dogs, measurement of pulmonary arterial pressure using doppler echocardiography is a non invasive procedure and can be used for monitoring the disease progress (Boon, 2011). The left sided cardiac diseases were one of the common causes of pulmonary hypertension in dogs and various causes included mitral valve disease, myocardial diseases or any left side of heart disease (Johnson *et al.,* 1999). In the present study, among 165 dogs screened for cardiac disorders, 61 dogs (36.96%) were diagnosed with DCM out of which, ten (16.39%) dogs had pulmonary arterial hypertension. On the day of presentation, the predominant clinical findings noticed in dogs with both the DCM and pulmonary hypertension were murmur, tachycardia, polypnea, orthopnea, arrhythmia, exercise intolerance, lethargy, ascites, dyspnea, coughing, cardiac cachexia and limb oedema (pitting). The clinical signs may be similar to signs of left-sided Congestive Heart Failure (CHF) (Stepien, 2009) or some dogs might be asymptomatic (Kellihan and Stepien, 2010). Bonagura and Twedt (2014) reported that the most common presenting signs in dogs with dilated cardiomyopathy were dyspnea, cough, exercise intolerance, weakness, inappetance, collapse, panting, syncope, gallop sound and lethargy. The clinical findings in the present study were in agreement with Stepien (2009) and Bonagura and Twedt (2014). In the present study, the predominant electrocardiographic findings noticed were atrial fibrillation, right axis deviation, ventricular premature complex, P mitrale and decreased 'R' wave amplitude. These electrocardiographic findings might also represent the underlying disease process (DCM). Out of ten dogs with PH secondary to DCM, two dogs (20%) had septal flattening, four dogs (40%) had absence of anterior dicrotic notch at right pulmonary artery

Table 1: Two sample t-test showing the mean±S.E of control group and dogs with pulmonary hypertension before treatment and Paired t-test showing the mean±S.E of animals before and after the treatment.

Parameter	Control (Apparently healthy dogs) (n=10)	Dogs with secondary PH before treatment (n=10)	Dogs with secondary PH after treatment (n=10)
Tricuspid regurgitant pressure gradient (TRPG in mmHg)	12.004±1.572^{B}	36.186±0.856^{Aa}	29.613±1.279^{b}
Ratio of acceleration time to ejection time (AT/ET)	0.474±0.018^{A}	0.384±0.029^{Ba}	0.392±0.020^{a}
Ratio of main pulmonary artery to aorta (MPa/Ao)	1.062±0.035^{B}	1.356±0.085^{Aa}	1.285±0.069^{b}
Right pulmonary artery distensibility (RPAD) index (%)	36.552±1.576^{A}	30.95±2.518^{Bb}	34.886±2.093^{a}
Anterior dicrotic notch (% of positives)	100	60	60
Anterior dicrotic notch (% of negatives)	0	40	40

Note: Differences in the superscripts (upper case letters) across rows indicates significant difference (P≤0.01) between control and dogs with PH before the treatment and differences in the superscripts (small case letters) across rows indicates significant difference (P≤0.01) between dogs with PH before and after the treatment.

and seven dogs (70%) had enlargement of the main pulmonary artery in two dimensional echocardiography. Septal flattening could be noticed in patients with pulmonary hypertension if the right ventricle pressure exceeds the left ventricular pressure (Kellihan and Stepien, 2010). The mean values of echocardiographic parameters such as the peak tricuspid regurgitant systolic pressure gradient (TRPG), AT/ET, MPa/Ao and right pulmonary artery distensibility index (RPAD index) in apparently healthy dogs and dogs with pulmonary hypertension secondary to dilated cardiomyopathy were presented in Table 1. In the present study, the mean of MPa/Ao ratio was significantly higher (P≤0.01) in dogs with pulmonary hypertension (1.356±0.085) in comparison to apparently healthy dogs (1.062±0.035). The pulse wave doppler echocardiographic parameters AT/ET, MPa/Ao in apparently healthy animals were 0.42±0.01 and 1.01±0.03 respectively (Boon, 2011). In the present study, dogs with secondary pulmonary hypertension had significant decrease in mean values of AT/ET ratio when compared to the apparently healthy dogs (Fig 4). In the current study, dogs with pulmonary hypertension had significantly elevated mean TRPG values when compared to the apparently healthy dogs (Fig 3). Doppler tricuspid regurgitant systolic pressure gradient can be used as standard non invasive technique for diagnosis of pulmonary hypertension in dogs (Yamini *et al*., 2020). Visser *et al.* (2016) reported that a cut off value of >0.98, <0.38 and <34.6% for MPa/Ao, AT/ET and RPAD index respectively has been predictive of peak TRPG of >36 mm Hg in dogs. A significant lower RPAD index values were observed for the dogs with pulmonary hypertension before (30.95±2.518) and after (34.886±2.093) treatment when compared to apparently healthy dogs (36.552±1.576) and the difference in the means between groups was highly significant.

In all apparently healthy dogs, the M-mode morphology of right pulmonary artery showed an anterior dicrotic notch (Fig 1) whereas four (40%) dogs with pulmonary hypertension had absence of anterior dicrotic notch (Table 1 and Fig 2). Venco *et al*. (2014) reported that in some of the dogs with pulmonary hypertension, M-mode morphology of right

Table 2: Correlation between RPADI with AT /ET, MPa/Ao and TRPG.

	RPADI	AT/ET	MPa/Ao	TRPG
RPADI	1.0	0.685*	-0.109	-0.565
AT/ET	0.685*	1.0	0.188	-0.620
MPa/Ao	-0.109	0.188	1.0	0.284
TRPG	-0.565	-0.620	0.284	1.0

(Note: *indicates P≤0.05).

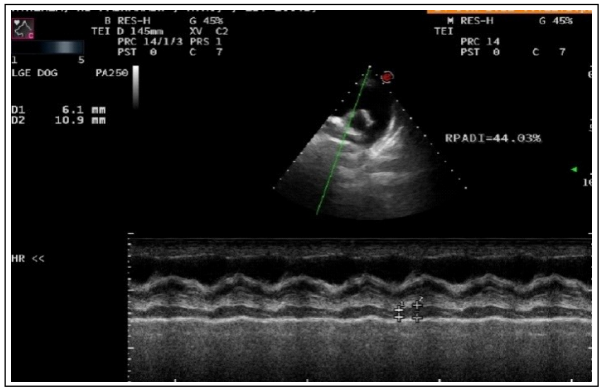

Fig 1: M-mode echocardiographic image of right pulmonary artery of the apparently healthy dog showing the RPAD index as 44.03 per cent and the presence of anterior dicrotic notch of the right pulmonary artery.

pulmonary artery showed an anterior dicrotic notch and seems to disappear as the systolic pressure increases. Correlation between RPADI with AT/ET, MPa/Ao and TRPG were presented in Table 2. In the present study, there was a significant positive correlation between RPAD index with AT/ET while the correlation between RPAD index with MPa/Ao and TRPG was negative. The values of the RPAD index was correlated with the TRPG and can be used for evaluating the PH in the absence of measurable tricuspid regurgitation or pulmonic regurgitation and help to predict the prognosis (Chan *et al*., 2019). The aim of the therapy was to ameliorate clinical signs, improve exercise intolerance, decrease the pulmonary artery pressure, decrease the right ventricle

workload, improve patient longevity and quality of life. In the present study, all the dogs with pulmonary hypertension secondary to DCM showed improvement with respect to exercise intolerance, cough, dyspnea and polypnea following treatment with pimobendan, enalapril and furosemide. In echocardiography, there was a significant difference in the mean values of TRPG and RPAD index values before and after the treatment. But there was no significant difference in AT/ET values between animals before treatment and after treatment. The dual action of pimobendan (PDE-3 inhibition and positive inotropic effect) provided benefit to the dogs with PH secondary to left-sided heart disease (Kellihan and Stepien, 2010). The calcium sensitizing action of pimobendan improved the left and right ventricular myocardial function, which might result in decreased left and right atrial pressure, ultimately improving left and right sided congestive heart failure.

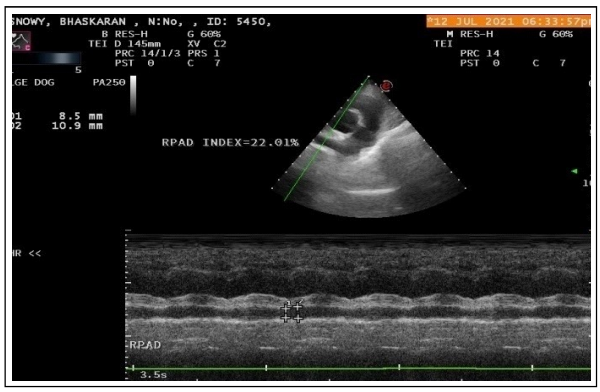

Fig 2: M-mode echocardiographic image of right pulmonary artery in dog with pulmonary hypertension showing the RPAD index as 11.82 per cent and the absence of anterior dicrotic notch of the right pulmonary artery.

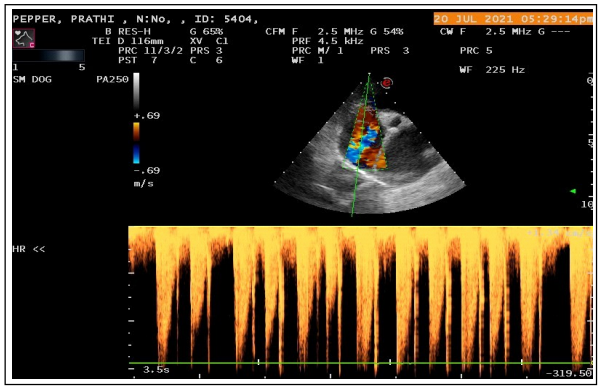

Fig 3: Continuous wave and Color flow doppler at apical four chamber view in a dog with pulmonary hypertension showing TRPG as 40.70 mm HG.

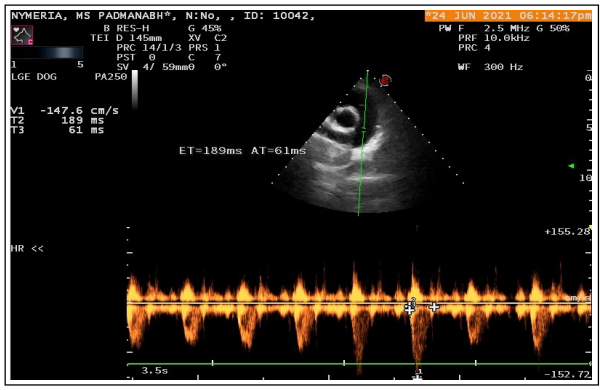

Fig 4: Pulsed wave doppler at pulmonic valve in a dog with pulmonary hypertension showing decreased acceleration time and AT/ET ratio (0.32).

CONCLUSION

The M-mode measurement of RPAD index in dogs with pulmonary hypertension secondary to DCM is easy and accurate method for diagnosis of pulmonary hypertension in dogs. RPAD index and M-mode morphology of right pulmonary artery (anterior dicrotic notch) may be considered as supportive indicator to diagnose PH in absence of tricuspid regurgitant velocity jet. The TRPG and RPAD index measurement aid in assessment of the prognosis following treatment in dogs with pulmonary hypertension.

ACKNOWLEDGEMENT

The authors are grateful to the Head of the Department, Dept. of Veterinary Medicine, Veterinary college, Hebbal, Bengaluru for providng all the necessary fecilities to succsseful completion of research work.

Conflict of interest

The authors declared that there is no conflict of interests regarding the publication of this article.

REFERENCES

Bonagura, J.D. and Twedt, D.C. (2014). Cardiovascular Diseases. In: Kirk's Current Veterinary Therapy XV, 15th edn. Edited by: Bonagura J.D. and D.C. Twedt, Saunder. pp. 719-838.

Boon, J.A. (2011). Hypertensive Heart Disease (Pulmonary Hypertension). Veterinary echocardiography. Second edn. Willey-Blackwell. Ames, Iowa, United states of America. pp. 335-351.

Chan, I.P., Weng, M.C., Hsueh, T., Lin, Y.C. and Lin, S.L. (2019). Prognostic value of right pulmonary artery distensibility in dogs with pulmonary hypertension. Journal of Veterinary Science. 20(4): e34. doi.org/10.4142/jvs.2019.20.e34.

Chetboul, V. (2015). Pulmonary Arterial Hypertension-Clinical echocardiography of the dog and cat: Elsevier, Missouri, pp: 229-240. doi.org/10.1016/b978-0-323-31650-7.00014-4.

Johnson, L., Boon, J. and Orton, E.C. (1999). Clinical characteristics of 53 dogs with doppler-derived evidence of pulmonary hypertension. Journal of Veterinary Internl Medicine. 13: 440-447. doi.org/10.1111/j.1939-1676.1999.tb01461.x.

Kellihan, H.B. and Stepien, R.L. (2010). Pulmonary hypertension in dogs: Diagnosis and therapy. Veterinary Clinics of North America: Small Animal Practice. 40: 623-641. doi.org/10.1016/j.cvsm.2010.03.011.

Stepien, R.L. (2009). Pulmonary arterial hypertension secondary to chronic left-sided cardiac dysfunction in dogs. Journal of Small Animal Practice. 50(suppl 1): 34-43. doi.org/10.1111/j.1748-5827.2009.00802.x.

Tilley, L.P. and Smith, F.W.K. (2008). The History and Physical Examination. In: Manual of Canine and Feline Cardiology [(Edt.) Tilley, L.P., Smith, F.W.S., Oyama, M.A. and Sleeper, M.M.] Edn.4th., Saunders Elisevier Publication. pp: 49-77. doi.org/10.1016/B978-141602398-2.10003-8.

Venco, L., Mihaylova, L. and Boon, J.A. (2014). Right pulmonary artery distensibility index (RPAD index). A field study of an echocardiographic method to detect early development of pulmonary hypertention and its severity even in the absence of regurgitant jets for doppler evaluation in heartworm infected dogs. Journal of Veterinary Parasitology, 60-66. doi.org/10.1016/j.vetpar.2014.08.016.

Visser, L.C., Im M.K, Johnson, L.R. and Stern, J.A (2016). Diagnostic value of right pulmonary artery distensibility index in dogs with pulmonary hypertension: comparison with doppler echocardiographic estimates of pulmonary arterial pressure. Journal of Veterinary Internal Medicine. 30: 543-552. doi.org/10.1111/jvim.13911.

Yamini, S.H., Jeyaraja, K., Chandrashekar, M. and Kavitha, S. (2020). Prevalence of pulmonary hypertension in dogs with degenerative mitral valve disease. Indian Journal of Animal Research. 54(9): 1136-1142. doi: 10.18805/ijar.B-3704.