RESEARCH ARTICLE Indian Journal of Animal Research, Volume 57 Issue 6: 722-729 (June 2023)

Structural Modification and CD8+ Cells Distribution of Uterus in Pregnancy of Ewes

M.M. Islam[1], P. Das[1], R. Malakar[1], A.K. Gautam[1]

10.18805/IJAR.B-4778

ABSTRACT

Background: Nowadays, the infertility and abortion due to different etiological factors are very fatal cause of economic loss in animal husbandry practices. Infections outreach when natural immune defense barrier breaks down resulting in abortion, miscarriage. The gravid and non-gravid genitalias have self-defense power in the form of natural immunity and lymphocytes and their subsets are major responsible immune components. The current study was aimed to evaluate the changes of uterine structure and population of immune cells in pregnancy.

Methods: During the period of 2017-2018, apparently healthy 6 gravid and 6 non-gravid uterus of Garole ewes were procured from Govt. registered slaughter unit, West Bengal. The samples were processed for routine histological sectioning and different staining techniques were followed for assessment of structural modification. For immune cells identification, immunohistochemistry was performed.

Result: The endometrial thickness and the lining epithelial height of the gravid uterus were maximum. The number as well as size of the caruncles were maximum in gravid uterus. The uterine glands of the gravid uterus were hyperplastic and the epithelium showed stronger PAS-AB reaction. The myometrial thickness was more in the gravid uterus. The lymphocytes were especially abundant in the basal zone of endometrium and their population was more at the middle part of the uterus. The occurrence of CD8+ cells was found within the luminal and glandular epithelium of the caruncular and inter caruncular areas. In the gravid uterus, comparatively the population of CD8+ cells was more. As the CD8, cytotoxic T cells inhibit anti-foetal response, increase natural immune defensive barrier and destroy intracellular pathogens, we may conclude that increased population of CD8+ cells maintain the successful pregnancy.

Key words: Abortion and immunity, Garole sheep, Histology, Immunohistochemistry.

INTRODUCTION

Livestock plays an important role in the national economy of an agricultural developing country like India and they are reared for the production of milk, meat and wool, particularly in arid, semitropical or mountainous areas. Garole sheep (*Ovis aries*) are distributed in the Sundarban region of West Bengal in India. It is a small-sized native breed known for its prolificacy and adaptation to the saline marshy land of the Sundarban region. Twin and triplet births are common and they are reared mainly for mutton production (Sahana *et al*., 2001). They are seasonally polyestrous and usually conceive during spring season.

Infertility and abortion due to different etiological factors are very fatal cause of economic loss in animal husbandry practice. Infections outreach when natural immune defense barrier breaks down resulting in abortion, miscarriage. The gravid and non-gravid genitalias have self-defense power in the form of natural immunity and cells like neutrophils, macrophages, plasma cells, lymphocytes, NK-cells *etc.* are responsible for this. The major components of natural immunity are lymphocytes. Subsets of T-lymphocytes present in the uterus are CD4, CD8, CD25, CD45R *etc.* They play key roles in the defense mechanism, regulate acquired immunity and are responsible for cell mediated immunity response. CD8+ T-cells are T-lymphocyte, also known as killer cell or cytotoxic T cell and they act like class-I MHC receptor molecules. It is very important for immune defense against intracellular pathogens, including viruses and bacteria. CD8+ T cells are critical in the balance between foetal tolerance and antiviral immunity. To establish a healthy pregnancy, the maternal immune system must tolerate foetal alloantigens yet remain competent to respond to infections. CD8+ T cells are key cells to provide protective immunity against viral infections and are the most important cells that can directly recognize allogeneic MHC class I molecules (Tilburgs and Strominger, 2013).

Histomorphological and immunohistochemical studies of immunocompetent cells may explain the detailed morphological background of cell disposition and related immunity of the uterus and thus may help in improving uterine health status. Keeping in view the high prolificacy regulated reproductive behavior of Garole ewes and scanty

[1]Department of Veterinary Anatomy and Histology, Faculty of Veterinary and Animal Sciences, West Bengal University of Animal and Fishery Sciences, Kolkata-700 037, West Bengal, India.

Corresponding Author: M.M. Islam, Department of Veterinary Anatomy and Histology, Faculty of Veterinary and Animal Sciences, West Bengal University of Animal and Fishery Sciences, Kolkata-700 037, West Bengal, India. Email: mailmofijulislam@gmail.com

How to cite this article: Islam, M.M., Das, P., Malakar, R. and Gautam, A.K. (2023). Structural Modification and CD8+ Cells Distribution of Uterus in Pregnancy of Ewes. Indian Journal of Animal Research. 57(6): 722-729. doi: 10.18805/IJAR.B-4778.

Submitted: 17-09-2021 **Accepted:** 13-12-2021 **Online:** 09-03-2022

of literature in this regard, the present study has been undertaken to elucidate the histomorphological and immunohistochemical characteristics of uterus of gravid and non-gravid ewes.

MATERIALS AND METHODS

Samples and histological methods

The present experiment was conducted in the Department of Veterinary Anatomy, West Bengal University of Animal and Fishery Sciences during the period of 2017-2018. To undertake the investigations, apparently healthy 6 gravid and 6 non-gravid uterus of ewes were procured from Govt. Registered Slaughter Unit, West Bengal. The samples were processed for routine histological sectioning as per Luna (1968). All sections were cut at 5 µm thickness. The samples were stained with Haematoxylin and Eosin (HE staining) (Luna, 1968) for routine histology, Masson's Trichrome (Luna, 1968) to visualize the collagen fibers, Periodic acid Schiff -Alcian Blue (PAS-AB) Staining PH 2.5 (Luna, 1968) for demonstration of neutral and acid mucopolysaccharides and Weigert's Resorcin Fuschin Method (Sheehan and Hrapchak, 1973) for elastic fibers identification. Microtomy and micrometry were done by Leica 2125 DM rotary microtome and Leica DM 2000 microscope with Leica Qwin software and standard statistical procedure were followed for data interpretations.

Immunohistochemistry

Immunohistochemistry was done from paraffin sections of tissues on Millennia 2.0 adhesion slides (Cat. No. 71863-01, abcam) as per the manufacturing instructions. The tissue sections were deparaffinized and hydrated in distilled water. The sections were covered with trypsin enzymatic antigen retrieval solution (Cat. No. ab970, abcam) and incubated at 37°C for 10 minutes. Non-specific binding sites of antibodies were blocked by peroxidase blocking solution (Lot. No. 00065614, Dako) and washed with phosphate buffer saline (PBS). Then the sections were incubated with mouse monoclonal anti CD8 antibody (Cat. No. MA1-80900, Thermo Fisher Scientific) and secondary antibody, Rabbit anti-mouse IgG H&L (HRP Conjugated, Cat. No. ab6728; abcam) in 1: 200 dilution at 37°C for 2 hours and 1 hour respectively. Slides were treated with freshly prepared DAB solution for 3 minutes (DAB substrate, Cat. No. 34001, Thermo Fisher Scientific). The sections were counter stained with Mayer's haematoxylin and then mounted in DPX.

Photomicrography

The stained slides were observed under light microscope (Leica DM2000) to study the histoarchitecture of different tissues and photomicrography were made with the help of Leica DM2000 microscope with camera (Leica) under lower as well as higher magnification.

Micrometry

Leica Qwin Images Analyser software in Leica DM 2000 Microscope was used for taking micrometrical data from the stained sections.

RESULTS AND DISCUSSION

Histological features of uterus

Morphological changes in the uterus of ewes during pregnancy suggest that the uterine wall facilitates embryonic development. The uterine wall of both the gravid and non-gravid uterus consisted of three layers *viz.* the endometrium, myometrium and perimetrium (Fig 1). Similar uterine structure also occurs in cows (Wimsatt, 1950; Espejel and Medrano, 2017).

Endometrium

On histomorphological identification, the lamina epithelialis mucosa was lined by the simple columnar epithelium. Similar observations were reported in other mammals including sows and ruminants (Eurell and Frappier, 2006); camel (Porjoosh *et al.*, 2010). The height of the epithelium and endometrial thickness were measured from the different parts of the uterus and the data is presented in Table 1.

During pregnancy the height of the epithelium was maximum in the gravid uterus which is the major modification to the structure of the uterine wall (Fig 2). These changes indicate that in pregnancy the increased surface area is meant for proper attachment of placenta and exchange between mother and offspring. Comparatively, the entire endometrial thickness was more in the middle horn of the

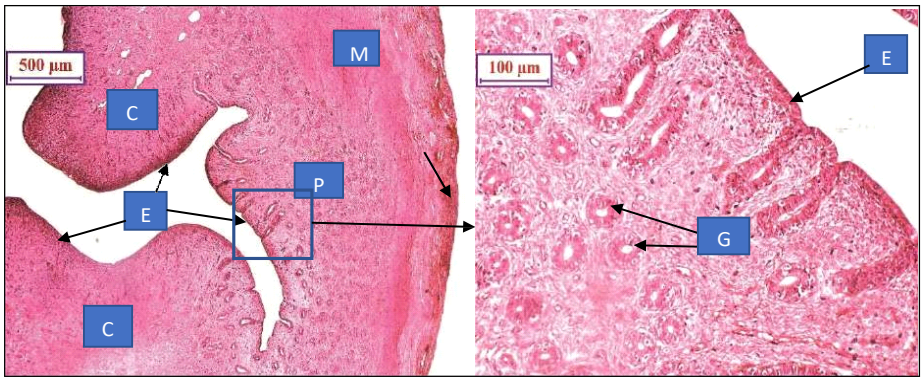

Fig 1: Photomicrograph showing non-pregnant middle horn (HE staining, x4 and x20).
(Arrow) *T. serosa*, (M) *T. muscularis*, (P) *I. propria*, (E) Simple columnar epithelium, (G) Glandular epithelium and (C) Caruncle.

gravid uterus. It helps in interdigitation between placental cotyledons and endometrial caruncles form placentomes, which serve a primary role in foetal-maternal gas exchange and derivation of nutrients by the placenta for hemotrophic nutrition of the foetus (Spencer, 2014). In non-pregnant ewes the endometrial thickness was more in middle horn as compared to the other part of the uterus (Fig 3). Similar results observed in non-luteal groups of cows and ewes (Shaham- Albalancy, 1997; Benbia *et al*., 2013).

Comparatively, the lamina propria submucosa of gravid uterus was enriched with vascular loose connective tissue with many more fibrocytes, lymphocytes, plasma cells, macrophages and giant cells than the lamina propria submucosa of non-gravid uterus (Fig 4 and 5). Similar findings were also observed in sow and ruminants (Eurell and Frappier, 2006; Espejel and Medrano, 2017).

The endometrium was divided into raised aglandular caruncular areas and intensely glandular inter caruncular areas. Identically, Spencer (2014) identified the similar results in adult ruminants (cattle, goats and sheep). Grossly, the caruncles were concave disc shaped structure and their numbers as well as size were more in the gravid uterus (Fig 6). Comparatively in the gravid uterus, the caruncles were rich in fibrocytes, lymphocytes and plasma cells with extensive capillary networks than non-gravid uterus as earlier reported by Eurell and Frappier (2006). This extensive

Table 1: Average height and thickness of different parts of both the gravid and non-gravid uterus.

Height and thickness	Parts of uterus	Non-gravid (average)	Gravid (average)
Epithelium	Tip of the horn	12.35±0.32 µm	28.67±0.50 µm
(Height)	Middle horn	13.40±0.22 µm	34.54±0.62 µm
	Body of the uterus	20.16±0.62 µm	51.19±0.47 µm
Endometrium	Tip of the horn	1539.39±23.10 µm	231.16±10.84 µm
(Thickness)	Middle horn	1818.59±13.43 µm	2759.65±16.81 µm
	Body of the uterus	1061.39±15.75 µm	655.80±11.04 µm
Myometrium	Tip of the horn	284.13±11.23 µm	502.85±8.27 µm
(Thickness)	Middle horn	1050.37±11.11 µm	1175.81±9.58 µm
	Body of the uterus	822.47±7.82 µm	1645.97±8.66 µm

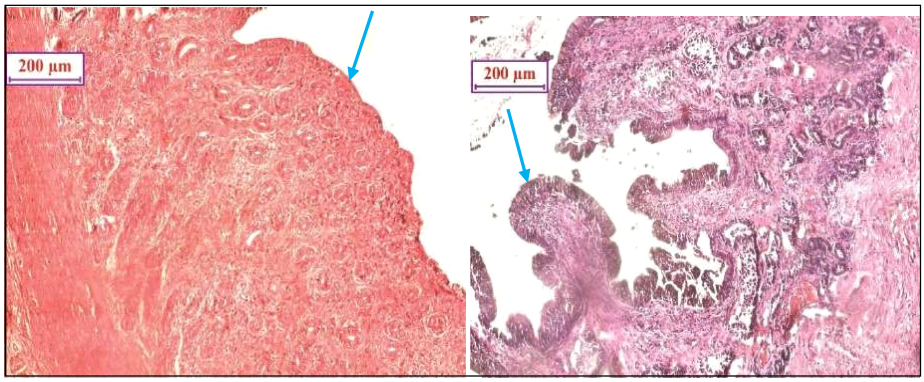

Fig 2: Photomicrograph showing non-gravid tip of the horn and gravid tip of the horn (H&E staining, x10). Epithelial (arrow) height more in gravid tip of the horn comparatively.

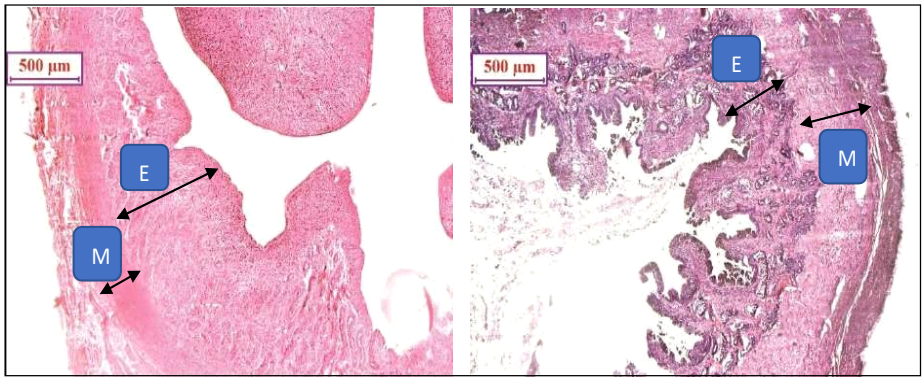

Non-gravid uterus ***Gravid uterus***

Fig 3: Photomicrograph showing non-gravid and gravid uterus where endometrial thickness is more in non-gravid uterus and myometrial thickness is more in gravid uterus (H&E staining, x4). Endometrium (E), Myometrium (M).

capillary network is responsible for the potential exchange between mother and embryo after implantation. Huckabee *et al.* (1961) described that in the non-pregnant uterus the blood flow is approximately 25 ml/min. It increases to approximately 200 ml/min. at the 80th day of gestation and exceeds 1000 ml/min. near the end of the 150-day gestation period of the small ruminants like sheep and goat.

The simple coiled, branched tubular glands were found within the propria submucosal region of intercrancular areas but these were absent in the caruncular area (Fig 7). The glands were lined by simple columnar glandular epithelium which showed variation in the height in non-gravid and gravid uterus. This was in accordance with the results of Benbia *et al.* (2013) and Qureshi *et al.* (2015). Of note, the endometrial glands were hyperplastic in the gravid uterus but branched more frequently in non-gravid uterus due to high estrogen level (Fig 8) and Spencer (2014) found these similar results. The cells of the luminal and glandular epithelium were PAS-AB positive. There was a strong alcianophilic reaction in the glandular epithelium of gravid uterus whereas in luminal epithelium, the reaction was faint (Fig 8). This result was in accordance with Restall (1966). It suggests that during pregnancy, activity of uterine glands increases and secrete more PAS alcian blue positive mucous substances.

The unique structures for pregnancy development were found in the gravid uterus. These were the placental attachments with the caruncles, the placentomes. Simple villi which were developed from the areas of chorionic sac of foetal membrane in contact with elevated cup shaped structure of maternal endothelium (caruncles) was noticed in gravid uterus (Fig 9). The simple chorionic villi ramified to form branching cotyledons and they consisted of a vascular mesenchyme covered with a simple layer of trophoblastic cells. The trophoblast included columnar or irregular shaped mono nucleated cells and large binucleated cells (Fig 10).

Myometrium

The myometrium was composed of inner circular and outer longitudinal layers of smooth muscle fibers and a vascular layer was in between them. Similar observation was found by Porjoosh *et al.* (2010) in camels, Qureshi *et al.* (2015) in teddy goats and Espejel and Medrano (2017) in dairy cows. Thickness of myometrium was measured and data is presented in the Table 1 and that showing the thickness of the myometrium, was maximum at the middle of the horn and minimum towards the tip of the horn in both the groups. The overall myometrial thickness was more in the gravid uterus (Fig 3). This difference might be due to hyperplasia and hypertrophy occurring during gestation presumably to provide histotrophic support for conceptus growth and development (Eurell and Frappier, 2006; Gray *et al.*, 2001). In between the inner circular and

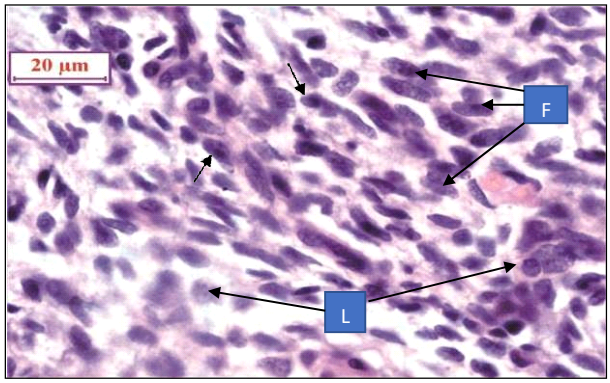

Fig 4: Photomicrograph showing non-gravid middle horn (HE staining, x100). (F) Fibroblasts, (L) Lymphocytes and (arrows) plasma cells.

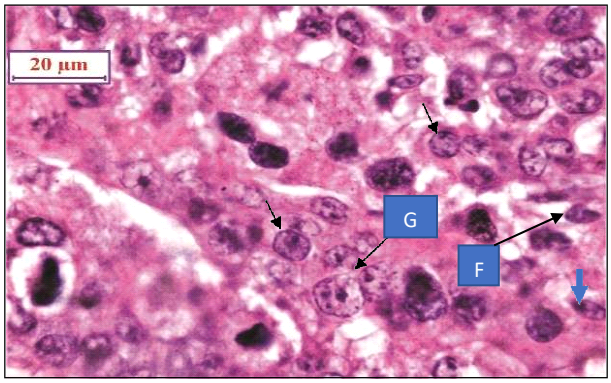

Fig 5: Photomicrograph showing gravid middle horn (HE staining, x100). (F) fibroblast, (G) giant cell, (blue arrow) plasma cell and (black arrows) lymphocytes.

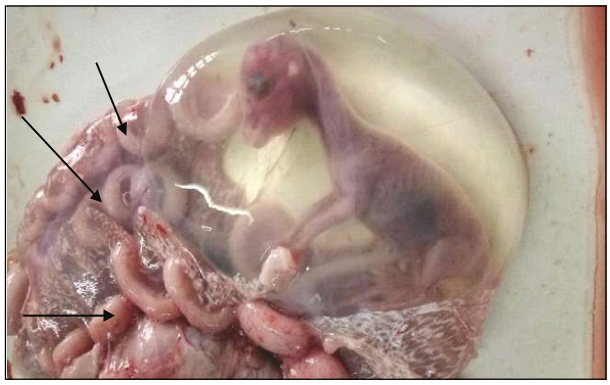

Fig 6: Photogragh showing gross cancave disc shaped caruncles (arrow) of gravid ewe.

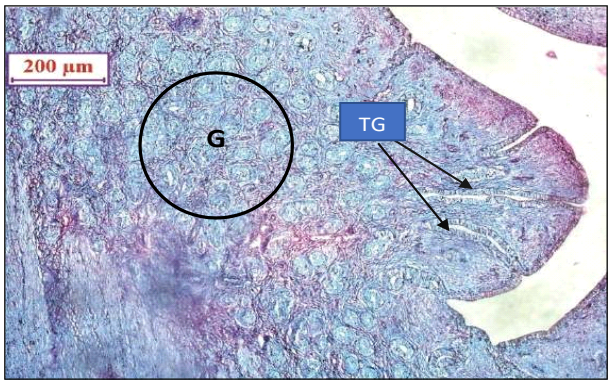

Fig 7: Photomicrograph showing uterine glands at inter caruncular area of non-gravid uterus (PAS-AB staining, x10). Uterine glands (G), Branch tubular glands (TG).

outer longitudinal layers, a separate vascular layer with abundant blood vessels within the connective tissue materials was visualized in all types of uterus. In the case of gravid uterus, this layer was packed with more blood vessels as compared to non-gravid uterus (Fig 11). It indicates profuse supply of blood during pregnancy. Rosenfeld *et al.* (1974) observed that the uteroplacental blood flow progressively increased throughout the pregnancy and was maximum at the third trimester. "Ligamenta viva uteri" was found mainly within the myometrium of the body of the gravid uterus in the

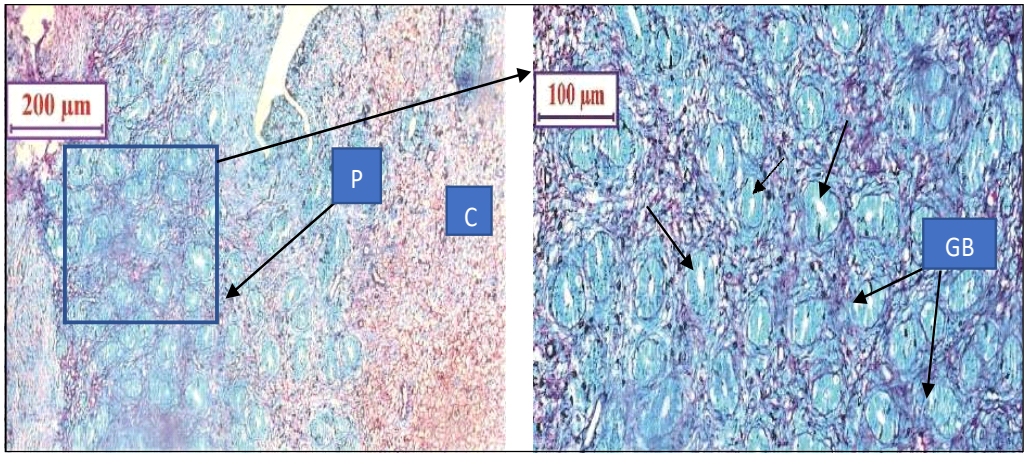

Fig 8: Photomicrograph showing hyperplastic glands at inter caruncular area of gravid uterus (PAS-AB staining, x10 and x20). (C) Caruncle, (P) Lamina propria, (GB) Goblet cells and (arrows) uterine glands.

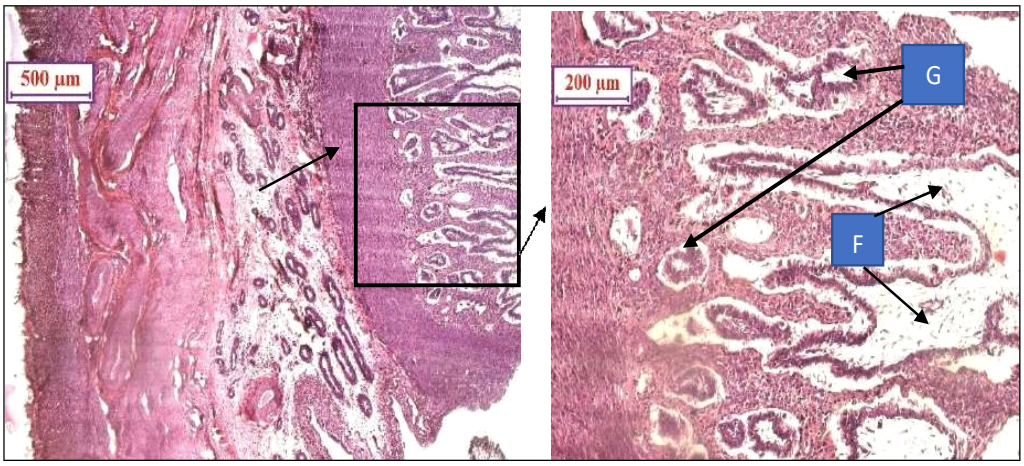

Fig 9: Photomicrograph showing pregnant middle horn of the uterus (H&E staining, x4 and x10). (Arrow) Muscular band of caruncle, (F) Foetal membrane and (G) Glands.

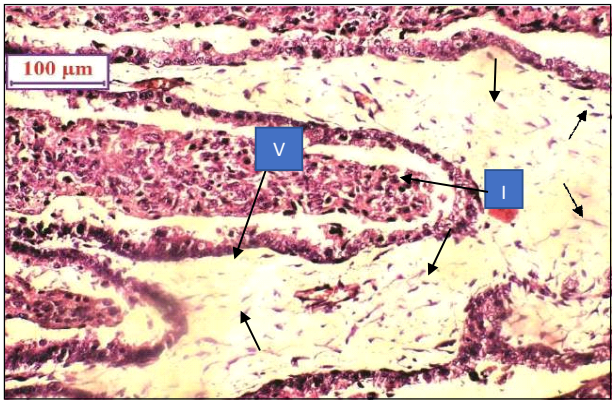

Fig 10: Photomicrograph showing gravid middle horn (H&E staining, x20). (I) involution of caruncle, (V) chorionic villi and (arrows) trophoblast cells.

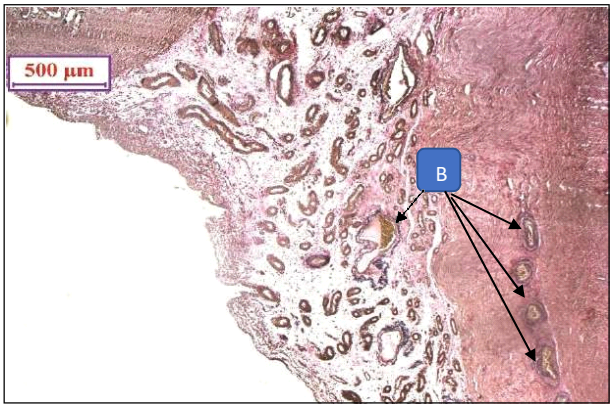

Fig 11: Photomicrograph showing more blood vessels in middle horn of the gravid uterus (Weigert's Resorcin Fuschin staining, x4). Blood vessels (B).

form of the larger and smaller groups. These were the thickenings of the collagen fibers on the wall of the blood vessels which occluded almost the whole of the lumen of the blood vessels (Fig 12). Similar findings were studied in sheep (Katica *et al*., 2014) and in women with pre-eclampsia (Ong *et al*., 2005).

The special histochemical staining of the uterus with Weigert's method revealed the presence of elastic fibers around the blood vessels (Fig 13). The longitudinal sections stained with Masson's Trichrome method showed presence of collagen fibers as a predominant fibers in the vascular layer of tunica muscularis and found in lamina propria submucosa also (Fig 14).

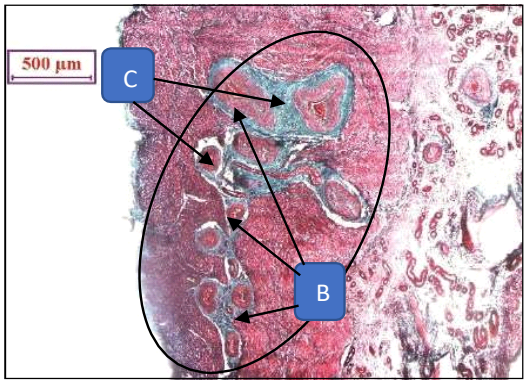

Fig 12: Photomicrograph showing ligamenta viva uteri (circle area) in pregnant body of the uterus (Masson's Trichrome staining, x4). (B) Blood vessels and (C) Collagen fibers surrounding the blood vessels.

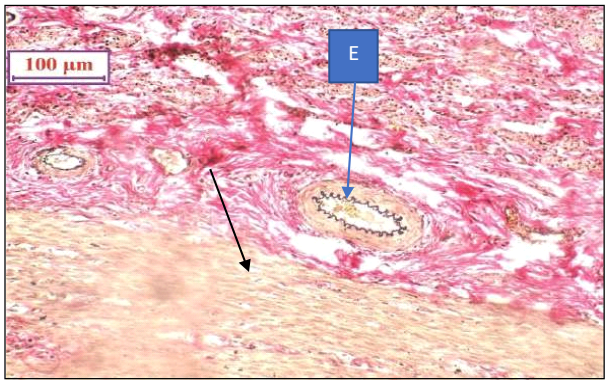

Fig 13: Photomicrograph showing non-pregnant body of the uterus (Weigert's Resorcin Fuschin staining, x20). (E) Elastic fiber and (arrow) circular muscle layer.

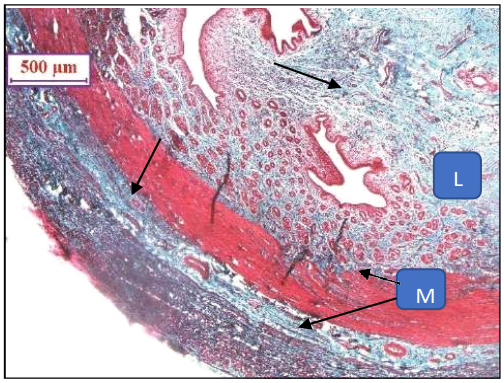

Fig 14: Photomicrograph showing non-pregnant body of the uterus (Masson's Trichrome staining, x4). (Arrows) collagen fibers in inter muscular layers and in lamina propria (L), Tunica muscularis (M).

Perimetrium

The perimetrium was clearly separated from myometrium and no variation was noticed between the gravid and non-gravid uterus (Eurell and Frappier, 2006; Katica *et al*., 2014). It consisted of loose connective tissue fibers and collagen fibers which were covered by peritoneal mesothelium.

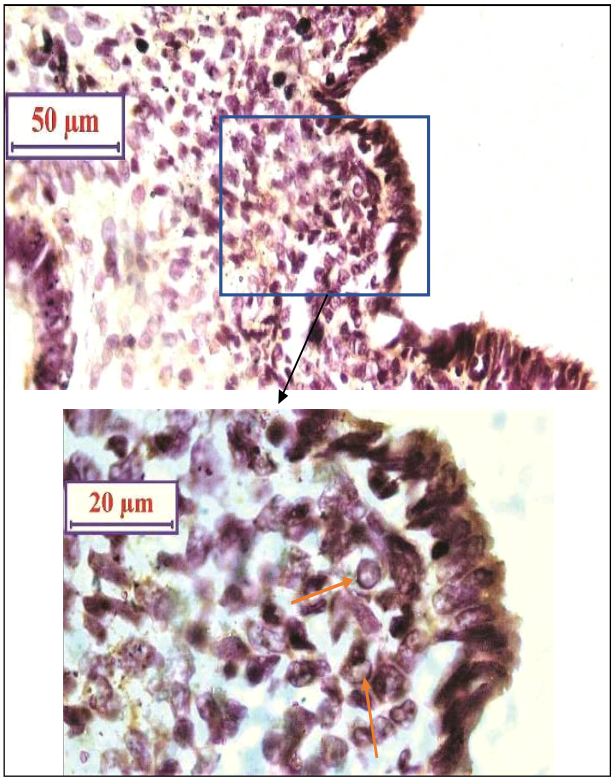

Fig 15: Photomicrograph showing CD8 lymphocytes localisation at the sub-epithelial region of inter-caruncular area of tip of the horn of gravid ewe (IHC, x40 and x100). CD8 positive lymphocytes (arrows).

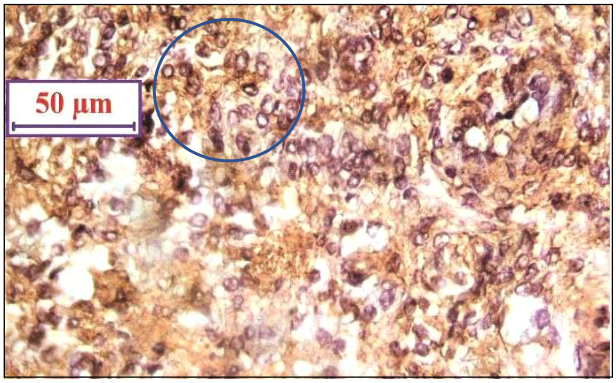

Fig 16: Photomicrograph showing CD8 lymphocytes distributed in stromal area of middle horn of gravid ewe in a cluster form (circle area) (IHC, x40).

Immunohistochemical studies

IHC is a technique for identifying cellular or tissue constituents (antigens) by means of antigen-antibody interactions (Kabiraj *et al.*, 2015). In the present study, the greatest number of T-lymphocytes was identified in the glandular and luminal epithelium and in the stroma immediately adjacent to the epithelium of the sheep endometrium. This result was in accordance with the result of Gottshall and Hansen (1992), Gogolin Ewens *et al.* (1989) and Lee *et al.* (1988).

Immunohistochemically, CD8+ cells, subtype of T lymphocyte, were identified in different parts of the uterus and were distributed mostly in the stroma and subepithelial regions of both the caruncular and inter caruncular areas of the uterus in gravid and non-gravid ewes. Meeusen *et al.* (1993) and Cobb and Watson (1995) described that the cytotoxic (CD8+) T cells were located primarily adjacent to the epithelial layer of the uterus of sheep. Similar observation was documented in the uterus of the female goat (Perez-Martinez *et al.*, 2002) and in the uterus of sow (Kaeoket *et al.*, 2001). We observed more CD8+ cells in the stromal component than in the lining epithelium of endometrium (Fig 15 and 16). Although, Majewski *et al.* (2001) reported that CD45R, $\gamma\partial$ T cells and CD8 positive cells were located predominantly in the luminal and glandular epithelium and only a few scattered lymphocytes were present in the stroma of the uterus of the sheep. In some areas within the caruncular stroma of the gravid uterus, CD8 positive cells appeared in the form of clusters (Fig 16). This is in accordance with the findings observed by Lee *et al.* (1988). The epithelium of the endometrial glands and their ducts was frequently infiltrated by CD8+ T lymphocytes at the inter-caruncular areas (Fig 17) but the same was absent in the non-glandular carancular areas. Lee *et al.* (1988) observed the similar results at all stages of the oestrous cycle inconsistently. However, Gottshall and Hansen (1992) reported that in most sections, CD4+ and CD8+ cells were rarely observed or absent in the uterine glands of ewes.

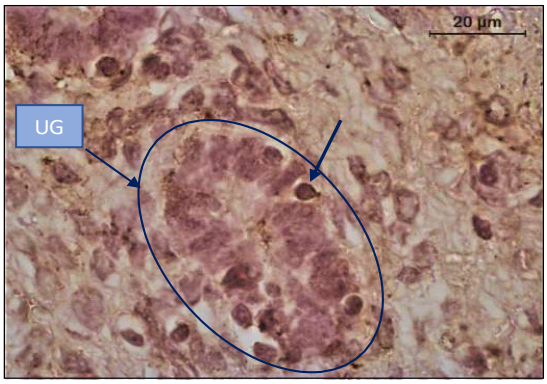

Fig 17: Photomicrograph showing CD8 positive lymphocyte (arrow) localize at the glandular epithelium of the inter-caruncular area of tip of the horn of non-gravid uterus (IHC, x100). Uterine gland (UG).

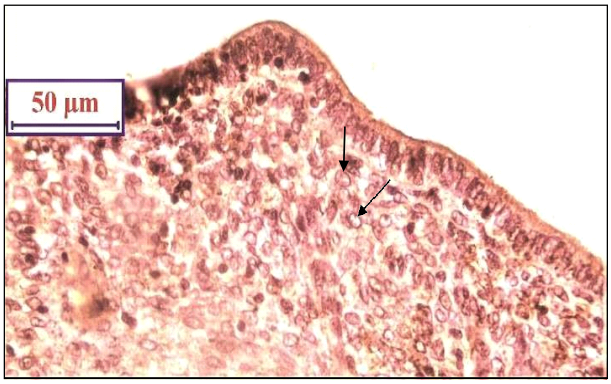

Fig 18: Photomicrograph showing CD8 positive lymphocytes (arrows), interspersed at the sub-epithelial region of caruncle of middle horn of uterus of non-gravid ewe (IHC, x40).

The lymphocyte population was significantly more at the middle of the horn of the uterus as compared to the tip of the horn of the uterus in both the gravid and non-gravid ewes (Fig 15 and 16). In comparison between the gravid and non-gravid uterus, the population of CD8+ cells was more in the gravid uterus (Fig 16 and 18) but in the placentome of the gravid uterus, CD8+ cell was nearly absent. Present results indicate that these changes, rather than due to locally acting conceptus factors, are instead the result of hormonal signals of maternal or foetal origin that either act directly on endometrial lymphocytes or stimulate the uterine endometrium to induce synthesis of regulatory molecules that affect lymphocyte dynamics as earlier observed by Majewski *et al.* (2001) in sheep. The role of immunocompetent cells was documented by Bischof *et al.* (1995) who observed acute inflammation in the pig endometrium in response to fertile mating which included marked changes in the tissue and immune cell components of the endometrium. There appeared to be suppression and activation of various immune cell components in the uteri of pregnant pigs. This phenomenon was presumably in response to foetal or trophoblast antigens, suggesting that the local immune system was involved in the uterine response to pregnancy. In the gravid uterus, CD8+ cell was nearly absent in the placentomal region. A few CD8+ lymphocytes were observed among the stromal cells of the caruncular septa throughout pregnancy. Gogolin-Ewens *et al.* (1989) reported that after Day 50 of pregnancy, CD8+ lymphocytes had also infiltrated into the interplacentomal uterine epithelium.

CONCLUSION

From the present investigation we have observed several histomorphological changes between the gravid and the non-gravid uterus. We may conclude that during pregnancy in the ewe the immune system responds to changes in the maternal uterine environment and the CD8 positive T-lymphocytes and the other immune competent cells increase for maintain the successful pregnancy.

ACKNOWLEDGEMENT

Authors are thankful to the Department of Veterinary Anatomy and Histology, Faculty of Veterinary and Animal Sciences, West Bengal University of Animal and Fishery Sciences, Kolkata, India for providing necessary facilities to do this work.

Conflict of interest: None.

REFERENCES

Benbia, S., Yahia, M., Boutelis, S., Chennaf, A. and Yahia, M. (2013). Evaluation of the cytology and histology of uterus and cervix as predictors of estrous stages in ewes and dairy cows. Proceedings of the 2013 International Conference on Biology and Biomedicine. 33-35.

Bischof, R.J., Brandon, M.R. and Lee, C.S. (1995). Cellular immune responses in the pig uterus during pregnancy. Journal of Reproductive Immunology. 29(2): 161-178.

Cobb, S.P. and Watson, E.D. (1995). Immunohistochemical study of immune cells in the bovine endometrium at different stages of the oestrous cycle. Research in Veterinary Science. 59(3): 238-241.

Espejel, M.C. and Medrano, A. (2017). Histological cyclic endometrial changes in dairy cows: An overview. Journal of Dairy and Veterinary Sciences. 1-3.

Eurell, J.A. and Frappier, B.L. (2006). In: Dellmann's Textbook of Veterinary Histology. 6th edn, Blackwell Publishers, Iowa, USA.

Gogolin-Ewens, K.J., Lee, C.S., Mercer, W.R. and Brandon, M.R. (1989). Site-directed differences in the immune response to the foetus. Immunology. 66(2): 312-317.

Gottshall, S.L. and Hansen, P.J. (1992). Regulation of leucocyte subpopulations in the sheep endometrium by progesterone. Immunology. 76(4): 636-641.

Gray, C.A., Bartol, F.F., Tarleton, B.J., Wiley, A.A., Johnson, G.A., Bazer, F.W. and Spencer, T.E. (2001). Developmental biology of uterine glands. Biology of Reproduction. 65(5): 1311-1323.

Huckabee, W.E., Metcalfe, J., Prystowsky, H. and Barron, D.H. (1961). Blood flow and oxygen consumption of the pregnant uterus. American Journal of Physiology-Legacy Content. 200(2): 274-278.

Kabiraj, A., Gupta, J., Khaitan, T. and Bhattacharya, P.T. (2015). Principle and techniques of immunohistochemistry-A Review. Int. J. Biol. Med. Res. 6(3): 5204-5210.

Kaeoket, K., Dalin, A.M., Magnusson, U. and Persson, E. (2001). The sow endometrium at different stages of the oestrous cycle: Studies on the distribution of CD2, CD4, CD8 and MHC class II expressing cells. Animal Reproduction Science. 68(1-2): 99-109.

Katica, A., Mlaćo, N., Avdić, R., Tandir, F., Ćutahija, V., Bejdić, P. and Hadžiomerović, N. (2014). Histology of uterus of Dubska pramenka during sexual season. Biotechnology in Animal Husbandry. 30(2): 225-232.

Lee, C.S., Gogolin-Ewens, K. and Brandon, M.R. (1988). Identification of a unique lymphocyte subpopulation in the sheep uterus. Immunology. 63(1): 157-164.

Luna, L.G. (1968). In: Manual of Histologic Staining Methods of the Armed Forces Institute of Pathology, 3rd edn, McGraw-Hill, New York. pp. 36-37, 168-169.

Majewski, A.C., Tekin, S. and Hansen, P.J. (2001). Local versus systemic control of numbers of endometrial T cells during pregnancy in sheep. Immunology. 102(3): 317-322.

Meeusen, E., Fox, A., Brandon, M. and Lee, C.S. (1993). Activation of uterine intraepithelial γδ T cell receptor positive lymphocytes during pregnancy. European Journal of Immunology. 23(5): 1112-1117.

Ong, S.S., Baker, P.N., Mayhew, T.M. and Dunn, W.R. (2005). Remodeling of myometrial radial arteries in preeclampsia. American Journal of Obstetrics and Gynecology. 192(2): 572-579.

Perez-Martinez, M., Luna, J., Mena, R. and Romano, M.C. (2002). Lymphocytes and T lymphocyte subsets are regionally distributed in the female goat reproductive tract: Influence of the stage of the oestrous cycle. Research in Veterinary Science. 72(2): 115-121.

Porjoosh, A., Raji, A.R., Nabipour, A. and Farzaneh, N. (2010). Gross and histological study on the uterus of camels (*Camelus dromedarius*). Journal of Camel Practice and Research. 17(1): 91-94.

Qureshi, A.S., Mohsin, M. and Rehan, S. (2015). Effect of parity on gross and microscopic structure of uterus in teddy goats (*Capra hircus*). Ruminant Science. 4(2): 133-136.

Restall, B.J. (1966). Histological observations on the reproductive tract of the ewe. Australian Journal of Biological Sciences. 19(4): 673-686.

Rosenfeld, C.R., Morriss Jr, F.H., Makowski, E.L., Meschia, G. and Battaglia, F.C. (1974). Circulatory changes in the reproductive tissues of ewes during pregnancy. Gynecologic and Obstetric Investigation. 5(5-6): 252-268.

Sahana, G., Gupta, S.C. and Nivsarkar, A.E. (2001). Garole: The prolific sheep of India. Animal Genetic Resources/Resources génétiques animales/Recursos genéticos Animals Animals. 31: 55-63.

Schäfer Somi, S., Beceriklisoy, H.B., Budik, S., Kanca, H., Aksoy, O.A., Polat, B. and Aslan, S. (2008). Expression of genes in the canine pre implantation uterus and embryo: Implications for an active role of the embryo before and during invasion. Reproduction in Domestic Animals. 43(6): 656-663.

Shaham-Albalancy, A., Nyska, A., Kaim, M., Rosenberg, M., Folman, Y. and Wolfenson, D. (1997). Delayed effect of progesterone on endometrial morphology in dairy cows. Animal Reproduction Science. 48(2-4): 159-174.

Sheehan, D.C. and Hrapchak, B.B. (1973). Theory and Practice of Histotechnology. 1st Edn. The CV Mosby Company, Saint Louis, pp. 80-172.

Spencer, T.E. (2014). Biological Roles of Uterine Glands in Pregnancy. In: Seminars in Reproductive Medicine. 32(05): 346-357. Thieme Medical Publishers.

Tabibzadeh, S. (1990). Proliferative activity of lymphoid cells in human endometrium throughout the menstrual cycle. The Journal of Clinical Endocrinology and Metabolism. 70(2): 437-443.

Tilburgs, T. and Strominger, J.L. (2013). CD8+ effector T cells at the Fetal-Maternal Interface, Balancing Fetal Tolerance and antiviral immunity. American Journal of Reproductive Immunology. 69(4): 395-407.

Tizard, I.R. (1977). An Introduction to Veterinary Immunology. 8th edn, WB Saunders.

Vasudevan, S., Kamat, M.M., Walusimbi, S.S., Pate, J.L. and Ott, T.L. (2017). Effects of early pregnancy on uterine lymphocytes and endometrial expression of immune-regulatory molecules in dairy heifers. Biology of Reproduction. 97(1): 104-118.

Wimsatt, W.A. (1950). New histological observations on the placenta of the sheep. Developmental Dynamics. 87(3): 391-457.