RESEARCH ARTICLE Indian Journal of Animal Research, Volume 59 Issue 9: 1538-1544 (September 2025)

Experimental Infection of Goldfish (*Carassius auratus* L.) and Tilapia (*Oreochromis niloticus* L.) with Koi Ranavirus (KIRV)

D. Kaviarasu[1], K. Riji John[2], M. Rosalind George[2], B. Ahilan[1], P. Padmavathy[3], M. Petchimuthu[4]

10.18805/IJAR.B-4790

ABSTRACT

Background: Ranaviruses are now emerging as serious pathogens for the amphibians, reptiles and fishes. The aim of this study was the determination of the susceptibility of goldfish (*Carassius auratus* L.) and tilapia (*Oreochromis niloticus* L.) to experimental infection with Koi ranavirus (KIRV).

Methods: The experimental fishes were challenged with an infective dose of KIRV ($10^{6.8}$ $TCID_{50}$/ml) by intraperitoneal injection (IP), while the control groups were injected with L-15 medium. Target tissues were collected from the experimental fishes infected with virus at 3, 7, 14, 21 and 28 dpi. Tissue samples were subjected to detection of KIRV by polymerase chain reaction (PCR), cell culture assay and histopathological technique.

Result: This study reports no specific clinical signs and mortality due to virus infection during the experimental period. Experimentally infected goldfish and tilapia were tested positive for KIRV by PCR at 3 dpi, while target viral DNA was also detected in tilapia at 7 dpi by PCR. However, specific DNA of KIRV was not detected in tissues of experimental fish sampled at later experimental study periods. Cell culture assay revealed no cytopathic effect in the *Epithelioma Papulosum Cyprini* (EPC) cell line at all sampling time points. Histopathological study revealed focal necrosis, shrunken glomerulus and detached epithelium of tubules in kidney tissue at 3 and 7 dpi in gold fish and melanomacrophage cells and focal necrosis of glomerulus and detachment of the epithelium of tubules in kidney tissue at 3 and 7 dpi in tilapia. Melanomacrophage centers and necrosis were observed in spleen tissues of goldfish and tilapia at 3 and 7 dpi. The challenge study indicated that goldfish and tilapia are not the targeted species for KIRV.

Key words: Cell culture assay, Goldfish, Histopathology, Koi ranavirus (KIRV), Polymerase chain reaction, Tilapia.

INTRODUCTION

Aquaculture is the fastest growing food producing industry, which contributes to almost half of the fish food production in the world (Shefat, 2018). The aquaculture industry is mainly affected by diseases and various problems due to infection of virus, bacteria, fungi, parasites and undiagnosed and emerging pathogens. Particularly, virus infection is one of the most important challenges threatening sustainable growth of farmed fish especially due to the difficulty to treat them directly. Viruses in the family of *Iridoviridae* have emerged over the last two decades to become important pathogens in the intensively raised finfish aquaculture sector. Iridoviridae family consists of five genera *viz. Iridovirus, Chloriridovirus, Ranavirus, Lymphocystivirus* and *Megalocytivirus* (Jancovich *et al*., 2012). Ranavirus infection causes significant morbidity and mortality among the ectothermic vertebrates like amphibians, fish and reptiles for the period of past 30 years (Chinchar *et al*., 2011). Susceptibility to ranavirus infection has been reported from at least 14 families with about 70 amphibian species, more than 100 fish species and dozens of reptiles (Robert *et al*., 2011).

Ranaviruses has a size range of 120-200 nm diameter and an icosahedral symmetry. Main core of the virion contains nucleoprotein filament, which is surrounded by lipid membrane having transmembrane proteins and the capsid which is composed of identical capsomers. The genome of ranaviruses is with a single linear double-stranded DNA (dsDNA) molecule of 105 to 140 kbp (Holopainen, 2012). The first documentation of the isolation of virus (koi ranavirus) resembling Santee-Cooper ranavirus infection in koi (*Cyprinus carpio* L) was reported from India (George *et al*., 2015). Marine ranavirus (similar damselfish

[1]Dr. M.G.R. Fisheries College and Research Institute, Tamil Nadu Dr.J. Jayalalithaa Fisheries University, Ponneri-601 204, Tamil Nadu, India.
[2]Kerala University of Fisheries and Ocean Studies, Panangad, Kochi-682 506, Kerala, India.
[3]Fisheries College and Research Institute, Tamil Nadu Dr. J. Jayalalithaa Fisheries University, Thoothukudi-628 008, Tamil Nadu, India.
[4]Dr. M.G.R. Fisheries College and Research Institute, Tamil Nadu Dr. J. Jayalalithaa Fisheries University, Thalainayar-614 712, Tamil Nadu, India.

Corresponding Author: D. Kaviarasu, Department of Aquatic Animal Health Management, Dr. M.G.R. Fisheries College and Research Institute, Tamil Nadu Dr. J. Jayalalithaa Fisheries University, Ponneri-601 204, Tamil Nadu, India.
Email: dkaviarasu07@gmail.com

How to cite this article: Kaviarasu, D., John, K.R., George, M.R., Ahilan, B., Padmavathy, P. and Petchimuthu, M. (2025). Experimental Infection of Goldfish (*Carassius auratus* L.) and Tilapia (*Oreochromis niloticus* L.) with Koi Ranavirus (KIRV). *Indian Journal of Animal Research*. **59(9):** 1538-1544. doi: 10.18805/IJAR.B-4790.

Submitted: 29-09-2021 **Accepted:** 06-06-2022 **Online:** 29-06-2022

virus, SRDV) causing significantly high mortalities have been reported in seabass (*Lates calcarifer*) and similar damselfish (*P. similis*) fingerlings (Sivasankar *et al*., 2017). Recent investigation on the pathogenicity of koi ranavirus (KIRV) infection has been reported in common carp, *Cyprinus carpio* L and rohu, *Labeo rohita* (Kaviarasu *et al*., 2020). Based on this report, there was no clear virus associated clinical pathology either in common carp or rohu fingerlings following experimental infection with KIRV. The objective of this study was to determine the susceptibility of goldfish and tilapia to KIRV infection.

MATERIALS AND METHODS

Cell culture and virus propagation

The experimental infection study was conducted in 2018 at the Department of Fish Pathology and Health Management, Fisheries College and Research Institute, Thoothukudi, Tamil Nadu. The Indian strain of KIRV isolated from infected koi (*Cyprinus carpio* L.) (George *et al*., 2015) was used for this challenge study. Isolation, propagation and infectivity assay of this virus was carried out in *Epithelioma papillosum cypini* (EPC) cell line. The cell line was maintained in L-15 (Leibovitz-15) medium (Gibco, USA) supplemented with 10% FBS (Fetal Bovine Serum) (Gibco, USA) and 1x antibiotic-antimycotic solutions (Gibco, USA) in 25 cm^2 the cell culture flasks (Thermo, Korea) at 27°C. On completion of the cytopathic effect (CPE), the infected culture supernatant was harvested from the cell culture flask and clarified using centrifugation at 1500 g for 15 min. The clarified supernatant stored at 4°C was used to titrate in EPC cells.

Experimental fish

Goldfish (*Carassius auratus*) fingerlings (mean length of 7.59 cm and mean weight 6.54 g) and tilapia (*Oreochromis niloticus*) fingerlings (mean length of 7.14 cm and mean weight 6.32 g) were obtained from the local fish farm and maintained in the laboratory having no clinical signs for any infection or associated with any non-specific mortality. Fishes were acclimatized to the glass tank capacity with 100 L maintained with 50 L freshwater at a temperature of 29±1°C and fed with commercial pelleted feed twice daily.

Challenge study

Two groups consisting of 30 fish each in duplicate were used for the challenge study (Fig 1). Prior to injection experimental fishes were sedated using benzocaine at 40 mg/l. Fishes were administered with 50 µl of KIRV stock ($10^{6.8}$ $TCID_{50}$/volume inoculated) from cell culture by intraperitoneal (i.p) injection while control group fishes received 50 µl of L-15 medium from the supernatant of an uninfected cell culture medium. Tissues of the spleen and kidney were collected from three fish of each group at 3, 7, 14, 21 and 28 days of post infection and samples were investigated by a various diagnostic technique such as PCR, cell culture assay and histopathology.

Virus re-isolation

The kidney and spleen tissues from the experimental fishes were aseptically removed, pooled and examined for the abnormality after the experimental infection. The pooled extract of spleen and kidney tissues were inoculated into the EPC cell line by following the standard virus isolation procedures (Amos, 1985). The homogenised tissue samples were diluted to 1/10 (w/v) in L-15 medium containing 10% FBS and 1x antibiotic-antimycotic mix and it was clarified using centrifuge at 3000 g for 15 min and the supernatant was passed through a 0.22 µm sterile disposable filter. The pellet with the little amount of supernatant was subjected to PCR analysis with diagnostic primer developed from KIRV-MCP to assay the presence and the absence of the virus in both groups of experimental fish sample.

DNA isolation and polymerase chain reaction (PCR)

DNA samples collected from the tissues of both experimentally infected virus and the control groups were extracted using 1ml of DNA extraction solution (Himedia) following the manufacturer's instructions. The extracted DNA was dissolved in 100 µl of sterilized distilled water. The DNA extracted from the virus injected and the control group were used for PCR in a 25 µl reaction mixture with Smart Prime Mix (Ampliqon, Denmark). The specific primers and cycling conditions of KIRV; MCPFORW and MCPREV sets (George *et al.,* 2015) were used for PCR amplification. The PCR amplified products along with the molecular markers were stained using an ethidium bromide and it was visualized in 1.5% agarose gels using a gel documentation system (Biorad, U.S.A).

Histopathology

For histological analysis, spleen and kidney tissue samples from both the experimental group and control group fishes were fixed in 10% neutral buffered formalin further it was preserved and embedded in paraffin wax. The sections were stained using hematoxylin and eosin stains and it was observed under bright-field microscopy.

RESULTS AND DISCUSSION

Clinical pathology

The persistence of an infectious disease in the environment mainly depends on the availability of suitable host species and the likelihood of pathogen transmission routes either by direct or indirect contact (Haydon *et al*., 2002). Ranaviruses infection, which is dynamically different between the host species and viral isolate and the detailed molecular mechanisms by which ranaviruses are able to cause disease and circumvent the host immune response are not completely understood (Allen *et al.,* 2017). Infection by ranavirus results in mortality and morbidity differ from species to species.

Some of the experimental pathogenicity studies and field data show that mortality can range from 0% to 100%

in infected animals of an experimental test group based on species, age group, virus and health condition of the host following short infection times (Pearman *et al*., 2004; Harp and Petranka, 2006). Experimental pathogenicity study of koi ranavirus (KIRV) has been reported in common carp, *Cyprinus carpio* L. and rohu, *Labeo rohita* (Kaviarasu *et al*., 2020). The results revealed that no clear external clinical signs and mortalities were observed in experimental fishes after injection with KIRV. Not all diseases caused by ranaviruses always result in mortality (Miller *et al*., 2009). In the present study, no specific external clinical signs and mortalities were observed in goldfish and tilapia during the experimental period.

Cell culture assay

Ranavirus isolated from marine damselfish was found to be cultured in marine and freshwater fish cell lines derived from seabass and snakehead respectively (Sivasankar *et al*., 2017). They have also re-isolated ranavirus using cell culture from the pooled homogenates of the kidney and spleen of each moribund seabass fingerlings which had been experimentally infected. KIRV virus could not be

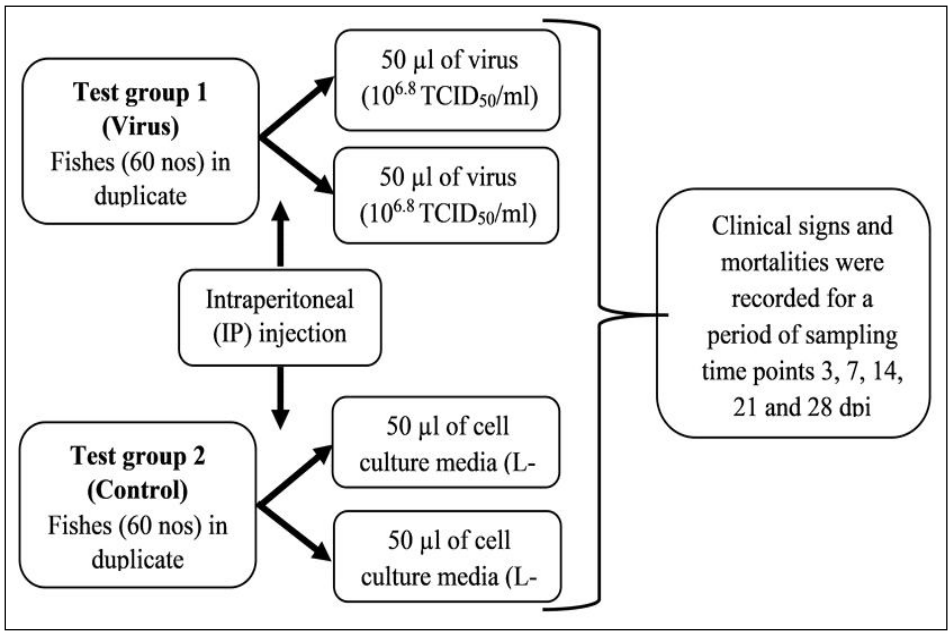

Fig 1: Experimental setup for experimental fishes challenge with koi ranavirus (KIRV).

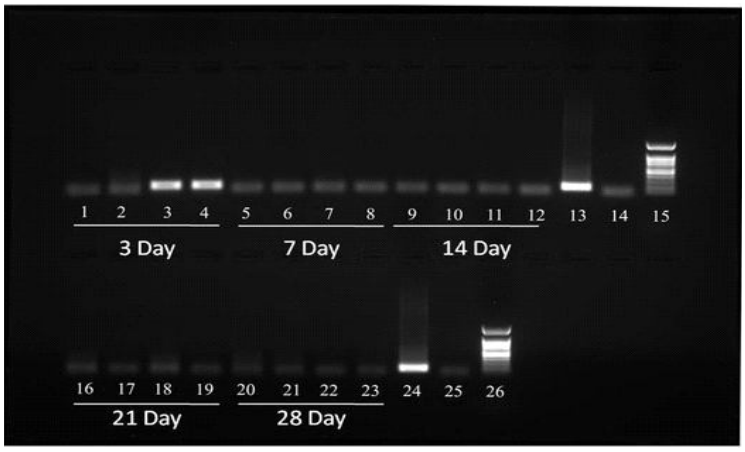

Lane 1,2, 5,6,9,10,16,17,20 and 21- (control group samples in duplicate), Lane 3,4,7,8,11,12,18,19,22 and 23 - (virus group samples in duplicate), Lane 3 and 4 - positive sample (virus group sample in duplicate), Lane 13 and 24 - Positive control (156 bp), Lane 14 and 25 - Negative control, Lane 15 and 26 - 100 bp DNA marker.

Fig 2: Agarose gel electrophoresis analysis for detection of KIRV in tissue samples (kidney and spleen) collected from control and virus groups of goldfish at 3, 7, 14, 21 and 28 dpi.

reisolated from the spleen and kidney of both experimental virus infected fish species common carp and rohu indicating that the virus could have been either eliminated by the fish or reduced the load that evaded detection using cell cultures (Kaviarasu *et al*., 2020). In the present study, cell culture assay revealed no cytopathic effect in the EPC (Epithelioma papulosum cyprini) cell line at any time points both for goldfish and tilapia species.

PCR detection

Variations in host susceptibility to different ranavirus pathogens create an ideal scenario for the pathogen to move between hosts, utilizing highly susceptible species and also low susceptible hosts for amplification and for persistence respectively (Gray *et al*., 2009). In the present study, target viral DNA was detected from the tissues of virus test group fish sampled at 3 dpi by PCR in goldfish and tilapia (Fig 2 and 3). In experiment with tilapia, the target viral DNA was also detected from the virus test group sampled at 7 dpi by PCR. However, specific DNA of KIRV could not be detected in tissues of experimental fish sampled at later experimental study periods. In a similar way, PCR detection of the infected fish tissues revealed the presence of viral DNA in the infected tissues such as the spleen and kidney of the koi (George *et al*., 2015). In the current study the virus was detected in the samples collected after 3 dpi from goldfish and in tilapia at 3 and 7 dpi indicating the virus was able to infect the fishes but had low pathogenicity so that the infection was subsequently got eliminated by the host species.

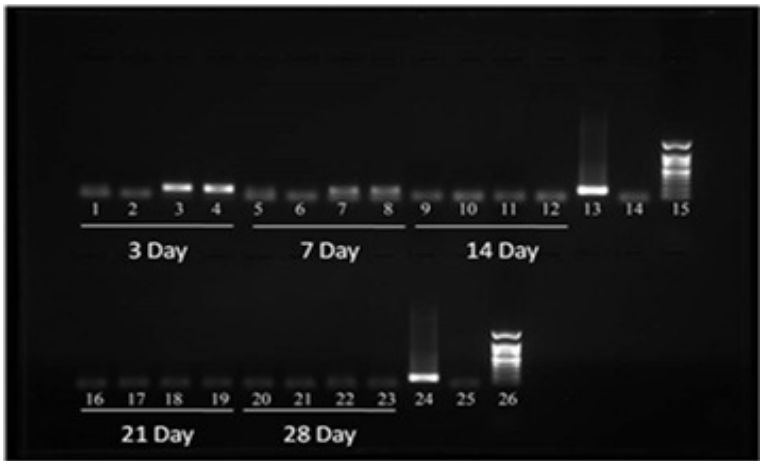

Lane 1,2, 5,6,9,10,16,17,20 and 21- (control group samples in duplicate), Lane 3,4,7,8,11,12,18,19,22 and 23 - (virus group samples in duplicate), Lane 3,4,7 and 8 - Positive sample - (virus group sample in duplicate), Lane 13 and 24 - Positive control (156 bp), Lane 14 and 25- Negative control, Lane 15 and 26- 100 bp DNA marker.

Fig 3: Agarose gel electrophoresis analysis for detection of KIRV in tissue samples (kidney and spleen) collected from control and virus groups of tilapia at 3, 7, 14, 21 and 28 dpi by PCR.

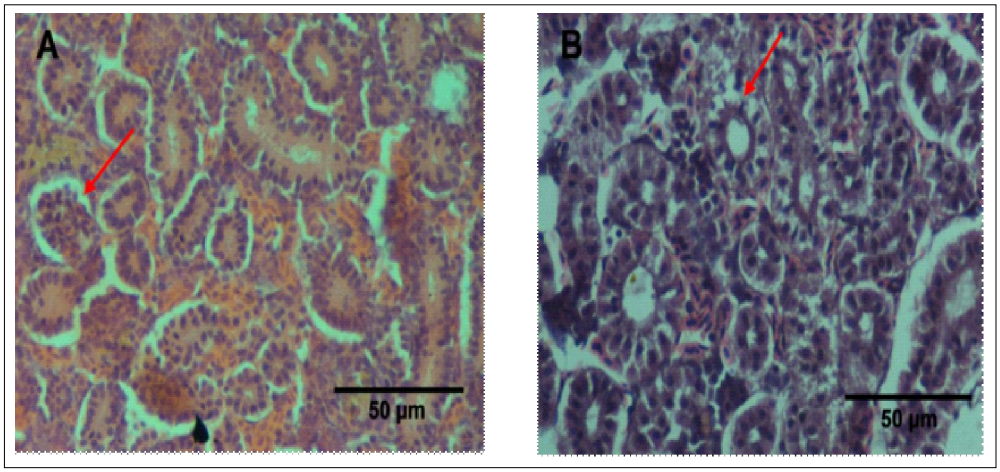

Fig 4: Focal necrosis, shrunken glomerulus and detached epithelium of tubules observed in kidney tissue of goldfish (virus group) at 3 (A) and 7 (B) dpi (scale bar = 50 µm).

Histopathological analysis

Haematopoietic tissues of the spleen and kidney, heart, intestine and gill tissues are important target organs for isolation of red sea bream iridovirus infection and the liver, kidney, spleen and other parenchymal tissues are target organs for isolation of EHNV infection (OIE, 2009). Zilberg *et al*. (2000) reported that the necrosis was observed in the gill tissue, gastrointestinal (GI) mucosal epithelium and heart of largemouth bass (*Micropterus salmoides*) and also for those fishes which are experimentally challenged with Santee Cooper ranavirus. Ranaviruses can cause acute and systemic diseases in fish by increasing severity resulting from haemorrhages on the skin and internal organs and necrosis of the spleen and kidney (Williams *et al*., 2005).

Our results of the histopathological study revealed focal necrosis, shrunken glomerulus and detached epithelium of tubules which were observed in kidney tissue of goldfish at 3 and 7 dpi (Fig 4). In tilapia, the experimental results showed melanomacrophage cells and focal necrosis of glomerulus and detachment of the epithelium of tubules in kidney tissue at 3 and 7 dpi (Fig 5). In tilapia

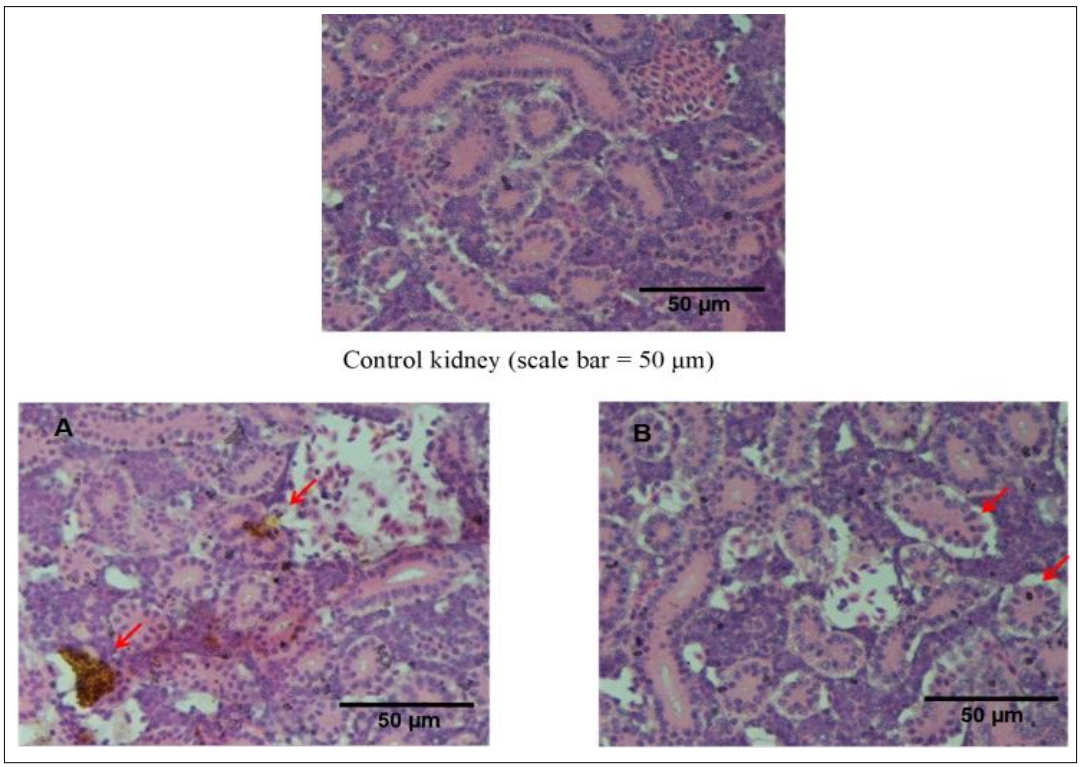

Fig 5: Melanomacrophage cells and focal necrosis of glomerulus and detachment of the epithelium of tubules observed in kidney tissue of tilapia (virus group) at 3 (A) and 7 (B) dpi (scale bar = 50 µm).

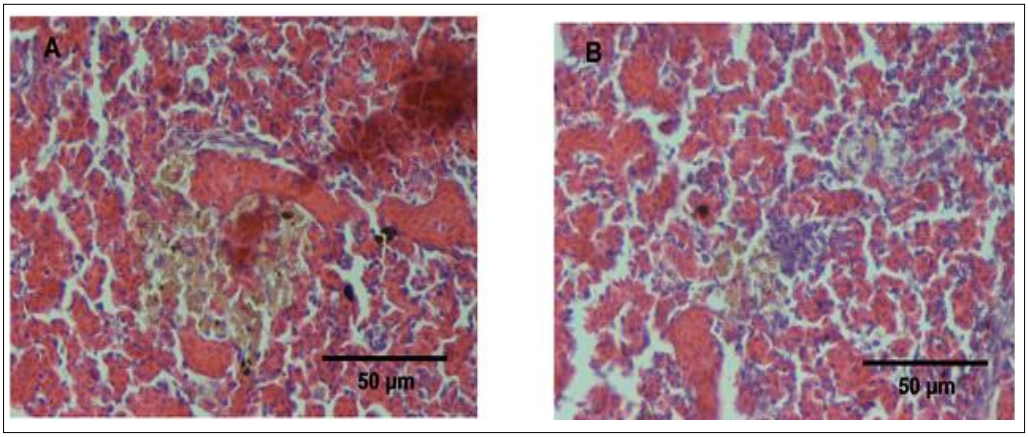

Fig 6: Melanomacrophage centers and necrosis observed in spleen tissue of goldfish (virus group) at 3 (A) and 7 (B) dpi (scale bar= 50 µm).

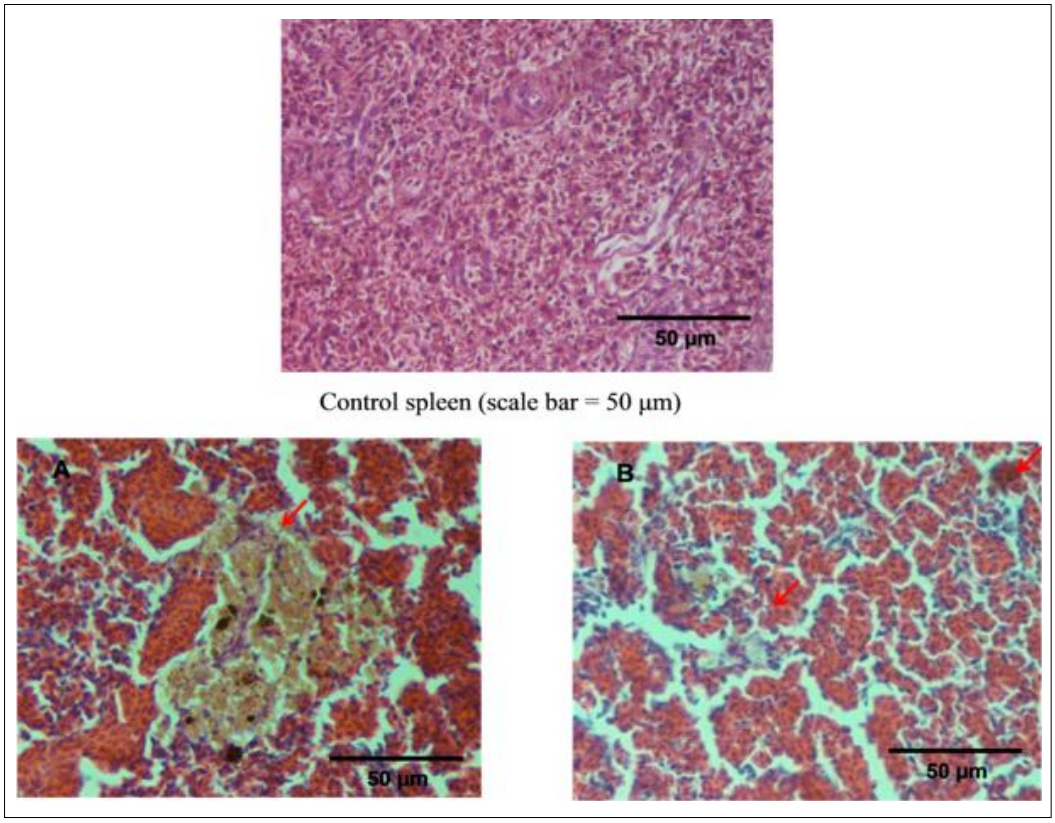

Fig 7: Melanomacrophage centers and necrosis observed in spleen tissue of tilapia (virus group) at 3 (A) and 7 (B) dpi (scale bar = 50 µm).

and goldfish, the experimental results showed melanomacrophage centers and necrosis in the spleen at 3 and 7 dpi (Fig 6 and 7). No typical histopathological changes were observed in the spleen of the experimental fishes at other time points. The reports indicated that there are 10 different families represented among the 14 host fish species which are potentially susceptible to EHNV infection but the its susceptibility does not appear to be associated with its taxonomic relationships (Bang-Jensen *et al*., 2011).

CONCLUSION

The present study was carried out to determine the experimental transmission and pathogenicity of koi ranavirus (KIRV) to goldfish (*Carassius auratus* L.) and tilapia (*Oreochromis niloticus* L.). This study reported that there is no gross mortality or any specific external pathological changes observed in goldfish and tilapia fingerlings following experimental infection with KIRV and also experimental study indicates that goldfish and tilapia are not susceptible species to KIRV infection.

ACKNOWLEDGEMENT

The study formed the part of the Ph.D thesis of the first author. The authors are grateful to the National Surveillance programme for Aquatic Animal Diseases (sub project no - 21) ICAR-NBFGR, Lucknow for the funding support to carry out the study.

Conflict of interest

All authors declare that they have no conflict of interest.

REFERENCES

Allen, A.G., Morgans, S., Smith, E., Aron, M.M., Jancovich, J.K. (2017). The Ambystoma tigrinum virus (ATV) RNase III gene can modulate host PKR activation and interferon production. *Virology*. **511:** 300-308.

Amos, K.H. (1985). Procedures for the Detection and Identification of Certain Fish Pathogens, 3rd Ed. Fish Health Section, American Fisheries Society, Bethesda, MD.

Bang Jensen, B., Holopainen, R., Tapiovaara, H. (2011). Susceptibility of pike-perch *Sander lucioperca* to a panel of ranavirus isolates. *Aquaculture*. **313:** 24-30.

Chinchar, V.G., Yu, K.H., Jancovich, J.K. (2011). The molecular biology of frog virus 3 and other iridoviruses infecting cold-blooded vertebrates. *Journal of Virology*. **3:** 1959-1985.

George, M.R., John, K.R., Mansoor, M.M., Saravanakumar, R., Sundar, P., Pradeep, V. (2015). Isolation and characterization of a ranavirus from koi, *Cyprinus carpio* L., experiencing mass mortalities in India. *Journal of Fish Diseases*. 38: 389-403.

Gobbo, F., Cappellozza, E., Pastore, M.R., Bovo, G. (2010). Susceptibility of black bullhead *Ameiurus melas* to a panel of ranavirus isolates. Diseases of Aquatic Organisms. **90:** 167-174.

Gray, M.J., Miller, D.L., Hoverman, J.T. (2009). Ecology and pathology of amphibian ranaviruses. *Diseases of Aquatic Organisms*. **87:** 243-266.

Harp, E.M., Petranka, J.W. (2006). Ranavirus in wood frogs (*Rana sylvatica*): Potential sources of transmission within and between ponds. *Journal of Wildlife Diseases*. **42:** 307-318.

Haydon, D.T., Cleaveland, S., Taylor, L.H., Laurenson, M.K. (2002). Identifying reservoirs of infection: A conceptual and practical challenge. *Emerging Infectious Diseases*. **8:** 1468-1473.

Holopainen, R., Tapiovaara, H., Honkanen, J. (2012). Expression analysis of immune response genes in fish epithelial cells following ranavirus infection. *Fish and Shellfish Immunology*. **32:** 1095-1105.

Jancovich, J.K., Chinchar, V.G., Hyatt, A., Miyazaki, T., Williams, T., Zhang, Q.Y., (2012). Family *Iridoviridae*. In: Virus Taxonomy: Ninth Report of the International Committee on Taxonomy of Viruses. [King, A.M.Q., Adams, M.J., Carstens, E.B. and Lefkowitz, E.J. (eds)] Elsevier, San Diego, EE.UU. pp. 193-210.

Kaviarasu, D., John, K.R., George, M.R., Ahilan, B., Padmavathy, P., Petchimuthu, M. (2020). Experimental infection with Koi ranavirus (KIRV) of common carp (*Cyprinus carpio* L.) and rohu (*Labeo rohita* H.). *International Journal of Current Microbiology and Applied Sciences*. **9:** 3234-3243.

Miller, D.L., Gray, M.J., Rajeev, S. (2009). Pathological findings in larval and juvenile anurans inhabiting farm ponds in Tennessee, USA. *Journal of Wildlife Diseases*. **45:** 314-324.

OIE, (2009). Red Sea Bream Iridoviral Disease. In Manual of Diagnostic Tests for Aquatic Animals 2012, Edited by the World Organisation for Animal Health (OIE). Paris, OIE. pp. 345-356.

Pearman, P.B., Garner, T.W., Straub, M., Greber, U.F. (2004). Response of the Italian agile frog (*Rana latastei*) to a Ranavirus, frog virus 3: A model for viral emergence in naive populations. *Journal of Wildlife Diseases*. **40:** 660-669.

Robert, J., George, E. andino, F.D.J., Chen, G. (2011). Waterborne infectivity of the Ranavirus frog virus 3 in *Xenopus laevis*. *Virology*. **417:** 410-417.

Shefat, S.H.T. (2018). Vaccines for Use in Finfish Aquaculture. *Acta Scientific Pharmaceutical Sciences*. **2:** 15-19.

Sivasankar, P, John, K.R., George, M.R., Mageshkumar, P., Manzoor, M.M., Jeyaseelan, M.P. (2017). Characterization of a virulent ranavirus isolated from marine ornamental fish in India. *Virus Disease*. **28:** 373-382.

Williams, T., Barbosa-Solomieu, V., Chinchar, V.G. (2005). A decade of advances in iridovirus research. *Advances in Virus Research.* **65:** 173-248.

Zilberg, D., Grizzle, J.M., Plumb, J.A. (2000). Preliminary description of lesions in juvenile largemouth bass injected with largemouth bass virus. *Diseases of Aquatic Organisms*. **39:** 143-146.