RESEARCH ARTICLE Indian Journal of Animal Research, Volume 57 Issue 4: 436-442 (April 2023)

Histomorphological Study of Thymus in Japanese Quail (*Coturnix coturnix japonica*)

S.D. Kadam[1], J.Y. Waghaye[1], P.N. Thakur[1]

10.18805/IJAR.B-4796

ABSTRACT

Background: Thymus is the primary lymphoid organ in avian. It is a site of differentiation and maturation of T lymphocytes. Quail thymus showed age related involution with decrease in its volume and cellular contents. It is a lymphoepithelial organ and thus plays a major role in the anti-infection defense mechanism.

Methods: For the present study 48 Japanese quail birds reared and thymus was collected from 12 birds each at end of first week, second week, third week and fourth week. The tissue was processed for routine paraffin embedding and processed for different staining procedures for histomorphological studies.

Result: In all age group of birds, each thymic lobe was enclosed by thin connective tissue capsule. Thymic lobule was found to be composed of outer cortex and inner medulla. Cortex was composed of lymphocytes, lymphoblasts, myoid cells, macrophages, plasma cells and epithelial reticular cells and that of medulla was composed of lymphocytes, lymphoblast, epithelial reticular cells, myoid cells, macrophages, plasma cells, cyst and Hassall's corpuscles. The cyst of various shapes and sizes were observed in cortex and medulla. In all age group of birds, unilamilar and multilamilar Hassall's corpuscles were observed. Number of Hassall's corpuscles and macrophages were increased with the advancement of age.

Key words: Cortex, Hassall's Corpuscles, Histomorphology, Japanese quail, Medulla, Thymus.

INTRODUCTION

Japanese quail (*Coturnix coturnix japonica*) is catching attention in poultry industry due to its low fat, soft meat and fast growing bird. Apart from this, low maintenance cost along with its small body size, short generation interval *and* considerable resistance to disease quail an excellent laboratory animal (Oguz and Minvielle, 2001).

The poultry immune system comprised of primary and secondary lymphatic organs. Thymus is the primary lymphoid organ in avians (Gulmez and Aslan, 1999). Thymus is a site of differentiation and maturation of T lymphocytes (Song *et al.*, 2012). Quail thymus showed age related involution with decrease in its volume and cellular contents (Ciriaco *et al.*, 2003). Thymus is a lymphoepithelial organ and thus plays a major role in the anti-infection defense mechanism. Structure of thymus differs from one another among different birds by the amount of lobes it includes (Gulmez and Aslan, 1999). The histoarchitecture of normal thymus may serve as a reference for pathological condition, guideline for control strategies against biotic and abiotic diseases and diagnosis of diseases with immunodeficiency. Considering the importance and histoarchitectural alterations of thymus with advancement of age, the present study is under taken.

The principle objective of the research is to study histological changes in thymus of Japanese quail at different age groups.

MATERIALS AND METHODS

Place of research work

The present study was conducted in the Department of Veterinary Anatomy and Histology, College of Veterinary and Animal Sciences, Parbhani. The study was carried out in the year 2019.

[1]Department of Veterinary Anatomy and Histology, College of Veterinary and Animal Sciences, Maharashtra Animal and Fishery Sciences University, Parbhani-431 402, Maharashtra, India.

Corresponding Author: S.D. Kadam, Department of Veterinary Anatomy and Histology, College of Veterinary and Animal Sciences, Maharashtra Animal and Fishery Sciences University, Parbhani-431 402, Maharashtra, India. Email: shrikant430@gmail.com

How to cite this article: Kadam, S.D., Waghaye, J.Y. and Thakur, P.N. (2023). Histomorphological Study of Thymus in Japanese Quail (*Coturnix coturnix japonica*). Indian Journal of Animal Research. 57(4): 436-442. doi: 10.18805/IJAR.B-4796.

Submitted: 01-10-2021 **Accepted:** 31-01-2022 **Online:** 19-04-2022

Collection of samples

For the present study 48 Japanese quail birds (*Coturnix coturnix japonica*) irrespective of sex reared on poultry farm of College of Veterinary and Animal Sciences, Parbhani under standard managemental quail rearing practices. The thymus was collected from 12 birds each at end of first week, second week, third week and fourth week. These birds are sacrificed by cranial subluxation. The thymus was excised by ventro-lateral neck dissection. Quail thymus start to become involved from fourth weeks of age (Gulmez and Aslan, 1999).

Processing of samples

The collected organ was washed with normal saline and fixed in 10% neutral buffered formalin, 10% formal saline,

Bouin's fluid and Baker's Formal Calcium. Then the tissue was processed for routine paraffin embedding. Sections of 5 µm thickness were taken and processed for following staining procedures for histomorphological studies.

1. Haematoxylin and Eosin for normal histoarchitectural study.
2. Masson's trichrome method for collagen and muscle fibers.
3. Gomori's reticulin method for reticular fibers.
4. Verhoeff's elastic stain for elastic fibers.

RESULTS AND DISCUSSION

During the present study, grossly it was observed that the thymus was present as a series of separated lobes within the adipose tissue. Histomorhologically, in all age group of birds, each thymic lobe was enclosed by thin connective tissue capsule of uneven thickness (Fig 1). The present observations confirm the reports made by (Haseeb *et al*., 2014) in Aseel chicken, (Khalil *et al*., 2003) in chicken and (Senapati *et al*., 2015) in quail, chicken and duck. They reported that the thin connective tissue capsule of thymic lobes gives rise to septa to divide lobes in to lobules. Similar reports were also made by (Treesh *et al*., 2014) in chicken, Gulamez and Aslan (1999) in Geese, (Song *et al*., 2012) in ostrich chick and (Davison *et al*., 2008) in avian. The findings of the present study regarding the components of thymic capsule and septa and lobulation is in accordance with those reported by (Ali *et al*., 2016) in turkey, El-Zoghby and Attia (2007) in ostrch and (Tamilselvan *et al*., 2017) in guinea fowl. These workers reported that capsule and vascularised speta was mainly composed of collagen and reticular fibres.

The each thymic lobule during the present study was found to be composed of outer basophilic stained cortex and inner acidophilic stained medulla in all age group of birds (Fig 2). This observation is in line with earlier reports made by Hashimoto and Sugimura (1976) in pekin duck, Gulmez and Aslan (1999) in Geese, (Ciriaco *et al.,* 2003) in avian, El-Zoghby and Attia (2007) in ostrich, (Davison *et al*., 2008) in avian, (Treesh *et al*., 2014) in chicken, (Haseeb *et al*., 2014) in Aseel chicken, (Ali *et al*., 2016) in turkey, (Tamilselvan *et al*., 2017) in guinea fowl and (Senapati *et al*., 2015) in quail, chicken and duck.

The cortex of each lobule was predominantly composed of densely populated small lymphocytes with medium lymphocytes, lymphoblasts and few numbers of epithelial reticular cells. The epithelial reticular cells were comparatively larger with spherical to oval euchromatic nucleus and widely spread in the cortex. The evident of mitotic activity was found among the cortical cellular

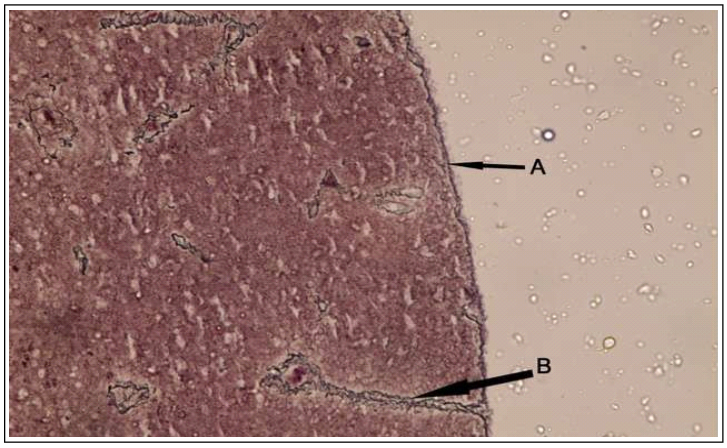

Fig 1: Photomicrograph of thymus in group II showing-A. Capsule; B. Cortical connective tissue strand (Gomori's Reticulin, × 400).

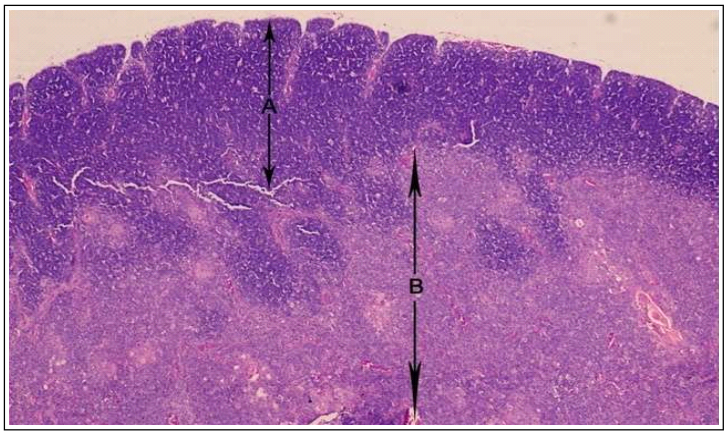

Fig 2: Photomicrograph of thymus in group II showing-A. Cortex; B. Medulla (Haematoxylin and Eosin, × 100).

population in all age group of birds under present study (Fig 3). This observation is in agreement with the findings reported by (Haseeb *et al.,* 2014) and (Treesh *et al.,* 2014) in chicken. They reported that cortex was enriched with lymphocytes. Gilmore and Bridges (1974) in fowl and Hashimoto and Sugimura (1976) in pekin duck reported the numerous densely packed small lymphocytes in cortex within meshwork of epithelial reticular cells. In addition, (Tamliselvan *et al.,* 2017) in guinea fowl presence of medium lymphocytes and El- Zoghby and Attia (2007) in ostrich mentioned the presence of lymphoblasts in the cortex.

During the present study, few myoid cells, macrophages and plasma cells were observed in the thymic cortex of all age group birds (Fig 3). The macrophages and plasma cells were very few at age group of one week, however their population was found to be increase with the advancement of age. Present observations are also in accordance with the (Tamliselvan *et al.*, 2017) in guinea fowl and Gulmez and Aslan (1999) in Geese. In agreement with the present findings, (Tamliselvan *et al.,* 2017) reported increase in number of plasma cells with the advancement of age.

During the present work, it was observed that, thin connective tissue strands extended from interlobular connective tissue septa in to the each lobular parenchyma up to the corticomedullary junction. These connective tissue strands carried the blood vessels up to the corticomedullary junction. From group II age of birds, the connective tissue strands found to be more prominent with the advancement of age and divided the cortical tissue in compartments giving lobular appearance to thymic cortex (Fig 1). In agreement with this finding, (Treesh *et al.,* 2014) in chicken reported the presence of blood capillaries at the corticomedullary junction. The observation of the present study confirms the report made by (Davison *et al.,* 2008) in Avian. They reported that the invasion of the connective tissue septa resulted in to the thymic cortical lobulation.

The medulla was composed of cellular population of lymphocytes, lymphoblast, epithelial reticular cells, myoid

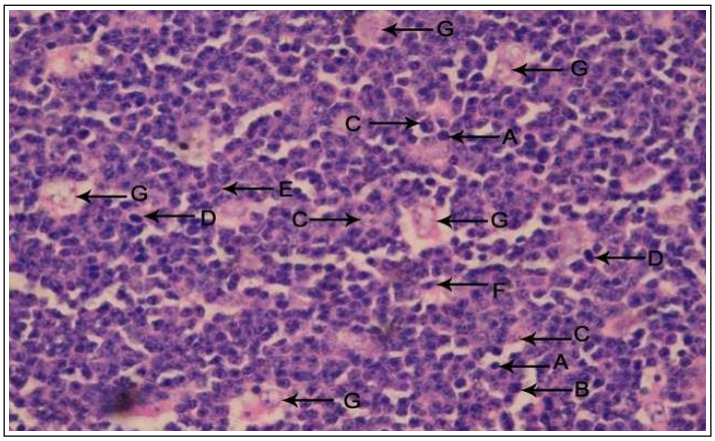

Fig 3: Photomicrograph of thymic cortex in group IV showing-A. Small lymphocyte; B. Lymphoblast; C. Reticular cells; D. Macrophages; E. Plasma cells; F. Myoid cells; G. Hypertrophied epithelial reticular cells in vacuoles (Haematoxylin and Eosin, × 1000).

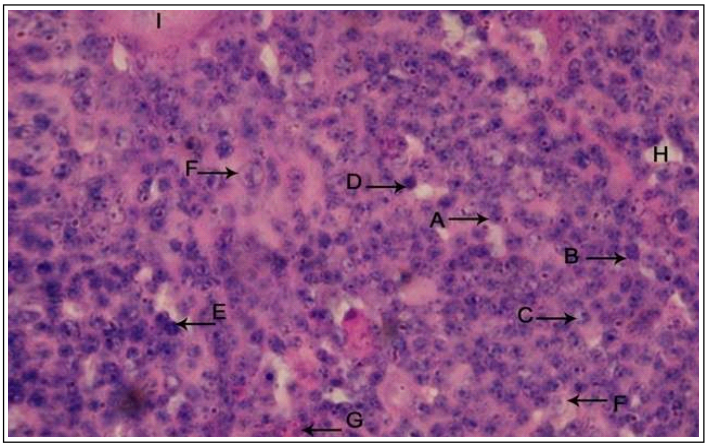

Fig 4: Photomicrograph of thymic medulla in group I showing-A. Lymphocyte; B. Lymphoblast; C. Reticular cells; D. Macrophages; E. Plasma cells; F. Hypertrophied epithelial reticular cells; G. Myoid cells (Haematoxylin and Eosin, × 1000); H. Cyst I. Hassall's corpuscles.

cells, macrophages, plasma cells and structures like cyst and Hassall's corpuscles (Fig 4). This is in line with the reports made by (Tamilselvan *et al*., 2017) in guinea fowl, (Haseeb *et al*., 2014) in chicken and Hashimoto and Sugimura (1976) in pekin duck. These workers reported the similar components of the thymic medulla.

The epithelial reticular cells were more in number and larger with spherical to ovoid vacuolated nucleus as compared to epithelial reticular cells of cortex. The increase in number of hypertrophied epithelial reticular cells was found to be increase with the advancement of age (Fig 5). In agreement with the present findings, El-Zoghby and Attia (2007) in ostrich, Ali (2016) in Turkey, (Tamilselvan *et al*., 2017) in guinea fowl, Gilmore and Bridges (1974) in fowl and (Davison *et al*., 2008) in avian reported more number of epithelial reticular cells in the thymic medulla.

The myoid cells were found to be more in the medulla as compared to the cortex. The medullary myoid cells showed the same characteristic structures as observed in the cortex (Fig 5). Similar observations were also made by Hashimoto and Sugimura (1976) in pekin duck and Gilmore and Bridges (1974) in fowl, who they reported more number of myoid cells in medulla than the cortex.

The number of macrophages and few plasma cells were found in the medulla. It was observed that the number of macrophages and plasma cells in thymic medulla increased with the advancement of age (Fig 5). This observation is in concurrence with the findings of (Treesh *et al*., 2014) in chicken.

The increase in number of macrophages with the advancement of age may be attributed to the necessity of more number of macrophages to remove the degenerative cellular debris.

During the present work, the cyst of various shapes and sizes were observed in cortex and medulla of all age group of birds. The cysts were characterized by the presence of flattened epithelial wall surrounded by degenerative cells. It was observed that, group of cyst coalesced to form the larger cysts (Fig 6 and 7). These observations are in agreement with the findings reported by (Kannan *et al.,* 2015)

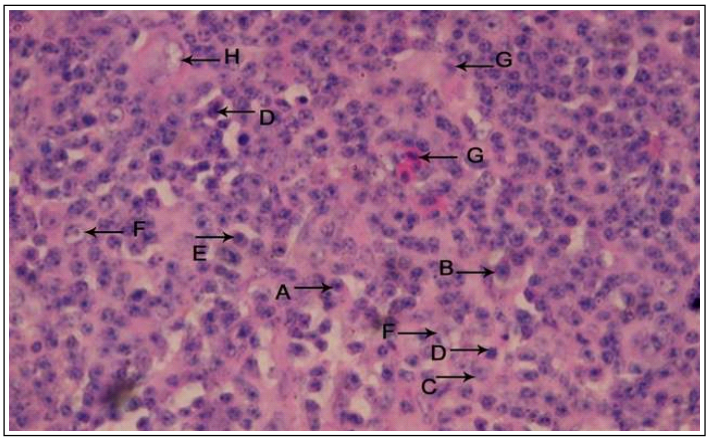

Fig 5: Photomicrograph of thymic medulla in group IV showing-A. Lymphocyte; B. Lymphoblast; C. Reticular cells; D. Macrophages; E. Plasma cells; F. Hypertrophied epithelial reticular cells; G. Myoid cells; H. Formation of Hassall's corpuscles (Haematoxylin and Eosin, × 1000).

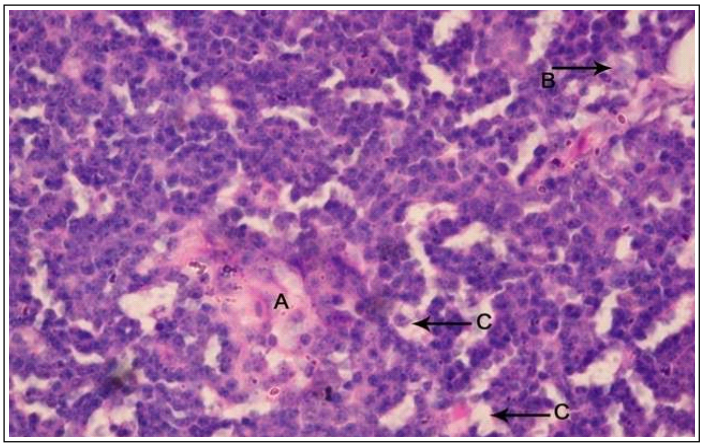

Fig 6: Photomicrograph of thymic cortex in group II showing-A. Cyst; B. Hypertrophied epithelial reticular cell in vacuole; C. Vacuole (Haematoxylin and Eosin, × 1000).

in fowl. Hashimoto and Sugimura (1976) in Pekin duck reported the similar morphology of cyst. (Tamilselvan *et al.,* 2017) in Guinea fowl reported more number of cysts of varied shape and size.

In all age group of birds, the Hassall's corpuscles in various stages of development and form were observed. In all age group of birds, unilamilar and multilamilar Hassall's corpuscles were observed. In unilamilar Hassall's corpuscles, a single layer of flattened epithelial reticular cell around the central acidophilic mass or degenerating epithelial reticular cell. The multilamilar Hassall's corpuscles were characterized by two or more concentric layers of flattened keratinized

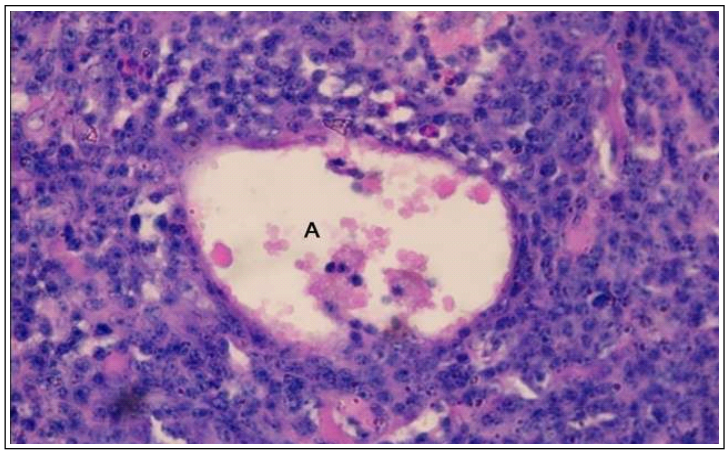

Fig 7: Photomicrograph of thymic medulla in group II showing-A. Cyst (Haematoxylin and Eosin, × 1000).

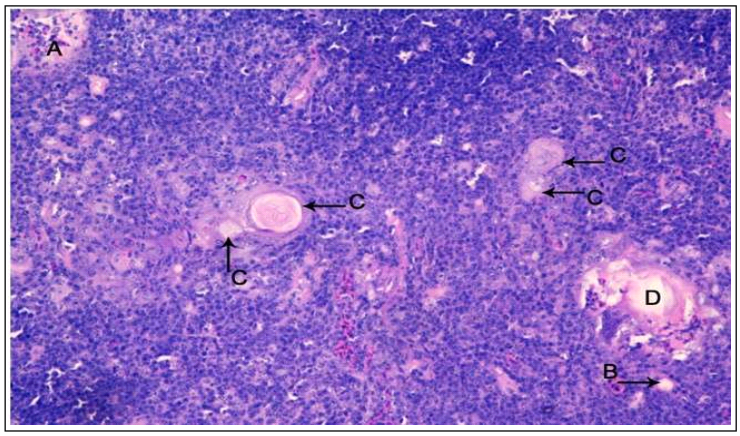

Fig 8: Photomicrograph of thymic corticomedullary region in group III showing-A. Cyst; B. Vacuole; C. Unilamilar Hassall's corpuscle; D. Multilamilar Hassall's corpuscle (Haematoxylin and Eosin, × 400).

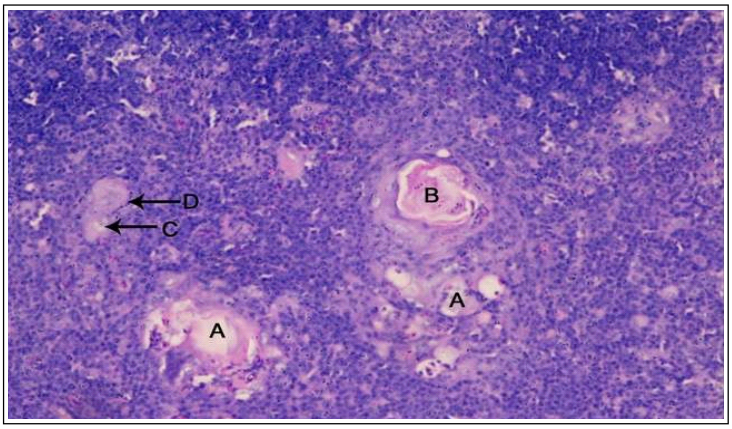

Fig 9: Photomicrograph of thymic medulla in group IV showing-A. Cyst; B. Multilamilar Hassall's corpuscle; C. Hypertrophied epithelial reticular cells; D. Newly formed unilamilar Hassall's corpuscle (Haematoxylin and Eosin, × 400).

epithelial reticular cells or other cells around the central degenerating acidophilic mass (Fig 8 and 9).

The coalition of two or more developing or unilamilar Hassall's corpuscles to form the large multilamilar Hassall's corpuscles was observed in all age group of birds (Fig 8 and 9).

In the present study, the Hassall's corpuscles associated with one or more cysts were observed in all age group of birds. These cysts subsequently increased in size or merged with each other to form larger cysts around the Hassall's corpuscles (Fig 10).

These observations of the present findings are in line with reports made by (Kannan *et al.,* 2015) in fowl, Gulmez and Aslan (1999) in Geese, (Tamilselvan *et al.,* 2017) in Guinea fowl, Hashimoto and Sugimura (1976) in Pekin duck and (Senapati *et al.,* 2015) in quail, chicken and duck. These workers reported the similar morphology of Hassall's corpuscles. In agreement with the present observation, Hashimoto and Sugimura (1976) in Pekin duck, (Treesh *et al.,* 2014) in chicken, (Haseeb *et al.,* 2014) in Aseel chicken and (Kannan *et al.,* 2015) in fowl reported the increase in number of Hassall's corpuscles with the advancement of age.

The increase in number of Hassall's corpuscles and macrophages with the advancement of age recorded during the present study may be attributed to the increased function for destruction of self-antigen responsive lymphocytes by the process of apoptosis to generate tolerance and necessity of more number of macrophages to digest the debris of large number of apoptotic lymphocytes.

The infiltration of cortical cells in to the medulla was observed from group III age of birds (Fig 11). This cortical infiltration along with increase in number of Hassall's corpuscles with the advancement of age may be indicative of start of regressive changes in thymus.

Similarly, the increase in medullary vascularisation and presence of lymphocytes in the lumen of vein as well as infiltration of cortical cells in to the medulla with the advancement of age during the present study indicated the differentiation of more lymphocytes in the cortex and their migration to the peripheral circulation or to the secondary lymphoid organs.

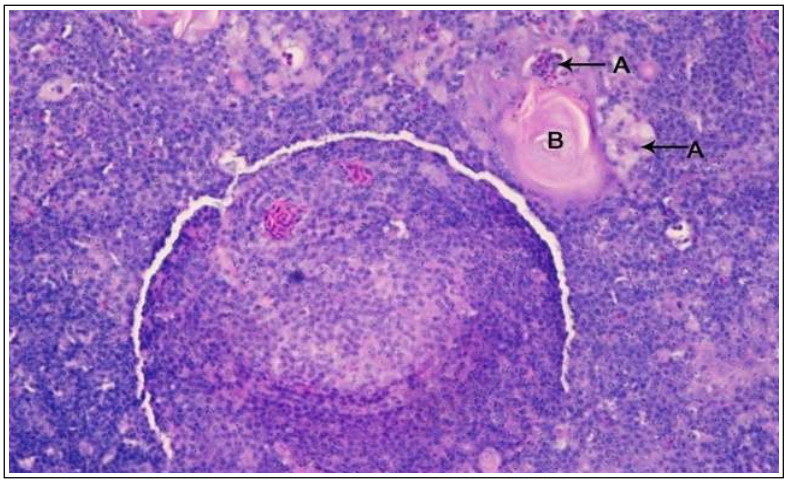

Fig 10: Photomicrograph of thymic corticomedullary region in group II showing-A. Cyst; B. Hassall's corpuscle; (Haematoxylin and Eosin, × 400).

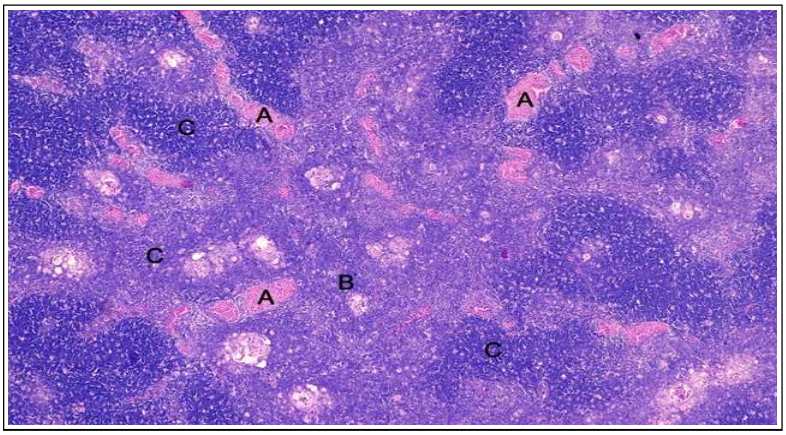

Fig 11: Photomicrograph of thymic medulla in group III showing-A. Vessel; B. Medulla; C. Infiltration of cortical tissue (Haematoxylin and Eosin, × 400).

CONCLUSION

Each thymic lobule composed of outer cortex and inner medulla in all age group of birds. Cellular population of the cortex was composed of lymphocytes, lymphoblasts, myoid cells, macrophages, plasma cells and epithelial reticular cells. The mitotic activity was evident among the cortical cellular population indicated the active involvement of thymic tissue in the lymphopoiesis in all age group of birds. The medulla of each thymic lobule was composed of cellular population as of cortex along with cyst and Hassall's corpuscles. The epithelial reticular cells were more and larger than epithelial reticular cells of cortex. There was increase in the number of macrophages with the advancement of age may be attributed to the necessity to remove the degenerative cellular debris. The cyst of various shapes and sizes were observed in cortex and medulla of all age group characterized by the presence of flattened epithelial wall surrounded by degenerative cells. These group of cyst coalesced to form the larger cysts. In all age group of birds, unilamilar and multilamilar Hassall's corpuscles were observed. Number of Hassall's corpuscles were increased with the advancement of age. The cortical infiltration along with increase in number of Hassall's corpuscles with the advancement of age may be indicative of start of regressive changes in thymus.

Conflict of interest: None.

REFERENCES

Ali, H.K. (2016). Anatomical and Histological Study of Thymus Gland in the Local Breed of Turkey "*Meleagris gallopavo"* in Iraq. 3rd Scientific Conference, College of Veterinary Medicine, University of Tikrit, 2-3 May: 93-97.

Ciriaco, E., Pinera, P.P., Esnal, B.D. and Laura, R. (2003). Age-related changes in the avian primary lymphoid organs (Thymus and Bursa of Fabricius). Microscopy Research and Technique. 62: 482-487.

Davison, F., Kaspers, B. and Schat, K.A. (2008). Avian Immunology, 1st Edn., London, UK: Academic Press Publication, Elsevier Ltd., Sa Diego.15-32.

El-Zoghby, I.M.A. and Attia, H.F. (2007). Fine Structure of the Thymus Gland in Ostrich (*Struthio camelus* L). The 31th Scientific Conference of the Egyptian Society of Histology and Cytology. 1-16.

Gilmore, R.S.C. and Bridges, J.B. (1974). Histological and ultrastructural studies on the myoid cells of the thymus of the domestic fowl, Gallus domesticus. J. Anat. 118(3): 409-416.

Gulmez, N. and Aslan, S. (1999). Histological and histometrical investigations on bursa of fabricius and thymus of Native Geese. Turk. J. Vet. Anim. Sci. 23: 163-171.

Haseeb, A., Shah, M.G., Gandahi, J.A., LOchi, G.M., Khan, M.S., Faisal, M., Kiani, F.A., Mangi, R.A. and Oad, S.K. (2014). Histo-morphological study on Thymus of Aseel chicken. J. Agric. Food. Tech. 4(2): 1-5.

Hashimoto, Y. and Sugimura, M. (1976). Histological and quantitative studies on the postnatal growth of the thymus and bursa of fabricius of white pekin ducks. Japanese J. of Vet. Res. 24: 65-76.

Kannan, T.A., Ramesh, G., Ushakumary, S., Dhinakarraj, G. and Vairamuthu, S. (2015). Thymic Hassall's corpuscles in Nandanam chicken - light and electron microscopic perspective (*Gallus domesticus*). Journal of Animal Science and Technology. 57: 30. https://doi.org/10.1186/s40781-015-0064-2.

Khalil, M., Khan, Z.I., Khalil, M. and Islam, R. (2003). A prospective study of prenatal and postnatal development of thymus of Deshi chicken. Mymensingh Med. J. 12(1): 20-24.

Oguz, I. and Minvielle, F. (2001). Effects of Genetics and Breeding on Carcass and Meat Quality of Japanese Quail. A Review. Proceedings of XV European Symposium on the Quality of Poultry Meat, WPSA Turkish Branch, 9-12 Sept 2001, Kusadasi- Turkey. http://www.sciencepub.net/newyork.

Senapati, M.R., Behera, P.C., Maity, A. and Mandal, A.K. (2015). Comparative histomorphological study on the thymus with reference to its immunological importance in quail, chicken and duck. Explor Anim. Med. Res. 5(1): 73-77.

Song, H., Peng, K., Li, S., Wang, Y., Wei, L. and Tang, L. (2012). Morphological characterization of the immune organs in ostrich chicks. Turk. J. Vet. Anim. Sci. 36(2): 89-100.

Tamilselvan, S., Balasundaram, K. and Jayachitra, S. (2017). Histomorphology of thymus gland in Guinea fowl (*Numida meleagris*). Int. J. Curr. Microbiol. App. Sci. 6(5): 1076-1083.

Treesh, S.A., Buker, A.O. and Khair, N.S. (2014). Histological, histochemical and immunohistochemical studies on thymus of chicken. International Journal of Histology and Cytology. 1(11): 103-111.