RESEARCH ARTICLE Indian Journal of Animal Research, Volume 59 Issue 9: 1575-1578 (September 2025)

Surgical Management of Mechanical Intestinal Ileus under Right Paravertebral Nerve Block and Lignocaine Continuous Rate of Infusion in Cattle

P. Vidya Sagar[1], S. Kathirvel[1], S. Dharmaceelan[1], S. Sivaraman[1], S. Jayachandran[1]

10.18805/IJAR.B-4804

ABSTRACT

Background: Mechanical intestinal ileus is an abdominal emergency that is potentially life threatening in cattle. Early diagnosis and surgical correction is challenging for clinician under field conditions. Successful outcome depends upon effective management of visceral pain during surgical procedure and restoration of early intestinal motility. The present study is aimed to study the quality of visceral analgesia using right paravertebral nerve block and lignocaine continuous rate of infusion in standing surgery and prokinetic effect of azithromycin.

Methods: The present work was carried out from April 2019 to September 2021, in 6 cattle presented to the veterinary clinical complex, veterinary college and research institute, Namakkal with a history of not voiding the dung. In all the cases, clinical, haematological, biochemical, ultrasonographic, anaesthetic, prokinetic evaluation and surgical management was performed.

Result: In the present study, inclusion of lignocaine as intravenous bolus @ 2 mg/kg body weight and continuous rate infusion (CRI) dose of 50 µg/kg/min produced good quality of visceral analgesia and no animal was recumbent intraoperatively. Prokinetic action of azithromycin was found effective to control the post-operative ileus in intestinal surgical procedures.

Key words: Azithromycin, Cow, Lignocaine CRI, Mechanical intestinal ileus.

INTRODUCTION

Intestinal ileus is an abdominal emergency that is potentially life threatening in cattle. If not treated in appropriate time, it is a menace to the both clinician and animal owners due to its confusing symptoms and sustainable economic loses, respectively (Braun *et al.,* 1993).

Mechanical intestinal ileus is the major cause of intestinal obstruction which occurs due to wide variety of causes which includes luminal and extra luminal obstruction such as complicated hernias, faecoliths, volvulus, mesenteric torsion, caecal dilatation, intussusception, abscess and tumors. It is an emergency surgical condition which results in to death very quickly due to the secondary changes caused by obstruction. The present paper reports clinical, haemato biochemical, ultrasonographic, anaesthetic evaluation, prokinetic effect of azithromycin and surgical management of mechanical intestinal ileus in 6 cows.

MATERIALS AND METHODS

The present work was carried out from April 2019 to September 2021, in cattle presented to the veterinary clinical complex, veterinary college and research institute, Namakkal with a history of not voiding the dung. After thorough screening, using physical, clinical and ultrasonographic examination, 6 animals with mechanical intestinal ileus, were selected and prepared for standing right flank laparotomy as per the standard procedure. Anaesthesia of surgical site was achieved by right paravertebral nerve block (Farquharson technique) using 2% lignocaine. Intravenous bolus dose of lignocaine hydrochloride @ 2 mg/kg body weight was administered 15 min prior to the surgical procedure and maintained with lignocaine CRI dose @ 50 µg/kg/min intraoperatively. Thorough abdominal exploration was performed to localize the lesion and correlated with the ultrasonographic observations. Intestinal obstruction was corrected by suitable surgical procedure such as enterectomy and end-to- end enteroanastamosis (n=5) and typhlotomy (n=1). In all the cases, haemato-bio chemical alterations were studied which includes packed cell volume (PCV), haemoglobin (Hb), total leucocyte count (TLC), total erythrocyte count (TEC), total protein (TP), albumin, calcium (Ca), phosphorous (P), sodium (Na), potassium (K) and chloride (Cl). Post operatively all the animals were treated with a prokinetic dose of Inj. Azithromycin @ 1 mg/kg bwt

[1]Department of Veterinary Surgery and Radiology, Veterinary College and Research Institute, Namakkal-637 002, Tamil Nadu, India.

Corresponding Author: P. Vidya Sagar, Department of Veterinary Surgery and Radiology, Veterinary College and Research Institute, Namakkal-637 002, Tamil Nadu, India.
Email: doctorpentyala@gmail.com

How to cite this article: Sagar, P.V., Kathirvel, S., Dharmaceelan, S., Sivaraman, S. and Jayachandran, S. (2025). Surgical Management of Mechanical Intestinal Ileus under Right Paravertebral Nerve Block and Lignocaine Continuous Rate of Infusion in Cattle. *Indian Journal of Animal Research*. **59(9):** 1575-1578. doi: 10.18805/IJAR.B-4804.

Submitted: 12-10-2021 **Accepted:** 22-04-2022 **Online:** 06-07-2022

intravenously and dung voiding time was recorded. All the animals administered with inj. Streptopenicillin 5 g IM, Inj. Chlorpheneramine malate @ 0.5 mg/kg for 5 days and Inj. Flunixin megludyne @ 2.2 mg/kg IM for 3 days. With holding of feed for 48 hours was advised and intravenous fluid therapy included Calcium borogluconate, Ringers lactate and Dextrose normal saline to correct the electrolyte imbalances and to avoid the post-operative functional ileus for 5 days.

RESULTS AND DISCUSSION

In the present study, average time of presentation of the cases to the veterinary clinical complex was 72 hrs (range 2-5 days). Animals with delayed presentation and recumbent animals with poor prognosis were not included in the present study. The mean age of the animals with intestinal obstruction was 4 yr (3-6). Prominent clinical signs observed were anorexia, suspended rumination, severe dehydration, tachycardia, complete absence of voiding dung (n=6), unilateral right flank or bilateral distention of flank region. Similar findings reported earlier (Anderson *et al*., 1993; Dharmaceelan *et al.,* 2018 and Mestry *et al.,* 2011). History of colic and straining was reported as early signs by the owners and were subsided after 24 hrs. Per rectal examination revealed empty rectum with palpable mass (n=3), raspberry jam appearance of dung (n=4) (Plate 1), blood tinged white mucus strands with empty rectum (Plate 2), distended loops of intestines, distended caecum (n=1) against the right flank. Present findings were also reported earlier (Constable *et al.,* 2017). Severe dehydration was also observed in animals with intestinal obstruction (Dharmaceelan *et al.,* 2018).

In all the cases, dehydration was evident with dry muzzle, sunken eyes and skin tenting for more than 7 seconds. Mean±SE of temperature, respiration and heart rate were 38.17±0.13°C, 85.67±1.68 beats/min, 38.17±0.13°C, respectively. Significant increase in the heart rate was observed in all the cases. (Imran *et al.,* 2011) correlated heart rate with the chronicity of the condition and observed elevated heart rate, with increased duration of intestinal obstruction as observed earlier (Anderson *et al.,* 1993 and Khalphallah *et al.,* 2016). Increased heart rate might be due to the occlusion of blood vessels of intestinal segment and resultant endotoxemia in intussusception cases (Radostits *et al*., 2009). In the present study, complete absence of rumen motility was observed in all the cases as observed earlier (Zavita and Zavita, 1960; Smart *et al.,* 1977 and Abutarbush and Naylor, 2007). Reduced motility or complete absence of rumen motility might be due to the pain evinced by the distension of bowel and its inhibitory effect on primary cycle motility (Leek, 1983).

Trans abdominal ultrasonography was performed as per the method described by Braun *et al.,* 1995 using Esoate Mylab 40 Vet ultrasound machine in real time B mode with a 3.5 MHz convex probe and observed the multiple distended loops of intestines with absence of motility (n=6) (Plate 1), target lesion (n=3) (Plate 2) in cases of intussusception and distended caecum (n=1). Similar findings were observed by Kumar *et al.,* 2015. The average diameter of small intestine was 6.04±0.34 cm. In the present study, multiple distended loops in a single scan area with absence of motility was an important diagnostic sign of mechanical intestinal ileus due to accumulation of fluid and gas proximal to the obstruction. The present findings were in accordance with the Braun *et al.* (1995). However, similar findings were also observed in paralytic ileus (Kumar *et al.,* 2015). In the present study, intussusception was diagnosed by ultrasonography in 3 cases only and in one case by intraoperative abdominal exploration. This might be due to the sinking fluid filled intestinal loops in to the ventral abdomen and involvement of obstruction in more cranial part of intestine. Abdominal exploration was found to be gold standard for diagnosis of intestinal obstruction.

Haematological values were predicted in Table 1. The mean±SE of haemoglobin and PCV and TLC was 12.78±1.08 g/dl, 40.68±2.08%, 9.76±0.73/µl respectively. Significant rise in PCV valuesmight be due to dehydration as a result of hypovolemia (Hussain *et al*., 2015). Significant rise in TLC and neutrophil count (59.33±0.73%) than normal range might be due to the infection and inflammation produce by obstruction. In the present study, animals with

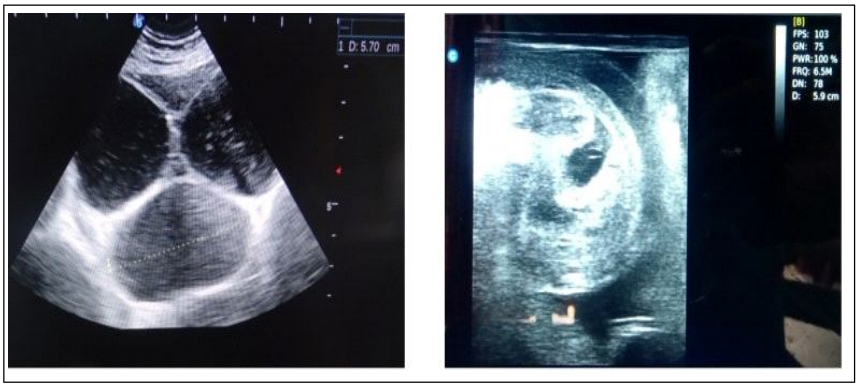

Plate 1 and 2: Showing cross sectional ultrasonographic image of non-motile dilated intestinal loops with ingesta and bulls eye pattern in a cow with intussusception.

Table 1: Haemato-biochemical parameters in six cattle suffering from intestinal obstruction.

Parameters	Values
Haemoglobn (g/dl)	12.78±1.08
PCV (%)	40.68±2.08
TEC (10^6/µl)	8.05±0.30
TLC (10^3/µl)	9.76±0.73
Neutrophil (%)	59.33±0.73
Lymphocyte (%)	40.33±2.30
Total Protein (g/dl)	6.93±0.12
Albumin (g/dl)	2.90±0.08
Calcium (mg/dl)	7.05±0.28
Phosphorous (mg/dl)	4.87 ±0.31
Sodium (mEq/L)	126.83±0.28
Chloride (mEq/L)	76.83±6.77

delayed presentation, showed marked rise in the immature neutrophils with left shift. The inflammatory leucytosis with left shift might be due to ischemic necrosis of the intestine and endotoxemia due to intestinal obstruction (Anderson and Eweoldt, 2005). The mean lymphocyte count (40.33±2.30%) was reduced significantly compared to normal. Reduced lymphocyte count might be due to release of corticosteroids as a result of stress (Jain, 1986).

Serum biochemical values were predicted in Table 1. The mean±SE of total protein 6.93±0.12 g/dl, was observed with in the normal range (6.7-7.4). Moderate reduction of albumin towards its lower side was observed. Normal total protein with lower albumin level may be due to the third space loses (Hussain *et al.,* 2015). Significant decrease in inorganic calcium, phosphorous, sodium, chloride was observed in all the cases. The mean calcium level was 7.05±0.28 mg/dl. In all the cases, hypocalcemia was observed. Hypocalcemia was reported in cases of intestinal obstruction due to intussusception (Kumar *et al.,* 2015) and hemorrhagic bowel syndrome (Braun *et al.,* 2010). Hypocalcemia might be due to prolonged anorexia and no or reduced absorption of calcium form gut in intestinal obstruction (Smith, 2009).

Intra operative findings of intestinal status were correlated with the ultrasonographic findings and localized the lesions by thorough abdominal exploration. Present study revealed that intestinal obstruction mainly due to the intussusception (n=4) followed by volvulus (n=1) and caecal dilatation (n=1). In all the cases, distended intestinal loops with congestion and fibrin deposits around the intestinal obstruction were observed. In cases of intussusception and volvulus affected intestinal part was exteriorized through laparotomy incision. Affected intestinal part was resected and end-to-end enteroanastamosis was performed using no.0 polyglactin 910 by simple interrupted suture pattern. In caecal dilatation, apex of the caecum was exteriorized through right flank laparotomy incision and content were drained by typhlotomy. Typhlotomy incision was closed with double inversion suture pattern using no.0 polyglactin 910.

The decision for surgical access and patient positioning is important regarding intestinal surgeries in cattle. Though large animals well tolerate the standing surgery under local anaesthetic techniques, the possibility of movement and risk of lying down occurs due to increased tension on mesentery during manipulation of viscera. (Anderson and Ewoldt, 2005 and Dharmaceelan *et al.,* 2018), recommended the infiltration of 2% lignocaine in to mesentery and 15% lignocaine spray during the resection of the intestinal mass to alleviate the visceral pain, respectively. In the present study, visceral pain was effectively alleviated by the administration of lignocaine hydrochloride @ 2 mg/kg body weight as loading dose and maintenance with 50 µg/kg/min 15 min prior to the surgical incision. Complications such as lying down of animal during exteriorization of intestines and prolapse of intestine were absent. The average time taken for surgical procedure was 68.83±2.36 min.

All the animals initially passed watery faeces post operatively and normal consistency of dung was observed after 36 hrs. The average dung voiding time was 122.5± 4.43 min. Post-operative administration of azithromycin reduced the dung passage time in cases of intestinal obstruction compared to the earlier report (Vishnugurubharan *et al.,* 2015). Erythromycin, macrolid antibioticis most commonly used prokinetic drug in the treatment of post-operative ileus in humans, dogs, horses and large ruminants. It has the best prokinetic effect on abomasum and the jejunum (Sylvion and Fecteau, 2017). Erythromycin exerts it prokinetic action by bonding to motlin receptors in pyloric antrum and proximal part of the small intestine (Wittek and Constable, 2005). Studies on prokinetic efficacy of azithromycin in twenty cows (Reddy *et al*., 2018) and buffaloes (Reddy *et al.,* 2019) with functional ileus reported that the animals treated with azithromycin passed dung earlier than those administered with the neostigmine.

Lidocaine is widely used as a local anaesthetic and in horses to treat post-operative ileus. The direct effect of lidocaine in reducing the ileus is not known but exerts an indirect effect on motility by reducing pain and intestinal inflammation. In the present study, administration of intravenous Lignocaine and azithromycin resulted in shorter hospitalization time because of early voiding of the dung and restoration of normal intestinal motility as also reported earlier (Malone *et al.,* 2006).

CONCLUSION

In all cases of the present study, good plane of surgical analgesia was achieved by using a combination of intravenous administration of lignocaine in addition to the right paravertebral nerve block. Further, lignocaine continuous rate of infusion effectively alleviated the mesenteric pain throughout the surgical procedure without prolapse of the intestines and intraoperative lying down of the patient. Administration of Inj. Azithromycin was effective in the management of post-operative functional ileus after

intestinal surgical procedure. It can be concluded that inclusion of lignocaine continuous rate of infusion enhances the quality of visceral analgesia, ease the standing abdominal surgical procedures under the field condition and economical as compared to the general anaesthetic procedures.

Conflict of interest

All authors declare that they have no conflict of interest.

REFERENCES

Anderson, D.E., Constable, PD., St Jean, G., Hull, B.L. (1993). Small-intestinal volvulus in cattle: 35 cases (1967-1992). *Journal of the American Veterinary Medical Association*. **203:** 1178-1183.

Anderson, D.E., Ewoldt, J.M. (2005). Intestinal surgery of adult cattle. *Veterinary Clinics of North America Food Animal Practice*. **21:** 133-154.

Abutarbush, S.M., Naylor, J.M. (2006). Obstruction of the small intestine by a trichobezoar in cattle 15 cases.1992-2002. *Journal of the American Veterinary Medical Association*. **229:** 1627-1630.

Braun, U., Steiner, A., Gotz, M. (1993). Clinical signs, diagnosis and treatment of duodenal ileus in cattle. *Schweizer Archivfur Tierheilkunde*. **135(11-12):** 345-355.

Braun, U., Marmier, O., Pusterla, N. (1995). Ultrasonographic examination of the small intestine of cows with ileus of the duodenum, jejunum or ileum. *Veterinary Record*. **137:** 209-215.

Braun, U. (2009). Ultrasonography of the gastrointestinal tract in cattle. *Veterinary clinics of North America Food Animal Practice*. **25:** 567-590.

Braun, U., Schmid, T., Muggli, E., Steininger, K., Previtali, M., Gerspach, C., Phospischil, A., Nuss, K. (2010). Clinical findings and treatment in 63 cows with haemarrhagic bowel syndrome. *Schweizer Archivfur Tierheilkunde*. **152(11):** 515-522.

Constable, P.D., St Jean, G., Hull, B.L., Rings, D.M., Morin, D.E., Nelson, D.R. (1997). Intussusception in cattle: 336 cases (1964-1993). *Journal of the American Veterinary Medical Association*. **210(4):** 531-536.

Dharmaceelan, S., Rajendran, S., Nanjappan, K., Subramanian, M., Balasubramaniam, G.A. (2018). Anamnesis and Clinical Signs of Gastrointestinal tract obstruction in cattle. *Indian Veterinary Journal*. **95(07):** 68-69.

Dharmaceelan, S., Rajendran, S., Nanjappan, K., Subramanian, M., Balasubramaniam, G.A. (2018). Administration of lignocaine by different routes during enterectomy in cattle. *Indian Veterinary Journal*. **95(06):** 79-80.

Hussain, S.A., Uppal, S.K., Randhawa, C.S., Sood, N.K. (2015). Bovine intestinal obstruction: blood gas analysis, serum C-reactive protein and clinical, haematological and biochemical alterations. *Journal of Applied Animal Research.* **43:** 224-230.

Imran, S., Tyagi,S.P., Kumar, A., Sharma, A., Shivali, S. (2011). Usefulness and limitation of ultrasonography in the diagnosis of intestinal intussusception in cows. *Veterinary Medicine International*. **11:** 584387. doi: 10.4061/2011/584387.

Jain, N.C. (1986). Schalm's Veterinary Hematology. 4th ed. Lea and Febiger, 600. Washington square, Philadelphia, USA.

Khalphallah, A., Aref, N.M., Elmeligy, E., El-Hawari, S.F. (2016). Clinical and ultrasonographic observations of functional and mechanical intestinal obstreuction due to intussusception in buffaloe (*Bubalus bubalis). Veterinary World*. **9(5):** 475-480.

Kumar, A., Kumar, A., Mohindroo, J., Singh, T., Gupta, A. (2015). Ultrasonographic diagnosis and surgical management of intussusception in cattle. *Indian Journal of Veterinary Surgery*. **36(2):** 116-118.

Leek, B.F. (1983). Clinical diseases of the rumen: A physiologist view. *Veterinary Record*. **113:** 10-14.

Malone, E., Ensink, J., Turner, T. (2006). Intravenous continuous infusion of lidocaine for treatment of equine ileus. *Veterinary Surgery*. **35(1):** 60-66

Mestry, G.R., Patel, P.B., Patel, J.B., Mistry, J.N., Suthar, D.N. (2011). Intestinal Obstruction in Bovines and its Surgical management- A Clinical report of 12 cases. *Intas Polivet*. **12:** 308-12.

Radostits, O.M., Gay, C.G., Blood, D.C., Hinchcliff, K.W. (2000). Veterinary Medicine-A Textbook of the Diseases of Cattle, Sheep, Pigs, Goats and Horses. W.B. Saunders Company Ltd, London. 259-346.

Reddy, B.S., Vlijaykumar, G., Balasubramaniam, G.A., Sivaraman, S., Kathirvel, S. (2018). Evaluation of efficacy of Neostigmine and Azithromycin as motility modifiers in the medical management of functional ileus in twenty cows-A pilot study. *Indian Veterinary Journal*. **95(08):** 47-50.

Reddy, B.S, Vlijaykumar, G., Balasubramaniam, G.A, Sivaraman, S., Kathirvel, S. (2018). Efficacy of Neostigmine and Azithromycin in buffaloes with functional ileus. *Buffalo Bulletin*. **38(04):** 649-652.

Saini, N.S., Anand, A. (2002). Surgical successful repair of three delayed cases of intestine obstruction in holstein friesian cows. *Indian Veterinary Journal*. **79:** 835-836.

Smart, M.E., Fretz, P.B., Gudmundson, J., Cymbaluk, N. (1977). Intussusception in a charolais bull. *Canadian Veterinary Journal*. **18:** 244-246.

Smith, B.P. (2009). Large Animal Internal Medicine, 4th ed., Elsevier. USA. 779-870.

Sylvian, N., Fecteau, G. (2017). Surgical management of abomasal and small intestinal disease. *Veterinary Clinic Food Animal*. doi: 10.1016/Jj.cvfa.2017.10.007.

Vishnugurubaran, D., Amritha, V., Senthilkumar, S., Kathirvel, S., Dharmaceelan S. (2015). Surgical management of intussusception in cattle under general aneasthesia: A report of six cases. *Indian Journal of Veterinary Surgery.* **36(2):** 132-33.

Wittek, T., Constable, P.D. (2005). Assessment of effects of erythromycin, neostigmine and metoclopramide on abomasal motility and emptying rates in calves. *American Journal of Veterinary Research*. **66:** 545-552.

Zavitz, S., Zavitz, V. (1960). Rumenotomy and intestinal anastomosis in a heifer. *Canadian Veterinary Journal*. **1(3):** 115-118.