RESEARCH ARTICLE Indian Journal of Animal Research, Volume 59 Issue 5: 864-868 (May 2025)

Detection of Epsilon Toxin in Goats Affected with Acute Enterotoxaemia and the Haemato-biochemical Alterations

S. Saravanan[1], T. Mohanapriya[1], R. Ramprabhu[1]

10.18805/IJAR.B-4805

ABSTRACT

Background: The principal cause of caprine enterotoxaemia is *Clostridium perfringens* type D which is normally resident in digestive tract and soil in fairly low numbers. Overeating of carbohydrate rich diet or sudden change in diet leads to proliferation of the bacteria and release of lethal toxins in intestine of the host. It causes sudden death in affected ruminants of different ages, though lambs of 3 to 10 weeks of age are highly susceptible. It causes sever enterocolitis with or without haemorrhagic diarrhoea and encephalitis resulting in acute nervous signs with a fatal outcome.

Methods: Thirty goats of different breeds under 1-4 years age and both sex were presented to Veterinary Clinical Complex, Veterinary College and Research Institute, Tirunelveli with the neurological signs and diarrhoea were the subject of study. Faecal samples were collected from all these cases and tested on spot by immunochromatographic test kit to identify the *Clostridium perfringens* Epsilon toxin (ETX). Blood and serum samples were collected and subjected haemato-biochemical analysis. Peripheral blood smears were also collected to rule out haemoprotozoan infections in all the cases.

Result: Epsilon toxin was detected from faecal samples of 36.6 per cent of the goats. Diarrhoea was the most consistent finding which is due to enterocolitis in acute cases. A significant increase (P<0.001) in the neutrophils and leukocytes count and a significant increase (P<0.05) in the levels of BUN, creatinine, glucose, ALP and chloride levels were observed. All the cases were treated with sulphadimidine at recommended dose with supportive therapy but no response was reported due to the fatal encephalitis.

Key words: Enterotoxaemia, Epsilon toxin, Goats, Haemato-biochemical analysis, Nervous signs.

INTRODUCTION

Enterotoxaemia is an infectious disease observed in well fed animals, mainly in sheep, less often in goat and rarely in cattle (Jemal *et al*., 2016). Peracute form of this disease occurs in animals of 3-10 weeks old, where as acute and chronic forms can occur in both young and old sheep and goats (Tariq Javed *et al.,* 2009).

The disease is caused by a gram positive, anaerobic, spore forming and toxin producing bacilli, *Clostridium perfringens* type D (Uzal *et al*., 2014) in goats, whereas *C. perfringens* type A is most commonly isolated type in ovine enterotoxaemia (Fahimeh *et al*., 2018). However, type A, C and D isolate were detected respectively in 75.6 per cent, 0.4 per cent and 0.4 per cent of total faecal samples from healthy goats (Santana *et al*., 2018). It is a normal component of the intestinal flora of healthy warm-blooded animals and human beings and soilin fairly low numbers (Songer, 1996).

C. perfringens can secrete 4 major toxins like alpha, beta, epsilon and iota and accordingly, the pathogen is typed into 5 toxins types namely A, B, C, D and E (Sakurai, 1995). Excess carbohydrate-rich feed or sudden change in diet leads to reduced peristaltic action resulting in rapid and excessive proliferation of organisms and production of lethal toxins in the intestine. Epsilon toxin (ETX) is the most important one which enters the blood stream and cause perivascular edema in tissues such as kidneys, lungs, heart and brain (Popoff, 2011). It causes sudden death in goats of all age groups (Veschi *et al*., 2008) and the case-fatality rate approximates 100% (Constable *et al*., 2017).

[1]Department of Veterinary Medicine, Veterinary College and Research Institute, Tamil Nadu Veterinary and Animal Sciences University, Tirunelveli-627 358, Tamil Nadu, India.

Corresponding Author: S. Saravanan, Department of Veterinary Medicine, Veterinary College and Research Institute, Tamil Nadu Veterinary and Animal Sciences University, Tirunelveli-627 358, Tamil Nadu, India. Email: sarvet_25@yahoo.com

How to cite this article: Saravanan, S., Mohanapriya, T. and Ramprabhu, R. (2025). Detection of Epsilon Toxin in Goats Affected with Acute Enterotoxaemia and the Haemato-biochemical Alterations. Indian Journal of Animal Research. 59(5): 864-868. doi: 10.18805/IJAR.B-4805.

Submitted: 16-10-2021 **Accepted:** 31-01-2022 **Online:** 12-03-2022

Though sheep enterotoxaemia is well documented, the situation is less clear in goats on account of limited studies carried in the goats. Availability of literature on haematologic and clinical biochemistry studies on enterotoxaemia is also limited (Pawaiya *et al*., 2020). This paper aims to report the incidence of classical enterotoxaemia in goats of different age groups with specific signs by qualitative detection of epsilon toxin in faeces, therapeutic management and haemato-biochemical analysis in the affected goats.

MATERIALS AND METHODS

Thirty goats of under 1-4 years age group, both male and female and Kodi, Kanni and Salem Black breeds were

presented to Medicine section, Veterinary Clinical Complex, Veterinary College and Research Institute, Tirunelveli in 2021 with the neurological signs like violent convulsions, opisthotonos, nystagmus, bruxism, ataxia, lateral recumbency, paddling, ptyalism and coma (Fig 1a,1b and 1c). Diarrhoea with semisolid, watery or haemorrhgic faeces could be observed in some of the cases.All the goats were reported to have no history of insecticide poisoning in their premises. Faecal samples were collected by using a rectal scoup from all these cases and tested immediately on spot by immunochromatographic test kit (BioX Diagnostics®, France) to identify the *Clostridium perfringens* Epsilon toxin. The test faecal sample was diluted in the buffer provided in the sample vial and the immunochromatographic device was placed into the liquid sample. The positive reaction was read if pink line appeared on test line indicating weak or strong positivity without development of reaction in control line (Fig 2) Serum samples were collected from the positive cases for haematobiochemical analysis (Table 1). Peripheral blood smears were also collected to rule out haemoprotozoan infections in all the cases.

RESULTS AND DISCUSSION

In this study, 36.6 per cent of the goats were found to be positive by the immunochromatographic test. The definitive diagnosis of enterotoxaemia is mostly based only on the detection of epsilon toxin in the intestinal contents and other supportive tests could be measurement of urine glucose levels or examination of Gram-stained smears of intestinal mucosa (Smith and Sherman, 2011). Molecular test like, multiplex PCR is generally used for toxin genotyping of *C. perfringens* (Mohiuddin *et al*., 2016). Recently, immuno chromatographic test is found to detect ETX with fivefold detection limits in different matrices such as serum and intestinal contents (Feraudet-Tarisse *et al*., 2017). The peripheral blood smears revealed no blood parasites from all the cases.

The clinical signs observed are in consistent with that of Smith and Sherman (2011) and Ortega *et al*. (2019). Diarrhoea was the most consistent finding which is due to enterocolitis in acute cases and initial softening of faeces in sub acute cases (Pawaiya *et al*., 2020). The nervous signs observed could be associated with ETX that was known to stimulate the release of glutamate, an excitatory neurotransmitter, by targeting the hippocampal glutamatergic system (Lonchamp *et al*., 2010 and Popoff, 2011) or vasogenic edema and neuronal toxicity (Morris *et al*., 2017). Brain is a prime target of epsilon toxin which initially binds to endothelial cells of the blood-brain-barrier (BBB), resulting in swelling, vacuolation and necrosis and thereby leakage of fluid and proteins, hypoxia of the neural parenchyma (Stiles *et al*., 2013). However, Kumar (2019) and Singh (2017) observed brain changes as inconsistent in caprine enterotoxaemia. The damage to the vascular endothelium leads to the accumulation of protein-rich fluid effusions in heart, brain and lung (Constable *et al*., 2017).

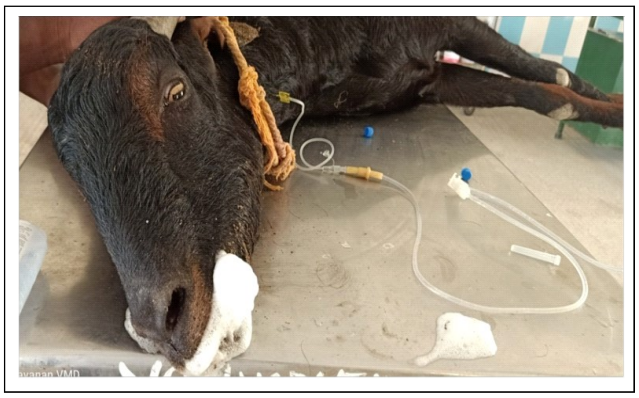

Fig 1a: Copious salivation in an adult salem black goat affected with enterotoxaemia.



Fig 1b: Opisthotonos and watery diarrhoea in an adult Kanni goat affected with enterotoxaemia.



Fig 1c: Extensor rigidity of hind limbs in an adult Kanni goat affected with enterotoxaemia.

In this report, neutrophilia and leukocytosis were observed in majority of the cases (90.0%) of enterotoxaemia and statistically, a highly significant increase ($P<0.001$) in the neutrophilsand leukocytes count and a highly significant decrease ($P<0.001$) in the lymphocyte count were noticed in the positive cases when compared to the controls. Reduction in total erythrocyte count (TEC) was observed in 40.0 per cent of the cases, however, statistically, no significant difference was observed in



Fig 2: Immunochromatographic test (DiPFIT- Epsilon) showing negative reaction in test line of the control and positive reactions (weak and strong) inpositive cases of enterotoxaemia.

Table 1: Haemato-biochemical values (mean±SD) associated with the cases of enterotoxaemia.

Parameters	Enterotoxaemia cases	Controls	P Value
	Haematological values (Mean±SE)		
Hb (g/dl)	11.90±1.53	12.94±1.44	0.6269
PCV (%)	20.84±2.10	25.54±0.95	0.0567
RBC ($\times 10^6$/ul)	9.81±1.08	12.15±0.62	0.0762
WBC ($\times 10^3$/ul)	58180.00±20840.84	18510.00±1742.76	0.0740
Platelet ($\times 10^5$/ul)	198350.00 ±60727.68	401800.00±16980.25	0.0047
Neutrophils (%)	62.30±6.53	28.80±0.71	<0.001
Lymphocytes (%)	34.20±6.09	65.10±0.35	<0.001
Monocytes (%)	1.40±0.72	2.30±0.40	0.112z
Eosinophils (%)	2.00±0.68	3.80±0.39	0.075
Basophils (%)	0.00±0.00	0.00±0.00	
	Biochemical values (Mean±SE)		
BUN (mg/dl)	110.55±21.54	27.12±2.71	0.0012
Creatinine (mg/dl)	2.50±0.54	0.90±0.04	0.0084
Total protein (g/dl)	6.04±0.75	7.23±0.24	0.1505
Albumin (g/dl)	2.79±0.27	2.80±0.30	0.9807
Globulin (g/dl)	3.28±0.54	4.43±0.29	0.0746
ALT (u/l)	18.00±2.04	22.60±2.26	0.1478
AST (u/l)	78.90±7.43	68.10±13.90	0.5020
ALP (u/l)	201.10±50.16	376.70±62.37	0.0416
Calcium (mg/dl)	10.62±0.81	10.54±0.36	0.9292
Phosphorous (mg/dl)	4.37±1.06	3.93±0.48	0.7095
Glucose (mg/dl)	361.00±85.21	70.97±12.30	0.0034
Sodium (meq/l)	180.66±5.07	145.79±3.43	<0.001
Potassium (meq/l)	5.07±0.72	3.70±0.46	0.1249
Chloride (meq/l)	105.84±3.32	92.19±1.87	0.0021
Magnesium (meq/l)	4.20±0.46	7.03±3.33	0.4110

positive cases when compared to controls. The findings are in accordance with Kumar (2019) who observed a significant increase in the white blood cells (WBC) in affected goats, with a significant reduction in mean erythrocyte (RBC) count and haemoglobin level. Reduction in RBC levels could be associated with haemorhhagic enteritis caused by the ETX and the leukocytosis with clostridial proliferation in the GI tract.

In this report, elevated blood urea nitrogen (BUN) creatinine, glucose, sodium, alkaline phosphatise (ALP) and chloride levels were observed in positive cases. Statistically, a significant increase ($P<0.05$) in the levels of BUN, creatinine, glucose, ALP and chloride levels was observed, and statistically a significant increase ($P<0.001$) in the sodium level was observed. This finding was in accordance with Khan *et al*. (2017) who recorded a significant increase in blood glucose, liver enzymes, serum creatinine, total bilirubin caprine enterotoxaemia, pulpy kidney was not consistently reported, but with petechial and ecchymotic subcapsular haemorrhages (Uzal *et al*., 1994). Pronounced hyperglycem, blood urea and glucose in goats affected with enterotoxaemia.

The elevated BUN and creatinine could be associated with lesions in kidney. However, in ia (150 to 200 mg/dL) due to the mobilization of hepatic glycogen and marked glycosuria are reported to be characteristic in the terminal stage of enterotoxaemia (Constable *et al*., 2017). Glycosuria is said to be strongly indicative of enterotoxaemia in both sheep and goats (Uzal and Songer, 2008), where as Pawaiya *et al.* (2020) reported the hyperglycaemia and glycosuria to be inconsistent in goats.

All the animals were treated with parentral administration of sulphadimidine @ 150 mg/kg body weight to prevent further growth of the bacterium and toxin production, flunixin meglumin @2.2 mg//kg body weight to alleviate toxaemia, mannitol @2.0 gms/kg body weight to reduce the cerebral oedema, diazepam @ 0.5/kg body weight as an anticonvulscent, dextrose normal saline and Ringer's lactate to alleviate dehydration along with recommendation of oral sulphadimidine, activated charcoal as toxin binder, bloat relieving suspension and rumenotorics (Smith and Sherman, 2011). However, all the cases were not presented for follow up therapy which might possibly be due to the fatal outcome of the disease, as the treatment is generally not effective due to acute nature of the disease.

Conclusion

In conclusion, acute enterotoxaemia mostly leads to a fatal outcome due to the encephalitic form not only in young kids but also in adults. Hence, periodical prophylactic vaccination of sheep and goats against enterotoxaemia especially before rainy season in endemic areas will help prevent the onset of disease and the mortality.

Acknowledgement

The authors thank the Dean, veterinary College and Research Institute, Tirunelveli and Director of Clinics, Tamil Nadu veterinary and Animal Sciences University for providing necessary facilities to carry out the present work.

Conflicts of interest

There is no conflict of interest with any of the authors either directly or indirectly to the content of this article.

References

Constable, P.D., Hinchcliff, K.W., Done, S.H. and Grunbergh, W. (2017). In: Veterinary Medicine: A Textbook of the Diseases of Cattle, Horses, Sheep, Pigs and Goats (11th Edn). Elseviers Publications, Philadelphia. pp: 1224-1227.

Fahimeh, Y., Peyman, N., Gholamreza, H., Gholamali, K., Mohammad, R. and Jamshid, R. (2018). Major and minor toxins of *Clostridium perfringens* isolated from healthy and diseasedsheep. Small Ruminant Research. 168: 1-5. https://doi.org/10.1016/j.smallrumres. 2018.09.008.

Feraudet-Tarisse, C., Mazuet, C., Pauillac, S., Kruger, M., Lacroux, C., Popoff, M.R., Dorner, B.G., Andreoletti, O., Plaisance, M., Volland, H. and Simon, S. (2017). Highly sensitive sandwich immunoassay and immunochromatographic test for the detection of clostridial epsilon toxin in complex matrices. PLoS One. 12: e0181013. https://doi.org/10.1371journal.pone.0181013.

Jemal, D., Shifa, M., Kebede, B. (2016). Review on pulpy kidney disease. Journal of Veterinary Science and Technology. 7: 361. https://doi.org/10.1053/ajkd.2016.06.005.

Khan, M.A., Durrani, A.Z., Khan, S.B., Khan, M.A., Khan, A.A.S.N.U., Prince, K., Khan, N.U.A.U. (2017). Association between bacterial strain type and host biomarkers in *Clostridium perfringens* infected goats. microbial pathogenesis. 112: 254-258. https://doi.org/10.1016/j.micpath.2017.09.059.

Kumar, R. (2019). Pathology and Transcriptional Response of Enterotoxaemia in Goats. M.V.Sc. Thesis, Indian Veterinary Research Institute (IVRI), Izatnagar, Uttar Pradesh.

Lonchamp, E., Dupont, J.L., Wioland, L., Courjaret, R., Mbebi-Liegeois, C., Jover, E., *et al*. (2010). *Clostridium perfringens* epsilon toxin targets granule cells in the mouse cerebellum and stimulates glutamate release. PLoS One. 5: e13046.

Morris, W.E., Goldstein, J., Redondo, L.M., Cangelosi, A., Geoghegan, P., Brocco, M., *et al*. (2017). *Clostridium perfringensepsilon* toxin induces permanent neuronal degeneration and behavioral changes.Toxicon, 130:19- 28. https://doi.org/10.1016/j.toxicon. 2017.02.019.

Mohiuddin, M., Iqbal, Z. and Rahman, S.U. (2016). Prevalence of *Clostridium perfringens* β2-toxin in sheep and goat population in Punjab, Pakistan. The Thai Journal of Veterinary Medicine. 46: 491-496.

Ortega, J., Verdes, J.M., Morrell, E.L., Finnie, J.W., Manavis, J. and Uzal, F.A. (2019). Intramural vascular edema in the brain of goats with *Clostridium perfringens* Type D Enterotoxemia. Veterinary Pathology. 56: 452-459. https://doi.org/10.1177/0300985818817071.

Pawaiya, R.S., Gururaj, K., Gangwar, N.K., Singh, D.D., Kumar, R. and Kumar, A. (2020). The challenges of diagnosis and control of enterotoxaemia caused by *Clostridium perfringens* in small ruminants. Advances in Microbiology. 10: 238-273. https://doi.org/10.4236/aim.2020.105019.

Popoff, M.R. (2011). Epsilon toxin: A fascinating pore-forming toxin. FEBS J. 278: 4602-4615. https://doi. org/10.1111/j.1742-4658. 2011.08145.x PMID: 21535407.

Santana, J.A., de Andrade Ferreira, AC, de Souza, MCC, Moreira, M.A.S., Lima, M.C., Cruz, D.S.G., Lobato, F.C.F. and Silva, R.O.S. (2018). Isolation and genotyping of *Clostridium perfringens* from goats in Minas Gerais, Brazil. Ciencia Rural. 48: 7. https://doi.org/10. 1590/0103-8478cr2018 0101.

Sakurai, J. (1995). Toxins of *Clostridium perfringens*. Revies in Medical Microbiology. 6: 175-185.

Singh, D.D. (2017). Molecular pathogenesis of enterotoxaemia in neonatal goat kids. Ph.D. Thesis, U.P. Pandit Deen Dayal Upadhyaya Pashu Chikitsa Vigyan Vishwavidyalaya Evam Go Anusandhan Sansthan (DUVASU), Mathura.

Smith, M.C. and Sherman, D.M. (2011). Goat Medicine. 2nd Edition, Wiley-lackwell, Hoboken.

Songer, J.G. (1996). Clostridial enteric diseases of domestic animals. Clinical Microbiology Reviews. 9: 216-234. https://doi.org/ 10.1128/CMR.9.2.216.

Stiles, B.G., Barth, G., Barth, H. and Popoff, M.R. (2013). *Clostridium perfringens* Epsilon Toxin: A Malevolent Molecule for Animals and Man? Toxins. 5: 2138-2160. https://doi.org/ 10.3390/toxins5112138.

Tariq Javed, Irfan, M.M., Mukhtar, N., Sajjad-ur-Rahman and Hussain, R. (2009). An outbreak of enterotoxaemia at livestock farm during subtropical summer. Acta Tropica. 112: 225-227.

Uzal, F.A. and Songer, J.G. (2008).Diagnosis of *Clostridium perfringens* intestinal infections in sheep and goats. Journal of Veterinary Diagnostic Investigation. 20: 253-265. https://doi.org/10.1177/104063870802000301.

Uzal, F.A., Pasini, M.I., Olaechea, F.V., Robles, C.A. and Elizondo, A. (1994). An outbreak of enterotoxaemia caused by *Clostridium perfringens* Type D in goats in Patagonia. Veterinary Record. 135: 279-280. https://doi.org/10.1136/ vr.135.12.279.

Uzal, F.A., Vidal, J.E., McClane, B.A. and Guraj, A.A. (2014). *Clostridium perfringens* toxins involved in mammalian veterinary diseases. Open Toxicology Journal. 2: 24-42.

Veschi, J.L., Bruzzone, O.A., Losada-Eaton, D.M., Dutra, I.S. and Fernandez-Miyakawa, M.E. (2008). Naturally acquired antibodies against *Clostridium perfringens* epsilon toxin ingoats. Veterinary Immunology and Immunopathology. 125: 198-202. https://doi.org/10.1016/j.vetimm.2008. 04.015.