RESEARCH ARTICLE Indian Journal of Animal Research, Volume 59 Issue 7: 1249-1252 (July 2025)

Histochemical Study of the Harderian Gland of *Pati* Duck of Assam

Jiten Rajkhowa[1], Kabita Sarma[1], Snehangsu Sinha[1], Chandan K. Gautam[2], Anil Deka[1] 10.18805/IJAR.B-4842

ABSTRACT

Background: *Pati* duck population constitutes a major indigenous non-descript economically important duck variety in Assam. Harderian gland acts as a part of the head associated lymphoid tissue (HALT) and provides local innate immunity to the upper respiratory system, to the eye and oral cavity. Since literature on histoenzymic or histochemical study of harderian gland of *Pati* duck was scant, hence the present study was designed to establish the basic histoenzymic details on harderian gland of *Pati* duck of Assam.

Methods: The present study was conducted on total forty five (45) *Pati* duck of Assam. Ducks were divided into five groups: 0, 4, 16, 24 and 42 weeks. For histochemical parameters, tissue samples were preserved in deep freeze maintained at -80°C (except for PAS-alcian blue, where paraffin sections were utilized) immediately after collection. The preserved tissue samples were shifted directly to cryostat microtome maintained at -22°C. The frozen sections were cut at 7 µm thickness and were collected on clean slides and were treated as per the method of Singh and Sulochana (1978).

Result: Histochemical studies revealed that the reaction of Alkaline phosphatase enzyme was mildin Harderian land of *Pati* duck. The reaction of the acid phosphatase was absent. The Adenosine triphosphatase (ATPase) activity was observed moderate in all the age groups. The activity of non specific esterase was observed strong in all the age groups. The periodic acid-Schiff (PAS-Alcian Blue 2.5 pH) stain revealed positive reaction in all the age groups which indicated the presence of acid sulfated mucosubtances in the cells.

Key words: Harderian gland, Histochemistry, *Pati* duck, Postnatal.

INTRODUCTION

The *Pati* duck (*Anas platyrhynchos domesticus*) population constitutes a major indigenous non-descript duck variety in the state of Assam. The Annual egg production per *Pati* duck is 70-95 eggs, (Kalita *et al*., 2009). The indigenous duck variety of Assam is the only duck enlisted in the website of the bureau under the name '*pati*' (0200 PATI 11001) of Animal Genetic Resources. Johann Jacob Harder (1694) reported his discovery of a 'glandula nova lachrymalis', suggesting that the large structure he had identified in deer server to moisten the surface of the eye, the Harderian gland. It has been held to be a site of immune responses, a source of thermoregulatory lipids, a source of pheromones, a photoprotective organ and part of a retinal-pineal axis. (Payne, 1994). Since there is scanty of literature on histochemical study of the postnatal development of Harderian gland of *Pati* duck of Assam, hence the present study was designed to establish the basic histoenzymic or histochemical norms on Harderian gland at different stages of postnatal development of *Pati* duck of Assam.

MATERIALS AND METHODS

The present study was conducted on total forty five (45) numbers *Pati* duck of Assam at different stages of postnatal development. The ducks were divided into five as age group 0, 4, 16, 24 and 42 weeks. For histochemical parameters, tissue samples were preserved in deep freeze maintained at -80°C (except for PAS-alcian blue, where paraffin sections were utilized) immediately after collection. The preserved tissue samples were shifted directly to cryostat microtome (Shandon Finesse) which was maintained at -22°C. The frozen sections were cut at 7 µm thickness and were collected on clean slides. They were temporarily stored at -22°C and were then treated as per the method of Singh and Sulochana (1978) for demonstration of following histochemical parameters:

a). Gomori's alkaline phosphatase cobalt method (Singh and Sulochana, 1978).

b). Gomori's method for acid phosphatase (Singh and Sulochana, 1978).

[1]Department of Anatomy and Histology, College of Veterinary Science, Assam Agricutural University, Guwahati-781 022, Assam, India.

[2]Department of Anatomy and Histology, Lakhmipur Colllege of Veterinary Science, Joyhing, Lakhmipur-787 051, Assam, India.

Corresponding Author: J. Rajkhowa, Department of Anatomy and Histology, College of Veterinary Science, Assam Agricutural University, Guwahati-781 022, Assam, India.
Email: drjitenrajkhowa@gmail.com

How to cite this article: Rajkhowa, J., Sarma, K., Sinha, S., Chandan, G.K. and Deka, A. (2025). Histochemical Study of the Harderian Gland of *Pati* Duck of Assam. *Indian Journal of Animal Research*. **59(7):** 1249-1252. doi: 10.18805/IJAR.B-4842.

Submitted: 14-12-2021 **Accepted:** 29-04-2022 **Online:** 13-06-2022

c). Lead method for ATPase (Bancroft, 2008).
d). Gomori's method for non-specific esterase (Bancroft, 2008).

Representative tissue samples from the same birds were also processed as per procedure followed by Luna, (1968) and paraffin sections were cut at 8 µm thickness with the Shandon Finesse microtome and were stained for mucopolysaccharides by Periodic Acid Schiff -alcian blue method (Luna, 1968).

RESULTS AND DISCUSSION

Alkaline phosphatase

The activity of Alkaline Phosphatase enzyme was weak to moderate (Fig 1, Table 1) in Harderian gland of *Pati* duck. The activity was observed at the basal border of the cells near the nucleus. It was due to the presence of large amount of secretion which occupied the whole apical portion of the cell. The activity was moderate in 0 week, 4 weeks and 16 weeks age group but weak in 24 weeks and 42 weeks age. Mobini (2012) has reported that there was moderate to intense reaction of alkine phosphatase in the harderian gland of chicken.

Acid phosphatase

The activity of the Acid Phosphatase was absent due to accumulation of mucoid substances in the cytoplasm of the cell (Fig 2). Moderate to intense activity of acid phosphatase was reported in harderian gland of chicken by Mobini (2012) The literatures regarding activities of Acid Phosphatase in the Harderian gland of avian species were very scanty.

Adenosine triphosphatase (ATPase)

The Adenosine Tri Phosphatase (ATPase) activity was observed moderate in all the age groups of birds (Fig 3, Table 1). The activity of ATPase was observed at both the apical and basal border of the cells. The ATPase activity was same in the all age groups. The ATPase enzyme related to active transport of the Na and K ion through the cell membrane as recorded by Maire and Wins (1972) in the Harderian gland of duck.

Non specific esterase

The activity of non specificesterase was strong in the Harderian gland of the *Pati* duck in all the age groups (Fig 4,

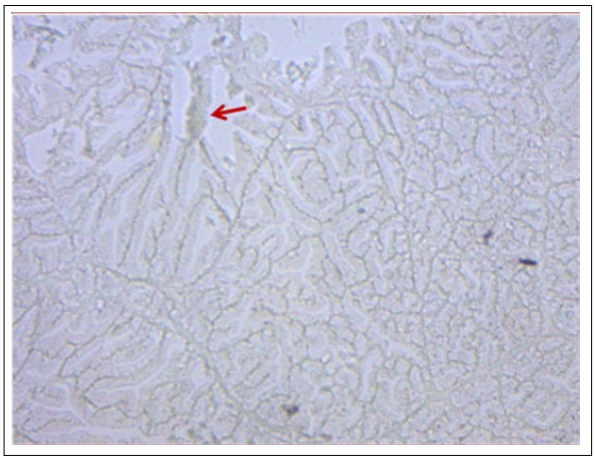

Fig 1: Photomicrograph showing the activity of Alkaline phosphatase enzyme (Arrow) in the harderian gland of the *Pati* duck, 42 weeks.

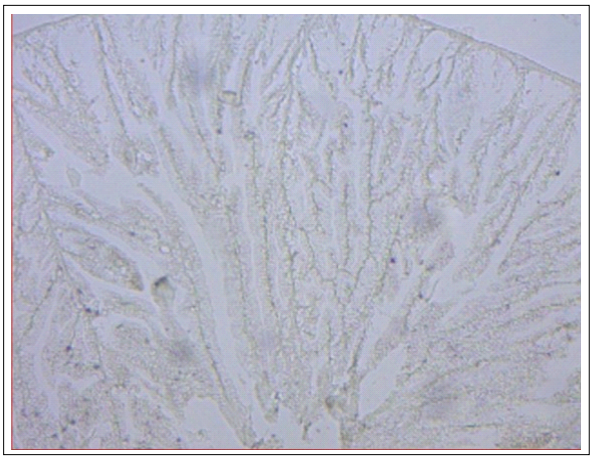

Fig 2: Photomicrograph showing the activity of acid phosphatase enzyme in the harderian gland of *Pati* duck, 4 week.

Table 1: Showing the activity of histoenzymic reaction in the harderian gland of pati duck in different age group.

Histoenzymic reaction	0 week	4 week	16 week	24 week	42 week
Alkaline phosphatas	+ +	+ +	+ +	+	+
Acid phosphatase	-	-	-	-	-
ATPase	++	++	++	++	++
Non specific esterase	+ + +	+ + +	+ + +	+ + +	+ + +
Mucopolysaccharids (PAS-Alcian blue- 2.5 pH)	+ + +	+ + +	+ + +	+ + +	+ + +

Gradation for intensity:
Absent = --
Weak = +
Moderate = + +
Strong = + + +
Intense = + + + +



Fig 3: Photomicrograph showing the activity of ATPase enzyme (Arrow) in the harderian gland of *Pati* duck, 24 weeks.

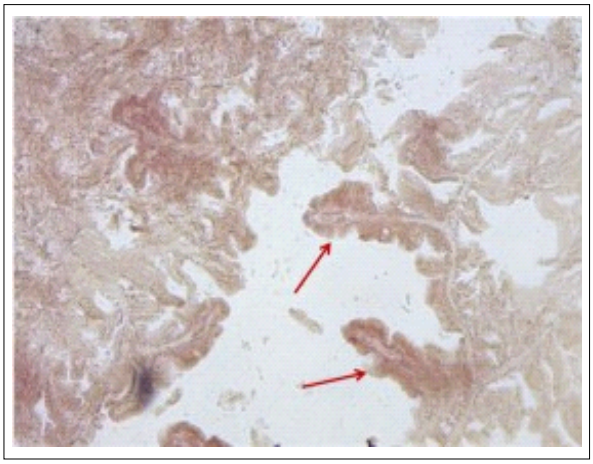

Fig 4: Photomicrograph showing the activity of N S Esterase enzyme (Arrow) in the harderian gland of *Pati* duck, 16 weeks.

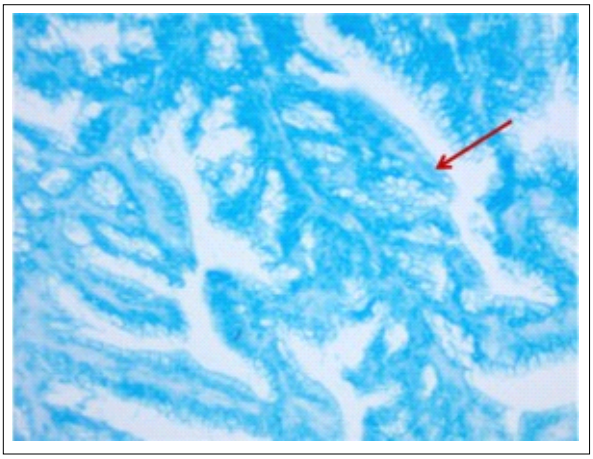

Fig 5: Photomicrograph showing the activity of PAS and Alcian Blue *i.e.* Mucopolysaccharide (Arrow) in the harderian gland of *Pati* duck, 24 weeks.

Table 1). The reaction of the non specificesterase distributed throughout the whole cell. Fukuda and Shindo (1974) also found intense reaction of non specific esterase in the Harderian gland of rat.

Mucopolysaccharids by periodic acid-Schiff stain (PAS-Alcian blue 2.5 pH)

The harderian gland reacted strongly with the periodic acid-Schiff (PAS-Alcian Blue 2.5 pH) stain in all the age groups (Fig 5). The present findings were in agreement with Frahmand and Mohammadpour (2015) and Kle-ckowska-Nawrot *et al*. (2014) in Ostrich. Both acidic and neutral mucopolysaccharids were reported by Ali *et al*. (2016) in the Harderian gland of pigeon.

CONCLUSION

The histoenzymic activity of Alkaline phosphatase in the Harderian gland of Pati duck was observed moderate in all age group and Acid phosphatase reaction was absent in all the age group. The Adenosine triphosphatase (ATPase) showed moderate reaction in apical border of the cells of the Harderian gland in all the age groups of birds. Non specipic Estarase established a strong reaction throughout the gland in all the age group. The PAS Alcian blue (2.5 pH) reactivity was observed moderate against the acid sulfated mucosubstance present in the gland uniformly in all the age groups.

Conflict of interest

All authors decalre that they have no conflict of interest.

REFERENCES

Ali, F.R., Ilaf, H.H. and Hadaf, H.M. (2016). Morphological and histochemical study of harderian gland of domestic pigeon (*Columba livia domestica*). *Bull. Iraq Nat. Hist. Mus.* **14(2):** 161-170.

Bancroft, J.D. and Cook, H.C. (1984). Manual of Histological Techniques. Churchill Livingstone, London.

Bancroft, J.D. and Gamble, M. (2008). Theory and Practice of Histological Techniques. 6th Edition, Churchill Livingstone, Elsevier, China.

Brownscheidle, C.M. (1974). The Morphology and Histochemistry of the Harderian Gland of the Mongolian Gerbil, Meriones unguiculatus. Doctoral Dissertation, State University of New York at Buffalo, Buffalo, NY.

Frahmand, S. and Mohammadpour, A.A. (2015). Harderian Gland in Canadian Ostrich (*Struthio camelus*): A Morphological and Histochemical Study. *Anat. Histol. Embryol*. **44:** 178-185.

Fukuda, K. and Shindo, H. (1974). Histochemical demonstration of non specific esterase in whole body section of Rat. *Acta Histochem. Cytochem*. **7(3):** 181-183.

Kalita, N., Barua, N., Bhuyan, J. and Chidananda, B.L. (2009). Present status of duck farming in Assam. Proceeding of IV world waterfowl conference held at Thrissur, Kerala, India. 11-13 Nov. pp. 359-363.

Kleckowska-Nawrot, J., Gozdziewska-HarŁajczuk, K.G., Barszcz, K. and Kowalczyk, A. (2014). Morphological studies on the Harderian gland in the Ostrich (*Struthio camelus domesticus*) on the embryonic and post-natal period. *Anat. Histol. Embryol*. **44:** 146-156.

Maire, M.L. and Wins, P. (1972). Some properties of particulate atpases and phosphatases isolated from the harderian gland of the duck. *Archives Internationales de Physiologie et de Biochimie*. **8(3):** 423-441.

Mobini, B. (2012). Histological and Histochemical studies on the Harderian gland of native chicken. *Veterinami Medicina*. **57(8):** 404-409.

Olah, I., Scottr, T.R., Gallego, M., Kendall, C. and Glick, B. (1992). Plasma cells expressing immunoglobulins M and A but not immunoglobulin G develop an intimate relationship with centralcanal epithelium in the Harderian gland of the chicken. *Poultry Science*. **71:** 664-676.

Payne, A.P. (1994). The Harderian gland: A tercentennial review. *Journal of Anatomy*. **185:** 1-49.

Singh, U.B. and Sulochana, S. (1978). A Laboratory Manual of Histological and Histochemical Technique. Kothari Medical Publishing House, Bombay, 1st Edn. pp. 50-55.

Wight, P.A.L., Mackenzie, G.M., Rothwell, B. and Burns, R.B. (1971). The Harderian glands of the domestic fowl. II. Histochemistry. *Journal of Anatomy*. **110:** 323-333.