RESEARCH ARTICLE Indian Journal of Animal Research, Volume 59 Issue 8: 1388-1394 (August 2025)

Titanium Elastic Stable Intramedullary Nailing for the Repair of Long Bone Fractures in Dogs

Ankush Kumar[1], R.N. Chaudhary[1], Ram Niwas[1], Priyanka[1]

10.18805/IJAR.B-4856

ABSTRACT

Background: Elastic stable intramedullary nailing has become a widely accepted, standard surgical technique for the repair of long bone diaphyseal fractures in children and adolescents however, references for its use in veterinary practice are still rare.

Methods: The present study was conducted on ten clinical cases, selected randomly irrespective of their age, sex and breeds; diagnosed with long bone diaphyseal fractures. Titanium elastic intramedullary nailing was performed in all the cases. Clinical, orthopaedic and radiographic examinations were performed pre-operatively, just after surgery and at 15th, 30th and 60th post-operative days.

Result: There was an increase in the mean weight bearing score during standing and walking from 0th day to 60th post-operative day. Post-operative radiographic examinations revealed increase in the mean values of bone formation score and bone union scores. The nails were removed easily in all the cases on 60th post-operative day. Five cases had complications; delayed wound healing (n=1) and slight nail migration from insertion site (n=4) which were managed conservatively and by cutting the extra lengths of the migrated nails. The clinical outcome on the basis of functional limb usage was excellent in seven cases, good in two cases and fair in one case. Overall, titanium elastic stable intramedullary nailing had good efficacy with respect to weight bearing in dogs without any systemic adverse effect.

Key words: Dogs, ESIN (elastic stable intramedullary nailing), Fracture, Titanium elastic nail.

INTRODUCTION

Bone is a metabolically active connective tissue composed of an extracellular matrix and bone cells (osteocytes) that provides structural support, protects vital organs and facilitates movement (Sayed *et al.*, 2020). Long bone fracture is a common orthopaedic condition found in dogs (Harasen, 2001). The primary aim of any method of fracture fixation is to achieve the fastest possible healing by regeneration of mineralized tissue at fracture site and enabling the patient to function normally by allowing early mobility (Aron, 1998; Shahar, 2000; Marsell and Einhorn, 2011). Any internal fixation device is used to transmit the loads from one end of the bone to the other and to maintain alignment of the fractured fragments during the healing process (Gozna, 1982).

Elastic stable intramedullary nailing (ESIN) has become a well-accepted method of osteosynthesis of diaphyseal fractures in children and adolescents in medical sciences (Lascombes *et al.,* 2006). Advantages of ESIN are minimal invasiveness, avoidance of growth plate injury, ability for direct mobilization to maintain joint movement and muscle tone as well as normal circulation, early bridging of callus and rapid restoration of bone continuity which leads to early limb function (Ligier *et al.,* 1988; Mazda *et al.,* 1997; Flynn *et al.,* 2001; Flynn *et al.,* 2004; Hunter, 2005; Lascombes *et al.,* 2006). Titanium and stainless steel are commonly used as elastic nails and both of these metals result in adequate stabilization of the fractured bone (Perez *et al.*, 2008; Wall *et al.*, 2008; Gyaneshwar *et al.*, 2016; Mohamed and Rajeev, 2017) but the use of titanium alloys has been increasing because of their appropriate mechanical properties, excellent biocompatibility and good corrosion resistance (Uhthoff *et al.*, 1981; Cui *et al.*, 2011). The titanium nails are more flexible, with a Young's modulus of ~110 GPa, compared to stiffer stainless nails (~200 GPa). Despite a lower modulus of elasticity, titanium nails provided greater fracture stability than stainless steel nails in fixing femoral shaft fractures in a synthetic bone model (Mahar *et al.*, 2004).

[1]Department of Veterinary Surgery and Radiology, Lala Lajpat Rai University of Veterinary and Animal Sciences, Hisar-125 004, Haryana, India.

Corresponding Author: Ankush Kumar, Department of Veterinary Surgery and Radiology, Lala Lajpat Rai University of Veterinary and Animal Sciences, Hisar-125 004, Haryana, India. Email: dr.ankushgill@gmail.com

How to cite this article: Kumar, A., Chaudhary, R.N., Niwas, R. and Priyanka (2025). Titanium Elastic Stable Intramedullary Nailing for the Repair of Long Bone Fractures in Dogs. *Indian Journal of Animal Research*. **59(8):** 1388-1394. doi: 10.18805/IJAR.B-4856.

Submitted: 31-12-2021 **Accepted:** 26-05-2022 **Online:** 20-06-2022

MATERIALS AND METHODS

Ten dogs having long bone diaphyseal fracture (transverse, short oblique or comminuted) were selected (with the consent of owner) irrespective of their age, sex, breed and body weight for the repair of the fractures with ESIN technique by using titanium elastic nails (TENs). Thorough clinical, orthopaedic and radiographic evaluations were performed in all the animals at different time intervals *i.e.*,

at pre-operative, just post-operatively and at 15th, 30th and 60th post-operative days. Selection of diameter of the nail was based on the pre-operative radiographic evaluation of diameter of the isthmus of the fractured bone (one-third diameter of the isthmus was taken as the diameter of the titanium elastic nail) (Fig 1). The surgical procedure was performed under general anaesthesia by using Inj. Atropine Sulphate @ 0.04 mg per kg b.wt (pre-anaesthetic) 10 minutes before the induction with a combination of Inj. Xylazine hydrochloride @ 1 mg per kg b.wt and Inj. Ketamine hydrochloride @ 5 mg per kg b.wt intramuscularly followed by maintenance of anaesthesia with isoflurane. Reduction of the fracture fragments was done by using closed method in one case of tibial fracture or open surgical method in other cases followed by passing of the nails from one fracture fragment to the other *via* the pre-drilled hole at the metaphyseal cortex (Fig 2). The hole at the metaphyseal cortex was created at an oblique angle by using a bone awl. For the open surgical method different approaches according to the long bone involved were used as per the technique explained by Piermattei and Greeley (1979). After achieving adequate fixation, the exposed portion of the nail was bent slightly away from the bone to decrease chances of nail migration and also to aid in pulling out of the nail at the time of nail removal, before cutting it near the surface of the bone with the help of nail cutter. Full cerclage wiring was used along with the titanium elastic nails in one case of comminuted fracture having three fracture fragments to hold the butterfly fragment along with the two fracture fragments. To facilitate removal of the nail, around 1-2 cm of the exposed portion of the nail was left outside the bone and was covered with the subcutaneous tissue followed by a single horizontal mattress or simple interrupted suture with silk (# 1) for the closure of the skin wound. Once the fracture has been healed, removal of the nail was performed by making stab skin incision at the nail insertion site followed by pulling the nail with the help of extraction plier for TEN system. The skin wound at the nail removal site was closed by applying simple interrupted suture with silk (#1). For pre-emptive analgesia and prophylactic antibiotic, Inj. Meloxicam @ 0.3 mg per kg b.wt and Inj. Cefotaxime @ 20-25 mg per kg b.wt respectively, were injected intramuscularly for 5 days. The intra-operative radiographic examinations were done using C-arm system (Allengers®-HF49R, Chandigarh, India) and for pre and post-operative radiographic examination, Siemens® X-ray machine and Konika Minolta® Computerized Radiographic System were used. Titanium elastic stable intramedullary nailing instrument set along with the titanium elastic nails having different diameters (2 mm, 2.5 mm, 3 mm and 3.5 mm) were used for the fracture repair in the study. Post-operative scoring for the bone union and bone formation were performed on the basis of extent



Fig 1: Radiographs showing diameter of medullary cavity (narrowest) and diameter of bone, length of proximal and distal fragments of fracture.



Fig 2: Intraoperative photographs showing titanium elastic stable intramedullary nailing in dog with fracture of tibia at proximal third of diaphysis.

Table 1: Bone union scores as per Lane and Sandhu (1987).

Description	Score (0, 2, 4)
With complete fracture trace	0
With incomplete fracture trace	2
Absence of fracture trace	4

Table 2: Bone formation scores as per Lane and Sandhu (1987).

Description	Score (0-4)
No evidence of bone formation	0
Bone formation in 25% of the gap	1
Bone formation in 50% of the gap	2
Bone formation in 75% of the gap	3
Bone formation in 100% of the gap	4

of bridging callus formation and disappearance of the fracture line as per Lane and Sandhu (1987) (Table 1 and 2). Radiographic staging system given by Hammer *et al*. (1985) was used for the evaluation of the different stages of bone union at different time intervals (Table 3). Post-operative functional limb usage was evaluated on the basis of degree of lameness and graded by using classification system developed by Fox *et al.* (1995) on 60th post-operative day.

RESULTS AND DISCUSSION

In this study, six dogs were having body weight of more than 15 kg, three were between 10-15 kg and one was having body weigh of less than 10 kg. Etiology of fracture, affected bone, location of fracture and type of fracture for all the cases are given in Table 4. For the confirmation of

Table 3: Staging of bone union as per Hammer *et al.* (1987).

Grade (1-5)	Callus formation	Fracture line	Stage of union
1	Homogenous bone structure	Obliterated	Achieved
2	Massive- Bone trabeculae crossingthe fracture line	Barely discernible	Achieved
3	Apparent-Bridging of fracture line	Discernible	Uncertain
4	Trace- No bridging of fracture line	Distinct	Not Achieved
5	No callus formation	Distinct	Not Achieved

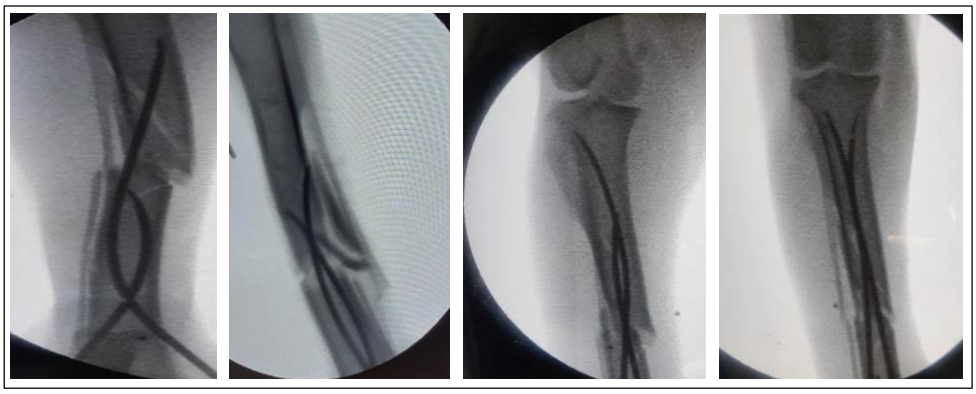

Fig 3: Intraoperative C-Arm radiographs of different dogs during titanium elastic stable intramedullary nailing.



Fig 4: Post-operative photographs showing initial weight bearing on fractured limb treated with titanium elastic stable intramedullary nailing.

proper placement of the titanium elastic nail and proper anatomical reduction of the fracture fragments, C-arm radiography was performed intra-operatively which revealed satisfactory anatomical reduction and proper placement of titanium elastic nails in the present study (Fig 3). All the cases had shown gradual improvement in weight bearing on the operated limb starting from 4th to 7th post-operative day followed by complete weight bearing on 30th post-operative day in seven cases and on 60th post-operative day all the dogs had shown complete weight bearing without lameness while moving (Fig 4 and 5). Scoring for weight bearing on the operated limb while standing and walking was done at different time intervals of examination as per the scoring system given

Table 4: Etiology of fracture, bone affected, location of the fracture and the type of fracture in dogs.

Etiology of fracture	Bone affected	Location of fracture	Type of fracture
Being stepped by buffalo	Right tibia	Proximal diaphysis	Short oblique
Automobile accident	Right femur	Mid diaphysis	Short oblique
Fall from height	Left radius-ulna	Distal diaphysis	Transverse
Fall from height	Right tibia	Mid diaphysis	Short oblique
Hit by wooden stick	Left tibia	Mid diaphysis	Transverse
Hit by wooden stick	Right tibia	Mid diaphysis	Comminuted
Automobile accident	Right tibia	Mid diaphysis	Transverse
Fall from height	Right femur	Mid diaphysis	Short oblique
Automobile accident	Right radius-ulna	Distal diaphysis	Transverse
Fall from height	Right tibia	Proximal diaphysis	Short oblique



Fig 5: Post-operative photographs after 60 days of surgery showing weight bearing on the limb treated with titanium elastic stable intramedullary nailing.



Fig 6: Postoperative radiographs of dog treated with titanium elastic stable intramedullary nailing on 15th, 30th and 60th post-operative day respectively.

by Sahu *et al*. (2017) (Table 5 and 6). Postoperative radiographic examinations at 15th, 30th and 60th days after the surgery showed satisfactory fracture alignment (Fig 6). On radiographic examination, evaluation of bone formation score and bone union score was done as per the scoring system given by Lane and Sandhu (1987). Mean±S.E. of bone formation score (BFS) and bone union score (BUS) increased from 0±0.00 at 0th day to 3.7±0.15 and 3.7±0.32 at 60th post-operative day respectively (Table 7). Stages of bone union at different time intervals of all the dogs were recorded as per Hammer *et al.* (1985) which had shown achievement of bone union in 70% cases on 30th post-operative day while on 60th post-operative day it was achieved in all the cases (Table 8).

Table 5: Weight bearing scores (0-3) during standing in all the dogs as per Sahu *et al*. (2017).

Case no.	0th day	15th day	30th day	60th day
1	0	2	3	3
2	0	3	3	3
3	0	3	3	3
4	0	2	3	3
5	0	2	3	3
6	0	3	3	3
7	0	2	3	3
8	0	2	3	3
9	0	2	3	3
10	0	2	3	3
Mean±S.E.	0.00±0.00	2.30±0.15	3.00±0.00	3.00±0.00

All the cases had shown full range of motion of both in the proximal and distal joints on 60th post-operative day on clinical examination. In the present study, satisfactory surgical wound healing was observed on clinical examination in nine cases within two weeks of surgery while in one case there was infection in sutures leading to delayed wound healing (18-20 days) due to owner negligence. On clinical examination, it was observed that there was slight migration of the nails at site of insertion in four cases (Fig 7) which were easily managed by cutting the extra length of the nail outside the skin along with regular antiseptic dressing with povidone iodine solution. The nail migration could be prevented be avoiding sudden rapid or jerky movements especially in highly active and medium to large size dogs for the initial 15 post-operative days. The nails were



Fig 7: Photographs showing nail migration observed on clinical examination in four cases.

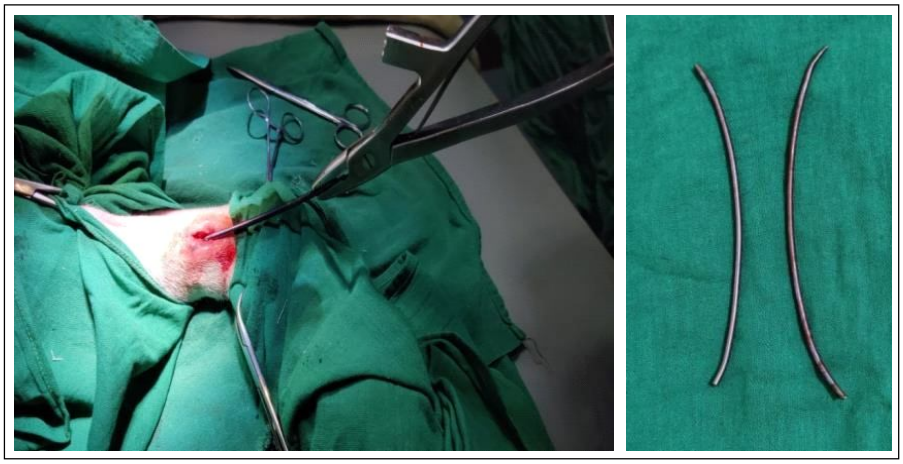

Fig 8: Photographs showing removal of titanium elastic nail with the help of extraction pliers for TENs and the nails after the removal.

Table 6: Weight bearing scores (0-4) during walking in all the dogs as per Sahu *et al.* (2017).

Case no.	0th day	15th day	30th day	60th day
1	0	3	4	4
2	0	4	4	4
3	0	4	4	4
4	0	2	3	4
5	0	2	4	4
6	0	3	4	4
7	0	2	4	4
8	0	3	4	4
9	0	2	3	4
10	0	1	3	4
Mean±S.E.	0.00±0.00	2.30±0.31	3.7±0.15	4.00±0.00

Table 7: Mean ± S.E of bone formation scores (BFS) and bone union scores (BUS) at different time intervals of examination.

Time Interval	0th day	15th day	30th day	60th day
BFS	0±0	1.9±0.28	2.8±0.25	3.7±0.15
BUS	0±0	1.2±0.32	3.0±0.33	3.7±0.32

Table 8: Stages of bone union in all the dogs treated with titanium elastic stable intramedullary nailing at different time intervals.

Case no.	15th day	30th day	60th day
1	Uncertain	Achieved	Achieved
2	Uncertain	Achieved	Achieved
3	Uncertain	Achieved	Achieved
4	Uncertain	Achieved	Achieved
5	Not achieved	Uncertain	Achieved
6	Uncertain	Achieved	Achieved
7	Not achieved	Uncertain	Achieved
8	Uncertain	Achieved	Achieved
9	Not achieved	Uncertain	Achieved
10	Uncertain	Achieved	Achieved

removed at 60th day after assessment of fracture healing status on radiographic examination and weight bearing on clinical examination (Fig 8). Grading of functional limb usage was found to be excellent in seven cases, good in two cases and fair in one case.

CONCLUSION

On the basis of clinical, orthopaedic and radiographic evaluations, it was concluded that Titanium elastic stable intramedullary nailing for the treatment of long bone fractures in dogs had good efficacy with respect to weight bearing and functional limb usage, however, migration of the nail at the insertion site was the main complication.

Conflict of interest

All authors declare that they have no conflict of interest.

REFERENCES

Aron, D.N. (1998). Practical Techniques for Fractures. In: Bojrab M.J. ed. Current Techniques in Small Animal Surgery. 4th ed. Philadelphia, Williams and Wilkins. pp. 934-941.

Cui, C., Hu, B., Zhao, L., Liu, S. (2011). Titanium alloy production technology, market prospects and industry development. *Materials and Design-Mater Design*. **32:** 1684-1691.

Flynn, J.M., Hresko, T., Reynolds, R.A., Blasier, R.D., Davidson, R., Kasser, J. (2001). Titanium elastic nails for pediatric femur fractures: A multicenter study of early results with analysis of complications. *Journal of Pediatric Orthopedics*. **21(1):** 4-8.

Flynn, J.M., Luedtke, L.M., Ganley, T.J., Dawson, J., Davidson, R.S., Dormans, J.P., Ecker, M.L., Gregg, J.R., Horn, B.D., Drummond, D.S. (2004). Comparison of titanium elastic nails with traction and a spica cast to treat femoral fractures in children. *The Journal of Bone and Joint Surgery*. **86(4):** 770-777.

Fox, S.M., Bray, J.C., Guerin, S.R., Burbridge, H. (1995). Antebrachial deformities in the dog and treatment with external fixation. *Journal of Small Animal Practice*. **36:** 316-320.

Gozna, E.R. (1982). Biomechanics of Internal Fixation. In: Biomechanics of Skeletal Injury. [Gozna, E.R., Harrington, I.J. and Evans, D.C. (eds)]. Williams and Wilkins, Baltimore. pp. 87-133.

Gyaneshwar, T., Nitesh, R., Sagar, T., Pranav, K., Rustagi, N. (2016). Treatment of pediatric femoral shaft fractures by stainless steel and titanium elastic nail system: A randomized comparative trial. *Chinese Journal of Traumatology*. **19(4):** 213-216.

Hammer, R.R., Hammerby, S., Lindholm, B. (1985). Accuracy of radiographical assessment of tibial shaft fracture union in humans. *Clinical Orthopaedics*. **199:** 233-238.

Harasen, G. (2001). Fractures involving the distal extremity of the femur. Part 1-The immature patient. *The Canadian Veterinary Journal*. **42(12):** 949-950.

Hunter, J.B. (2005). The principles of elastic stable intramedullary nailing in children. *Injury*. **36(1):** 20-24.

Lane, J.M. and Sandhu, H.S. (1987). Current approaches to experiment bone grafting. *Orthopaedics Clinics of North America*. **18:** 213-215.

Lascombes, P., Haumont, T., Journeau, P. (2006). Use and abuse of flexible intramedullary nailing in children and adolescents. *Journal of Pediatric Orthopedics*. **26(6):** 827-834.

Ligier, J.N., Metaizeau, J.P., Prevot, J., Lascombes, P. (1988). Elastic stable intramedullary nailing of femoral shaft fractures in children. *The Journal of Bone and Joint Surgery*. **70(1):** 74-77.

Mahar, A.T., Lee, S.S., Lalonde, F.D., Impelluso, T., Newton, P.O. (2004). Biomechanical comparison of stainless steel and titanium nails for fixation of simulated femoral fractures. *Journal of Pediatric Orthopedics*. **24(6):** 638-641.

Marsell, R. and Einhorn, T.A. (2011). The biology of fracture healing. *Injury*. **42:** 551-55.

Mazda, K., Khairouni, A., Penneçot, G.F., Bensahel, H. (1997). Closed flexible intramedullary nailing of the femoral shaft fractures in children. *Journal of Pediatric Orthopaedics*. **6(3):** 198-202.

Piermattei, D.L. and Greely, R.G. (1979). An Atlas of Surgical Approaches to the Bones of Dog and Cat. W.B. Saunders Co, Philadelphia.

Sahu, S., Pathak, R., Shah, M.A., Reetu, Jayalakeshmi, S., Darshan, Sharma, D., Aithal, H.P., Amarpal, Kinjavdekar, P., Pawde, A.M. (2017). Evaluation of locking compression plate in wedge and complex fractures of long bones in dogs. *Indian Journal of Veterinary Surgery*. **38(2):** 81-85.

Sayed, E.L., S.A., Nezwek, T.A., Varacallo, M. (2020). Physiology, Bone. Stat Pearls. Stat Pearls Publishing.

Shahar, R. (2000). Relative stiffness and stress of type I and type II external fixators: Acrylic versus stainless-steel connecting bars-a theoretical approach. *Veterinary Surgery*. **29(1):** 59-69.

Uhthoff, H.K., Bardos, D.I., Liskova-Kiar, M. (1981). The advantages of titanium alloy over stainless steel plates for the internal fixation of fractures: An experimental study in dogs. *The Journal of Bone and Joint Surgery*. **63-B(3):** 427-484.

Wall, E.J., Jain, V., Vora, V., Mehlman, C.T., Crawford, A.H. (2008). Complications of titanium and stainless steel elastic nail fixation of pediatric femoral fractures. *The Journal of Bone and Joint Surgery*. **90(6):** 1305-1313.