RESEARCH ARTICLE Indian Journal of Animal Research, Volume 59 Issue 9: 1570-1574 (September 2025)

Study on Incidence of Canine Cardiac Disorders in Jabalpur City

A. Sawhney[1], A. Shahi[1], B. Das[1], R. Vaish[1]

10.18805/IJAR.B-4866

ABSTRACT

Background: Canine cardiac disorders are one of the most common silent killers encountered in veterinary practice. The diagnosis of these disorders is an important factor to ensure proper medication and pet care. The current study was aimed to evaluate incidence of the canine cardiac disorders in Jabalpur city.

Methods: The study was conducted on 109 dogs presented at VCC, Jabalpur from October 2019 to March 2020 with clinical signs of ascites, obesity, distended abdomen, weight loss, frequent coughing, difficulty in breathing, exercise intolerance, fainting or syncope, lack of energy, swelling of extremities, pale gums and hind limb weakness. All the dogs were subjected to chest X ray, electrocardiography and echocardiography. Following the diagnosis, the dogs suffering with cardiac disorders were included in the study.

Result: Of all the 109 dogs screened, 60 were found to suffering with cardiac disorders. Amongst 60 dogs, arrhythmia was encountered in 42 dogs, followed by left or bi-atrial enlargement in 07 dogs, dilated cardiomyopathy in 06 dogs, hypertrophic cardiomyopathy in 03 dogs and pericardial effusion in 02 dogs.

Key words: Cardiac disorder, Echocardiography, Electrocardiography, Radiography.

INTRODUCTION

Heart disease in dogs is almost as common as it is in humans. Cardiac diseases in canines are an extensively studied phenomenon all over the world but meagre information has been reported in India. The recognition of canine cardiac diseases had been delayed and ignored on account of lack of awareness and knowledge by the owner and inadequate diagnostic facility in our country (Devi *et al*., 2009). Cardiac disorders are reported to be the second most commonly encountered disorder after cancer (Sahoo *et al*., 2021). Despite these numbers, many people are unaware that their dog may be at risk of heart disease. It is important that every dog considered vulnerable to cardiac diseases should be examined for cardiac function during routine examination. A delay in diagnosis and treatment could result in a grave prognosis or life-threatening condition. Many a times the condition was detected too late until pronounced signs appear (Martin *et al*., 2009). The substantial involvement of heart has provoked numerous investigations leading to advancements in medical and surgical management of cardiovascular disorders. Presently access to echocardiographic facility in veterinary practice has revolutionized the field of cardiology by aiding the diagnosis and management of cardiac diseases in dogs.

MATERIALS AND METHODS

In a period of 06 months, starting from October, 2019 to March, 2020, 109 dogs having clinical signs related to cardiovascular disorders were screened at the Veterinary Clinical Complex, Nanaji Deshmukh Veterinary Science University, Jabalpur.

The dogs were firstly subjected to electrocardiographic examination for the assessment of the derangements in the heart conductivity. The dogs having deviation from the normal conduction activity were further subjected to echocardiographic and radiographic examination. A total of 60 dogs were confirmed to be having cardiac abnormalities.

Electrocardiographic examination

Electrocardiographic tracings were recorded with Cardiart electrocardiography machine (Cardiart 8408 View; BPL Limited) in a distraction free area. The dog was placed in right lateral recumbency with its leg perpendicular to the long axis of the body, on an insulated surface. The electrodes were attached to the dog's skin after shaving the hair. Generous application of coupling gel was done. Each pair of limbs were not allowed to come in contact with each other. The point just proximal to the olecranon on the lateral aspect (caudal surface of elbow) was used as reference mark for the forelimbs, whereas the point proximal to the patella (over the stifle) on the lateral aspect was used as reference mark for hind limbs. The limb leads were attached to these reference marks. Three bipolar limb leads (lead I, lead II and lead III) and three augmented unipolar limb leads (aVR, aVL and aVF) were used (Fig 1).

[1]Department of Veterinary Surgery and Radiology, College of Veterinary Science and Animal Husbandry, Nanaji Deshmukh Veterinary Science University, Jabalpur-482 001, Madhya Pradesh, India.

Corresponding Author: A. Sawhney, Department of Veterinary Surgery and Radiology, College of Veterinary Science and Animal Husbandry, Nanaji Deshmukh Veterinary Science University, Jabalpur-482 001, Madhya Pradesh, India.
Email: sawhneyayushi@gmail.com

How to cite this article: Sawhney, A., Shahi, A., Das, B. and Vaish, R. (2025). Study on Incidence of Canine Cardiac Disorders in Jabalpur City. *Indian Journal of Animal Research*. **59(9):** 1570-1574. doi: 10.18805/IJAR.B-4866.

Submitted: 15-01-2022 **Accepted:** 18-05-2022 **Online:** 06-07-2022

ECG was recorded with paper speed of 50 mm/sec. Before each recording, a one millivolt standardization pulse was made. A longer rhythm strip was run on lead II and four or five beats were recorded on each lead. Tilley's (1985) guidelines for measuring complexes and intervals were followed for interpretation of electrocardiograms.

Radiographic examination

Digital X rays were taken for assessment of alteration of the cardiac silhouette by using 100 mA X-ray machine and CR System. The animal was placed in the left lateral recumbency and in the dorsal recumbency to obtain right lateral and ventro-dorsal views of the thoracic region. For this view, the sternum and spine were in the same horizontal plane and the front legs were pulled as far cranially as possible. Exposure times and kilovoltage were adjusted according to the technique chart. All radiographs were evaluated empirically.

Measurement of vertebral heart score (VHS)

The general principles followed for evaluation of cardiac radiographs were those advocated by Buchanan and Bucheler (1995). The vertebral heart score (VHS) compares the heart on the lateral view to the dog's thoracic vertebrae. The long axis (L) of the heart was measured from the ventral border of the left main stem bronchus to the most distant ventral contour of the cardiac apex. This dimension reflects the combined size of left atrium and left ventricle and compared this to the vertebrae starting with the cranial edge of 4th thoracic vertebra (T4) and result expressed in units of vertebral lengths. The maximum short axis (S) of the heart was measured at the widest point of the cardiac silhouette on a line perpendicular to the long axis (L) at the level of the caudal vena cava and compare this to the thoracic vertebrae, again starting from the 4th thoracic vertebra (T4) (Fig 2). Vertebral Heart Score was calculated by using the formula:

V.H.S. = L+S = No. of vertebrae traversed.

Measurement of cardio-thoracic ratio (CTR)

The Cardio-thoracic ratio (CTR) was assessed by comparing the greatest width of the heart silhouette and the distance between the thoracic walls in the same plane, according to methodology described by Mohammadyar *et al.* (2019) (Fig 3).

Echocardiographic examination

The echocardiographic examination of the dogs was carried out to evaluate the structural and functional alterations. The animals were kept in minimal stress conditions, so that the evaluation would not be affected. The hair from the thoracic area were clipped, usually between 3rd-5th inter-costal space on right side. Adequate amount of coupling gel was applied after clipping, for echocardiographic evaluation (Fig 4). Evaluation of all the dogs was performed by using sector transducer having frequency 2-4 MHz by using the ultrasonography machine. Assessment of the cardiac parameters was done by using following views:

Long axis view

By placing the transducer over the palpable apex beat, on the right side with no angulation. At this position, left side of heart, ventricle and atrium was visualized, with part of right side. From the above position, the transducer was slightly rotated anticlockwise, while tilting it dorsally. This caused the sector plane to transect the aorta and permit the examination of left ventricular outflow tract and 4 chamber view.

Short axis view

Transverse or short axis image of the heart was obtained by rotating the transducer towards the sternum with reference mark turned 90 degrees from its location from long axis plane. This view permitted the examination of left ventricle with papillary muscle, mitral valve, heart-base aorta and heart base pulmonary artery. B-mode was used for the visualisation of the chambers and normal morphology of the heart and M-mode for the assessment of the diameter of various chambers of heart whereas, colour Doppler was used to check valvular leakage (valvular regurgitation).

RESULTS AND DISCUSSION

Incidence

Total 6245 cases were registered at Veterinary Clinical Complex (V.C.C.) during the period of six months (October, 2019 to March, 2020). Out of these 4509 (72.20%) cases were of canine, in which 109 (2.41%) were found having



Fig 1: Placement of electrical probes during electrocardiographic examination in a dog.

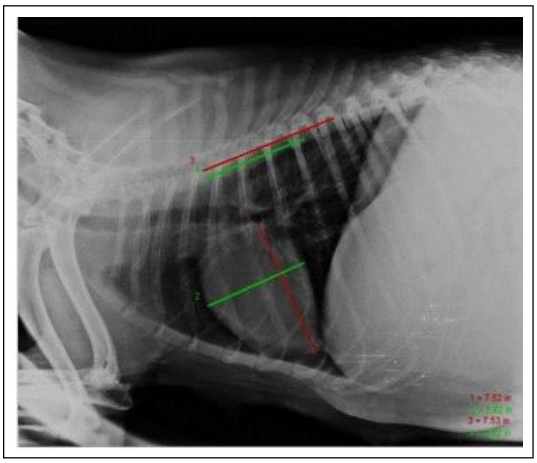

Fig 2: Assesssment of verterbral heart score (VHS) to ascertain the cardiomegaly.

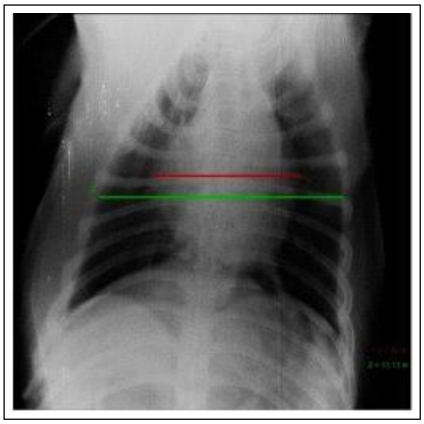

Fig 3: Estimation of cardio-thoracic ratio (CTR) in a ventro-dorsal chest radiograph in dog.



Fig 4: Placement of sector probe in a cut-out table to perform echocardiographic examination.

various symptoms of cardiac disease such as laboured breathing, exercise intolerance, distended abdomen, frequent coughing, dyspnoea, hind limb weakness, ascites, obesity and fainting or collapsing. On further examination, out of 109 cases only 60 (1.30%) cases were found to be of cardiac origin (Table 1). Badsar *et al.* (2018) reported that overall prevalence of cardiac abnormalities in dogs was 2.41% (40/1655) while Haritha *et al.* (2017) and Himalini *et al.* (2017) reported overall prevalence of cardiovascular diseases to be 1.77% and 1.61%, respectively which is in accordance to the present study.

Distribution of dogs after screening

The data recorded is presented in Table 2. Among the total cases (109) showing clinical signs of cardiac affections majority of dogs, 60 (55.04%) were diagnosed with various types of arrhythmias, pericardial effusion, dilated cardiomyopathy and hypertrophy. The diagnostic modalities revealed that 15 (13.76%) cases were having kidney affections, 26 (23.85%) cases showed ascites due to non-cardiac origin and 8 (7.33%) cases were having splenic and other affections. Vishnurahav *et al.* (2018) screened 203 suspected cases for cardiac disorders and reported the prevalence of cardiac disorders to be 28.07% (57/203) whereas Badsar *et al*. (2018) and Kumar *et al.* (2011) reported 40.81% and 55.30% prevalence of cardiac diseases amongst suspected cases. The clinical signs that are expressed by dogs having cardiac disease can be exhibited while ailments of other organ systems also. Hence, the cases having symptoms related to cardiac disease can also be caused by derangement in physiological activity of other biological tissues too.

Age wise incidence of dogs affected with cardiac disorders

Complete history of all dogs suffering with cardiac affections were recorded which included age, sex, breed, diet and duration of symptoms. Maximum incidence (48.33 per cent) of various affections diagnosed during study was related to age group of 5-10 years followed by below 5 years (36.67%) and above 10 years (15.00%) (Table 3). Haritha *et al*. (2017) reported highest prevalence (50.44%) in dogs between 5-10 years. Similar findings were reported by Montoya (2002), Jeyaraja *et al*. (2008) and Hoque *et al.* (2019), supporting the findings of this study. This might be due to many factors such as poor diet; lack of exercise and overweight represented the disease up to middle age as observed in the present study; the disease is not always due to senile changes. Some breeds such as Labrador and German Shepherd are predisposed to cardiac diseases, this might also be a reason to develop the disease in an early age.

Sex wise incidence of dogs affected with cardiac disorders

During the study period total 4509 cases were presented at Veterinary Clinical Complex out of which 3045 were male and 1464 were female. Out of which 42 males and 18 females were suffering with various cardiac affections. Thus, the incidence was accounted to be 1.37% and 1.22%, respectively (Table 4). Whereas among 60 dogs suffering

Table 1: Incidence of cardiac disorders in dogs.

Detail of cases	Number of cases	Per cent
Cases registered at Veterinary Clinical Complex (V.C.C.)	6245	-
Total number of canine cases	4509	72.20
Cases having various signs related to cardiac affections	109	02.41
Cases of various cardiac disorders in canine	60	01.30

Table 2: Distribution of dogs after screening.

Group no.	Description	No. of cases	Per cent
1	Cardiac affections	60	55.04
2	Ascites	26	13.76
3	Kidney affections	15	23.85
4	Splenic and other affections	08	07.33
	Total	109	100.00

Table 3: Age wise incidence of dogs affected with cardiac disorders.

Age group (years)	No. of dogs	Per cent
Below 5	22	36.67
5-10	29	48.33
Above 10	09	15.00
Total	60	100.00

Table 4: Sex wise incidence of dogs affected with cardiac disorders.

Sex	Total no. of registered dogs	No. of dogs with cardiac affections	Per cent
Male	3045	42	01.37
Female	1464	18	01.22

Table 5: Breed wise incidence of dogs affected with cardiac disorders.

Breed of dog	No. of dogs	Per cent
Labrador	20	33.33
Mongrel	15	25.00
German Shepherd	08	13.33
Pomeranian	04	06.66
Saint Bernard	03	05.00
Golden Retriever	02	03.33
Lhasa Apso	02	03.33
Pug	01	01.67
Rottweiler	01	01.67
Beagle	01	01.67
Akita cross	01	01.67
Dobermann	01	01.67
Boxer	01	01.67
Total	60	100.00

with cardiac disorders, 42 (70%) were male and 18 (30%) were female. Kumar (2019), Vishnurahav *et al.* (2018) and Haritha *et al.* (2017) also reported the similar trend regarding the gender predilection. The greater incidence (1.37%) in male dogs can be attributed to the large number of male dogs being referred to VCC or more likability of the owners for male dogs.

Breed wise incidence of dogs affected with cardiac disorders

There was no breed predilection noticed, however more cases were observed in Labrador (33.33%) followed by Mongrel (25.00%), German Shepherd (13.33%) and Pomeranian (06.67%) (Table 5). Similar findings have also been reported by Hoque *et al.* (2019), Badsar *et al.* (2018) and Reetu *et al.* (2017) as these authors also reported highest prevalence rate in Labradors. Labrador were affected mostly might be due to genetic predisposition of breed to the cardiac affection however no such examination was performed in the present study. Another reason was attributed to presence of obesity in Labradors with lack of exercise which can lead to significant health problems such as joint problems, metabolic and digestive disorders, back pain and heart disease. In other breeds also idiopathic cardiac affection could develop or it may be due to various predisposing factors which were beyond the capacity of present research work.

The distribution of the 60 dogs having cardiac disorders was recorded as follows:

Arrhythmia in 42 dogs (85.71%) followed by left atrial or bi-atrial enlargement in 07 dogs (14.28%), dilated cardiomyopathy (DCM) in 06 dogs (10%), hypertrophic cardiomyopathy (HCM) in 03 dogs (05%) and pericardial effusion (PE) in 2 dogs (3.33%).

CONCLUSION

The overall incidence of cardiac disorders in a period of 6 months, from October, 2019 to march, 2020 was recorded to be 1.30%, in Jabalpur city. The incidence of cardiac disorders was recorded more to be in male dogs (1.37%) than female dogs (1.22%). The incidence was more in Labradors followed by Mongrel. The arrhythmia was encountered to be the most common cardiac disorder followed by left or bi-atrial enlargement and DCM. Hence it can be ascertained that the cardiac disorders are an important cause of suffering in dogs that are often the silent- killers. So, it's important to develop a proper routine to diagnose cardiovascular disorders at various facilities to diagnose and treat the cardiac disorders, as early as possible. The largest portion of the favourable outcome of the treatment depends on the early and accurate diagnosis of the condition prevailing. So, echocardiography is the gold standard for the diagnosis of cardiac disorders and is definitely to be combined with electrocardiographic examination and radiographic examination for proper diagnosis of the condition.

ACKNOWLEDGEMENT

The authors are grateful to the Dean, College of Veterinary Science and Animal Husbandry, NDVSU, Jabalpur for providing the necessary facilities to carry out the research work. This study was not possible by kind cooperation and awareness of pet lovers of Jabalpur (M.P.).

Conflict of interest

All authors declare that they have no conflict of interest.

REFERENCES

Badsar, P., Mehta, H.K., Nema, S.P. and Kumbhkar, Y. (2018). Cardiac abnormalities in dogs-A diagnostic study. *Intas Polivet*. **19:** 118-120.

Buchanan, J.W. and Bucheler, J. (1995). Vertebral scale system to measure canine heart size in radiographs. *Journal of American Veterinary Medical Association*. **206:** 194-199.

Devi, S., Jani, R.G., Anne, F.K. and Singh, R.D. (2009). Study on clinical symptoms in canine cardiac diseases. *Veterinary World*. **2:** 307-309.

Haritha, G.S., Kumar, K.S., Ayodhya, S. and Kumar, V.V.V.A. (2017). Prevalence of cardiac disorders in canines - A clinical study. *Intas Polivet*. **18:** 148-152.

Himalini, Gupta, S.K., Bhardwaj, R.K., Singh, R. and Gupta, A.K. (2017). Study on prevalence of cardiovascular diseases in canines of Jammu. *Journal of Animal Research*. **7:** 201-204.

Hoque, M., Saxena, A.C., Reetu, Gugjoo, M.B. and Bodh, D. (2019). Cardiac diseases in dogs. *Indian Journal of Animal Health*. **58:** 01-20.

Jeyaraja, K., Gowri, B., Nambi, A.P. and Vasu, K. (2008). Echocardiographic evaluation of dilated cardiomyopathy in dogs. *Indian Veterinary Journal*. **85:** 983-984.

Kumar, G. (2019). Evaluation of cardiac functions through cardiac biomarkers, thoracic radiography and echocardiography in dogs. M.V.Sc. thesis (Veterinary Surgery and Radiology), Lala Lajpat Rai University of Veterinary and Animal Sciences, Hisar.

Kumar, K.S., Rao, D.S. and Nagaraj, P. (2011). Dilated cardiomyopathy in dogs: A study for three years (2006-2009). *Vet Scan.* **6:** 93.

Martin, M.W.S., Stafford-Johnson, M.J. and Celona, B. (2009). Canine dilated cardiomyopathy: a retrospective study of signalment, presentation and clinical findings in 369 cases. *Journal of Small Animal Practice*. **50:** 23-29.

Mohammadyar, L., Molazem, M., Esmaili Nejad, M. and Parseh, A. (2019). Follow up the treatment process of mitral valve diseases by radiography and echocardiography in dogs. *Iranian Journal of Veterinary Medicine*. **13(2):** 123-130.

Montoya, J.A. (2002). Dilated cardiomyopathy: Sexual and breed-related differences. World Small Animal Veterinary Association Congress, Columbia.

Reetu, Hoque, M., Saxena, A.C., Pawde, A.M., Verma, N.K., Kalaiselvan, P. and Dey, S. (2017). Incidence of cardiac diseases in dogs: A retrospective study. *Indian Journal of Veterinary Medicine*. **37:** 64-67.

Sahoo, K.K., Gupta, D.K., Mourya, A., Shahi, A., Das, G., Pathak, S., Kumar, S., Sawhney, A. and Ahirwar, M.K. (2021). Electrocardiographic interpretations of cardiac disorders in dogs. *Indian Journal of Animal Research*. **55(12):** 1476-1483. doi: 10.18805/IJAR.B-4551.

Tilley, L.P. (1985). Analysis of P-QRS-T Deflections. In: Essentials of Canine and Feline Electrocardiography, 2nd Edn, [Lea and Febiger], Philadelphia, U.S.A. pp. 57-97.

Vishnurahav, R.B., Ajithkumar, S., Pillai, U.N., Madhvan, U.N., Martin, K.D.J. and Aravindakshan, T.V. (2018). Occurrence of cardiac diseases in dogs: A retrospective study. *Journal of Entomology and Zoology Studies*. **6:** 1901-1903.