RESEARCH ARTICLE Indian Journal of Animal Research, Volume 58 Issue 3: 422-428 (March 2024)

Oral Fibrosarcoma in Dog: Cytological, Histopathological and Immunohistochemical Diagnosis

Amishi[1], Yamini Verma[1], Madhu Swamy[1], Shobha Jawre[1], Amita Dubey[1], Nidhi Rajput[2] 10.18805/IJAR.B-4873

ABSTRACT

Background: Canine oral fibrosarcomas are locally invasive malignant mesenchymal tumors and the third most frequently occurring neoplasia of oral cavity of dogs. The present study was conducted to record pathological features of oral fibrosarcomas in canines.

Methods: During the study period (September 2020- April 2021), a total of 18 cases of canine oral neoplasia were reported and amongst these fibrosarcoma was diagnosed in five animals (27.78%). The blood samples were collected from all the dogs and the excised tumor mass was processed at Department of Veterinary Pathology, Co.V.Sc. and A.H., Jabalpur.

Result: The hematological profile of all the five dogs showed no variation however; serum biochemical analysis revealed hypercalcemia. The serum MDA concentration was elevated in dogs with fibrosarcoma, indicating oxidative stress. The gross morphology of the tumors included red to pink colored irregular masses, hard in consistency and firmly attached to the underlying tissue. Cytologically, the impression smears revealed spindle shaped cells with round to elongated nuclei along with strands of collagen fibres. Upon histopathological examination proliferation of fibrous connective tissue was observed in the sub-mucosa. Higher magnification revealed several immature spindle shaped fibroblasts along with scanty amounts of collagenous matrix. Masson's trichome staining also exhibited blue stained collagen deposition. Mitotic figures were numerous (8.4 mitosis/10 hpf). The tissue sections stained by modified silver colloid staining were examined at 1000 × magnification. Mean Ag-NOR count of the silver nitrate stained tissue sections was enumerated to be 9.15 dots/nucleus. Immunohistochemical examination detected CD31 immunopositivity in the tissue sections as brown staining of the infiltrating blood vessels, indicating neovascularization of the tumor.

Key words: Canines, CD31 immunohistochemistry, Fibroblasts, Histopathology, Oral fibrosarcoma.

INTRODUCTION

Cancer is considered one of the leading causes of death in canines worldwide and oral tumors accounts for 6-7% of all canine malignancies (Frazier *et al.,* 2012). Oral fibrosarcoma is the third most common malignant tumor of the oral cavity of dogs, representing 8-25% of all canine oral neoplasms (Liptak and Withrow, 2013). Oral fibrosarcomas are locally, invasive malignant mesenchymal tumors of the oral cavity of dogs, originating from the connective tissue cells. They usually appear as solitary, nodular, non- pigmented lesions that are less likely to ulcerate, when compared to other oral neoplasms. The mean age of presentation in dogs is 7 to 8 years (Todoroff and Brodey, 1979; Liptak and Withrow, 2013), with fibrosarcoma being often diagnosed in slightly younger dogs than those with oral melanoma or squamous cell carcinoma. Dogs under 5 years of age have also been reported to develop oral fibrosarcomas (Todoroff and Brodey, 1979; Hoyt and Withrow, 1984). Medium to larger breeds of dogs tends to be over-presented with the neoplasm (Martano *et al.,* 2018). There is no sex predilection; however, the tumor is reported to have a male predisposition in several studies (Todoroff and Brodey, 1979; Hoyt and Withrow, 1984; Martano *et al.,* 2018). Canine fibrosarcomas of oral cavity are most commonly localized in the gingiva (56-87%) (Simons, 2015; Munday *et al.,* 2017); with approximately equal occurrence in the maxillary and mandibular gingiva (White, 1991; Girish *et al*., 2016).

[1]Department of Veterinary Pathology, College of Veterinary Science and Animal Husbandry, Nanaji Deshmukh Veterinary Science University, Jabalpur-482 001, Madhya Pradesh, India.
[2]School of Wild Life Forensic and Health, Nanaji Deshmukh Veterinary Science University, Jabalpur-482 001, Madhya Pradesh, India.

Corresponding Author: Amishi, Department of Veterinary Pathology, College of Veterinary Science and Animal Husbandry, Nanaji Deshmukh Veterinary Science University, Jabalpur-482 001, Madhya Pradesh, India.
Email: amishisingh876@gmail.com

How to cite this article: Amishi, Verma, Y., Swamy, M., Jawre, S., Dubey, A. and Rajput, N. (2024). Oral Fibrosarcoma in Dog: Cytological, Histopathological and Immunohistochemical DiagnosisIndian Journal of Animal Research. 58(3): 422-428. doi: 10.18805/IJAR.B-4873.

Submitted: 28-01-2022 **Accepted:** 30-05-2022 **Online:** 20-06-2022

Clinical signs are often minimal and owners usually become aware of the tumor by observing the mass. Facial swelling, drooling of blood-tinged saliva, dysphagia, halitosis and anorexia might be the clinical signs observed in most of the cases. Additionally, displacement or loss of teeth or regional lymphadenopathy may be seen in few (Munday *et al.,* 2017; Martano *et al.,* 2018). Cytological examination may exhibit several spindle shaped cells with varying degree of cellular atypical. Numerous mitosis and identification of multinucleate cells favors the diagnosis of fibrosarcoma (Munday *et al.,* 2017).

Histology of oral fibrosarcoma displays moderately to poorly differentiated large spindle shaped cells arranged in interlacing bundles and are separated by small amounts of collagenous matrix (Munday *et al.,* 2017). Frequent occurrence of mitotic figures, lesser cellular differentiation and presence of necrosis allows differentiation from fibroma. In addition, an infiltrative growth pattern deeper into the mass further confirms the diagnosis (Munday *et al.,* 2017). Distinction from amelanotic or poorly melanocytic melanoma, dominantly consisting of spindle cells, is often difficult and requires IHC using melanocytic markers. Presence of ossification aids in the diagnosis of osteosarcoma. Odontogenic tumors can be easily excluded since odontogenic epithelium is usually visible and if not, then the location of tumor away from the dental acrade favours the diagnosis of fibrosarcoma (Munday *et al.,* 2017).

Ciekot *et al.* (1994) illustrated a distinct variant of oral fibrosarcoma known as 'histologically low grade but biologically high grade fibrosarcoma', characterized by histopathologic features of a benign fibroma despite aggressive biological behavior.

Canine oral fibrosarcomas are locally invasive tumors with high local recurrence rates of about 57%. Although, distinct metastasis is less commonly detected but may occur in 0-35% cases (Todoroff and Brodey, 1979; Frazier *et al.,* 2012; Sarowitz *et al.,* 2017). Thereby, the major challenge is achieving local control. Treatment and prognosis of fibrosarcomas in dogs usually depends upon the location of mass within the oral cavity, relative size and stage of the tumor (Girish *et al.*, 2016). Conservative surgical excision of the mass is the conventional treatment most frequently adopted for oral fibrosarcomas (Ciekot *et al.*, 1994; Frazier *et al.,* 2012); however multimodality treatment, primarily including combination of surgery and radiation therapy is considered the mainstay of treatment (Hoyt and Withrow, 1984; Gardner *et al.,* 2015; Sarowitz *et al.,* 2017).

The current investigation was undertaken to study the occurrence of oral fibrosarcoma in canines and its pathological features.

MATERIALS AND METHODS

During the study period spanning from September 2020 to April 2021, a total of 7,371 dogs irrespective of age, sex and breed were registered at Veterinary Clinical Complex (VCC), College of Veterinary Science and A.H., Jabalpur. The dogs were screened for oral cavity affections.

Detailed history of the cases was collected and dogs affected with oral neoplasia were subjected to clinical examination. Blood and serum samples were procured and analyzed for hematological and biochemical examination, respectively. Assessment of oxidative stress was also performed by estimating serum malondialdehyde (MDA) concentration in serum of dogs with oral tumors. Blood samples were also collected from six apparently healthy animals (control). The study was approved by Institutional Animal Ethics Committee (01/IAEC/Vety./2020). Biopsy samples were collected aseptically from growth found in the gums, lips, tongue, or palate and the gross morphology of tumor masses were recorded. For cytological examination, impression smears were prepared from the cut surface of the masses and stained with Methylene blue stain. Representative tissue samples from the surgically excised tumor masses were preserved in 10% neutral buffered formalin for examining the histopathological details. The samples were processed by standard paraffin embedding technique, sectioned at 4-5 µm thickness and stained with routine HandE staining method (Gridley, 1960). The mitotic index (MI) was calculated by counting the number of mitosis in 10 active fields of H&E stained sections under 400X magnification, selected at random. The duplicate tissue sections were stained with Masson's trichrome stain and/or Van Gieson stain for the demonstration of collagen fibers (Gridley, 1960). Tissue sections stained with colloidal silver nitrate were examined to identify and enumerate the argyrophilic nucleolar organizer regions (Ag-NOR) following the method described by Crocker (1992). Areas with maximum tumor cell concentration were selected as Ag-NOR dots. Ag-NOR in ten consecutive nuclei were counted and the mean value per nucleus was calculated for each sample.

The duplicate tissue sections were also subjected to immunohistochemical (IHC) staining using CD31 (cluster of differentiation) antibody to investigate tumor angiogenesis. For IHC, 2-3 micron thick paraffin sections were deparaffinized in xylol and rehydrated in graded alcohol series. The slides were immersed in retrieval solution (Biomarq citrate buffer at pH 6.0). Antigen retrieval was performed using Montage opus antigen retrieval system (Diagnostic BioSyatems) under high pressure for 15 minutes. Endogenous peroxidase block was done using 3% hydrogen peroxide. Tissue sections were incubated with Polyclonal CD31 (Invitrogen) antibody at 1:50 dilution for 45 minutes at 37°C. A commercial secondary antibody kit *i.e.*, Polyexcel HRP/DAB detection system (PathnSitu Biotechnologies) was used having diaminobenzidine (DAB) as chromogen. The slides were counterstained with hematoxylin and examined under light microscope.

RESULTS AND DISCUSSION

During the study period, a total of 42 dogs were diagnosed with oral affections. The prevalence of oral cavity affections in canines was recorded as 0.57 per cent. Amongst these, a total of 18 cases (42.86%) of oral neoplasia were recorded during the present study, while other 24 dogs were affected with inflammatory oral affections. Out of the 18 surgically excised masses from the oral cavity of dogs, a total of five cases revealed the features of fibrosarcoma (n=05). In the present study, the percentage of canine oral fibrosarcoma was estimated to be 27.78% (05/18). Canine oral fibrosarcoma is the third most frequently encountered malignant mesenchymal tumor affecting the oral cavity of dogs.

The current investigation describes the gross morphology, cytological and histopathological details of canine oral fibrosarcoma accompanied by immunohistochemical expression of CD31.

Demographic profile of dogs with oral fibrosarcoma

In the study, the mean age of dogs diagnosed with fibrosarcoma was recorded as 6.2 years (Range= 2 years to 9 years). In the investigation, 60% of the animals affected were male while 40% were female. Neoplasia is generally considered as a disease in aging animals. Our findings were in accordance to the reports of Frazier *et al.* (2012), Kotrappa *et al.* (2014) and Gardner *et al.* (2015). Though, oral tumors were reported to occur at higher frequency in male animals by Gardner *et al.* (2015), Simons (2015) and Putnova *et al.* (2020).

The first case was reported in a female German shepherd animal having a reddish brown irregular mass in the lower left gum. While in the second case, growth was observed on upper right gum and hard palate of a female Pomeranian dog (Fig 1). In two male Labrador retriever animals of 8 years and 2 years respectively, pink color irregular growths were located in the lower left gums of both animals. While in the third male Labrador dog, the growth was seen in the upper left gum; at the level of premolars (Table 1).

All the animals recovered following surgery and showed marked improvement in the clinical condition. However, the female German shepherd was presented with similar manifestation after approximately a month and the female Labrador was also reported with the recurrence of the tumor mass. The mass was surgically excised from the both the animals following reoccurrence. The other three animals did not showed tumor reoccurrence.

Clinical pathology

The detailed clinical examination of the animals revealed halitosis, excessive salivation, oral pain and difficulty in prehension. Mild facial swelling was also observed in all the five cases. The hemogram of all the five animals with fibrosarcoma was within the normal range except for one case with low hemoglobin and high TLC count. The serum biochemical profiles showed elevated alkaline phosphatase and serum calcium concentrations, however no variation was seen in levels of total serum protein and albumin. In the present study, the level of MDA in serum of dogs with fibrosarcoma was found to be 5.234±0.170 nmol/mL, which was higher as compared to the control animals (1.26±0.56 nmol/mL) (Table 2).

The results of the present study were in concurrence with the observations made by Girish *et al.* (2016) and

Table 1: Demographic profile of dogs with oral fibrosarcoma.

Breed	Age	Sex	Location	Size (cm)	Shape	Consistency	Color
German shepherd	6 yrs	F	Lower left gum at the level of premolars	5.2	Irregular	Hard	Reddish brown
Pomeranian	9 yrs	F	Upper right gum at the level of molars and hard palate	3.2	Irregular	Firm	Pink
Labrador	8 yrs	M	Lower left gum at the level of premolars	2.3	Irregular	Firm	Pink
Labrador	2 yrs	M	Lower left gum at the level of first and second premolars	1.6	Irregular	Hard	Reddish pink
Labrador	6 yrs	M	Upper left gum at the level of premolars	3.3	Irregular	Firm	Pink



Fig 1: Pink irregular growth on upper right gum and hard palate of a 9 years old female Pomeranian dog.

Martano *et al.* (2018). Cancer cells are highly metabolically active and hypoxic cells and due to massive growth and insufficient vascular irrigation tend to produce increased levels of reactive oxygen species causing oxidative stress in animals (Arfin *et al*., 2021). The data available on oxidative stress parameters in dogs bearing oral cancer is scarce, however, elevated levels of MDA in serum has been reported by Macotpet *et al*. (2013), similar to the present study.

Pathology

The gross appearance of the oral mass in all the five cases appeared as red to pink color, irregular growth arising from the gingival mucosa. The tumor was hard in consistency and firmly attached to the underlying tissue. For cytological diagnosis, most fibromas and fibrosarcomas often yield fewer cells owing to high cellular adhesion. The cytological appearance of cells in fibrosarcoma showed spindle shaped cells with round to elongated nuclei, mild to moderate anisokaryosis and basophilic cytoplasm (Fig 2).

Histopathology of oral fibrosarcoma revealed proliferation of fibrous connective tissue in the sub-mucosa. On higher magnification immature fibroblasts were seen as spindle shaped cells arranged in interlacing bundles along with scanty amounts of collagenous matrix (Fig 3). Microscopically, the fibroblasts were visualized as several pleomorphic spindle cells having elongated nuclei and large open nucleoli. Proliferation of fibrous connective tissue was demonstrated as red color collagen fibers upon Van gieson's staining, while the cornified epithelium and muscle appeared yellow. Masson's trichome staining also exhibited dense collagen deposition stained blue with keratin cover and muscle fibers appearing red in color (Fig 4). Mitotic figures were numerous and the mean count of mitotic index was calculated to be 8.4 mitosis/10 high power fields (Fig 5). The tissue sections stained by modified silver colloid staining were examined under light microscope. The mean Ag-NOR count of the five cases was enumerated to be 9.15 dots/nucleus (Fig 6).

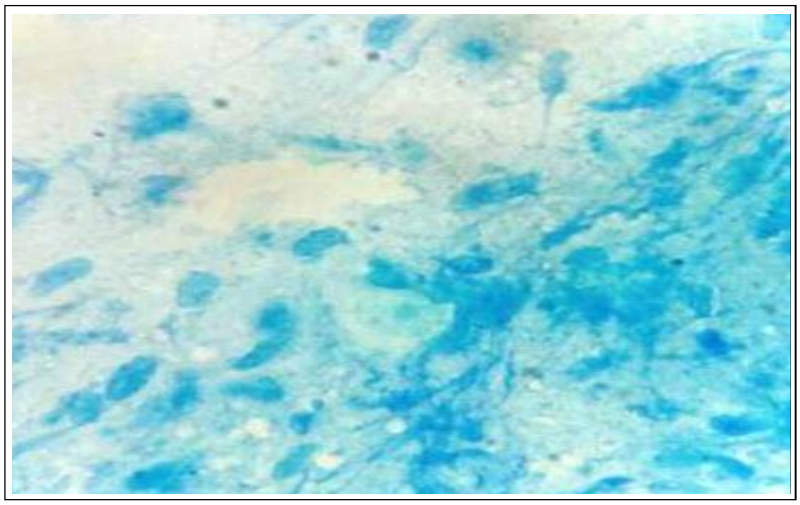

Fig 2: Impression smear showing spindle cells along with strands of collagen. Methylene blue × 1000.

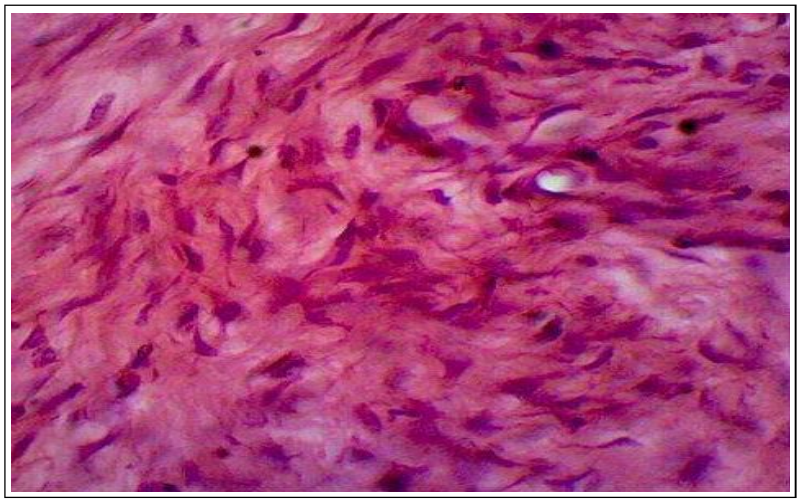

Fig 3: Microscopic section showing several immature fibroblasts along with few collagen fibres. H&E × 400.

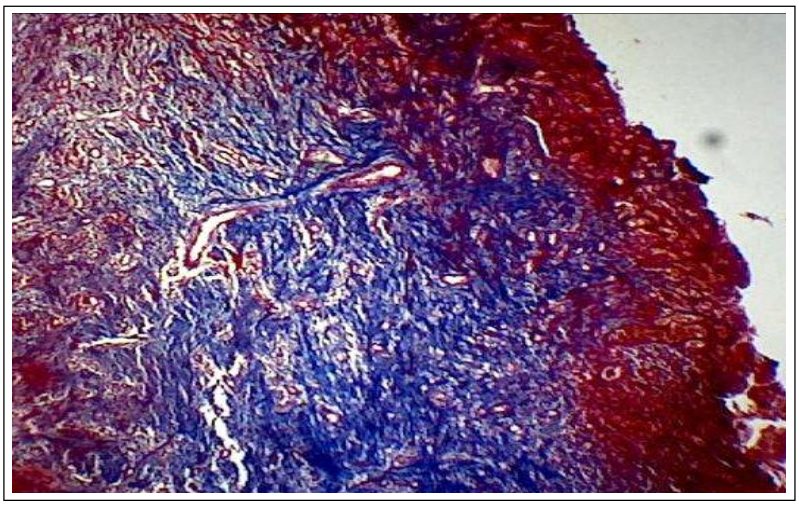

Fig 4: Microscopic section showing fibrous connective tissue stained blue. Masson's trichome × 200.

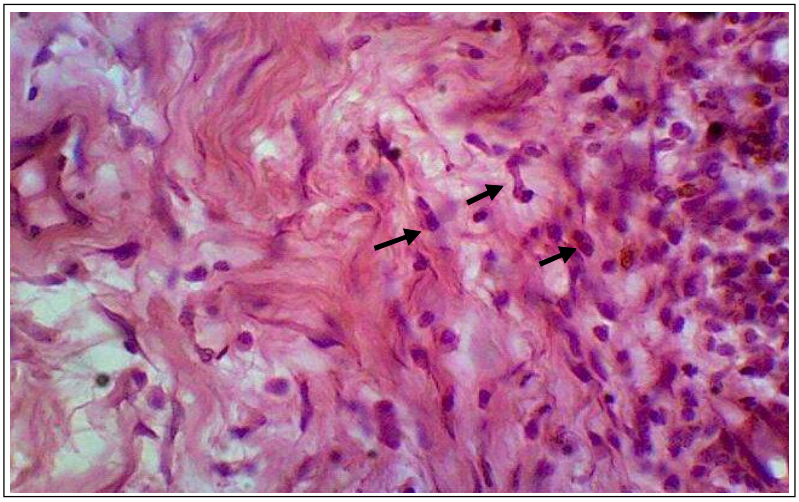

Fig 5: Microscopic section of fibrosarcoma showing mitosis (arrow). H&E × 400.

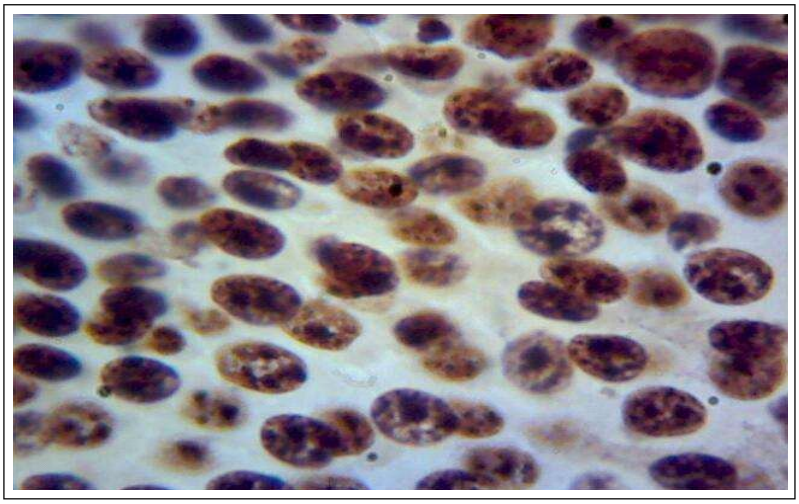

Fig 6: Microscopic section of fibrosarcoma showing Ag-NOR dots in the nucleus. Silver Nitrate × 1000.

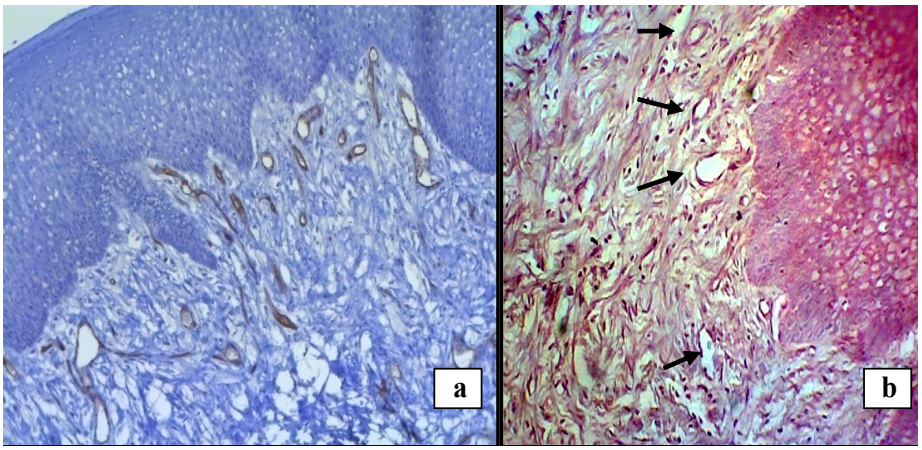

a. CD31 immunopositivity shown as brown stained of blood vessels, IHC × 100.
b. H&E × 100 (arrow).

Fig 7: Microscopic section of fibrosarcoma showing infiltrating vessels in the sub-mucosa.

Table 2: Clinical profile of the dogs with oral fibrosarcoma.

Parameter	Mean±SE	
	Oral fibrosarcoma (n=05)	Control (n=06)
Hb (g/dL)	14.51±1.42	15.24±0.52
TEC (×10^6/mm^3)	6.14±0.37	5.94±0.21
PCV (%)	43.11±2.59	44.86±1.79
TLC (×10^3/ mm^3)	11.58±3.3	10.09±0.55
Total protein (g/dL)	5.88±0.62	5.43±00.22
Albumin (g/dL)	1.78±0.32	2.85±00.12
Alkaline phosphatase (IU/L)	187.57±17.79	81.16±01.41
Calcium (mg/dL)	41.86±05.13	8.80±00.27
MDA (nmol/mL)	04.13±0.17	01.26±0.11

In the present study, expression of cluster of differentiation (CD31) marker was employed to investigate the tumor angiogenesis. CD31 immunopositivety in tissues is detected by brown staining of the blood vessels. The tissue samples of fibrosarcoma showed brown stained blood vessels infiltrating into the sub-mucosa, indicating neovascularization of the neoplasm. Numerous blood vessels were also observed in H&E stained sections (Fig 7).

The gross observations noticed in the present study were compatible with the reports of Gardner *et al.* (2015) and Simons (2015). Girish *et al.* (2016) observed oral fibrosarcoma as irregular pink growth, hard in consistency and deeply embedded in gums along with upper incisors and canine teeth. Munday *et al.* (2017) stated that canine oral fibrosarcomas develop most frequently in the gingiva (56-87%), followed by palate, lips and check and gums. They occur at almost equal frequency in mandibular and maxillary gingiva. Sumanth (2018) also reported a case of fibrosarcoma in the oral cavity of a Spitz dog as red colored, irregular, hard growth in the lower jaw. The cytological findings were in agreement with the observations made by Munday *et al.* (2017). The histological details of fibrosarcoma have been recorded by many previous workers (Frazier *et al.*, 2012; Girish *et al.*, 2016; Wingo, 2018), which were similar to our findings. According to Sumanth (2018) histologically, fibrosarcoma was characterized by spindle cells arranged in interwoven pattern. Individual cells showed elongated nuclei and mitotic figures. Higher magnification revealed higher cellularity and a few areas of necrosis.

CD31, also designated as PECAM-1 (platelet endothelial cell adhesion molecule 1), is a six domain transmembrane glycoprotein and is present on the surface of platelets, monocytes, macrophages, neutrophils and constitutively present on the endothelial intercellular junction (Pusztaszeri *et al.*, 2006). On account of its angiogenic role, it mediates endothelial cell adhesion during angiogenesis and transendothelial migration as well. The studies regarding the role of CD31 in oral tumors of canines are inadequate. However, Cushing *et al.* (2010) reported increase in number of microvessels in the tissue of squamous cell carcinoma of the oral cavity of dog. These vessels were positive for CD31, suggesting neovascularization of the mass.

CONCLUSION

The characteristics histopathology, including fibrous tissue proliferation, several immature spindle shaped fibroblasts along with few collagen strands and marked neovascularization, were suggestive of fibrosarcoma. Veterinarians generally underestimate the importance of routine oral examination in dogs; thereby oral tumors remain undiagnosed in the early stages leading to a poor prognosis. Owing to the increasing incidences of canine oral neoplasm, studies to evaluate the biological behavior and pathological features of all the types of tumor occurring in the oral cavity of dogs becomes a necessity in the present scenario.

Conflict of interest

All authors declared that they have no conflict of interest.

REFERENCES

Arfin, S., Jha, N.K., Jha, S.K., Kesari, K.K., Ruokolainen, J., Roychoudhury, S., Rathi, B., Kumar, D. (2021). Oxidative stress in cancer cell metabolism. Antioxidants. 10: 642.

Ciekot, P.A., Powers, B.E., Withrow, S.J., Straw, R.C., Ogilvie, G.K., LaRue, S.M. (1994). Histologically low-grade, yet biologically high-grade, fibrosarcomas of themandible and maxilla in dogs: 25 cases (1982-1991). Journal of the American Veterinary Medical Association. 204: 610-615.

Crocker, J. (1992). Nucleolar Organizer Regions and Fibrillar Centres. In: Diagnostic Molecular Pathology. A Practical Approach. [Herrington, C.S., Mc Gee, J.O.D. (ed.)]. Oxford University Press, Oxford. pp. 221-238.

Cushing, T., Barnard, S., Fleis, R., Peters, R. (2010). Pseudoangiomatous squamous cell carcinoma in the oral cavity of a dog. Journal of Veterinary Diagnostic Investigation. 22: 299-302.

Frazier, S.A., Johns, S.M., Ortega, J., Zwingenberger, A.L., Kent, M.S., Hammond, G.M., Rodriguez, C.O., Steffey, M.A., Skorupski, K.A. (2012). Outcome in dogs with surgically resected oral fibrosarcoma (1997-2008). Veterinary Comparative Oncology. 10: 33-43.

Gardner, H., Fidel, J., Haldorson, G., Dernell, W., Wheeler, B. (2015). Canine oral fibrosarcomas: A retrospective analysis of 65 cases (1998-2010). Veterinary and Comparative Oncology. 13: 40-47.

Girish, B.C., Shilpa, V.T., Manjunatha, D.R. (2016). Surgical management of oral fibrosarcoma in a dog. Intas Polivet. 17: 591-592.

Gridley, M.F. (1960). Manual of Histological and Special Staining Technique. McGraw-hill Book Company, New York. pp. 202.

Hoyt, R.F. and Withrow, S.J. (1984). Oral malignancy in the dog. J. Am. Anim. Hosp. Assoc. 20: 83-92.

Kotrappa, Y.M., Suguna, R., Girish, B.C., Byregowda, S.M., Manjunatha, K. (2014). Cytological and histopathological studies of mesenchymal and melanotic neoplasm in dogs. Journal of Cell and Tissue Research. 14: 4471-4483.

Liptak, J.M., Withrow, S.J. (2013). Cancer of the Gastrointestinal Tract. In: Small Animal Clinical Oncology. [Withrow, S.J., Vail, D.M., Page, R.L. (ed.)]. (5th Edn.). Elsevier, St Louis, Missouri, USA. pp. 318-398.

Macotpet, A., Suksawat, F., Sukon, P., Pimpakdee, K., Pattarapanwichien, E., Tangrassameeprasert, R., Boonsiri, P. (2013). Oxidative stress in cancer-bearing dogs assessed by measuring serum malondialdehyde. BMC Veterinary Research. 9: 101.

Martano, M., Iussich, S., Morello, E., Buracco, P. (2018). Canine oral fibrosarcoma: Changes in prognosis over the last 30 years? The Veterinary Journal. 241: 1-7.

Munday, J.S., Lohr, C.V., Kiupel, M. (2017). Tumors of Alimentary Tract. In: Tumors in Domestic Animals. [Meuten, D.J. (ed.)]. (5th Edn.). John Wiley and Sons, New York, USA. pp. 499-602.

Putnova, B., Burova, J., Georgiou, M., Fichtel, T., Stehlik, L., Frgelecova, L., Skoric, M. (2020). Occurrence site of canine oral lesions: A retrospective study of 659 cases. Acta Veterinaria Brno. 89: 179-187.

Sarowitz, B.N., Davis, G.J., Kim, S. (2017). Outcome and prognostic factors following curative-intent surgery for oral tumours in dogs: 234 cases (2004 to 2014). Journal of Small Animal Practice. 58: 146-153.

Simons, K. (2015). Oral tumours in dogs: A retrospective study of 110 cases (2002 to 2014). Master thesis, Clinical Sciences of Companion Animals, Faculty of Veterinary Medicine, Utrecht University, Netherlands. pp. 5-15.

Sumanth, B.M. (2018). Pathology of tumours of canine digestive system with special reference to galectin-3 expression. Master thesis, Department of Veterinary Pathology, Kerala Veterinary and Animal Sciences University, Kerala. pp. 50-75.

Todoroff, R.J., Brodey, R.S. (1979). Oral and pharyngeal neoplasia in the dog: A retrospective survey of 361 cases. Journal of American Veterinary Medical Association. 175: 567-571.

White, R.A. (1991). Mandibulectomy and maxillectomy in the dog: Long term survival in 100 cases. Journal of Small Animal Practice. 32: 69-74.

Wingo, K. (2018). Histopathologic diagnoses from biopsies of the oral cavity in 403 dogs and 73 cats. Journal of Veterinary Dentistry. 35: 7-17.