RESEARCH ARTICLE Indian Journal of Animal Research, Volume 59 Issue 11: 1943-1947 (November 2025)

Comparative Micro and Macro Anatomical Observation on Preen Gland of Kamrupa (*Gallus domesticus*), White Leg Horn (*Gallus domesticus*) and Daothigir Fowl (*Gallus domesticus*) of Assam

A. Deka[1], M. Sarma[1], D.P. Bora[1], K.B. Devchoudhury[1], Munmun Sarma[1], P.K. Kalita[1], B.J. Deori[1] **10.18805/IJAR.B-4874**

ABSTRACT

Background: The study on the preen gland of Kamrupa, White leg horn and Daothigir fowl of Assam is of great value in regard to protection of skin and feather of avian species. The aim of this study was to evaluate the micro and macro anatomical observation of preen gland of integument system.

Methods: The present study was conducted on the preen gland of fifteen healthy, adult birds of Kamrupa, White leg horn and Daothigir fowl of Assam in Department of Anatomy and Histology, College of Veterinary Science, Assam Agricultural University, Khanapara, Guwahati, Assam, India for period of one year from 2020-2021. Those fowl were procured from different parts of Assam. The birds were sacrificed according to the method of Gracy (1968). After sacrifice, preen gland were removed very carefully from the base of the tail of fowl. After collection, the tissue samples were fixed in 10% neutral buffered formalin solution, and were processed as per the standard technique of procedure (Luna, 1968). The paraffin blocks were sectioned in Shandon Finesse microtome at 5 µm thickness and the sections were stained with Mayer's Haematoxylin and Eosin staining technique for Cellular details as per the standard method of Luna (1968).

Result: In present investigation, it was observed that, macroscopically, the preen gland or oil gland or rump gland or uropygial gland of Kamrupa, White leg horn and Daothigir fowl of Assam was situated on the dorsal aspect of the base of the tail. Microscopically, the preen gland of Kamrupa, White leg horn and Daothigir fowl of Assam was bounded by connective tissue capsule. The interlobular connective tissues were observed among the secretary tubules of the gland. The preen gland parenchyma composed of secretary tubules; duct that formed trabeculae, which were differentiated by inter tubular connective tissue.

Key words: Anatomical, Daothigir, Kamrupa, Micro, Macro, Observation, Preen gland, White leg horn.

INTRODUCTION

The Indian poultry sector is one of the most vibrant, fastest growing, agro-based, techno-commercial industry which is characterized by its industrialization, faster growth in consumption and trade than any other major agricultural sectors in the world (Bhadauria *et al.,* 2014). Kamrupa is a multi-coloured bird for rural poultry production developed under All India Coordinated Research Project on Poultry Breeding at Assam Agriculture University, Khanapara, Guwahati, Assam. It is three ways cross developed using Assam local ecotype (25%), coloured broiler (25%) and Dalhem Red (50%) population. This variety has coloured plumage, mediocre body weight and longer shanks with optimum egg production. Under backyard system, the body weight at 8 and 20 weeks is 500-650 grams and 1300-1500 grams, respectively. The male birds weigh 1800-2200 grams at 40 weeks of age the annual egg production is 118-130 eggs with an egg weight of 52 grams. In Kamrupa, the organs are not studied yet except female reproductive system. Further poultry meat as dish is very popular in North East region being 90% of the population of the meat eaters. White Leghorns are good layers laying on an average of 280 per year and sometimes reaching 300-320, with a weight of at least 55 g. White Leghorns have been much used to create highly productive egg-laying hybrids for commercial and industrial operations. Daothigir fowl is found in Bodoland region of Assam. They are mainly found in Kokrajhar, some part of Barpeta, Nalbari, Bongaigaon and Dhubri on the north bank of Brahamaputra River. These birds are reared by Bodo community of Assam. They rear mainly for meat and eggs. The estimated population of these breeds are 14000. The preen gland or uropygial gland or rump gland or oil gland is a sebaceous gland. It secretes preen oil which maintain the flexibility of feathers and keeps feather barbules from breaking. It also

[1]Department of Anatomy and Histology, College of Veterinary Science, Assam Agricultural University, Khanapara, Guwahati-781 022, Assam, India.

Corresponding Author: A. Deka, Department of Anatomy and Histology, College of Veterinary Science, Assam Agricultural University, Khanapara, Guwahati-781 022, Assam, India.
Email: dranilvet01@gmail.com

How to cite this article: Deka, A., Sarma, M., Bora, D.P., Devchoudhury, K.B., Sarma, M., Kalita, P.K. and Deori, B.J. (2025). Comparative Micro and Macro Anatomical Observation on Preen Gland of Kamrupa (*Gallus domesticus*), White Leg Horn (*Gallus domesticus*) and Daothigir Fowl (*Gallus domesticus*) of Assam. *Indian Journal of Animal Research*. **59(11):** 1943-1947. doi: 10.18805/IJAR.B-4874.

Submitted: 29-01-2022 **Accepted:** 12-07-2022 **Online:** 29-07-2022

secrets fatty acids, antimicrobial agent and vitamin D precursors. The preen gland also preserved feather structures by keeping keratin flexible and also maintains feather water proofing. (Shafiian and Mobini, 2014). Though extensive information is available on the preen gland of birds in general (Lucas and Stettenhein,1972), the paucity of literature in the comparative micro and macro anatomical aspects in the Kamrupa, White leg horn and Daothigir fowl of Assam promoted to undertaken the present work.

MATERIALS AND METHODS

The present study was conducted on the preen gland of fifteen healthy, adult birds of Kamrupa, White leg horn and Daothigir fowl of Assam in Department of Anatomy and Histology, College of Veterinary Science, Assam Agricultural University, Khanapara, Guwahati, Assam, India for period of one year from 2020-2021. Those fowl were procured from different apart of Assam. The experimental birds were brought to the Department of Anatomy and Histology, College of Veterinary Science, Assam Agricultural University, Khanapara, Guwahati and were sacrificed according to the method of Gracey (1968). After sacrifice, the birds were placed on a clean dissecting table and skin and fascia were reflected carefully without disturbing the organs. Then preen gland were removed very carefully from the base of the tail of fowl. After collection, the tissue samples were fixed in 10% neutral buffered formalin solution and were processed as per the standard technique of procedure (Luna, 1968). The paraffin blocks were sectioned in Shandon Finesse microtome at 5 µm thickness and the sections were stained with Mayer's Haematoxylin and Eosin staining technique for cellular details as per the standard method of Luna (1968).

RESULTS AND DISCUSSION

Macro anatomical observation of preen gland of Kamrupa, white leg horn and daothigir fowl of Assam

In present investigation, it was found that the preen gland or oil gland or rump gland or Uropygial gland of Kamrupa, White leg horn and Daothigir fowl of Assam located just below the skin, on the dorsal aspect of the base of the tail. The glands were bilobed structure and it opened on to the surface of the skin by a nipple-like eminence (Fig 1, Fig 2 and Fig 3). The two lobes and the nipple like structure together form a somewhat heart shaped structure. The apexes of the glands were pointed whereas the bases of the glands were broad.

In present investigation, it was found that the preen gland or oil gland or rump gland of Kamrupa, White leg horn and Daothigir fowl of Assam located just below the skin, on the dorsal aspect of the base of the tail. The glands were bilobed structure and it opened on to the surface of the skin by a nipple-like eminence. Similar findings were reported by Sadoon (2011) in Starling birds, Salibian and Montalti (2009) in various avian species and King and Mclelland (1975) in domestic fowl. The two lobes and the nipple like structure together form a somewhat heart shaped structure. These findings were in accordance with the findings of Hodges (1974) in fowl. The apical portion of the glands were pointed whereas the base was broad.

Micro anatomical observation on the preen gland of Kamrupa, white leg horn and daothigir fowl of Assam

The capsule of the preen gland of Kamrupa, White leg horn and Daothigir was bounded by connective tissue capsule. The thickness of capsule of preen gland of Daothigir, White leg horn and Kamrupa were 40.32±1.61 µm, 38.41±2.31 µm and 36.51±µm, respectively. The thickness of capsule of preen gland was more in Daothigir (Fig 4) compared to the Kamrupa and White leg horn. The thickness of capsule of preen gland of Kamrupa was thin compared to the White leg horn. The capsule was rich in blood vessels (Fig 4). The interlobular connective tissue observed among the secretary tubules of the gland. The interlobular connective tissues arise from the capsule of the gland. The inter tubular connective tissues also is rich in blood vessels. Numerous fibroblasts were observed in the interlobular connective tissues (Fig 5). The number of fibroblasts were abundant in the preen gland of Daothigir compared to the Kamrupa and

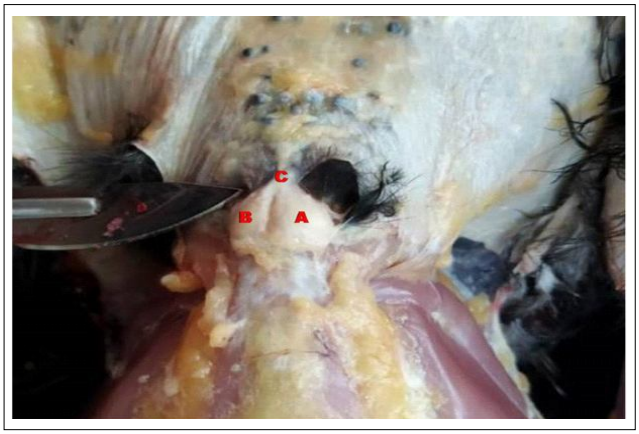

Fig 1: Photograph showing the left lobe (A), right lobe (B) and papilla (C) of Preen gland of Kamrupa bird of Assam.



Fig 2: Photograph showing the left lobe (A) and right lobe (B) of preen gland of white leg horn bird grown in agro-climatic condition of Assam.

White leg horn. The number of secretary tubules of preen gland in Kamrupa were less compared to the tubules of preen gland of White leg horn. The secretary tubules of the preen gland of Kamrupa, White leg horn and Daothigir were open in lumen of the gland (Fig 6). The preen gland parenchyma composed of secretary tubules; duct, which were differentiated by inter tubular connective tissue. The structure of the tubules was similar throughout the whole gland. The tubular epithelial cells were divided into basal or germinative, intermediate, secretary and degenerative layers (Fig 7). The basal or germinative layer consisted of one row of flat shaped cells lied on the basement membrane of the secretary tubules in the preen gland of Kamrupa, White leg horn and Daothigir. The intermediate layer was composed of 2 rows of polygonal cells which laid above the basal layer. The secretary layer was composed of 4 rows of polygonal cells contained lipid droplets as well as secretary granules in the preen gland of Kamrupa, White leg horn and Daothigir. The degenerative layer was adjacent to the lumen of each tubule, composed of few cells with pyknotic nuclei. Each secretary tubules classified into two zones, *i.e.,* peripheral zone and central zone (Fig 8).

The preen gland of Kamrupa, White leg horn and Daothigir was bounded by connective tissue capsule. These findings concurred with the findings of Kanasiya *et al.* (2017) in Kadaknath and White Leghorn breeds of poultry and Ushakumary *et al.* (2011) in Guinea fowl. The thickness of capsule of preen gland of Daothigir, White leg horn and Kamrupa were 40.32±1.61 µm, 38.41±2.31 µm and 36.51±µm, respectively. However, these could not be compared due to non-availability of literature. The thickness of capsule of preen gland was more in Daothigir compared to the Kamrupa and White leg horn. The thickness of capsule of preen gland of Kamrupa was thin compared to the White leg horn. The capsule was rich in blood vessels. The interlobular connective tissues were observed among the secretary tubules of the gland. The interlobular connective tissues that arise from the capsule of the gland was also rich in blood vessels. Numerous fibroblasts were observed in the interlobular connective tissue stroma The number of fibroblasts were abundant in the preen gland



Fig 3: Photograph showing the right lobe (A), left lobe (B), papilla (C) and downy feather tuft of preen gland of Kamrupa bird of Assam.

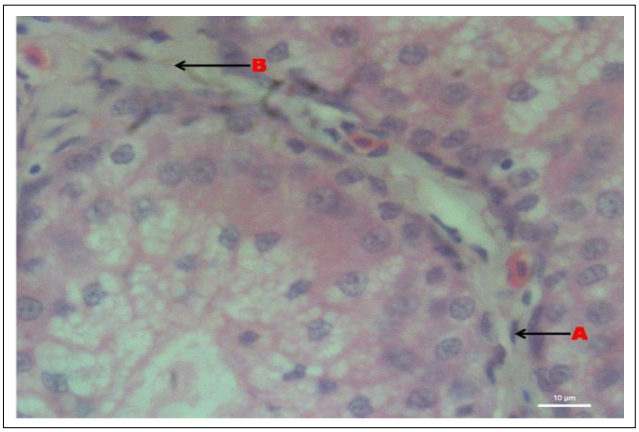

Fig 5: Photomicrograph showing the interlobular connective tissue (B) and fibroblast (A) of preen gland of daothigir bird of Assam.

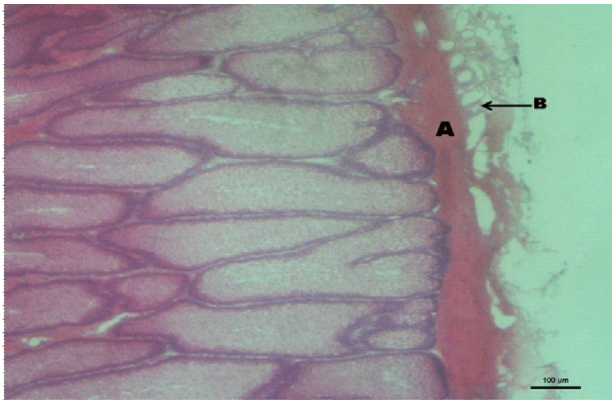

Fig 4: Photomicrograph showing the capsule (A) and blood vessels (B) of preen gland of daothigir bird of Assam.

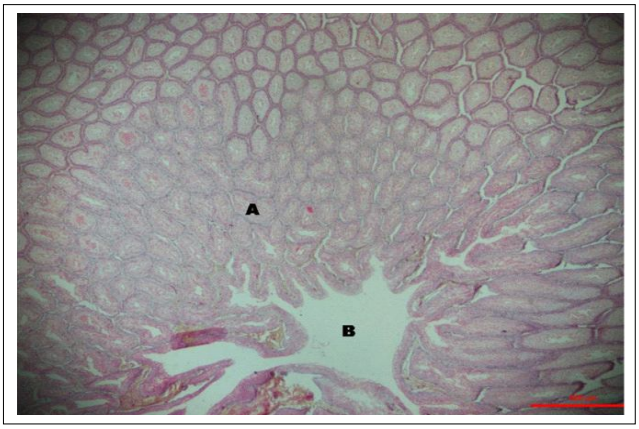

Fig 6: Photomicrograph showing the tubules (A) and lumen (B) of preen gland of Kamrupa bird of Assam.

of Daothigir compared to the Kamrupa and White leg horn. The number of tubules of preen gland in Kamrupa were less compared to the alveoli of preen gland of White leg horn. The tubules of the preen gland of Kamrupa, White leg horn and Daothigir were open in lumen of the gland. Similar observations were reported by Harem *et al.* (2010) in osprey. The preen gland parenchyma composed of secretary tubules; duct as well as trabeculae, which were differentiated by inter tubular connective tissue. These findings were in total agreement with the findings of Sawad (2006) in Moorhen and Al-Mehdawi (2003) in broiler birds. The structures of the tubules were similar throughout the whole gland of Kamrupa, White leghorn and Daothigir. Similar findings were reported by Hodges (1974) in domestic fowl. The tubular epithelial cells were divided into basal or germinative, intermediate and secretary layers which corroborated with the observations recorded by Mohamed (2019) in Mule duck. The basal or germinative layer consisted of one row of flat shaped cells lied on the basement membrane. In Kamrupa, White leg horn and Daothigir, the intermediate layer was composed of 2 rows of polygonal cells lied on the basal layer. The secretary layer composed of 4 rows of polygonal cells contained lipid droplets as well as secretary granules in Kamrupa, White leg horn and Daothigir. Each secretary tubules classified into two zones, *i.e.* Peripheral zone and central zone. The observation in this study was similar to that of Mohamed (2019) in Mule duck.

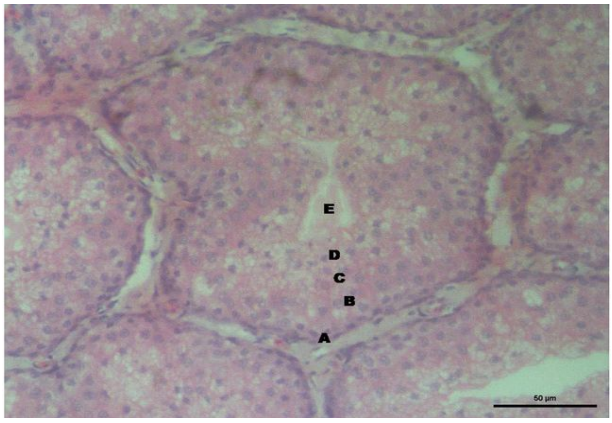

Fig 7: Photomicrograph showing the basal or germinative layer (A), intermediate layer (B), secretary layer (C), degenerative layers (D) and lumen (E) of tubules of preen gland of white leg horn bird grown in agro-climatic condition of Assam.

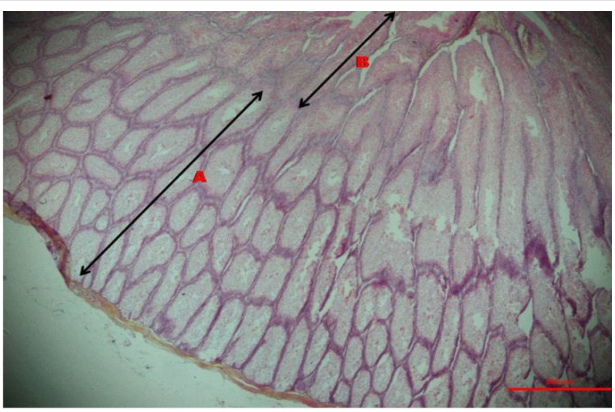

Fig 8: Photomicrograph showing the peripheral zone (A) and central zone (B) of preen gland of Kamrupa birds of Assam.

CONCLUSION

Thorough knowledge of the histology of preen gland of Kamrupa, White leghorn and Daothigir of Assam is very essential in elucidating its role in physiology, histopathology, microbiologist and poultry scientist. In current investigation, it was observed that, macroscopically, the preen gland or oil gland or rump gland or uropygial gland of Kamrupa, White leg horn and Daothigir fowl of Assam situated just below the skin, on the dorsal aspect of the base of the tail. The glands were bilobed structure and it opened on to the surface of the skin by a nipple-like eminence. Microscopically, the preen gland of Kamrupa, White leg horn and Daothigir fowl of Assam was bounded by connective tissue capsule rich in blood vessels. The interlobular connective tissues were observed among the secretary tubules of the gland. The interlobular connective tissues were arises from the capsule of the gland. The inter tubular connective tissues also rich in blood vessels. Numerous fibroblasts were observed in the interlobular connective tissues. The number of fibroblasts were abundant in the preen gland of Daothigir compared to the Kamrupa and White leg horn. The preen gland parenchyma composed of secretary tubules; duct as well as trabeculae, which were differentiated by inter tubular connective tissue. The structures of the tubules were similar throughout the whole gland. The tubular epithelial cells were divided into basal or germinative, intermediate, secretary and degenerative layers. Each secretary tubules classified into two zones, *i.e.*, peripheral zone and central zone. This study will be helpful to poultry scientist, microbiologist and pathologist in disease control regime. If we establish a normal anatomy of preen gland then it will helpful to the pathologist and microbiologist to detect any abnormality in the preen gland for control disease because it has antibacterial and antifungal property as well as precursor of Vitamin D for proception of skin. If the disease is control, then the production of meat and egg will increase.

ACKNOWLEDGEMENT

The authors are grateful to the Dean, College of Veterinary Science, Assam Agricultural University, Khanapara, Assam, India for providing the required facilities to conduct this experiment.

Conflict of interest

All authors declare that they have no conflict of interest.

REFERENCES

Al-Mehdawi, R.S. (2003). Effect of Uropygial Excision on the Physiological Activity of the Broiler. M.Sc. Thesis, College of Agriculture, University of Baghdad.

Bhadauria, P., Kataria, J. Majumdar, M., Bhanja, S., Divya, S.K. and Kolluri, G. (2014). Impact of hot climate on poultry production system-A review. *Journal of Poultry Science and Technology*. **2(4):** 56-63.

Gracey, J.F. (1968). Bleeding Method of Slaughtering- Slaughter. Meat Hygine. 8th Edn. pp. 144-145.

Harem, I.S., Harem, M.K., Kozlu, T.T., Bozkurt, Y.A., Sari, E.K. and Altunay, H. (2010). Histologic structure of the uropygial gland of the osprey (*Pandion hallaetus*). *Journal of Zoo and Wild Life Medicine*. **41:** 147-150.

Hodges, R.D. (1974). The Histology of Fowl. Academic Press Inc. (London) Ltd. pp. 25-26.

Kanasiya, S., Karmore, S.K., Deshmukh, R.K., Barihaiya, R.K. and Gupta, S.K. (2017). Comparative histomorphological studies on uropygial gland of Kadaknath and white leghorn breeds of poultry. *The Indian Journal of Veterinary Science and Biotechnology*. **13:** 58-61.

Kings, A.S. and McLelland, J. (1975). Outline of Avian anatomy. Bailler Tindall, London. pp. 6-7.

Lucas, A.M. and Stettenchein, P.R. (1972). Avian Anatomy. Part-II. Integument. Agriculture hand Book, U.S. Department of Agriculture Washington.

Luna, L.G. (1968). Manual of Histological Staining Methods of the Armed Forces Institute of Pathology. 3rd edn, The Blakistan Division, McGraw Hill Book Company, New York.

Mohamed, R. (2019). Macro and micro anatomical study on the uropygial gland of the Mule duck. *International Journal of Veterinary Science*. **8:** 96-100.

Sadoon, A.H. (2011). Histological study of european starling uropygial gland (*Sturnus vulgaris*). *International Journal of Poultry Science*. **10:** 662-664.

Salibian, A. and Montalti, D. (2009). Physiological and biochemical aspects of the avian uropygial gland. *Brazilian Journal of Biology*. **69:** 437-446.

Sawad, A.A. (2006). Morphological and histological study of uropygial gland in Moorhen (*G.gallinula C.choropus*). *International Journal of Poultry Science*. **5:** 938-941.

Shafiian A.H. and Mobini, B. (2014). Histological and histochemical study on the uropygial gland of the goose (*Anser anser*). *Bulgarian Journal of Veterinary Medicine*. **17:** 1-8.

Ushakumary, S.,Venkatesan, S., Basha, S.H., Selvan, S.S. and Ramesh, G. (2011). Histology and histochemistry of the preen gland in guinea fowl *(Numida mealagris*). *Indian Veterinary Journal*. **88(8):** 132-134.