RESEARCH ARTICLE Indian Journal of Animal Research, Volume 59 Issue 7: 1200-1205 (July 2025)

Clinical Evaluation Osteogenic Properties of Demineralised Bone Matrix (DBM) Xenograft in Femur Fracture in Dogs

Parmvir Singh[1], D.K. Dwivedi[1], R.B. Kushwaha[1], Sharad Kumar[1], Ankur Sharma[1], Pankaj Gupta[1], H.R. Bhardawaj[1]

10.18805/IJAR.B-4881

ABSTRACT

Background: Fracture is one of the common problems encountered in dogs. Fracture healing most of the times results into complications like delayed union, mal-union and non-union. To deal with these complications bone grafting is an important technique lying with clinicians.

Methods: The present study was conducted on 14 clinical cases of dogs with femur fracture. After preliminary examination the dogs were randomly divided into two groups. In group A (n=8) fractures were managed by intramedullary pinning and in group B (n=6), fractures were managed by IM pinning and demineralised bone matrix (DBM) xenograft implantation at the fracture site. The efficacy of the treatment was assessed on the basis of clinical, hemato-biochemical and radiographic observation on day 0 and on 7th, 15th, 30th, 45th and 60th post-operative days.

Result: The pain, lameness and weight bearing scores on the affected limb showed non-significant (P>0.05) variations between the two groups on different post-operative intervals. The hematological parameters also varied non-significantly (P>0.05) between the two groups. A significant (P<0.05) increase in the serum alkaline phosphatase values was observed upto 30th post-operative day in group B animals as compared to group A animals and thereafter it gradually decreases and return to normal level on 60th post-operative day in both the groups. Radiographic scores were better in group B dogs. Early radiographic signs of fracture healing were observed in group B dogs than group A dogs. No any graft related complications were observed during the study.

Key words: DBM, Dog, Femur, Fracture, Xenograft.

INTRODUCTION

Fracture of the long bones were one of the most common orthopedic problems in canines (Aithal *et al.*, 1999; Jani *et al.*, 2014). Femur fractures accounted for 45% of all long bone fractures, followed by the tibia (26%), radius and ulna (16%) and the humerus (13%) (Harasen, 2003). Fractures were more common in young animals under six months of age (46.02%) (Simon *et al.*, 2010).

The main goal of fracture treatment is to restore the structural integrity of the fractured bone as well as functional ability of the affected limb (Johnson *et al.*, 1998). Healing of these fractures is associated with various complications, such as delayed union, non-union and malunion, all of which have a negative impact on the limb's functionality. Non-union is a common consequence that occurs after a long bone fracture with defects and its frequency is determined by the location and severity of the injury to the bone, soft tissue and vascular structures. Loss of bone tissue and non-union fractures of long bones are challenging problemsfor orthopaedic surgeons (Rao *et al.,* 2001). Bone grafting, along with primary fixation, is one of the key techniques used by orthopedic surgeons to cope with these issues and speed up bone recovery.

Allografts, xenografts, polymers, ceramics and certain metals have all been used to induce bone reunion as alternatives to autografts (Friedlaender; 1987). Autografts are replaced with allografts and xenografts, which are obtained from living or deceased donors. DBM is a suitable allograft material for improving bone healing because it reduces the mineral phase, making growth factors more available and thereby increasing the osteoinductive qualities (Vertenten *et al.*, 2010). Urist (1965) found that removing the mineral from the bone exposes more biologically active bone morphogenetic proteins. Acid demineralization reduces antigenic stimulation and should increase the release of bone morphogenic proteins (BMPs) (Riley *et al.*, 1996). These growth factors control the transformation of progenitor cells into osteoprogenitor cells, which are responsible for the production of bone and cartilage.

[1]Division of Veterinary Surgery and Radiology, Faculty of Veterinary Science and Animal Husbandary, Sher-e-Kashmir University of Agricultural Sciences and Technology, Jammu-181 102, Jammu and Kashmir, India.

Corresponding Author: D.K. Dwivedi, Division of Veterinary Surgery and Radiology, Faculty of Veterinary Science and Animal Husbandary, Sher-e-Kashmir University of Agricultural Sciences and Technology, Jammu-181 102, Jammu and Kashmir, India.
Email: kumardinesh25@rediffmail.com

How to cite this article: Singh, P., Dwivedi, D.K., Kushwaha, R.B., Kumar, S., Sharma, A., Gupta, P. and Bhardawaj, H.R. (2025). Clinical Evaluation Osteogenic Properties of Demineralised Bone Matrix (Dbm) Xenograft in Femur Fracture in Dogs. *Indian Journal of Animal Research*. **59(7):** 1200-1205. doi: 10.18805/IJAR.B-4881.

Submitted: 09-02-2022 **Accepted:** 31-05-2022 **Online:** 13-06-2022

The use of xenogenic bovine DBM is a suitable alternative to cortical autogenous graft and will reduce the morbidity related to harvesting autogenous graft during surgery. Xenogenic demineralized bone matrix implanted in animals showed early mineralization compared to hydroxyapatite treated and control animals.

Keeping in view of paucity of literatures pertaining to clinical application of xenogenic demineralized bone matrix in bone tissue regeneration in dogs the present study was plannedto evaluate the efficacy of xenogenic demineralized bone matrix (DBM) in the healing of femur fracture and its complications.

MATERIALS AND METHODS

In the present study fourteen (14) dogs with femur fractures were included during the study period of one year. After history taking, clinical, radiographical and haemato-biochemical examinations, the dogs were randomly divided into two groups A and B (Table 1). In group A, eight (8) dogs were included and treated with intramedullary pinning only while in group B; six (6) dogs were included and treated with intramedullary pinning alongwith implantation of demineralized bone matrix xenograft at the fracture site. The efficacy of treatment was evaluated on the basis of clinical, haemato-biochemical and radiographic observations.

In all the dogs cranio-lateral surgical approach was followed (Piermattei *et al.,* 2004) under general anesthesia (Fig 1).

The data related to history and signalment of each case was recorded. Clinical evaluation was done on day 0 *i.e.* on operative day or pre-operative day and 7th, 15th, 30th, 45th and 60th post-operative day for pain, lameness and weight-bearing on affected / operated limb and graded on 0-4 score, where 0 indicated no pain, no lameness and no weight bearing and 4 indicated severe pain, severe lameness and complete weight bearing.

Two orthogonal views *i.e.* cranio-caudal and medio-lateral views of femur were taken in all the cases preoperatively, immediate post-operative and on 7th, 15th, 30th, 45th and 60th post-operative days for radiographic study. The following radiographic scoring system followed for assessment of fracture healing as described by Hayashi *et al.* (2008).

About 3-5 ml of venous blood was collected, in an EDTA vacutainer, to record the different haemato-biochemical parameters. 1 ml of blood was utilized for evaluation of hemoglobin (g/dl), PCV (%) and TLC (N$\times$10^3/mm^3). The remaining blood was centrifuged to obtain plasma for the estimation of calcium (mg/dl), phosphorus (mg/dl), alkaline phosphatase (U/L) and total protein (g/dl). By using the commercially available kits the values were recorded on days 0, 7th, 15th, 30th, 45th and 60th post-operative days. The data were analyzed by two way ANOVA followed by Duncan test at significance level of 0.05 ($P<0.05$) using SPSS programme 16.00 version.

RESULTS AND DISCUSSION

The present study was conducted at TVCC F.V.Sc and AH of SKUAST Jammu during July 2020 to July 2021. In present study most of the femur fracture in dogs were caused by automobile accidents (64.28%, n=9) followed by fall from the height (28.57%, n=4) and attacked by other dog (7.14%, n=1). According to the results of Jani *et al.* (2014), trauma in the form of road accident was the principal cause of fracture in dogs. The mean pain score was found better in group B dogs as compared to group A on 45th post-operative day during the present study. The reason behind this might be the slow healing of fracture in group A dogs where fracture was managed by intramedullary pinning alone. There were no significant difference in mean values of pain score between two groups at different intervals as the DBM xenograft material only facilitated in fracture healing, it unable to provide the structural stability at the fracture site. The mean lameness score in the affected limb was much better in the group B dogs on 45th post operative day as compared to group A dogs. This might be due to rigid fixation and the inflammatory phase early subsided because of osteoinduction at the fracture site due to implantation of DBM xenograft in the group B dogs. The mean score of weight bearing was lower in group A dogs as compared to group Bon 45th and 60th post-operative day in the present study. This might be due to the rapid healing of fractures in

Table 1: Design of study.

Group	No. of dogs	Treatment
A	8	Intramedullary pinning (IMP)
B	6	IMP + demineralized bone matrix (DBM) xenograft

Score	Radiographic interpretation
0	Presence of fracture line with no bone formation
1	Irregularity at fragment lines of the fracture site
2	Initial/discrete periosteal proliferation
3	Exuberant/organized periosteal proliferation
4	Exuberant osseous callus in evolution with the presence of periosteal proliferation
5	Exuberant osseous callus in evolution and discrete radiolucent line at the gap between the fracture fragments
6	Exuberant osseous callus and absence of radiolucent line

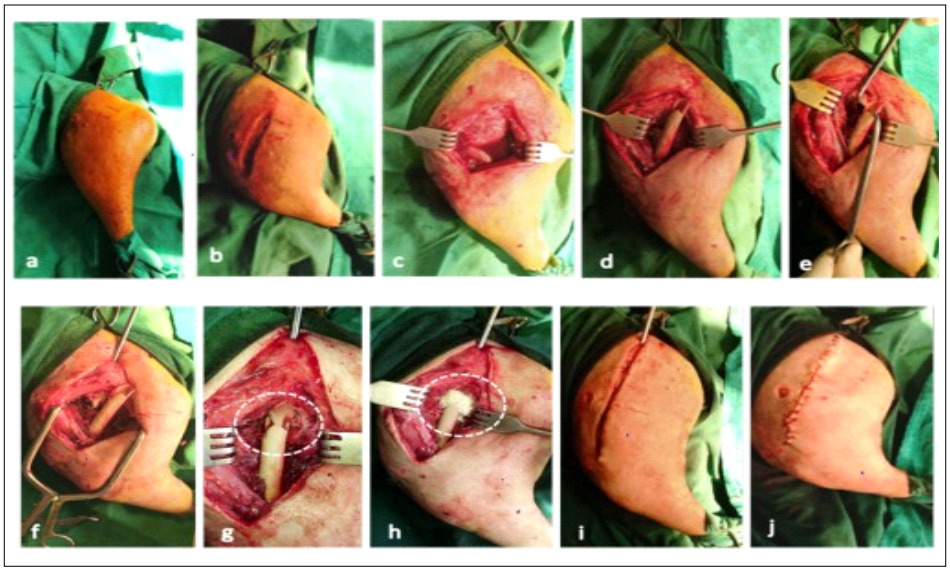

Fig 1: a) Aseptic preparation b) Incision over the skin, c, d, e) Exposure the fracture fragments f) Insertion of intramedullary pin in normograde fashion from trochanteric fossa; g) Advancement of pin into the distal fracture fragment h) DBM, xenograft implanted at the fracture site i) Suturing of tensor fascia-lata; j) Skin suturing.

group B dogs because of the effect of DBM xenograft implanted at the fracture site. Similar findings have also been reported by Tembhurne *et al.* (2010) in which they concluded that during fracture healing the delay in the weight bearing on the affected limb might be due to the pain and infection at the fracture site.

The haemoglobin values fluctuated between 9-12 g/dl in dogs of both the groups and these values were within the normal reference range (9-15 gm/dl). It might be considered that the DBM xenograft did not caused any harmful effect on haemogram. Nagaraja (1996) and Rajhans (2013) also reported the similar pattern in the hemoglobin values.

The mean ± SE values of PCV were found to be within the normal range in both the groups A and B pre-operatively as well as post-operatively. Similar findings were also reported by Patil *et al.* (2017).

The mean leucocyte count expressed a decreasing pattern on all the post-operative days in both the groups. This gradual decrease at successive post-operative days might be attributed to return to the normal condition after fracture in the dogs. Further, higher values of TLC in both the groups on 0 day were indicative of systemic inflammatory responses and stress after fracture. Similar findings were observed by Maiti *et al.* (1999) and Srinivasamurthy (2000).

The mean±SE values of serum calcium were significantly less on 7th and 15th post operative days in all the dogsof two groups. Thereafter, it gradually increases from 30th post-operative day onwards and reaches to normal level. The lower level of calcium on the 7th and 15th post-operative day might be due to mobilization of excessive calcium at the fracture site and the gradual increase in serum calcium from 30th day onward might be attributed to the remodelling phase of fracture healing. Soliman and Hasan (1964) and Kumar *et al.* (1992) also reported lower level of serum calcium during initial stages of fracture healing and opined that this decrease can be attributed to increased urinary excretion after traumatic bone injury. Similar findings were also observed by the Komnenou *et al.* (2005). Contrary to it, Hegade *et al.* (2007) and Rani *et al.* (2012) reported higher levels of calcium at successive post operative days. However, Saikia *et al.* (1986) and Chandy (2000) reported that there were no correlation between the fracture healing and the calcium levels. There was no any significant difference in mean value of calcium between two groups.

The mean values of serum phosphorus were within the normal physiological limits in all the dogs of both groups throughout the study period. The initial decrease in the serum phosphorus might be attributed to the osteoclastic activity leading to the resorption of the dead bone. Similar findings were also reported by Pandey and Udapa (1981) and Rajhans (2013). However, increase in the serum phosphorus level in later stages might be attributed to increased osteoblastic activity and collagen synthesis at the fracture site. These results are in agreement with the findings of Mahendra *et al.* (2007) and Manjunath (2010). Dwivedi *et al.* (2009) observed non-significant variation in serum calcium during compound fracture healing of long bones in subsequent post-operative period.

The mean±SE values of serum alkalinephosphatase showed a significant increase upto day 30th post-operatively in all the dogsof both groups and thereafter a significant decrease in ALP values from 45th day onward in both groups. Further the increase was more in case of group B dogsas compared to group A. This might be due to the implantation of the osteoinductive biomaterial *i.e.* DBM xenograft at the fracture site which further increases the osteoblastic activity.

The higher value of serum Alkaline phosphatase in the initial stages in all the dogscould be due to exuberant proliferation of fibrous tissue at the fracture site following the bone trauma and proliferation of maturing osteogenic cells and active osteoblasts as reported by Umashankar and Ranganath, (2008). Dwivedi *et al.* (2021) also reported significant increase in mean values of serum alkaline phosphates upto 15th post-operative day in a study on femur fracture repair in dogs.

The mean±SE values of total protein (g/dl) remain within the base value throughout the study period. According to Kaneko *et al.* (1997) decreased level of serum total protein is seen in chronic starvation and anorexia, while high level of total protein may due to dehydration.

The mean ±SE values of radiographic score in group A dogs on pre-operative day were 0.75±0.16 and post-operatively it were 1.75±0.25, 2.87±0.29, 3.87±0.23, 4.50±0.26 and 5.12±0.23 on 7th, 15th, 30th, 45th and 60th days, respectively. The mean±SE values of radiographicscore in group B dogs on pre-operative day were 0.67±0.21 and post-operatively it were 2.00±0.36, 3.33±0.42, 4.33±0.49, 5.00±0.36 and 5.33±0.33 on 7th, 15th, 30th, 45th and 60th days, respectively. There were significant (P<0.05) increase in the mean±SE values of radiographic scores at successive post-operative days as compared to day 0 within both the groups. The mean±SE values of radiographic scores showed a non-significant (P>0.05) difference between the groups at different post-operative time intervals but the values of radiographic scores were better in group B dogs on each post-operative day when compared with group A dogs.

The 45th post-operative radiographs revealed complete radiographic healing of fractures in group B dogs

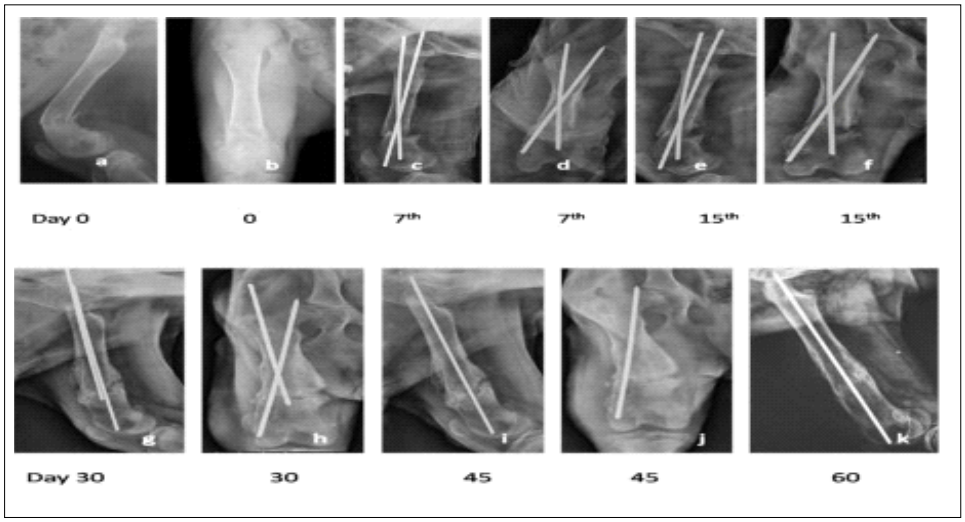

Fig 2: Pre and successive post-operative radiograph of group A animal showing complete healing of fracture and cortical continuity by 60th day.

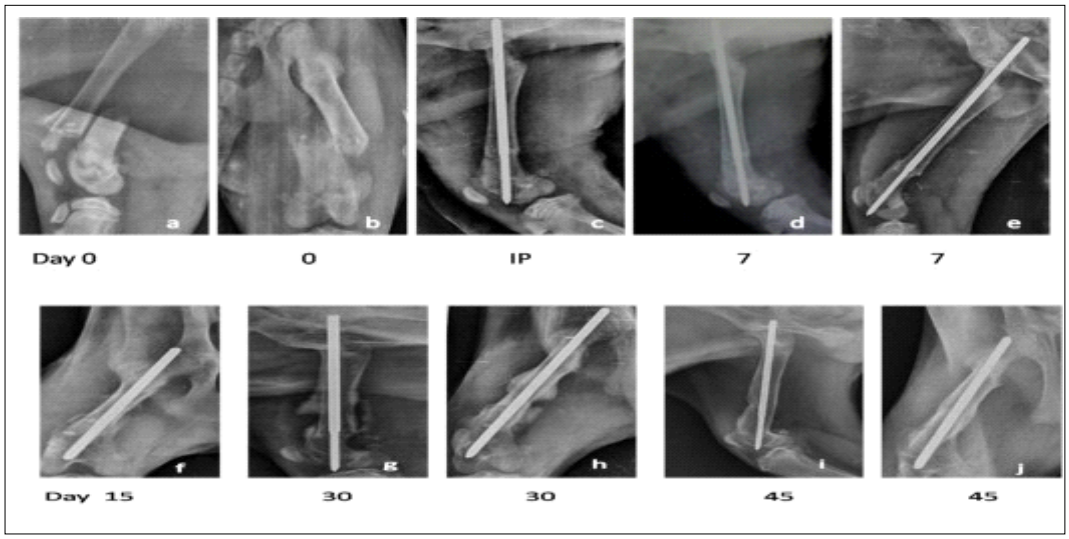

Fig 3: Pre and successive post-operative radiograph of group B animal: By 15th day showing invisible fracture line and on 45th day completely invisible fracture line.

as the fracture line was completely invisible on radiograph (Fig 3) while in group A dogs discrete fracture lines were still visible and complete healing occurs by 60th day (Fig 2).

No any intra-operative as well as post-operative graft related complications were noticed in any dog during the study.

CONCLUSION

Based on the above observations, we may conclude that in both the group clinical, haemato-biochemical and radiographic outcome were almost similar. The alkaline phosphatase showed better biochemical activity in group B dogs. Radiographic scores also showed better in group B dogs. Therefore, the femoral fractures repaired with intramedullary pinning along with incorporation of demineralized bone matrix xenograft may aid in healing of femoral fracture during the biochemical phases of fracture healing as evident from radiographic scores. Demineralized bone matrix xenograft is safe for use in femur fracture repair in dogs.

Conflict of interest

All authors declare that they have no conflict of interest.

REFERENCES

Aithal, H.P., Singh, G.R. and Bisht, G.S. (1999). Fractures in dogs: A survey of 402 cases. *Indian Journal of Veterinary Surgery*. **20(1):** 15-21.

Chandy, G. (2000). Clinical evaluation of stainless steel and acrylic external skeletal fixators as adjuncts to intramedullary pinning for fracture of femur in dogs. M.V.Sc. thesis, Tamil Nadu Veterinary and Animal Sciences University, Chennai.

Dwivedi, D.K., Ganesh, T.N., Ameerjan, K. and Ramesh, G. (2009). Management of compound fracture of radius-ulna and tibia-fibula using Ilizarov's ring fixator in dogs. *Indian J. Vet. Surg*. **30(2):** 98-100.

Dwivedi, D.K., Kushwaha, R.B., Bhadwal, M.S., Gupta, A.K., Soodan, J.S. and Bhardwaj, H.R. (2021). Evaluation of β-tricalcium phosphate biomaterial in femur fracture repair in dogs. *Indian Journal of Animal Research*. **58(5):** 827-833. doi: 10.18805/IJAR.B-4418.

Friedlaender, G.E. (1987). Bone grafts: The basic science rationale for clinical applications. *The Journal of Bone and Joint Surgery*. **69:** 786-790.

Harasen, G. (2003). Common long bone fractures in small animal practice-Part 1. *Canadian Veterinary Journal*. **44(4):** 333-334.

Hayashi, A.M., Matera, J.M., Almeida, F.D. and Muramoto, C. (2008). Evaluation ofelectro acupuncture in bone healing of radius-ulna fracture in dogs. *Brazilian Journal of Veterinary Research and Animal Science*. **45(5):** 339-347.

Hegade, Y., Dilipkumar, D. and Usturge, S. S. (2007). Comparative evaluation of biochemical parameters during fracture healing in dogs. *Karnataka Journal of Agricultural Sciences*. **20:** 694-695.

Jani, S.M.Y., Kushwaha, R.B., Gupta, A.K., Malik, K. and Soodan, J.S. (2014). Occurrence of fractures in dos: A retrospective study of five years. *Indian Journal of Veterinary Surgery*. **35(1):** 73-74.

Kaneko, J. (1997). Carbohydrate Metabolism and its Decrease: Blood Glucose in Animals. Text Book of Clinical Biochemistry of Domestic Animals. 5th Edn., Elsevier Publishers, Philadelphia, U.S.A. 64.

Komnenou, A., Karayannopoulou, M., Polizopoulou, Z.S., Constantinidis, T.C. and Dessiris, A. (2005). Correlation of serum alkaline phosphatase activity with the healing process of long bone fractures in dogs. *Veterinary Clinical Pathology*. **34(1):** 35-38.

Kumar, R., Gill, P.S., Singh, R., Setia, M.S. and Rattan, P.J.S. (1992). Plasma electrolyte changes during fracture healing in dogs. *Indian Veterinary Journal*. **69(5):** 476-477.

Mahendra, A.M., Ranganath, L. and Vasanth, M.S. (2007). Effect of polymethylmethacrylate in femoral fracture repair on hematobiochemical parameters in dogs. *Indian Veterinary Journal*. **84(6):** 587-589.

Maiti, B.K., Sen, T.B. and Sanki, S. (1999). Haemato-biochemical changes following application of Ilizarov technique in treatment of femur fractures in dogs. *Indian Journal of Animal Health*. **38:** 133-134.

Manjunath, D.R. (2010). Comparision of "c-arm guided" and "aiming device" interlocking nailing of femoral fracture repair in dogs. M.V.Sc. Thesis submitted to Karnataka Veterinary, Animal and Fisheries Sciences University, Bidar.

Nagaraja, B.N. (1996). Plastic implants for femoral fractures in experimental dogs. M.V.Sc. thesis, University of Agricultural Sciences, Bangalore, India.

Pandey, S.K. andUdapa, K.N. (1981). Effect of growth hormone on biochemical response after fracture in dogs. *Indian Journal of Veterinary Surgery*. **1(2):** 73-78.

Patil, M., Kumar, D. and Shivaprakash, B.V. (2017). Physiological and hemato-biochemical changes during repair of femur fracture in dogs. *The Pharma Innovation Journal*. **6(8):** 381-385.

Piermattei, D.L. and Jhonson, K.A. (2004). Approach to Shaft of Femur. In: An Atlas of Surgical Approaches to the Bones and Joints of the Dog and Cat. 4th ed. Saunders. 3336-337.

Rajhans, M. (2013). Stabilisation of splinters of long bone fracture in dogs. M.V.Sc. and A.H. thesis (Surgery and Radiology), Nanaji Deshmukh Veterinary Science University, Jabalpur.

Rani, R.U., Rajendran, N. and Vairavasamy, K. (2012). Immobilisation and treatment of femoral diaphyseal oblique fractures in dogs using double intramedullary pinning and cerclage wiring: A study in twelve patients. *Intas Polivet*. **13(2):** 411-415.

Rao, T.M., Lakhshmipathi, G.V., Satry, T.P. and Ramakrishna, O. (2001). Biochemical changes following ulnar segmental defect repair with fibrillar collagen-hydroxyapatite and porous hydroxyapatite implants in canines. *Indian Journal of Animal Research*. **35(2):** 112-115.

Riley, E.H., Lane, J.M., Urist, M.R., Lyons, K.M. and Lieberman, J.R. (1996). Bone morphogenetic protein-2: Biology and applications. *Clinical Orthopaedics and Related Research*. **324:** 39-46.

Saikia, J., Singh, A.P., Chandana, I.S. and Chawla, S.K. (1986). Changes in certain blood and bone biochemical constituents during fracture healing in the bovine. *Indian Journal of Animal Sciences*. **56:** 1-3.

Simon, M.S., Ganesh, R., Ayyappan, S., Rao G.D., Kumar R.S., Kundave, V.R. and Das, B.C. (2010). Incidence of pelvic limb fractures in dogs: A survey of 478 cases. *Veterinary World*. **3(3):** 120-121.

Soliman, F.A. and Hassan, S.Y. (1964). Serum calcium and phosphorus in rabbits during fracture healing with reference to parathyroid activity. *Nature*. **204(4959):** 693-694.

Srinivasamurthy, K.M. (2000). Studies on implantation of gentamicin plaster of paris beads for femoral fracture in experimental dogs. M.V.Sc. Thesis submitted to University of Agricultural Sciences, Bangalore.

Tembhurne, R.D., Gahlod, B.M., Dhakate, M.S., Akhare, M.S., Upadhaye, S.V. and Bawasker, S. (2010). Management of femoral fracture with the use of horn peg in canine. *Veterinary World*. **3(1):** 37-41.

Umashankar, S. and Ranganath, L. (2008). Osteomedullographic studies during fracture healing in dogs. *Indian Veterinary Journal*. **85(4):** 382-384.

Urist, M. (1965). Bone: Formation by autoinduction. *Science*. **150:** 893-899.

Vertenten, G., Gasthuys, F., Cornelissen, M., Schacht, E. and Vlaminck, L. (2010). Enhancing bone healing and regeneration: Present and future perspective in veterinary orthopaedics. *Veterinary Comparative Orthopaedics Traumatology*. **23(3):** 153-162.